INSTRUCTIONS FOR LETTERS TO THE EDITOR

Editorial comment in the form of a Letter to the Editor is invited. The length of a letter should not exceed 800 words, with a maximum of 10 references and no more than 2 figures or tables; and no subdivision for an abstract, methods, or results. Letters should have no more than 4 authors. Financial associations or other possible conflicts of interest should be disclosed.

Letters should be submitted via our online submission system, available at the Manuscript Central website: http://mc.manuscriptcentral.com/jrheum For additional information, contact the Managing Editor, The Journal of Rheumatology, E-mail: jrheum@jrheum.com

Association of Rheumatoid Arthritis with Multiple Sclerosis: Report of 14 Cases and Discussion of Its Significance

To the Editor:

Neurologic symptoms may be observed in rheumatoid arthritis (RA), but they rarely involve the central nervous system (CNS). Multiple sclerosis (MS) is the most frequent demyelinating disease and has been associated with various chronic inflammatory diseases, but the association with RA is not frequently described[1]. We describe a series of 14 patients with the coexistence of RA and MS and discuss the possible links between these 2 conditions.

Between 2001 and 2004, a retrospective study was conducted by Club Rhumatismes et Inflammation (CRI), a subgroup of the Société Française de Rhumatologie. All French rheumatologists belonging to the CRI were requested by letter and via the CRI website (www.cri-net.com) to report cases of RA and MS occurring in the same patient. Inclusion criteria for our study were the 1987 American College of Rheumatology criteria for RA[2] and the McDonald criteria for MS[3]. A rheumatologist was required for the diagnosis of RA and a neurologist for MS diagnosis. The following variables were analyzed: age at RA and MS onset, extra-articular disease, joint space narrowing and/or erosions on hand or foot radiographs, rheumatoid factors (RF, nephelometry), antinuclear antibodies (ANA, indirect immunofluorescence), treatments for RA, disease course of MS (remitting/relapsing or progressive), neurologic symptoms, brain and/or spinal cord magnetic resonance imaging (MRI) findings, cerebrospinal fluid (CSF) analysis, visual evoked potential (VEP) results, and MS treatments. Patient outcome was also examined. Exclusion criteria were all other causes of demyelinating diseases (primary Sjögren's syndrome, systemic lupus erythematosus, sarcoidosis, Behçet's disease, Lyme disease, HIV or HTLV1 infection); all these conditions were excluded during the initial evaluation of the neurologic disease by the neurologist. Previous anti-tumor necrosis-alpha (TNF-α) therapy (etanercept, infliximab, or adalimumab) was also an exclusion criterion.

Fourteen patients (12 men, 2 women) were reported by 12 rheumatologists (Table 1). Mean age (± SD; yrs) at RA and MS diagnosis were 47.1 ± 17.5 and 39.8 ± 10.3, respectively. Mean disease duration (yrs) at the time of the study was 7.6 ± 8.2 for RA and 14.2 ± 11.1 for MS. RA was diagnosed before MS in 3 cases (delay between the 2 diseases: 12.3 ± 12.1 yrs) while MS preceded RA in 10 cases (delay: 12.9 ± 8.3 yrs) and the diseases occurred simultaneously in one case. One patient with juvenile chronic arthritis developed joint deformities and erosions. No patient had sicca syndrome, nodules were observed in 3 cases, and one patient had Raynaud's phenomenon. Radiographic erosions were observed in 11 cases and joint space narrowing in 9 cases. No patients had cervical spine subluxation. RF was positive in 6/14 cases and ANA were found in only 4/12 cases. Three of these 4 patients had a labial salivary gland biopsy that did not show sialadenitis and the fourth had negative anti-SSA/SSB antibodies. The treatments they received were mainly methotrexate (11/14 cases) while other disease modifying antirheumatic drugs were rarely used (leflunomide in 1 case, gold and tiopronin in another case). Most patients received corticosteroids for their arthritis (8/14 cases).

In parallel, the neurologic disease was of the relapsing/remitting type in 6 cases and of the progressive type in 8 cases. Magnetic resonance imaging was performed in all cases, but results were not available for 2 patients: brain (and/or spinal cord) signal abnormalities were observed in the white matter in all cases. Oligoclonal bands were found on CSF examination in 9/11 cases while 2/11 analyses were normal (for 3 cases, the CSF analysis was not available). Finally, VEP showed retrobulbar optic neuritis in 4/6 cases and were normal in the 2 other cases (VEP were not available or not performed for the other patients). Treatments for MS were mainly intravenous methylprednisolone (8/14 cases), immunosuppressive drugs (4/14 cases: cyclophosphamide, azathioprine) and/or interferon-ß (5/14 cases). One patient died due to MS complications and 2 patients were lost to followup. The patient with juvenile chronic arthritis had a severe disease course with advanced articular damage.

The worldwide prevalence of RA has been estimated at 1% while the frequency of MS is 0.1%. RA and MS can be associated with various autoimmune diseases but the association of the 2 diseases in the same patient has rarely been reported[4,5]. In a case control study, 5 cases of RA were found in 155 MS (1.9%)[6]. Another study reported that 15% of French MS patients had a first degree relative with autoimmune disease (including Grave's disease, RA, vitiligo, type 1 diabetes mellitus)[7]. These data suggest that an association may exist between MS and another autoimmune disease. Many lines of evidence indicate that MS is a T cell mediated autoimmune disease similar to RA[1,8] with genetic and environmental factors playing a role in their pathogenesis. RA and MS share many similarities regarding their pathophysiology, etiology, and histology; and certain viruses like Epstein-Barr virus have been incriminated as a possible etiologic factor in both diseases[1]. Another relevant finding is the existence of T cell reactivity against myelin basic protein, the putative autoantigen in MS, for circulating mononuclear cells from patients with RA[8].

The relationship between RA and MS is strengthened by reports of demyelinating events occurring in the disease course of patients with RA receiving TNF-α antagonists. Indeed, 19 cases have been reported, 17 following etanercept administration and 2 following infliximab administration for inflammatory arthritis[9]. TNF-α is secreted by microglia and macrophages in the CNS and is thought to play a role in myelin and oligodendrocyte damage. Patients with progressive MS have high levels of TNF-α in their CSF; moreover, these TNF-α levels correlated with disease severity. However, anti-TNF-α therapy in patients with MS has been unsuccessful and has tended to increase MS attacks. The description of neurologic events in RA patients receiving TNF-α blockers leads to speculation regarding the causal relationship between neurologic signs and this treatment. However, the number of cases does not exceed what might be expected in the general population[10]. It might be hypothesized that RA

See Neurological complications of infliximab, *page 1018*.

Table 1. Clinical, biological, and radiological characteristics of inflammatory arthritis and neurological symptoms, and resonance imaging characteristics, in 14 patients with rheumatoid arthritis and multiple sclerosis.

Case	Sex	Age at RA Diagnosis	Age at MS Diagnosis	RA: Extra-articular Disease	Erosion/ Joint Space Narrowing	RF	ANA	RA Treatment	MS: Clinical Symptoms	Disease Course	MRI	CSF	VEP	MS Treatment
1	F	27	22	—	Yes/Yes	+	ND	MTX	Spastic paraplegia, urine sphincter dysfunction, optic neuritis	Progressive	ND	ND	ND	MP, CYC, IFN-ß
2	M	52	46	Nodules	Y/Y	+	–	MTX	Optic neuritis	Relapsing remitting	Brain lesions	Oligoclonal IgG bands	Abnormal	MP
3	M	50	45	—	Y/Y	–	–	Leflunomide, CS	Spastic paraplegia, cerebellar syndrome	Progressive	Brain lesions	Oligoclonal IgG bands	ND	MP, IFN-ß
4	F	47	37	—	No/No	–	–	MTX, CS	Optic neuritis paresthesia	Relapsing remitting	Brain plaques	ND	ND	MP, IFN-ß
5	F	64	31	—	Y/Y	+	–	MTX, CS	Spasticity, incontinence	Progressive	Brain plaques	Normal	ND	DM, AZA
6	F	24	27	Nodules	Y/Y	+	ND	MTX, CS	Spasticity, paresthesia, cranial nerve involvement	Relapsing remitting	Brain plaques	Oligoclonal IgG bands	Normal	MP, IFN-ß
7	F	69	57	—	Y/Y	–	–	MTX, CS	Spasticity, incontinence	Progressive	Brain plaques	Oligoclonal IgG bands	ND	AZA
8	F	40	48	—	Y/N	–	–	MTX	Spastic paraplegia, incontinence, optic neuritis	Progressive	Cervical cord and brain plaques	Oligoclonal IgG bands	Abnormal	MP
9	F	50	31	Nodules, Raynaud's syndrome	Y/Y	+	1/800	MTX	Optic neuritis, V cranial nerve, cerebellar and vestibular syndromes	Relapsing remitting	ND	Oligoclonal IgG bands	Abnormal	
10	F	6	32	—	Y/Y	–	1/100	Gold salts, tiopronin, and MTX	Paresthesia VII cranial nerve	Relapsing remitting	Spinal cord and brain plaques	Oligoclonal IgG bands	ND	MP, IFN-ß
11	F	67	53	—	N/N	–	–	MTX, CS	Spasticity, cerebellar syndrome, incontinence	Progressive	Brain plaques	Oligoclonal IgG bands	ND	CS
12	F	43	43	—	Y/N	+	1/640	NSAID	Optic neuritis, paresthesia	Progressive	Brain plaques	Oligoclonal IgG bands	Normal	CS
13	F	58	47	—	N/Y	–	–	CS	Spasticity, optic neuritis, paresthesia, incontinence	Progressive	Brain plaques	ND	ND	CS, CYC
14	F	52	38	—	Y/N	–	1/320	MTX. CS	Spastic paraparesia, optic neuritis, cerebellar syndrome, incontinence	Relapsing remitting	Brain plaques	Normal	Abnormal	MP

M: male; F: female; RA: rheumatoid arthritis; MS: multiple sclerosis; MRI: magnetic resonance imaging; CSF: cerebrospinal fluid; VEP: visual evoked potentials; MTX: methotrexate; CS: corticosteroids; NSAID: nonsteroidal antiinflammatory drugs; ND: not determined; MP: methylprednisolone; CYC: cyclophosphamide; AZA: azathioprine; DM: dexamethasone; IFN-ß: interferon-ß.

with high disease activity and/or high TNF-α levels could favor white matter neurologic lesions. Alternatively, neurologic events while receiving TNF-α blockers could be caused by latent neurologic disease unmasked by treatment, or by pre-existing neurologic disease[10].

Coexistence of neurologic disease with an inflammatory arthritis may increase disability, alter quality of life, and induce psychological disturbances. However, central neurologic disease may attenuate joint disease as observed in patients with hemiplegia, reflecting the CNS control of the inflammatory process. Thus, it is conceivable that MS may decrease joint inflammation by regulating the systemic production of inflammatory mediators. In our series, MS did not seem to have an influence on the clinical course of arthritis and *vice versa*. The concurrence of MS in our patients did not prevent joint damage in most cases and thus, despite the neurologic disease, RA will probably continue to progress. There are no previous reports of clinical and radiological outcomes of RA in a patient with MS.

Autoimmunity in MS is well demonstrated and it is reasonable to consider that patients with MS are prone to develop other autoimmune diseases. Since a great proportion of our patients developed MS first and subsequently RA, the best explanation for these cases is a predisposition in MS patients to develop another autoimmune disease with common etiologic cofactors. In addition, onset of MS is usually between 20 and 40 years of age while the onset of RA is usually between the fourth and sixth decade. In light of demyelinating events reported in association with anti-TNF-α treatment, we recommended the careful evaluation of patients with RA before anti-TNF-α administration and the avoidance of this treatment in those with preexisting MS diagnosis, a history of unexplained central neurologic signs, or a family history of MS.

ÉRIC TOUSSIROT, MD, PhD, University Hospital Besançon; ÉDOUARD PERTUISET, MD, René Dubos Hospital Pontoise; ANTOINE MARTIN, MD, Saint-Brieuc Hospital; SYLVIE MELAC-DUCAMP, MD, Nevers Hospital; MICHEL ALCALAY, MD, University Hospital Poitiers; BRUNO GRARDEL, MD, Arras; PAUL SEROR, MD, Av Ledru-Rollin Paris; ALETH PERDRIGER, MD, PhD, University Hospital Rennes; DANIEL WENDLING, University Hospital Besançon; DENIS MULLEMAN, MD, University Hospital Tours; LUC BERANECK, MD, Corbeil-Essonnes Hospital; XAVIER MARIETTE, MD, PhD, University Hospital Kremlin Bicêtre; the Club Rhumatismes et Inflammation, France.

Address reprint requests to Dr. E. Toussirot, Department of Rheumatology, University Hospital Jean Minjoz, Bd. Fleming, F-25030 Besançon Cédex, France.

REFERENCES

1. Hafler DA, Slavik JM, Anderson DE, O'Connor KC, De Jager P, Baecher-Allan C. Multiple sclerosis. Immunol Rev 2005;204:208-31.
2. Arnett FC, Edworthy SM, Bloch DA, et al. The American Rheumatism Association 1987 revised criteria for the classification of rheumatoid arthritis. Arthritis Rheum 1988;31:3215-24.
3. McDonald I, Compston A, Edan G, et al. Recommended diagnostic criteria for multiple sclerosis: guidelines from the international panel on the diagnosis of multiple sclerosis. Ann Neurol 2001;50:121-7.
4. Baker HGW, Balla JL, Burger HG, Ebeling P, Mackay IR. Multiple sclerosis and autoimmune diseases. Aust NZ J Med 1972;3:256-60.
5. De Keyser J. Autoimmunity in multiple sclerosis. Neurology 1988;38:371-4.
6. Migdard R, Gronning M, Riise T, Kvale G, Nyland H. Multiple sclerosis and chronic inflammatory diseases. Acta Neurol Scand 1996;93:322-8.
7. Heinzlef O, Alamowitch S, Sazdovitch V, et al. Autoimmune diseases in families of French patients with multiple sclerosis. Acta Neurol Scand 2000;101:36-40.
8. Martin R, McFarland HF, McFarlin DE. Immunological aspects of demyelinating diseases. Ann Rev Immunol 1992;10:156-87.
9. Mohan N, Edwards ET, Cupps TR, et al. Demyelination occurring during anti-tumor necrosis factor a therapy for inflammatory arthritides. Arthritis Rheum 2001;44:2862-9.
10. Robinson WH, Genovese MC, Moreland LW. Demyelinating and neurologic events reported in association with tumor necrosis factor a antagonism. Arthritis Rheum 2001;44:1977-83.

Regulation of Killer Immunoglobulin-like Receptors in Systemic Lupus Erythematosus

To the Editor:

The etiology of systemic lupus erythematosus (SLE) is still unclear. Recently, a viral origin has been suggested, since patients with SLE have almost always had Epstein-Barr virus (EBV) infection before onset of disease[1]. Autoantibodies against Ro or Sm have been shown to crossreact with EBNA1 antigen[1] and EBV replication is present in SLE flares[2].

In genome-wide scans, several genetic risk loci of SLE have been identified including chromosome region 19q13.4[3]. Here, killer immunoglobulin-like receptors (KIR) are localized. KIR are members of the immunoglobulin superfamily and are expressed on natural killer (NK) and subsets of T cells. Inhibitory and activating KIR molecules bind to target-cell major histocompatibility complex (MHC) class I molecules and either prevent or induce NK cell attack on normal or virus-infected cells[4]. Inhibitory KIR bind distinct subsets of MHC class I molecules. Varying expression of KIR on NK and T cell clones may allow subsets of these cells to recognize different virus-infected cells.

The KIR repertoire is highly diverse, since there are at least 13 different loci that are not universally expressed[5]. A number of KIR phenotypes as combinations of KIR have been defined[6]. There are 2 major haplotypes: A is characterized by the presence of KIR2DL1 and KIR2DL3, and B contains KIR2DL2. In addition, there appear to be numerous other haplotypes[7].

Recently, KIR2DS2 has been found to be associated with vasculitis in patients with rheumatoid arthritis (RA)[8]. In addition, the presence of KIR2DS2 and KIR2DL2 in the absence of ligands for KIR2DL2 is associated with psoriatic arthritis, and the presence of KIR2DS2 in the absence of KIR2DL2 with scleroderma[9].

We studied whether KIR are also associated with SLE. DNA from 200 patients with SLE was obtained from a stock that is being collected in a German multicenter study on the genetics of connective tissue diseases in Hannover[9]. All patients were German and Caucasian, fulfilled American College of Rheumatology (ACR) criteria for classification of SLE[10], and gave written consent to participate in our study. DNA samples from 104 German Caucasian blood donors were obtained as controls; 100 of these have been described[9].

Table 1. Frequency of 9 KIR genes in patients with SLE (n = 200) and blood donors (n = 104) (ns: not significant).

KIR	SLE, %	Controls, %	p
2DL1	92.5	90.4	ns
2DL2	44.5	51.9	0.045
2DL3	92.0	90.4	ns
2DS1	40.5	34.6	ns
2DS2	47.5	54.8	0.047
2DS3	23.5	24.0	ns
2DS4	92.5	93.3	ns
3DS1	37.0	34.6	ns
3DL1	95.0	96.2	ns

Table 2. Frequency of the 10 most frequent KIR phenotypes according to Crum, *et al*[5] in SLE (n = 200) and blood donors (n = 104).

KIR Phenotype	2DL1	2DL2	2DL3	2DS1	2DS2	2DS3	2DS4	3DS1	3DL1	SLE, %	Controls, %	p
1	+	–	+	–	–	–	+	–	+	35.0	34.6	ns
2	+	–	+	+	–	–	+	+	+	8.5	5.8	ns
3	+	–	+	–	+	–	+	–	+	1.0	1.9	ns
4	+	+	+	+	+	+	+	–	+	1.5	0	ns
5	+	–	+	+	+	–	+	+	+	0	1	ns
6	+	–	+	+	–	+	+	+	+	1	1	ns
7 and 8	+	+	+	+	+	+	+	+	+	9.0	8.7	ns
9	+	+	+	–	+	–	+	–	+	12.0	17.3	0.061
10	+	+	+	+	+	–	+	+	+	3.5	8.7	0.037

KIR were typed using genomic DNA of patients with SLE and controls by a polymerase chain reaction (PCR) method and primers as described[6,9].

For RNA preparation, blood was drawn from 7 patients with SLE in a flare and 3–4 months later in remission. A flare was defined as an increase of SLE Disease Activity Index (SLEDAI) score by at least 3 points compared to the previous visit. Only patients with a maximal medication of 5 mg prednisolone per day and no immunosuppressives were included. Medication in remission had to be identical to medication during the flare. All patients had both KIR2DS2 and KIR2DL2. Intron-spanning primers were designed for amplification of cDNA of KIR and to avoid amplification of genomic DNA. Values of KIR were normalized by comparison with actin as reference gene.

Comparing the frequency of 9 different individual KIR and of combinations of KIR, both KIR2DS2 and 2DL2 were found to be significantly less frequent in patients with SLE than in controls (47.5% vs 54.8% and 44.5% vs 51.9%; Table 1). Those differences were mainly due to a decreased prevalence of KIR phenotypes 10 ($p = 0.037$) and 9 ($p = 0.06$) (phenotypes as defined[5]), which both contain KIR2DS2 and 2DL2 (Table 2). Also, there was an increased prevalence of homozygous KIR haplotype A (56% vs 48.1%; $p = 0.041$) in patients with SLE (data not shown). KIR2DS1 was slightly more prevalent in patients than controls (40.5% vs 34.6%); however, this difference was not significant ($p = 0.061$). None of the associations remained significant after Bonferroni corrections for multiparameter analysis.

KIR combination 2DS2+2DL2–, found to be associated with scleroderma[9], was not associated with SLE.

In quantitative real-time PCR investigations, transcripts of KIR2DS2 and KIR2DL2 were not regulated differently in SLE flares, remission, or in healthy controls (data not shown).

KIR appear to be only minor risk factors, if at all, for SLE. KIR2DS2, a receptor associated with several other autoimmune disorders, was in contrast to our expectations less frequent in patients with SLE than in controls. Even that low significance has to be viewed with caution due to multiparameter testing in our study, and needs to be confirmed in other studies.

There was a weak association of KIR haplotypes and SLE, but after Bonferroni correction for multiparameter analysis, none of these associations remained significant. Neither KIR2DS2 nor KIR2DL2 were regulated in SLE flare. Therefore, KIR do not appear to be involved in pathogenesis of SLE.

TANJA MOMOT, MD; REINHOLD E. SCHMIDT, Professor of Internal Medicine; TORSTEN WITTE, MD, Abteilung Klinische Immunologie, Medizinische Hochschule Hannover, Hannover, Germany.

Address reprint requests to Dr. T. Witte. E-mail: witte.torsten@mh-hannover.de

REFERENCES

1. McClain MT, Heinlen LD, Dennis GJ, Roebuck J, Harley JB, James JA. Early events in lupus humoral autoimmunity suggest initiation through molecular mimicry. Nat Med 2005;11:85-9.
2. Kang I, Quan T, Nolasco H, et al. Defective control of latent Epstein-Barr virus infection in systemic lupus erythematosus. J Immunol 2004;172:1287-94.
3. Moser KL, Neas BR, Salmon JE, et al. Genome scan of human systemic lupus erythematosus: evidence for linkage on chromosome 1q in African-American pedigrees. Proc Natl Acad Sci USA 1998;95:14869-74.
4. Moretta A, Vitale M, Bottino C, et al. P58 molecules as putative receptors for major histocompatibility complex (MHC) class I molecules in human natural killer (NK) cells. Anti-p58 antibodies reconstitute lysis of MHC class I-protected cells in NK clones displaying different specificities. J Exp Med 1993;178:597-604.
5. Crum KA, Logue SE, Curran MD, Middleton D. Development of a PCR-SSOP approach capable of defining the natural killer cell inhibitory receptor (KIR) gene sequence repertoires. Tissue Antigens 2000;56:313-26.
6. Uhrberg M, Valiante NM, Shum BP, et al. Human diversity in killer cell inhibitory receptor genes. Immunity 1997;7:753-63.
7. Hsu KC, Liu XR, Selvakumar A, Mickelson E, O'Reilly RJ, Dupont B. Killer Ig-like receptor haplotype analysis by gene content: Evidence for genomic diversity with a minimum of six basic framework haplotypes, each with multiple subsets. J Immunol 2002;169:5118-29.
8. Yen JH, Moore BE, Nakajima T, et al. Major histocompatibility complex class I-recognizing receptors are disease risk genes in rheumatoid arthritis. J Exp Med 2001;193:1159-67.
9. Momot T, Koch S, Hunzelmann N, et al. Association of killer cell immunoglobulin-like receptors with scleroderma. Arthritis Rheum 2004;50:1561-5.
10. Tan EM, Cohen AS, Fries JF, et al. The 1982 revised criteria for the classification of systemic lupus erythematosus. Arthritis Rheum 1982;25:1271-7.

Angry Fat

To the Editor:

A 23-year-old Maori man presented in January 2004, with a 2-week history of exercise intolerance secondary to painful, swollen legs. He reported sweats and weight loss (10 kg). He was febrile (39.3°C) and had a nodular rash over the lower legs consistent with erythema nodosum. Blood tests showed anemia and neutropenia: hemoglobin 106 g/l, white blood cell count 2.6×10^9/l (neutrophils 62%, lymphocytes 35%), platelets 223 ×

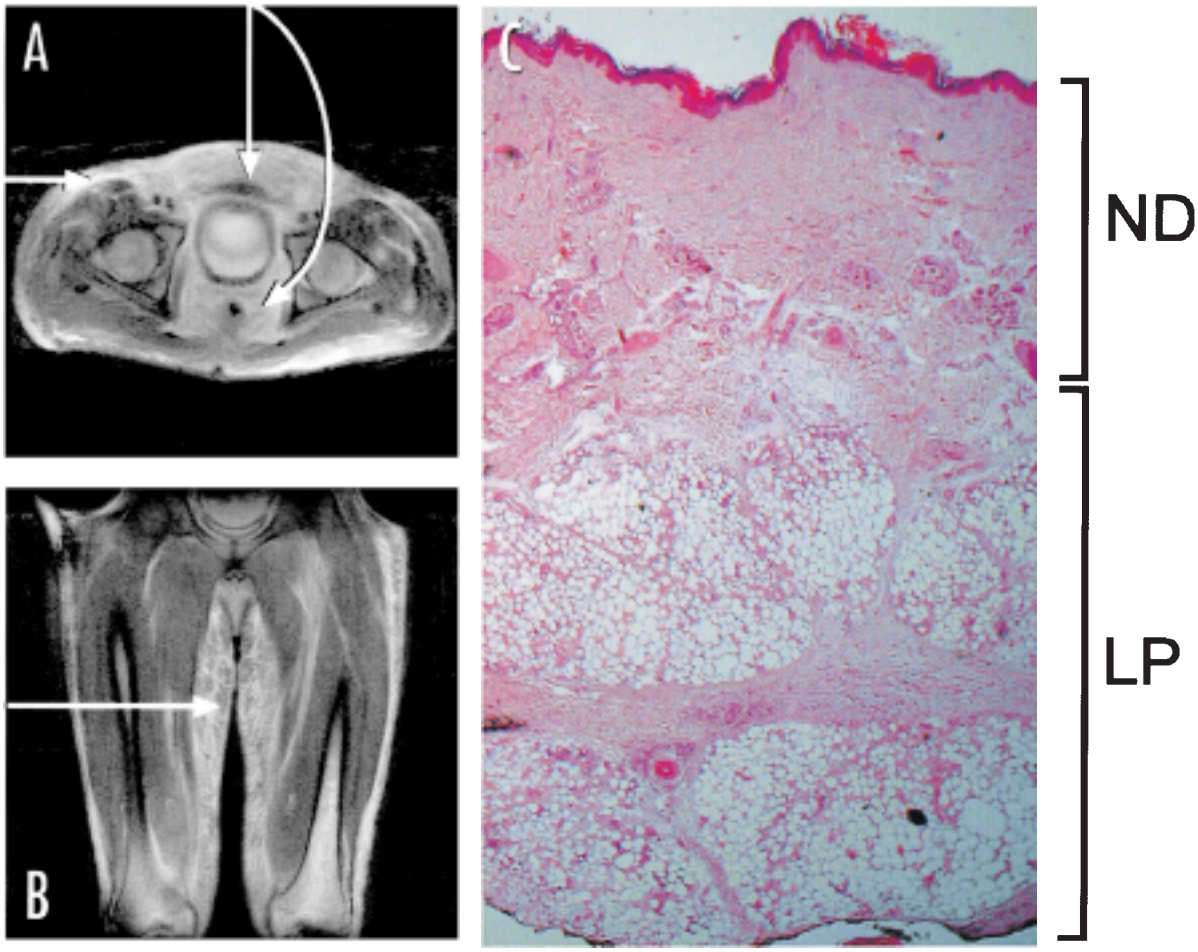

Figure 1. MRI of the pelvis and lower limbs, histology of the skin biopsy T2-weighted imaging of the pelvis showing increased signal in the subcutaneous fat, which is normally dark, and the pelvic fat surrounding the bladder and rectum (A, arrows). Short tau inversion recovery imaging of the lower limbs showing diffusely increased signal in the subcutaneous fat bilaterally (B, arrow). Low power hematoxylin-eosin stain (×40) of skin biopsy showing lymphocytic infiltration of lobules in the subcutaneous fat (C). Brackets indicate normal dermis (ND) and lobular panniculitis (LP).

10^9/l; increased C-reactive protein (56 mg/l), and mildly increased transaminases. Serology demonstrated previous contact with hepatitis B, Epstein-Barr, and cytomegaloviruses. Mantoux test, midstream urine, serum creatine kinase, α_1-antitrypsin, amylase, and computerized tomography (CT) of the chest were normal. After a 2-week course of indomethacin his rash resolved, but he was readmitted one month later with ongoing leg pain and fever. CT of the abdomen and pelvis showed widespread increased signal in the subcutaneous and intraperitoneal fat consistent with generalized panniculitis (Figure 1A). Vasculitis serology, bone marrow examination, blood cultures, echocardiography, and urine microscopy were negative. Over the next 2 months his symptoms progressed; he became immobile and lost more weight (10 kg). The plantar aspects of the feet were severely tender and there was moderate weakness and wasting of the hip and shoulder girdles. His deterioration was complicated by a lobar pneumonia and acute respiratory failure for which he required intensive care treatment. Magnetic resonance imaging (MRI) showed circumferential subcutaneous panniculitis involving the thighs and lower abdominal wall with no muscle involvement (Figure 1B). A full-thickness biopsy (MRI-guided) from normal-looking thigh skin showed diffuse infiltration of the subcutaneous lobules by small T lymphocytes (CD3, CD56 negative) without obvious atypia, accompanied by histiocytes (CD68 positive) and small numbers of B lymphocytes (CD20 positive) (Figure 1C). The lymphocytes rimmed intact fat cells, a feature of lymphoma, but there were no cytophagic features. T cell gene rearrangement analysis of abnormal tissue taken from the paraffin block showed no evidence of monoclonality. A muscle biopsy from vastus lateralis showed myofiber necrosis with mild inflammatory changes around the microvasculature of the surrounding connective tissue. In summary, the findings were lobular lymphocytic panniculitis in fat and ischemic necrosis in muscle. The patient was started on pulsed methylprednisone followed by high dose prednisone therapy and he rapidly improved. Over the next 12 months, on a combination of methotrexate and tapered prednisone, his symptoms resolved and his weight normalized. On at least 2 occasions he relapsed when he omitted his medications.

Panniculitis has never been regarded as a primary condition, with the exception of Weber-Christian disease, which is of uncertain etiology and now only of historical interest. It is usually a manifestation of another illness[1]. For example, erythema nodosum (the commonest form of panniculitis) secondary to streptococcal infection. The pathological classification has always been descriptive, using a mixture of geographic features, (septal or lobular or both); the infiltrating cell type; (neutrophils, lymphocytes, histiocytes, or mixed) and other characteristics such as vasculitis, calcification, granulomata, hemorrhage, cytophagia, or necrosis. Some of these features are specific for certain etiologies, for example acute neutrophilic panniculitis and α_1 antitrypsin defficiency. However, lobular lymphocytic panniculitis is not one of these and can be associated with a diverse range of conditions such as tuberculosis (erythema induratum when fully developed), chronic viral hepatitis, systemic lupus erythematosus,

dermatomyositis, severe weight loss, cold injury, and lymphoma[2-4]. This result is less helpful to the clinician, but soft tissue imaging may be useful for showing the extent of inflammation (and selecting an appropriate biopsy site), when the overlying skin is normal. We have no evidence that the T lymphocytes infiltrating the fat are malignant and so for diagnostic purposes we assume they are reactive. Therefore we are proposing that both the panniculitis and the systemic effects of this illness are secondary to cytokines secreted by reactive T cells, which in turn can be modulated by steroid therapy.

DAVID L. JARDINE, FRACP, Department of General Medicine, E-mail: david.jardine@cdhb.govt.nz; JACQUI GARDNER, FRCPA, Department of Pathology, Christchurch Hospital; RICHARD STEELE, FRACP, Clinical Immunologist, Wellington Hospital, Wellington, New Zealand.

ACKNOWLEDGMENT

The authors are grateful for the advice of Dr. John O'Donnell and Dr. Ken Macdonald who reviewed the manuscript. Dr. Wayne Bailey prepared the images for the figure.

REFERENCES

1. Weedon D. Skin Pathology. 2nd edition. New York: Churchill Livingstone; 2002:521-41.
2. Sutra-Loubet C, Carlotti A, Guillemette J, Wallach D. Neutrophylic panniculitis. J Am Acad Dermatol 2004;50:280-5.
3. Solans R, Cortes J, Selva A, et al. Panniculitis: a cutaneous manifestation of dermatomyositis. J Am Acad Dermatol 2002;46:S148-S150.
4. Craig AJ, Cualing H, Thomas G, Lamerson C, Smith R. Cytophagic histiocytic panniculitis — a syndrome associated with benign and malignant panniculitis: case comparison and review of the literature. J Am Acad Dermatol 1998;39:721-36.
5. Solomon AR, Kantak AG, Ramirez JE, Rajarman S, Raimer SS, Goldman AS. Suppressor-cytotoxic T-lymphocyte panniculitis. Pediatr Dermatol 1986;3:295-9.