

# Successful Treatment of Long-standing Neuro-Behçet's Disease with Infliximab

HAROON SARWAR, HUGH McGRATH Jr, and LUIS R. ESPINOZA

**ABSTRACT.** Behçet's disease is a chronic relapsing form of vasculitis affecting multiple organs. Central nervous system involvement is a common presentation. Tumor necrosis factor- $\alpha$  (TNF- $\alpha$ ) is considered to play a major role in the disease pathogenesis. We describe a patient with a long history of neuro-Behçet's disease who showed a remarkable response to infliximab therapy. Given the variable and limited success of other interventions, the use of anti-TNF- $\alpha$  therapy seems to be effective for patients with refractory disease. (J Rheumatol 2005;32:181-3)

*Key Indexing Terms:*

BEHÇET'S DISEASE

TUMOR NECROSIS FACTOR- $\alpha$

INFLIXIMAB

VASCULITIS

CYTOKINES

Behçet's disease (BD) is a multisystem chronic relapsing inflammatory disease classified among the vasculitides. Recurrent mucocutaneous lesions may be the only symptom in mild cases, but articular, ocular, vascular and gastrointestinal, and central nervous system (CNS) involvement may occur in severe cases. CNS involvement presenting with headache, aseptic meningitis, pyramidal signs, seizures, and/or ophthalmoplegia is seen in up to 49% of cases<sup>1,2</sup>.

Various nonspecific immunosuppressive drugs including cyclophosphamide, cyclosporine, and azathioprine, used alone or in combination, frequently fail to control inflammation or maintain remission. The etiology of BD is unknown; however, it is currently thought that a central pathogenic role of tumor necrosis factor- $\alpha$  (TNF- $\alpha$ ) is possible. Use of TNF- $\alpha$  blockers has been reported for various manifestations of BD<sup>3</sup>. We describe a patient with a history of long-standing advanced and disabling CNS-BD who was successfully treated with infliximab.

## CASE REPORT

A 42-year-old Palestinian man, who immigrated to the US about 15 years ago, presented to the emergency department at The Medical Center of Louisiana in New Orleans in May 2003 with altered mental status and difficulty walking.

His history included a diagnosis of CNS toxoplasmosis diagnosed in April 1996 when he presented to a local hospital with slurred speech, headache, and visual disturbances. A diagnosis of CNS-toxoplasmosis was

made on the basis of history, magnetic resonance imaging (MRI) findings, the presence of antibodies to *Toxoplasma gondii*, and a brain biopsy showing chronic inflammation. He was treated for cerebral toxoplasmosis with sulfadiazine, pyrimethamine, and leucovorin for several months. Following the brain biopsy, he developed a left-side hemiparesis and slurring of speech. He was subsequently transferred to an extended care facility for rehabilitation.

On his current presentation, physical examination showed 2 painful shallow ulcers on the lateral border of the tongue, 3 painful ulcers over the scrotum, and a 3 cm biopsy scar over his occipital region. A neurological examination revealed slurred speech and lack of orientation to time, place, and person, but normal cranial nerve, motor, and sensory systems. Routine laboratory tests including a comprehensive metabolic panel, complete blood count, and urinalysis were unremarkable. His immunologic profile showed an elevated sedimentation rate of 40 mm/h, negative antinuclear antibody testing, a negative extractable nuclear antigen assay, and a negative rheumatoid factor. A brain MRI showed multiple multifocal enhancing lesions involving deep white matter, more on the left than on the right side (Figure 1A). A brain biopsy was performed that showed acute and chronic small vessel vasculitis with a predominance of lymphocytes (Figure 2). A slit-lamp eye examination was normal. A pathology test was negative.

Based upon these findings, a diagnosis of BD with CNS vasculitis was made and treatment with oral prednisone 60 mg/day was started. After a negative PPD skin test he was given a 3 mg/kg intravenous infusion of infliximab. Two weeks later, he returned, showing marked improvement in his mental status and rapidly healing scrotal and oral ulcers. A second infusion of infliximab, again 3 mg/kg, was given and the prednisone reduced to 40 mg/day. The same and final dose of infliximab was administered 4 weeks later.

He was reevaluated after the third infusion. Examination showed complete healing of scrotal and oral ulcers and normal mental status. His prednisone was reduced to 20 mg/day. A repeat brain MRI (Figure 1B) showed complete resolution of the deep white matter changes evident on the previous MRI.

At one year followup, he continues to be stable after a successful tapering of prednisone to 10 mg/day.

## DISCUSSION

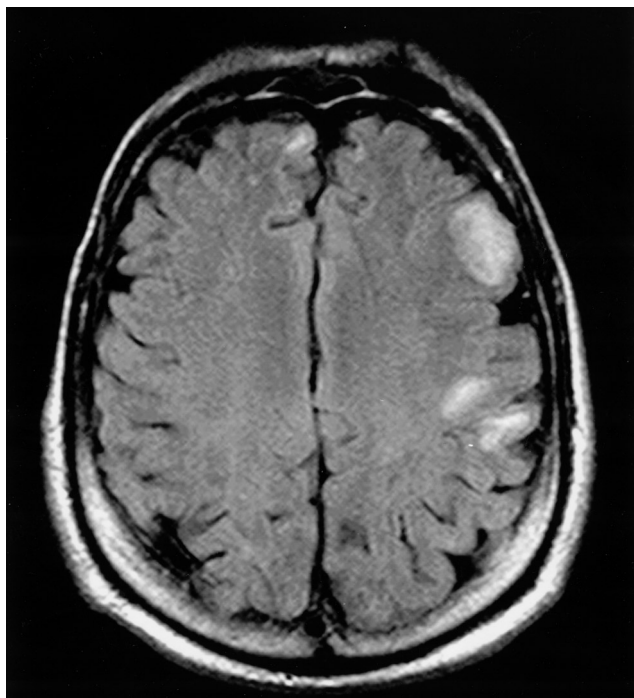
BD, also known as Behçet's syndrome, is a chronic relapsing, multisystem vasculitis seen predominantly in the Far East, Middle East, and the countries around the

*From the Section of Rheumatology, Department of Medicine, Louisiana State University Health Sciences Center, New Orleans, Louisiana, USA.*

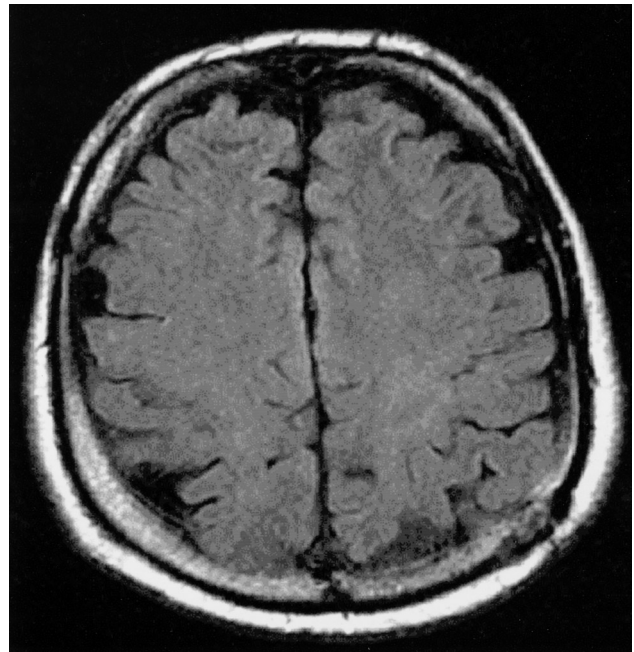
*H. Sarwar, MD, Clinical Rheumatology Fellow; H. McGrath Jr, MD, Professor of Medicine; L.R. Espinoza, MD, Professor of Medicine and Chief, Section of Rheumatology.*

*Address reprint requests to Dr. L.R. Espinoza, Section of Rheumatology, LSU Health Sciences Center, 1542 Tulane Ave., Box T4M-4, New Orleans, LA 70112, USA. E-mail: lespinl@lsuhsc.edu*

*Submitted April 1, 2004; revision accepted August 11, 2004.*



A



B

Figure 1. A. Axial T1 weighted sequence brain MRI done at admission showing multiple enhancing lesions. B. Repeat brain MRI showing complete resolution of enhancing lesions.

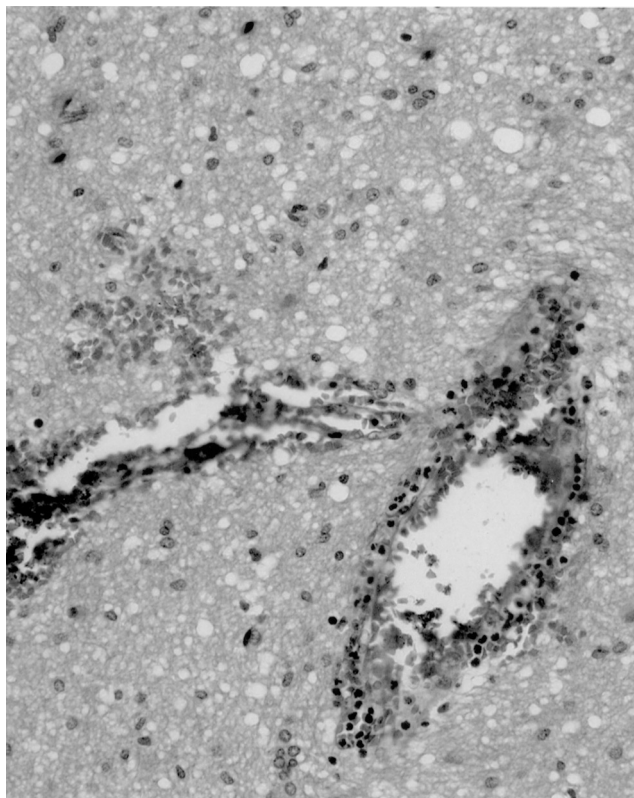


Figure 2. Right occipital lobe brain biopsy showing low-grade perivascular inflammation, neutrophils, and lymphocytes.

Mediterranean area. Its main clinical features are recurrent oral and genital ulcers, ocular inflammation, mucocutaneous lesions, arthritis, and neurologic involvement. BD is characterized by spontaneous exacerbations and remissions, while the rates of symptom recurrence and healing times vary greatly among patients. Although the course of inflammation is classically intermittent, the disease can stabilize in a significant number of patients or it can become chronic in a given organ<sup>4</sup>. The goal of management is to treat early to avoid recurrence and irreversible damage to vital organs. Our patient did not fulfill proposed diagnostic criteria for Behçet's syndrome, and he should be classified with an incomplete form. However, the presence of scrotal lesions, painful and recurrent oral ulcers, and CNS vasculitis with predominant lymphocyte perivascular infiltration support a diagnosis of Behçet's over other inflammatory disorders such as reactive arthritis<sup>5</sup>.

Inflammation in BD is thought to be mediated by cytokines, primarily TNF- $\alpha$ , derived from T helper-type 1 lymphocytes<sup>6</sup>. TNF- $\alpha$  is implicated as well by the increased numbers of monocytes and T lymphocytes expressing the gamma-delta receptor that overproduce TNF- $\alpha$  in patients with active disease<sup>7,8</sup>. There are also reports of increased levels of circulating TNF- $\alpha$  and soluble TNF- $\alpha$  receptors in the peripheral blood of patients with active disease<sup>9,10</sup>. Finally, a central pathogenic role for TNF- $\alpha$  is supported by reports describing remarkable benefit in BD patients who have received the anti-TNF drugs for various organ-specific

disease manifestations. However, a recent Medline review showed only one published case of the successful use of a TNF- $\alpha$  inhibitor, infliximab, for the treatment of neuro-BD<sup>11</sup>. More recently, Sfrikakis, *et al*<sup>12</sup> reported their experience in the use of infliximab in a large number of patients with sight-threatening ocular inflammation in Adamantiades-Beçet disease. They used infliximab infusions at 5 mg/kg in 25 patients, and were able to show a rapid and sustained improvement of visual acuity and a 5-fold decrease in relapses in the majority of their patients who were refractory to conventional immunosuppressive therapy including prednisone alone or in combination with cyclophosphamide, cyclosporine, and/or azathioprine. As in our patient, they were able to taper or discontinue other concomitant immunosuppressive drugs, including steroids. No major adverse effects requiring discontinuation of infliximab therapy were seen. Of interest, our patient experienced a rapid and prolonged clinical response with infliximab given at 3 mg/kg, compared to 5 mg/kg used for other patients with CNS and ocular involvement<sup>11,12</sup>.

To our knowledge, this is the second report of successful use of infliximab for treatment of CNS-BD. Given the variable and limited success of other interventions, use of anti-TNF- $\alpha$  therapy seems to be a step forward in the therapeutic approach for patients with refractory disease.

#### ACKNOWLEDGMENT

We thank Mark Stellingworth, MD, for providing computed tomographic imaging and brain biopsy micrographs.

#### REFERENCES

1. Akman-Demir G, Serdaroglu P, Tasci B, et al. Clinical patterns of neurological involvement in Behçet's disease: evaluation of 200 patients. *Brain* 1999;122:2171-82.
2. Serdaroglu P, Yazici H, Ozdemir C, et al. Neurologic involvement in Behçet's syndrome: a prospective study. *Arch Neurol* 1989;46:265-9.
3. Sfrikakis PP. Behçet's disease: a new target for anti-tumour necrosis factor treatment. *Ann Rheum Dis* 2002;61 Suppl 2:51-3.
4. Kaklamani VG, Vaiopoulos G, Kaklamani PG. Behçet's disease. *Semin Arthritis Rheum* 1998;27:197-217.
5. International Study Group for Behçet's Disease. Criteria for diagnosis of Behçet's disease. *Lancet* 1990;335:1078-80.
6. Gul A. Behçet's disease: an update on the pathogenesis. *Clin Exp Rheumatol* 2001;19 Suppl 24:S6-12.
7. Yamashita N, Kaneoka H, Kaneko S, et al. Role of gamma delta T lymphocytes in the development of Behçet's disease. *Clin Exp Immunol* 1997;107:241-7.
8. Mega JL, Dilsen N, Sanguedolce V, et al. Overproduction of monocyte-derive TNF- $\alpha$ , IL-6, IL-8 and increased neutrophil superoxide generation in Behçet's disease. A comparative study with familial Mediterranean fever and healthy subjects. *J Rheumatol* 1993;20:1544-9.
9. Turan B, Gallati H, Gurler A, et al. Systemic levels of the T cell regulatory cytokines IL-10 and IL-12 in Behçet's disease; soluble TNFR-75 as a biological marker of disease activity. *J Rheumatol* 1997;24:128-32.
10. Evereklioglu C, Er H, Turkoz Y, et al. Serum levels of TNF- $\alpha$ , sIL-2R, IL-6 and IL-8 are increased and associated with elevated lipid peroxidation in patients with Behçet's disease. *Mediators Inflamm* 2002;11:87-93.
11. Licata G, Pinto A, Tuttolomondo A, et al. Anti-tumor necrosis factor alpha monoclonal antibody therapy for recalcitrant cerebral vasculitis in a patient with Behçet's syndrome. *Ann Rheum Dis* 2003;62:280-1.
12. Sfrikakis PP, Kaklamani PH, Elezoglou A, et al. Infliximab for recurrent, sight-threatening ocular inflammation in Adamantiades-Beçet's disease. *Ann Intern Med* 2004;140:404-6.