A Comparison of Magnetic Resonance Imaging, Sonography, and Radiography of the Hand in Patients with Early Rheumatoid Arthritis

JAN LUCAS HOVING, RACHELLE BUCHBINDER, STEPHEN HALL, GARY LAWLER, PETER COOMBS, STEPHEN McNEALY, PAUL BIRD, and DAVID CONNELL

ABSTRACT. ***Objective.*** As therapy for rheumatoid arthritis (RA) becomes more effective, more sensitive imaging methods are required to assess disease activity and joint damage. We compared magnetic resonance imaging (MRI), sonography, and radiography for assessment of disease activity for the detection of bony erosions.

Methods. Forty-six patients with newly diagnosed RA (onset within 2 years) received clinical and laboratory assessment followed by radiographs, sonography, and MRI of the right hand at baseline and at 6 months according to a standardized protocol. We determined the presence of edema, synovitis, effusions, tendon fluid, tendon thickening, and size in the same way by MRI and sonography. The intra- and interreader reliability of MRI and radiographs and predictors of MRI erosions at 6 month followup were also examined.

Results. At baseline, 39 (85%), 14 (30%), and 17 (37%) patients had erosions identified on MRI, sonography, and radiography, respectively. Over time, the percentage of patients with erosions increased to 91% for MRI, 41% for sonography, and 48% for radiography. The absolute number of erosions increased from 177 to 239 erosions for MRI, from 30 to 43 for sonography, and from 38 to 73 for radiographs. The intra- and interreader reliability for the assessment of erosions and synovitis on MRI was acceptable (intrareader ICC of 0.60 and 0.90; interreader ICC of 0.77 and 0.89, respectively).

Conclusion. MRI appears to be the most sensitive modality for erosive disease compared with sonography and radiography. Sonography detected more joint and tendon sheath effusions than MRI in this study and therefore may have a role in the assessment of disease activity. (J Rheumatol 2004;31:663–75)

Key Indexing Terms:
RHEUMATOID ARTHRITIS MAGNETIC RESONANCE IMAGING
SONOGRAPHY RADIOGRAPHY HAND

From the Department of Clinical Epidemiology, Department of Radiology, Department of Medical Imaging and Radiation Sciences, Department of Epidemiology and Preventive Medicine, Monash University, Melbourne; Cabrini Hospital; Melbourne Institute of Rehabilitation Research, University of Melbourne, Melbourne; Mercy Private Hospital, Melbourne; and Rheumatology Department, St. George Hospital, Sydney, Australia.

J. Hoving, PhD Postdoctoral Fellow; R. Buchbinder, MBBS (Hons), MSc, FRACP, Associate Professor, Director, Department of Clinical Epidemiology, Cabrini Hospital and Monash University Department of Epidemiology and Preventive Medicine; S. Hall, MBBS (Hons), FRACP, Associate Professor of Medicine, Monash University, Senior Research Fellow, Institute of Rehabilitation Research, University of Melbourne; G. Lawler, MBBS, FRANZCR, FRCR, Radiologist; D. Connell, MBBS (Hons) MMed, FRANZCR, Radiologist, Department of Radiology, Cabrini Hospital; P. Coombs, Dip App Sc, BA, Grad Dip US, Senior Lecturer, Department of Medical Imaging and Radiation Sciences, Monash University; S. McNealy, Dip App Sc, Grad Dip US, MIA, Mercy Private Hospital; P. Bird, BMed (Hons), FRACP, Grad Cert, MRI, Conjoint Lecturer, University of NSW, Rheumatology Department, St. George Hospital, Sydney.

Address reprint requests to Dr. R. Buchbinder, Department of Clinical Epidemiology, Suite 41, Cabrini Medical Centre, 183 Wattletree Road, Malvern, Victoria, Australia 3144.
E-mail: rachelle.buchinder@med.monash.edu.au

Submitted December 4, 2002; revision accepted August 11, 2003

As the treatment paradigm in rheumatoid arthritis (RA) shifts toward early and aggressive therapy to retard and prevent the development of joint damage[1], more sensitive imaging techniques are needed to evaluate the effectiveness of early therapy. Ideally, these newer techniques should be capable of detecting early changes and should be sensitive to change in longitudinal studies.

The putative advantages of magnetic resonance imaging (MRI) compared with traditional radiological outcome measures are well documented. First, MRI permits qualitative and quantitative assessment of synovitis[2-4] and documents the response of the inflammatory process to therapeutic intervention[5,6]. Second, MRI is more sensitive than radiographs in detecting bony erosions with changes occurring much earlier than those seen on radiographs[7-9]. Additionally, bone edema can be assessed and this may be another predictor of impending bony damage[10]. Finally, MRI allows the assessment of soft tissue structures such as tendons and ligaments that may be involved as part of the inflammatory process and have been incorporated as part of MRI activity scores[11,12].

Personal, non-commercial use only. The Journal of Rheumatology Copyright © 2004. All rights reserved.

Downloaded on April 18, 2024 from www.jrheum.org

More recently, sonography has been introduced as a promising alternative to radiography and an adjunct to MRI, especially in the assessment of extraarticular structures[13]. Sonography detects more joint damage than radiography and is sensitive to synovitis in early RA[14]. Further, it is an accessible, operator-dependent imaging modality, and the advent of smaller high frequency transducers has resulted in improved image resolution that can be applied to the small joints of the hand[9,15].

We evaluated MRI and sonography in the detection of synovitis and tendon involvement in patients with early RA. Additionally, we evaluated both modalities in the detection of bony erosions and compared the results to radiographs.

MATERIALS AND METHODS

Recruitment and selection criteria. Between 1999 and 2000, 46 consecutive patients with early RA were recruited from 2 private rheumatology practices in Melbourne, Australia. Inclusion criteria were as follows: age 18 years or older, fulfilled revised American College of Rheumatology criteria for the diagnosis of RA[16], and disease duration < 2 years. Patients were excluded for the following reasons: (planned) pregnancy in the 6 months of the study, and contraindications to MRI. The Cabrini Health Ethics Committee approved the study. Patients continued their current therapy as prescribed by their treating doctors.

Baseline data include date of birth, sex, years of formal education, marital status, employment, type of work, duration of symptoms, and current and past medication. A blood sample was taken for rheumatoid factor (RF) at baseline and C-reactive protein at baseline and at 6 months.

Clinical outcome measures. At baseline and 6 months patients completed a standardized self-administered questionnaire. Patients were asked to rate their current level of disease activity on a 0–10 point rating scale (0 = no symptoms, 10 = severe symptoms), current level of pain on a 0–10 point rating scale (0 = no pain, 10 = most severe pain), and duration of morning stiffness. Functional status was measured according to the Health Assessment Questionnaire[17] (HAQ) and hand function was assessed using the Hand Functional Disability Scale[18].

At baseline and 6 months a standardized clinical examination included a 28 point tender and swollen joint count, and the physician-rated global assessment of current level of disease activity on a 0–10 point rating scale (0 = no disease activity, 10 = most severe disease activity). Hand function was also measured using the hand and wrist component of the Keitel Index[19]. All examinations were performed by a single rheumatologist (SH).

All patients had MRI, sonography, and radiographs of their right wrist, metacarpophalangeal (MCP) and proximal interphalangeal (PIP) joints at baseline and 6 months. All clinical, radiological, and laboratory examinations were performed on the same day.

MRI and assessment. The following MR sequences were performed: (1) A T1 weighted fat-saturation 3D spoiled gradient-echo acquisition to evaluate articular cartilage (45 partitions). TR/TE 60/10; flip angle 55°; field of view (FOV) 10 cm; 1 mm slice thickness; 256 × 256 matrix; 1 NEX. (2) Coronal FSE image with fat-saturation to assess for bone and soft tissue edema. TR/TE 4000/35; FOV 10–18 cm; two NEX; bandwidth 31.3 kHz; ETL 8–10; slice thickness 2 mm with no interslice gap; matrix 512 × 256. (3) Gadolinium-enhanced MRI of the wrist to assess synovial and tendon sheath enhancement by injecting a bolus of 30 ml contrast (gadolinium dose 0.2 mmol/kg, infusion rate 1 ml/s) in a peripheral vein of the dorsal aspect of the wrist (236 cannula). The parameters included a 3D-SPGR, fast, EDR, VBW, no phase wrap, 30° flip angle with minimal TE. FOV was 15 cm and slice thickness 0.7 mm. Phase encoding steps number 160 with a frequency of 256. (4) Postcontrast axial T1 weighted image to evaluate tendons, tendon sheaths, and ligaments. TR/TE 600/12; FOV 12 cm; matrix 512 × 256; bandwidth 31.3 kHz; 2 NEX; ETL 8–10; slice thickness 4 mm with no interslice gap.

Two radiologists (DC and GL) independently read the MRI according to a standardized protocol without knowledge of the clinical status of the patient. One radiologist (DC) was experienced in reading MRI of RA and the other radiologist (GL) underwent specific training for the study by interpreting 50 examinations (RA images of the hand) under supervision. The experienced radiologist independently, and in a blinded fashion, read the baseline MRI twice in random order to determine intrareader reliability (interval 3 weeks).

A modification of the classification system used by McQueen and the OMERACT group was used to score the MRI static postcontrast images (Table 1)[20,21]. The OMERACT scoring system was developed by experts in the field to set provisional recommendations for MRI evaluation of RA in the hand and the wrist[21]; however, its feasibility and reliability had not been formally tested at the start of our study. On the other hand, the extensive work by McQueen, *et al* showed that their MRI rating scale for the wrist was feasible and had acceptable reliability[20]. The participating radiologists in our study chose the relevant, feasible, and easy to use items from each rating system. In addition, our rating system included the PIP joints and extensive imaging of the tendons (See Appendix 1 for a summary of the OMERACT and McQueen systems).

Table 1 summarizes the MRI abnormalities that were included in the scoring. Thirty-five regions were examined for the presence of bone erosions and bone edema: the distal radius and distal ulna (ulnar styloid; 2 sites), the carpi (8 sites: trapezium, trapezoid, capitate, hamate, scaphoid,

Table 1. MRI, sonography, and plain radiograph scoring system.

Imaging Endpoints	MRI	Sonography	Plain Radiograph	No. of Sites	Scoring, range	Possible Range
Erosions	X	X	X	35	Overall number of erosions	0–∞
					Presence or absence of erosion/s at each site	0–35
Bone edema (volume)	X	X		35	0 to 10	0–350
Synovitis	X	X		17	0 = < 1mm, 1 = 1mm, 2 = 2mm, 3 = ≥ 3mm	0–51
Effusions	X	X		17	0 = none, 1 = mild, 2 = moderate, 3 = gross	0–51
Tendons						
Fluid in tendon sheath	X	X		9	0 = none, 1 = mild, 2 = moderate, 3 = gross	0–27
Tendon sheath thickening	X	X		9	0 = < 1mm, 1 = 1mm, 2 = 2mm, 3 = ≥ 3mm	0–27
Tendon size	X	X		9	0 = normal, 1 = thickened, 2 = attenuated, 3 = absent/ruptured	0–27
Total tendon score	X	X		3×9	Sum of sheath fluid, thickening, and tendon size	0–81
Joint space (modified Sharp)			X	17	0 = normal, 1 = focal narrowing, 2 = < 50% original joint space, 3 = > 50% original joint space, 4 = collapse/ankylosis	0–68

Personal, non-commercial use only. The Journal of Rheumatology Copyright © 2004. All rights reserved.

Downloaded on April 18, 2024 from www.jrheum.org

lunate, triquetral, and pisoform), the metacarpal heads and bases (10 sites), the proximal and distal surfaces of the proximal phalanx (10 sites), and the proximal surfaces of the middle phalanx (5 sites). Bone erosions were scored in 2 ways — all erosions identified at each of the 35 sites were included in an overall score (score range 0–∞) and the presence (+1) or absence (+0) of erosion/s at each site was summed into a score (score range 0–35). The median number (range) of erosions in those participants with at least one erosion was also calculated. The presence of bone edema was scored on a numerical rating scale of 0–10 for each of the 35 sites (score range 0–350)[21].

Seventeen sites were scored for the presence of synovitis and effusions: the distal radio-ulnar joint, piso-triquetral joint, the carpometacarpal joints (CMC; 5 sites), the MCP joints (5 sites), and the PIP joints (5 sites). The extent of synovitis and effusion at each of the 17 sites was scored on 4 point scales (for synovitis, 0 = < 1 mm, 1 = 1 mm, 2 = 2 mm, 3 = ≥ 3 mm; for effusion, 0 = none, 1 = mild, 2 = moderate, and 3 = gross; score range 0–51).

Three tendon abnormalities were scored, including the presence of fluid (0 = none, 1 = mild, 2 = moderate, 3 = gross), thickening of the tendon sheath (0 = ≤ 1 mm, 1 = 1 mm, 2 = 2 mm, 3 = ≥ 3 mm), and tendon size (0 = normal, 1 = thickened, 2 = attenuated, 3 = absent/ruptured). The 9 assessed sites were extensor pollicis brevis (EPB) and abductor pollicis longus (APL); extensor carpi radialis brevis and longus (ECRB, ECRL); extensor pollicis longus (EPL); extensor digitorum (ED); extensor digiti minimi (EDM); extensor carpi ulnaris (ECU); flexor digiti profundus and superficialis (FDP, FDS); flexor carpi ulnaris (FCU); and flexor carpi radialis (FCR). The extent of abnormality at each of the 9 sites scored on 4 point scales (0–3) ranged from 0 to 27 (Table 1). A total tendon score was also calculated by summing the 3 tendon abnormality scores (total tendon score range 0–81).

Sonographic assessment. Sonography was performed by 2 trained musculoskeletal sonographers (PC, SMc) using current ultrasound systems (HD1 5000® Philips ATL, Sequioa®, Acuson, Mountain View, CA, USA). Small footprint, high frequency transducers were used (10 MHz). Findings were recorded on a data collection sheet by consensus. A screening method was adopted requiring a large amount of data to be acquired in a reasonable examination time (average examination time = 28 min). All joints were examined to full flexion and extension to ensure maximum cortical visualization. Dorsal and volar aspects of the joint were considered. Areas of abnormality were further examined with color-flow imaging to assess for increased vascularity. The ultrasound data recorded for this study corresponded with the MR imaging classification system used.

Radiograph assessment. The same 2 experienced radiologists (DC, GL) independently read the radiographs. Erosions at 35 sites were scored as for MRI (Table 1). The modified Sharp/van der Heijde method[22] was used to assess joint space at 17 joints (PIP 1–5, MCP 1–5, distal radio-ulnar joint, radiocarpal, ulnar carpal, intercarpal, CMC 1, CMC 2–5, piso-triquetral). Joint space was assessed at each of the 17 sites on a 5 point rating scale (0 = normal, 1 = focal, 2 = < 50% joint space, 3 = > 50% joint space, 4 = collapse/ankylosis; score range 0–68).

Statistical analyses. The intra- and interreader reliability of MRI and radiographic findings at baseline was examined using random effects intraclass correlation coefficients (ICC) and their 95% confidence intervals (CI) for continuous variables with normal distribution (only erosions and joint space narrowing)[23]. In those cases where the data were severely skewed we dichotomized the pathology as either "present" or "absent" and report percentage agreement and kappa statistics instead[24]. For the MRI and radiographic findings, we present the scores of the most experienced radiologist (DC). Differences in the patient characteristics, clinical assessments, and imaging results between baseline and 6 month followup were analyzed using T tests, Wilcoxon signed-rank tests, and chi-square tests.

The degree of correlation between MRI, radiographs, and clinical features was explored using Spearman's correlation coefficients. Using univariate analyses we identified any possible factors at baseline that predicted an unfavorable outcome of MRI findings at 6 months (statistical software SPSS v. 10.0). Any factors that were significant at the $p < 0.05$ level were included in a multivariate analysis. In addition, we included MRI bone edema in the multivariate analysis, although it did not appear to be significant in our univariate analysis, as this factor has been suggested to be predictive in other studies[11].

RESULTS

The demographic and clinical details of the 46 patients at baseline and 6 months are shown in Table 2. The median age was 58 years, about 70% were women, the median duration of RA symptoms was 26 weeks, and 71% had a positive RF. At baseline, 30% of the patients were taking nonsteroidal antiinflammatory drugs (NSAID), 48% were taking prednisolone, and 61% were taking disease modifying antirheumatic drugs (DMARD). During the course of 6 months, use of these medications remained largely unchanged, with a nonsignificant increase in the number of patients taking NSAID and DMARD. Apart from the HAQ score, all patient and physician-assessed variables improved over the 6 months of the study.

Baseline MRI, sonography, and radiographic findings. At baseline, 39 patients (85%) had one or more erosions at one or more bony sites of the hand or wrist detected by MRI (Table 3). In these 39 patients, 177 erosions distributed over

Table 2. Demographic and clinical characteristics at baseline and 6 month followup (n = 46).

	Baseline, n (%) or median (IQR)	6 Months, n (%) or median (IQR)
Age, yrs	58 (44–69)	—
Female	32 (69.6)	—
Symptom duration, weeks	26 (10–47)	—
Education: tertiary or higher	16 (35.6)	—
NSAID	14 (30.4)	20 (43.5)
Prednisolone	22 (47.8)	20 (43.5)
DMARD	28 (60.9)	31 (67.4)
Methotrexate	10 (43.5)	23 (50.0)
Salazopryine	6 (13.0)	9 (19.6)
Intramuscular gold	0	4 (8.7)
Plaquenil	7 (15.2)	8 (17.4)
Rheumatoid factor	26 (0–103.3)	—
C-reactive protein (≥ 10)	10 (21.7)	9 (14.0)
Patient global assessment of disease activity (0–10)	4.0 (2.0–5.0)	3.0 (1.0–5.0)
Patient pain assessment (0–10)	3.0 (1.0–4.3)	2.0 (1.0–4.0)
Duration early morning stiffness, min	15.0 (0–60.0)	10.0 (0–45.0)
HAQ score (0–3)	0.63 (0.22–1.0)	0.68 (0.09–1.0)*
Hand Functional Disability Scale (0–54)	6.0 (1.8–12.5)	2.0 (0–13.5)
Physician global assessment of disease activity (0–10)	3.0 (1.0–4.0)	1.0 (0–3.0)*
Modified Keitel Index (hand index: 0–21)	6.0 (2.8–10.3)	3.5 (2.0–6.0)*
Tender joint count (0–11)	3.5 (0.8–5.0)	1.0 (0–4.0)*
Swollen joint count (0–11)	1.5 (0–5.0)	1.0 (0–3.0)

* $p \leq 0.05$ comparison of baseline to 6 months.

Personal, non-commercial use only. The Journal of Rheumatology Copyright © 2004. All rights reserved.

Downloaded on April 18, 2024 from www.jrheum.org

Table 3. Number and percentage of patients with abnormal findings and total sum of abnormal findings identified at baseline and 6 months.

Imaging Endpoints	MRI		Sonography		Radiography	
	Baseline, N = 46	6 Months, N = 46	Baseline, N = 46	6 Months, N = 46	Baseline, N = 46	6 Months, N = 46
Joint space						
No. participants (%) modified Sharp score > 0	—	—	—	—	24 (52.2)	24 (52.2)
Number joints, abnormal joint space	—	—	—	—	70	89
Median (range) modified Sharp score, for those with modified Sharp score > 0	—	—	—	—	5 (1–19)	8 (1–22)
Erosions						
No. participants (%) with erosions	39 (84.8)	42 (91.3)	14 (30.4)	19 (41.3)	17 (37.0)	22 (47.8)
Overall number of erosions	177	239	30	43	38	73
Median (range) for those with ≥ 1 erosion	4 (1–11)	55 (1–12)	1 (1–8)	1 (1–6)	2 (1–5)	3 (1–8)
Median (range) of sites for those with ≥ 1 erosion (1–35)	5 (1–12)	6 (1–15)	2 (1–13)	2 (1–9)	2 (1–8)	3 (1–11)
Bone edema						
No. of participants (%) with bone edema	12 (26.1)	11 (23.9)	—	—	—	—
Median sites (range) for those with ≥ 1 involved site (1–35)	1.5 (1–4)	2 (1–5)	—	—	—	—
Median (range) bone edema score for those with ≥ 1 involved site (1–350)	7.5 (2–29)	8 (3–34)	—	—	—	—
Synovitis						
No. of participants (%) with synovitis	33 (71.7)	33 (71.7)	25 (54.3)	39 (84.4)	—	—
Median sites (range) for those with ≥ 1 involved site (1–17)	5 (1–17)	5 (1–15)	3 (1–11)	5 (1–12)	—	—
Median (range) synovitis score for those with ≥ 1 involved site (1–51)	12 (2–51)	15 (2–45)	4 (1–22)	5 (1–18)	—	—
Joint effusions						
No. of participants (%) with joint effusions	2 (4.3)	6 (13.0)	28 (60.9)	38 (82.6)	—	—
Median sites (range) for those with ≥ 1 involved site (1–17)	3 (1–5)	1 (1–1)	6 (1–12)	8 (2–12)	—	—
Median (range) joint effusion score for those with ≥ 1 joint effusion (1–51)	8.5 (2–15)	3 (2–3)	7 (1–15)	9 (2–17)	—	—
Tendons						
Tendon sheath effusion						
No. participants (%) with tendon sheath effusion	2 (4.3)	1 (2.2)	9 (19.6)	15 (32.6)	—	—
Median sites (range) for those with ≥ 1 tendon sheath effusion (1–9)	2 (1–3)	1 (1–1)	1 (1–2)	1 (1–3)	—	—
Median (range) tendon effusion score for those with ≥ 1 tendon sheath effusion (1–27)	2 (1–3)	3 (3–3)	1 (1–3)	1 (1–3)	—	—
Tendon sheath thickening						
No. participants (%) with tendon sheath thickening	30 (65.2)	31 (67.4)	16 (34.8)	25 (54.3)	—	—
Median sites (range) for those with ≥ 1 tendon sheath thickening (1–9)	2 (1–9)	2 (1–9)	2 (1–5)	2 (1–5)	—	—
Median (range) tendon sheath thickening score for those with ≥ 1 thickened tendon (1–51)	3 (1–27)	3 (1–19)	2 (1–10)	2 (1–11)	—	—
Tendon thickening						
No. participants (%) with tendon thickening	8 (17.4)	13 (28.3)	6 (13.0)	7 (15.2)	—	—
Median sites (range) for those with ≥ 1 tendon thickened (1–9)	1 (1–7)	1 (1–2)	1 (1–4)	1 (1–4)	—	—
Median (range) tendon thickening score for those with ≥ 1 tendon thickened (1–51)	1 (1–16)	2 (1–2)	1.5 (1–7)	1 (1–7)	—	—
Overall tendon abnormality						
Overall number of participants (%) with a tendon abnormality	31 (67.4)	31 (67.4)	18 (39.1)	31 (67.4)	—	—
Median (range) overall tendon score for those with ≥ 1 tendon abnormality (1–81)	4 (1–29)	4 (1–20)	2 (1–19)	2 (1–21)	—	—

the 35 examined sites were identified. The median number of erosions in those with ≥ 1 erosion at baseline was 4 (range 1–11). By contrast, only 17 patients (37.0%) were found to have erosions at baseline on plain radiographs (median 2, range 1–5). In these 17 patients, 38 erosions were distributed over the 35 examined sites. Twenty-four patients (52.2%) had some degree of joint space narrowing. For sonography, 14 patients (30.4%) were found to have one or more erosions (median 1, range 1–8), and a total of 30 erosions at baseline.

Figure 1 shows the most frequent sites of erosions identified by MRI including the heads of the metacarpals (65%) the capitate (41%), bases of the metacarpals (30%), triquetral (26%), and scaphoid (22%) (shown in Figure 2). No erosions were found in the pisiform or distal radius. Erosions anywhere in the phalanges (proximal or distal end

Personal, non-commercial use only. The Journal of Rheumatology Copyright © 2004. All rights reserved.

Downloaded on April 18, 2024 from www.jrheum.org

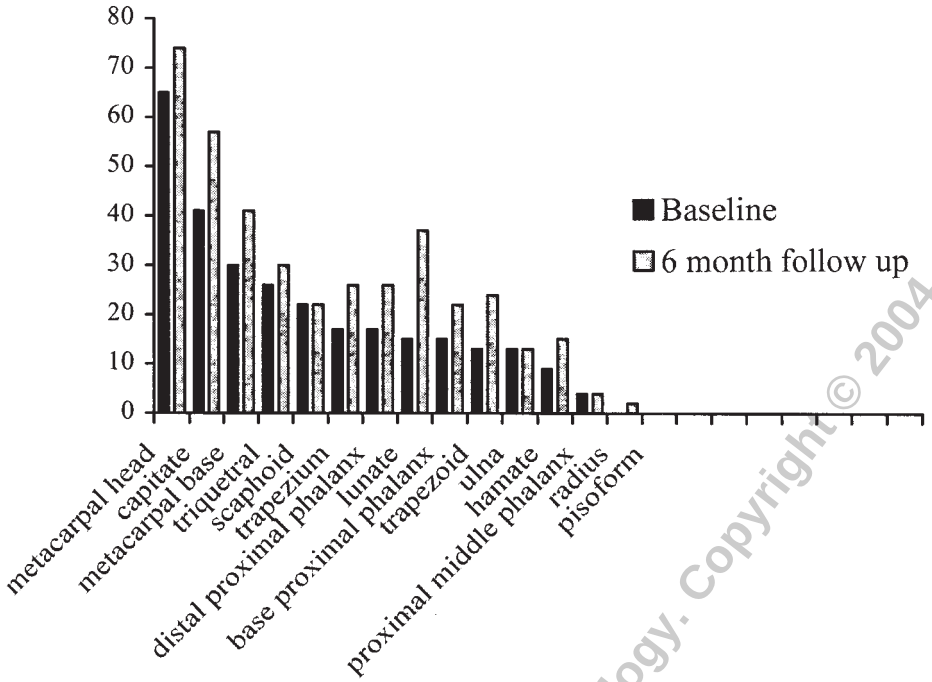

Figure 1. Location of MRI erosions at baseline and at 6 months (%).

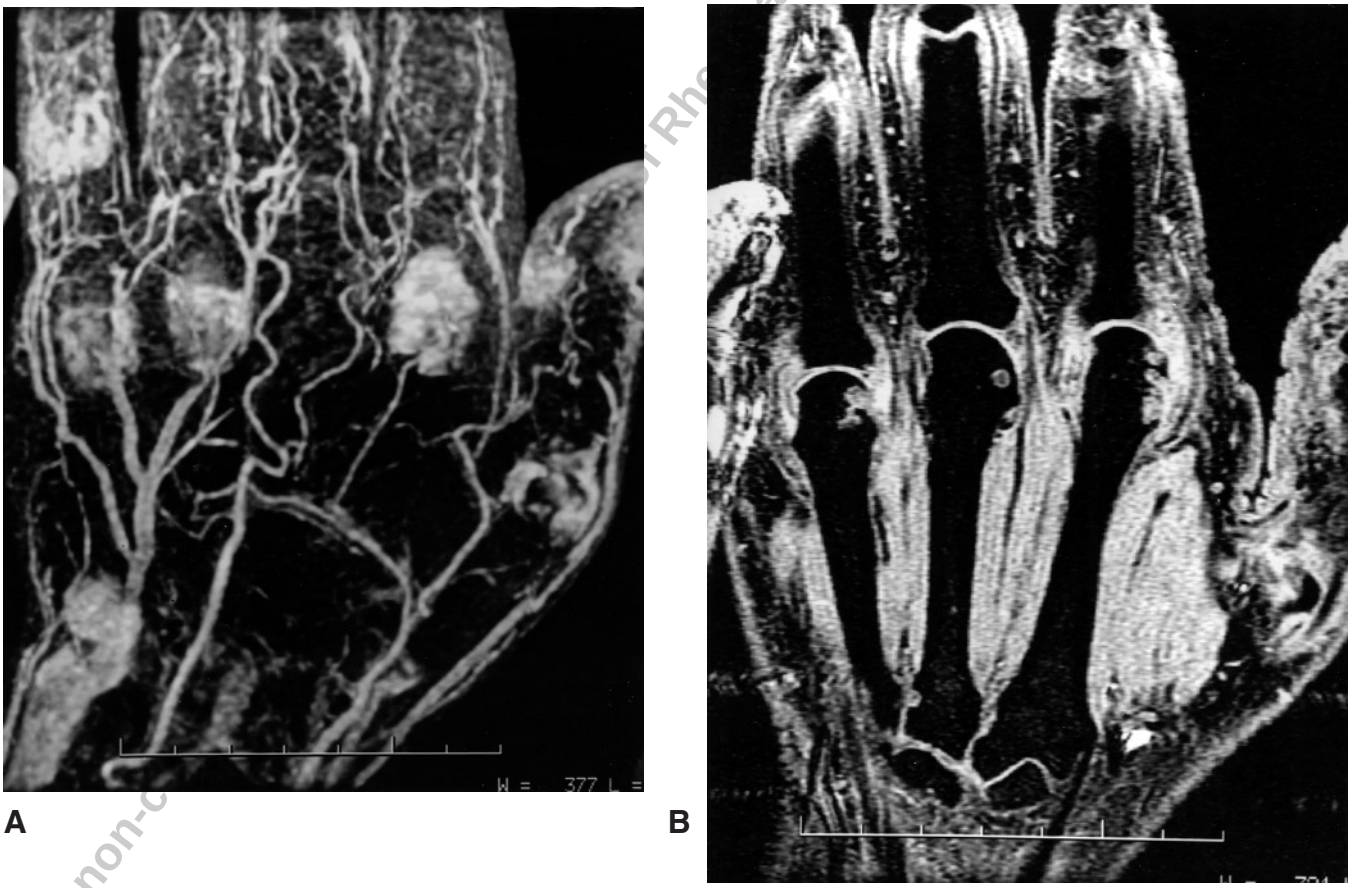

Figure 2. A 53-year-old man with early RA. A. A maximum intensity projection image shows synovial disease affecting the 1st, 2nd, 4th, and 5th MCP joints and PIP joints. Note the vivid enhancement of the tendon sheath of extensor carpi ulnaris. B. A coronal gradient-echo cartilage sequence reveals cortical breakdown and erosions on the radial sides of the 2nd and 4th metacarpal heads. Note the subcortical cyst in the head of the 3rd metacarpal, although the cortical margin is intact. The articular cartilage surface remains preserved.

Personal, non-commercial use only. The Journal of Rheumatology Copyright © 2004. All rights reserved.

Downloaded on April 18, 2024 from www.jrheum.org

of the proximal phalanx or base of the middle phalanx) were found in 28% of patients. Other prevalent findings detected by MRI at baseline were synovitis (33 patients, 71.7%), tendon sheath thickening (30 patients, 65.2%), and bone edema (12 patients, 26.1%) (Figures 3–5). Sonography detected more joint and tendon sheath effusions than MRI (Figure 6). For example, at baseline 2 patients (4.3%) had joint effusions on MRI compared to 28 patients (60.9%) on sonography. When MRI or sonography detected synovitis, synovial thickening was universally greater than 3 mm.

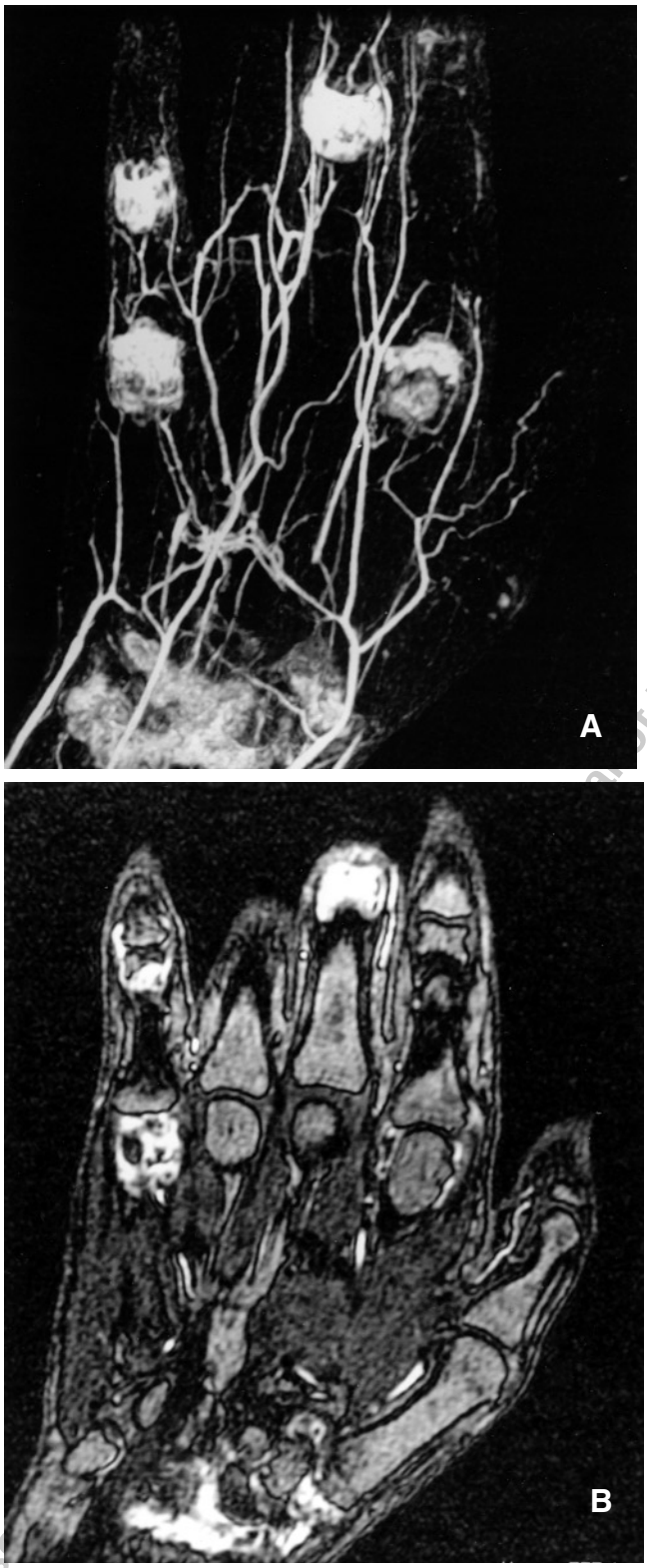

6-month MRI, sonography, and radiographic findings. At 6 months, the number of patients with erosions detected by MRI, ultrasound, and radiography increased from 39 to 42 (84.8% to 91.3%), from 14 to 19 (30.4% to 41.3%), and from 17 to 22 (37% to 47.8%), respectively (Table 3). The absolute number of erosions increased from 177 to 239 erosions at 6 months for MRI (median number of erosions in those with ≥ 1 erosion was 5.5, range 1–12), from 30 to 43 erosions at 6 months for sonography (median number of erosions in those with ≥ 1 erosion was 1, range 1–6), and from 38 to 73 erosions for radiography (median number of erosions in those with ≥ 1 erosion was 3, range 1–8).

Table 4 compares the number of erosions identified by MRI to those identified by radiography and sonography. At baseline, 23/39 patients (59.0%) were found to have erosions on MRI not detected by plain radiographs and 26/39 (66.7%) of these patients did not have erosions detected by ultrasound. On the other hand, only one patient was found to have erosions on plain radiograph that were not detected by MRI (1/17, 5.9%) and one patient was found to have erosions by ultrasound not detected by MRI (1/14, 7.1%). On review of these 2 cases, the erosion detected by plain radiograph was thought to be just a cortical defect on MRI and the erosion detected by sonography lay on the edge of the coronal plane and was missed by MRI. At 6 months, a similar number of patients were found to have erosions on MRI that were not detected by plain radiographs (22/42 patients, 52.4%) or by ultrasound (23/42, 52.4%). Finally, 2/22 patients (9.1%) had erosions on plain radiographs that were not detected by MRI. Both erosions were missed on MRI, one because of marked degradation of MRI image quality because of motion, and the other erosion lay on the edge of the coronal plane.

Intra- and interreader reliability of MRI and plain radiographs. The intrareader reliability for presence of erosions and synovitis on MRI at baseline was ICC = 0.90 (95% CI 0.82, 0.95) and 0.77 (95% CI 0.80, 0.94), respectively. The interreader reliability for presence of erosions and synovitis scored on MRI was ICC = 0.60 (95% CI 0.37, 0.75) and 0.77 (95% CI 0.62, 0.87), respectively. The interreader reli-

Figure 3. A 43-year-old woman with early onset RA. A. A partition image from the MR angiogram shows synovial thickening and enhancement of the 5th MCP joint and the 3rd and 5th PIP joints. Synovial thickening and enhancement is also seen around the radiocarpal and 1st carpometacarpal joints. Forty-five of these partition images sum to produce a maximum intensity projection image. B. Maximum intensity projection image from the same patient provides a simple but effective illustration of the synovial disease in the carpal, metacarpal, and interphalangeal joints.

Personal, non-commercial use only. The Journal of Rheumatology Copyright © 2004. All rights reserved.

Downloaded on April 18, 2024 from www.jrheum.org

ability for presence of erosions by radiograph at baseline was 0.86 (95% CI 0.75, 0.92) and the interreader reliability of the assessment of joint space by radiograph according to the modified Sharp score was ICC = 0.91 (95% CI 0.85, 0.95).

Percentage agreement for determining presence or absence of erosions at baseline on MRI and plain radiographs was 89.1% and 95.7%, respectively (erosions as either "present" or "absent" for each patient). The corresponding kappa scores were 0.55 and 0.91, respectively. The percentage agreement and kappa scores for joint space by radiography according to the modified Sharp score were 95.7% and 0.91, respectively. For other abnormalities detected on MRI the percentage agreement and kappa scores were as follows: bone edema 71.8%, 0.38; synovitis 87.0%, 0.66; effusions 19.5%, 0.02; tendon sheath fluid 28.2%, 0.03; tendon sheath thickening 37.0%, 0.02; and tendon thickening 80.4%, 0.28.

Predictors of erosion progression on MRI. Overall, the correlations for the baseline imaging endpoints (using MRI, radiography, and sonography) were fairly similar between the erosions identified by MRI at baseline and at 6 month followup (Table 5). The imaging parameters most strongly correlated ($p < 0.05$) with erosion identified by MRI at baseline and 6 months were: erosions (MRI 6 mo: $r = 0.57$, $p < 0.001$); synovitis (MRI baseline: $r = 0.52$, $p < 0.001$ and 6 mo: $r = 0.41$, $p = 0.004$); tendon sheath thickening (MRI: $r = 0.48$, $p = 0.001$ and $r = 0.30$, $p = 0.04$); erosions identified on plain radiograph ($r = 0.40$, $p = 0.005$ and $r = 0.41$, $p = 0.005$); and joint space (radiography: modified Sharp score, $r = 0.36$, $p = 0.01$ and $r = 0.44$, $p = 0.002$). The other baseline imaging variables, including bone edema identified by MRI, were not associated with MRI erosions at 6 months.

Univariate analyses (linear regression) indicated that significant imaging baseline predictors of erosions at 6 months were: erosions identified by MRI (beta = 0.63, $p < 0.001$); synovitis (beta = 0.29, $p = 0.009$); erosions identified by radiography (beta = 0.68, $p = 0.04$); and the modified Sharp score (beta = 0.62, $p = 0.006$; Table 5). Combining more imaging endpoints, including the (strongest) predictor "MRI erosions at baseline," in one (multivariate) model did not significantly improve the explained variance (r^2 with only MRI erosions was 0.36, and including the second strongest predictor "radiographic erosions" increased r^2 only marginally to 0.41).

A

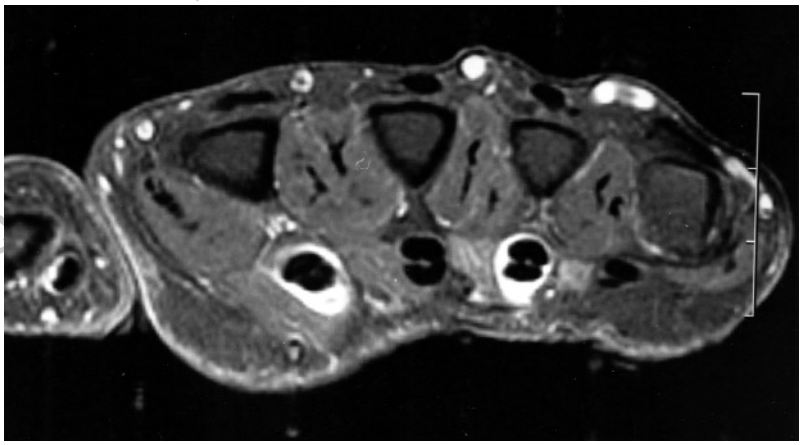

B

Figure 4. A 29-year-old woman with early onset RA. A. Maximum intensity projection image shows tendon sheath enhancement of the flexor pollicis longus tendon and the flexor tendons to the 2nd, 3rd, 4th, and 5th digits. B. Axial T1 weighted fat-suppressed imaging in the same patient shows thickening and enhancement of the tendon sheaths of the 1st, 2nd, and 4th flexors.

Personal, non-commercial use only. The Journal of Rheumatology Copyright © 2004. All rights reserved.

Downloaded on April 18, 2024 from www.jrheum.org

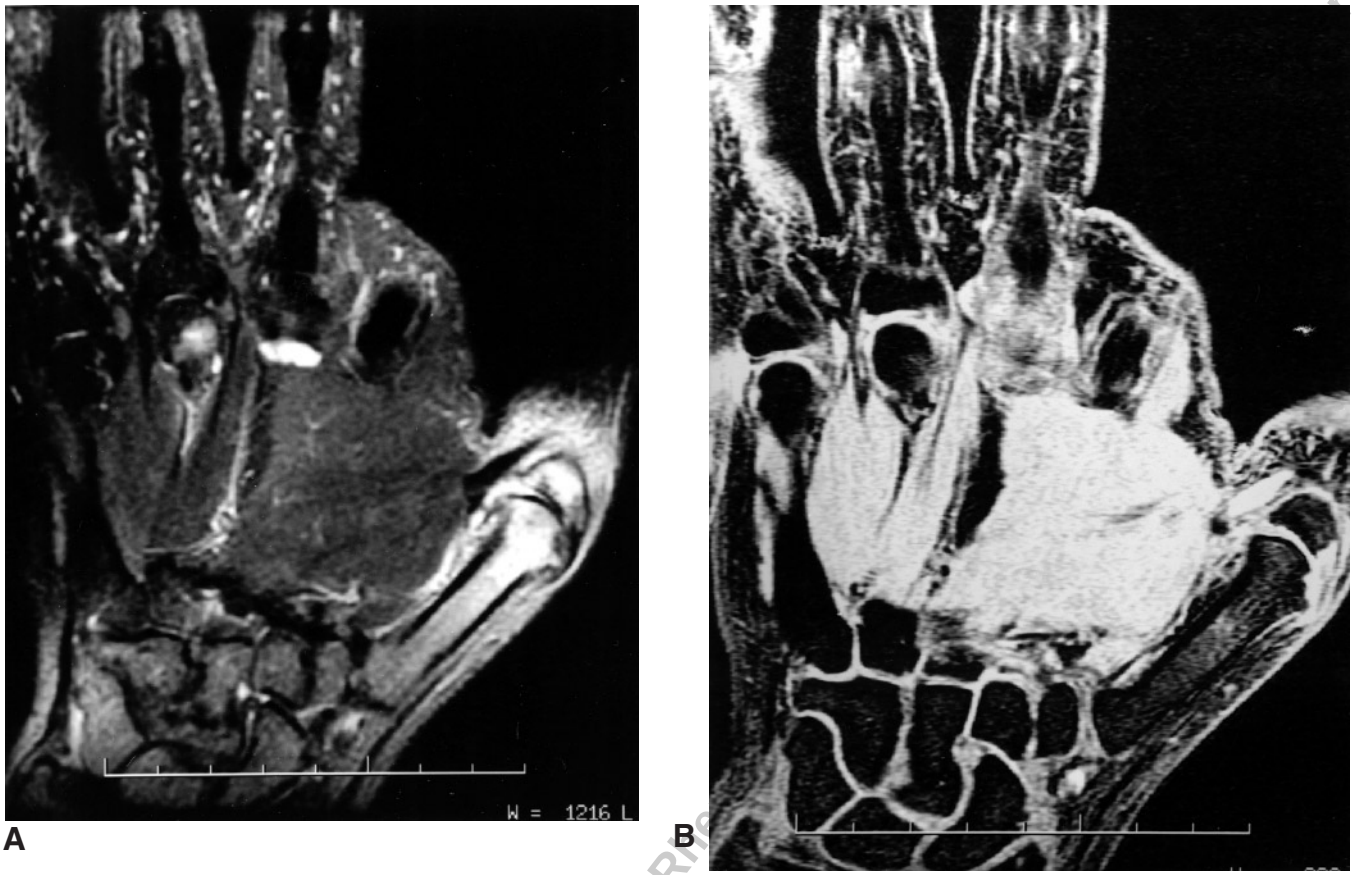

Figure 5. A 48-year-old woman with early RA. A. Marked T2 hyperintensity seen at the base of the 1st proximal phalanx and the head of the 1st metacarpal compatible with bone edema. Hyperintensity of the surrounding soft tissue is visible. There is also a focus of bone edema in the 4th metacarpal head. B. Coronal gradient-echo cartilage sequence shows a radial sided erosion in the head of the 1st metacarpal and an adjacent erosion in the base of the proximal phalanx.

Of the non-imaging baseline variables, age, CRP, and all physician-measured outcomes were significantly ($p < 0.05$) associated with MRI erosions at 6 months (data not shown). Age (median ≥ 58 yrs) and tender joint count (median tender joint count > 3) were the most important predictors ($r^2 = 0.25$) in a multivariate model (model 3.03 + 2.61 * age ≥ 58 yrs + 1.95 * joint count > 3). The magnitude of the explained variance was modest ($r^2 = 0.25$) compared to that of the imaging endpoints ($r^2 = 0.36$).

DISCUSSION

This prospective study of a cohort of patients with early RA compares 3 different imaging techniques at baseline and 6 months. The interreader reliability of 2 radiologists and intrareader reliability of one radiologist for each of the 3 imaging methods was also assessed. MRI was the most sensitive imaging modality for detection of bony erosions, identifying more than twice as many erosions as sonography and radiography. Sonography was the least sensitive method for damage assessment, detecting slightly fewer erosions than radiography. MRI was more sensitive for detecting synovial disease than sonography and the only modality able to detect bone edema. Sonography was more sensitive to joint effusion and tendon sheath inflammation compared to MRI.

MRI — bone damage detection. Other studies have shown that MRI is more sensitive than radiographs for detecting erosions[9,20,25-27]. However, in designing this study, we selected a sequence that had previously been shown to identify chondral lesions in the knee with good arthroscopic correlation[28]. This cartilage-sensitive sequence was modified in order to detect small and early erosions. Our slice thickness of 1 mm compares favorably to other studies[20] that selected slices of < 3 mm and sequences shown to be unreliable for chondral lesions. This approach probably resulted in increased detection of cortical defects (84%–91%) compared to the study by McQueen, *et al* (45%–74%)[25]. It is likely that not all of these defects were erosions. Small breaches of cortical bone may be present in normal individuals, some of which may be due to nutrient vessels or interosseous entheses. Cortical defects are commonly seen in the capital, hamate, and base of the 2nd metacarpal bones, and may be due to perforating nutrient vessels. Discriminating these normal findings from erosions may be

Personal, non-commercial use only. The Journal of Rheumatology Copyright © 2004. All rights reserved.

Downloaded on April 18, 2024 from www.jrheum.org

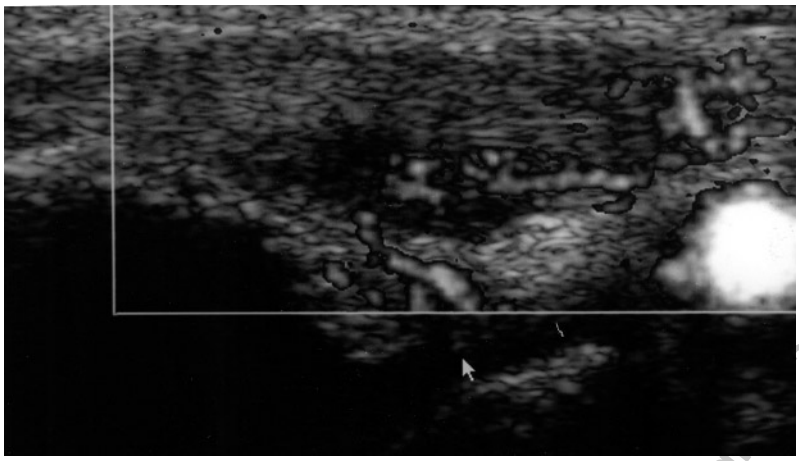

A

B

Figure 6. A 52-year-old man with early RA. A. Sonogram shows synovial thickening around the 3rd MCP joint. Color Doppler imaging shows neovascularization of the area of synovial thickening. The adjacent tendon sheath also shows neovascularity. B. Corresponding coronal gradient-echo cartilage sequence shows an early erosion forming at the head of the 3rd metacarpal with cortical breach and reactive bony change.

Table 4A. Comparison of erosions detected by MRI and plain radiograph at baseline and 6 months.

Radiography	MRI Erosions	MRI No Erosions	Total, n (%)
Baseline			
Erosions	16	1	17
No erosions	23	6	29
Total	39	7	46
6 months			
Erosions	20	2	22
No erosions	22	2	24
Total	42	4	46

Table 4B. Comparison of erosions detected by MRI and sonography at baseline and 6 months.

Sonography	MRI Erosions	MRI No Erosions	Total, n (%)
Baseline			
Erosions	13	1	14
No erosions	26	6	32
Total	39	7	46
6 months			
Erosions	19	0	19
No erosions	23	4	27
Total	42	4	46

difficult, particularly for the inexperienced radiologist. The relatively modest correlation between the experienced radiologist and the inexperienced radiologist trained for our study emphasizes the operator-dependent dimension of MRI interpretation.

During the course of 6 months, an increase in the number of erosions was detected by all 3 imaging modalities. We were unable to observe a correlation between clinical indicators of activity and the imaging findings, and there was no clear association between the HAQ score and the erosion score on radiographs, sonography, or MRI. This is in keeping with previous studies, where clinical indicators of activity and damage have not shown a clear correlation with the imaging results[11,26]. Based upon our observations, we

Personal, non-commercial use only. The Journal of Rheumatology Copyright © 2004. All rights reserved.

Downloaded on April 18, 2024 from www.jrheum.org

Table 5. Correlation coefficients (p value) for presence of erosions on MRI at baseline and 6 months and other radiographic variables and univariate analyses (p value) of baseline prediction of presence of erosions on MRI at 6 months.

	MR Imaging Erosions		
	Spearman Correlation Coefficients (p)		Univariate Analyses, Beta (p)
Imaging Endpoints at Baseline	Baseline	6 Months	6 Months
MRI			
Erosions	—	0.57 (< 0.001)	0.63 (< 0.001)
Bone edema	0.28 (0.06)	0.07 (0.67)	0.37 (0.47)
Synovitis	0.52 (0.00)	0.41 (0.004)	0.29 (0.01)
Effusions	0.15 (0.31)	0.20 (0.18)	0.67 (0.28)
Tendons			
Fluid tendon sheath	–0.13 (0.41)	–0.15 (0.33)	–0.50 (0.62)
Tendon sheath thickening	0.48 (0.001)	0.30 (0.04)	0.39 (0.056)
Increased size	0.12 (0.44)	0.06 (0.70)	0.08 (0.85)
Radiograph			
Erosions	0.40 (0.005)	0.41 (0.005)	0.68 (0.04)
Modified Sharp score	0.36 (0.01)	0.44 (0.002)	0.62 (0.006)
Sonography			
Erosions	0.26 (0.08)	0.28 (0.058)	0.57 (0.07)

hypothesize that cortical breakdown is often preceded by cortical thinning, subcortical reaction change, or edema. Further, the number of erosions not only increased in the interval 6 month period, they also tended to increase in size. Previous studies have shown a "lag" time for MRI erosions to become visible on radiographs[20], and it is likely that this is size or volume related. Note should be made that erosions around the metacarpal heads and interphalangeal joints were paramarginal, and that the true chondral surface remained robust and largely intact in patients with early RA. We hypothesize that it is likely that the chondral surface breaks down later in the disease process, leading to the characteristic marginal erosions identified on radiographs.

MRI — synovial assessment. The volume of synovium after contrast can be estimated by different methods[29]. We selected a contrast-enhanced MR angiographic technique. Our technique acquires 45 partition images in roughly 49 seconds. Each partition image can be reviewed to measure synovial thickness and enhancement. This was somewhat laborious when analyzing the data. When summed, the 45 partitions make up a maximum image projection, which is a simple but striking way of presenting information to clinicians. This sequence was repeated 4 times (4 × 49 s = 196 s) to show synovial disease in arterial, capillary, venous, and late venous phases. In addition, we increased the field of view to include the PIP joints. It is questionable whether the inclusion in our protocol of erosions of the phalanx was valuable, as MRI detected erosions in the fingers in only 28% of the patients. In contrast, 70% of the erosions were scored in the metacarpal and 63% in the carpal bones. Our data would suggest that inclusion of the PIP joints may add little if any information when screening or monitoring rheumatoid patients.

In the literature on MRI in RA, erosions and synovitis have traditionally been measured most frequently[30]. Our study shows that most patients (85%) have erosions at baseline, which highlights the importance of using thin slices (< 1 mm) to detect early or small erosions. Synovitis was also a frequent (71.7%) endpoint, yet slightly less sensitive compared to erosions (84.8%). The overall number of patients with synovitis remained exactly the same during 6 months (71.7%) and like the erosions, synovitis predominated around the MCP joints (56.5% of patients). In addition, tendon sheath disease was also a common finding in our patient cohort.

Sonography — bony damage detection. Sonography is a readily available modality, examines patients comfortably, and does not require intravenous injection of gadolinium. However, its use in detecting erosions is limited to the wrist. The deep intraarticular surfaces of the 3rd and 4th MCP joints, midcarpal, and CMC joints are not readily accessible, which limits assessment. In addition, there are few sonographic features that enable discrimination between cortical irregularity and erosions. For the purposes of this study, bony erosions were required to have a distinct "U" shape and to be found in close proximity to the joint. Lateral joint irregularity was particularly difficult to separate from erosive disease. This probably accounts for the discrepancy in erosion number compared with MRI. Unlike others, we did not detect more erosions with sonography compared to plain radiography[9,14,31]. Our protocol included imaging of the carpometacarpal and carpal joints, which are somewhat less accessible for ultrasound, hence the relatively small differences between radiography and ultrasound. On review of the one case of detection of erosion by sonography but not MRI, the erosion was missed, as it lay on the edge of the

Personal, non-commercial use only. The Journal of Rheumatology Copyright © 2004. All rights reserved.

Downloaded on April 18, 2024 from www.jrheum.org

coronal plane, despite thin 1 mm slices and a cartilage-specific sequence. This erosion (and one other, detected by plain radiograph but not MRI) may have been detected by repeating this sequence in another (preferably sagittal) plane, although this would have required another 11 minutes of MR scanning time. On the other hand, the long duration of the cartilage sequences (which renders them more susceptible to motion) may have contributed to another erosion being missed by MRI because of marked degradation of image quality due to motion.

Sonography — synovitis assessment and effusions. MRI was more sensitive for detecting synovial disease than sonography; however, ultrasound performed well in this area. This is in contrast to the results from Backhaus, *et al*, who report that synovitis was a common finding and even more prevalent compared to MRI[9]. Color and power Doppler sonography are sensitive techniques for assessing neovascularization and synovial proliferation in the radiocarpal 1st, 2nd and 5th, MCP, and PIP joints and rivals MRI assessment at these sites. In our study, synovitis was seen as subtle or marked areas of hypoechogenicity around the joint. The fibrils of proliferative synovium were sometimes delineated by small anechoic effusions. Color-flow imaging was further used to show areas of hyperemia. High resolution ultrasound provides excellent imaging of this region and thus we propose sonography could serve as an alternative for monitoring RA, although it is not clear for which patient groups this would be most useful. However, there are several caveats — in our study sonography was performed with a state of the art unit and it is unlikely that lower-end models would be as accurate. Sonography is highly operator-dependent and time-consuming, and there is also a moderately steep learning curve. Ultrasound also proved much more sensitive in the observation of small joint effusions. These were best visualized with gentle flexion while examining the volar aspect of the joint. The small amount of fluid would track into the redundant synovial fold created by the flexion. Observation of the effusions also served to delineate the volar plate. It was seen to be significantly involved in joint synovitis in some joints, while elsewhere it was completely spared. To our knowledge, involvement of the volar plate in RA has not been reported in the literature and is worth further study.

Our study showed that synovial enhancement is a constant finding independent of disease duration or treatment. This has been reported in other studies[2,28]. It is our experience that when a joint is affected, synovial thickening on MRI and sonography is almost universally greater than 3 mm, rendering smaller measurements redundant. Moreover, we have no evidence that the degree of synovial thickness is a predictor for developing erosive disease. Therefore we propose that it may be easier and more feasible to determine the presence or absence of synovial thickening without measurement of the degree of synovial thickening.

MRI and sonography — tendon assessment. MRI and sonography were equivalent for detecting tendon sheath disease. We found that tendon sheath disease was common in patients with RA. The value of scoring tendon pathology is as yet unclear. Most promising was the finding of the high incidence of tendon sheath thickening (in 65.2% of the patients). Tendon sheath disease was common, and in some patients, the only feature of disease activity. The most common tendon sheaths involved were the flexor digitorum tendons, followed by extensor carpi ulnaris and flexor carpi radialis. Multiple tendon sheaths were usually involved. When the common flexor tendons were involved, commonly one or 2 tendons were affected and involvement was focal rather than diffuse, suggesting that the whole tendon sheath needs to be examined. Ultrasound was also able to provide details about tendon size and variations in fibrillar pattern including degenerative splitting. Multiple small tendon sheath cysts were also observed, although like volar plate abnormalities were not classifiable within the scoring system that we applied in this study.

Intra- and interreader reliability — MRI and radiographs. The intrareader reliability of our scoring system was excellent. However, when applied by 2 independent radiologists the interreader reliability was variable. The scoring of tendon pathology was not very reliable. On the other hand, the interreader reliability for erosions was found to be acceptable for both MRI and radiographs. The reliability was fair to poor for the other MRI indices. Possibly this is due to the low prevalence of some measures, reflecting the early stage of RA, when bone and joint changes are still minor. The erosions score for MRI (85% of the patients had erosions) was considerably higher than for radiograph (37% had erosions), and therefore by chance there was a high probability of agreement, resulting in lower kappa values for MRI. Both intraclass correlations and kappa values showed similar results. A similar study based on the MRI classification system of McQueen, *et al* found high interreader reliability for erosions (ICC = 0.79)[11]. In contrast to the erosion scores by one radiologist (DC; intrareader ICC = 0.90), our interreader reliability erosion scores were lower (ICC = 0.60), probably reflecting differences in experience between the 2 radiologists.

Our scoring system for classifying MRI and sonography was based on the scoring system by McQueen and Ostergaard[11,30]. In addition to scoring the carpal and metacarpal bones and joints we also included the PIP and MCP joints. The inclusion of all these sites is questionable. As the metacarpal bones were the most typical location of erosions in the hand, it may be that assessment of this site alone may provide similar results. If we include, using MRI, only the 5 metacarpal heads and bases we can identify 32 patients with erosions at baseline as compared to 39 patients if we look at all sites. Thus we "miss" erosions in 7 patients. For radio-

Personal, non-commercial use only. The Journal of Rheumatology Copyright © 2004. All rights reserved.

Downloaded on April 18, 2024 from www.jrheum.org

Appendix. Summary of the 2 scoring systems modified in this study.

Imaging Endpoints	OMERACT MRI Scoring System[21]	McQueen MRI Scoring System[20]
Erosions	Location: in hand and wrist (including carpal bones). Scoring: 0 to 10 by the volume of the defect (in 10% increments of the total assessed bone volume)	15 locations: 10 carpal bones and 5 metacarpal bones. Scoring 0, 1 (< 4 mm), 2 (> 4 mm). Overall number of erosions and number of erosions per site. Maximum sum score is 30
Defects	Scoring: as for erosions 0 to 10	Not applicable
Bone edema	Scoring: as for erosions 0 to 10	Locations: as for erosions. Scoring: 0 = none, 1 = minor < 50% bone, 2 = gross edema > 50% bone. Maximum sum score is 30
Synovitis	Location: MCP 2–5 scored by 2 methods: 1. Global score 0–3: 0 = normal, 1–3 = "by thirds of the presumed maximum volume of enhancing tissue in the synovial compartment" 2. Thickness (in mm) of enhancing tissue on axial scan in slice showing most thickening Location: carpus scored by 2 methods: 1. Global score 0–3: 0 = normal, 1–3 = "by thirds of the presumed maximum volume of enhancing tissue in the synovial compartment of radioulnar, radiocarpal, and intercarpal-CMC joints" 2. Thickness (in mm) of enhancing tissue perpendicular to cortical surface. Coronal scan (from scaphoid, triquetrum). Axial scan (at radioulnar joint and along curved dorsal surface of the 1st and 2nd carpal rows)	Location: Carpus 7 sites: CMC 2–5 (assessed together), 1st CMC joint and piso-triquetral joint. Scoring synovial thickening: 0 (< 2 mm), 1 (2–4 mm), 2 (> 4 mm) + post-gadolinium enhancement (0 for none, 1 mild to moderate, 2 gross). Maximum total score for carpus is 28.
Tendons	Not applicable	9 tendon groups. Scoring for inflammation of the tendon sheath 0 (absent) and 1 (present); inflammation within the tendon itself 0 (normal) and 1 (increased signal); tendon size 0 (normal), 1 (thickened), and 2 (attenuated). Maximum tendon score carpus = 36

graphy, we miss 10 of 17 patients if we only look at the metacarpals (at baseline).

Unfortunately, our followup period may not have been sufficiently long for MRI, sonography, and radiographs to pick up substantial changes in imaging findings. In addition, the sample size of our study was modest, with 46 patients. Identification of any predictors of MRI changes at 6 months using baseline findings other than imaging findings was limited. Bone edema is believed to be secondary to changes in inflammatory activity[29] or synovitis[10]. Unlike McQueen, we did not find that bone edema was a predictor for erosions. The prevalence of bone marrow edema MRI in this study was quite low (26%) compared to Savnik, *et al*, McQueen, *et al*, and McGonagle, *et al*, who reported prevalences of 39%[29], 64%[20], and 68%[10], respectively. We attribute this to differences in our selection criteria (disease duration, clinical selection criteria the sites assessed). In addition, Savnik, *et al* found that edema is most prevalent in patients with a longer duration of RA (> 3 yrs)[29].

In our study, MRI was found to be the most sensitive imaging technique for identifying joint damage in RA, and the most common and reliable MRI features were erosions and synovitis. Tendon pathology may be a useful indicator of activity in patients with RA, and the identification and classification of tendon pathology by MRI and sonography deserves further study. Although less sensitive compared to MRI, sonography was found to be an adequate technique that detects many of the endpoints identified by MRI. Its ability to distinguish small amounts of fluid from the adjacent synovium/volar plate offers potential in understanding patterns of RA distribution. It also has potential as a tool for monitoring patients with early RA/inflammatory arthritis.

ACKNOWLEDGMENT

We thank Corrine Garamszegi, Gail Grant, Kate Brady, and Pru Pratten for their assistance in the study and Marissa Lassere for helpful advice.

REFERENCES

1. Peterfy CG. Magnetic resonance imaging in rheumatoid arthritis: current status and future directions. J Rheumatol 2001;28:1134-42.
2. Ostergaard M, Hansen M, Stoltenberg M, et al. Magnetic resonance imaging-determined synovial membrane volume as a marker of disease activity and a predictor of progressive joint destruction in the wrists of patients with rheumatoid arthritis. Arthritis Rheum 1999;42:918-29.
3. Klarlund M, Ostergaard M, Lorenzen I. Finger joint synovitis in rheumatoid arthritis: quantitative assessment by magnetic resonance imaging. Rheumatology Oxford 1999;38:66-72.
4. Gaffney K, Cookson J, Blades S, Coumbe A, Blake D. Quantitative assessment of the rheumatoid synovial microvascular bed by gadolinium-DTPA enhanced magnetic resonance imaging. Ann Rheum Dis 1998;57:152-7.
5. Lee J, Lee SK, Suh JS, Yoon M, Song JH, Lee CH. Magnetic resonance imaging of the wrist in defining remission of rheumatoid arthritis. J Rheumatol 1997;24:1303-8.
6. Ostergaard M, Stoltenberg M, Gideon P, Sorensen K, Henriksen O, Lorenzen I. Changes in synovial membrane and joint effusion volumes after intraarticular methylprednisolone. Quantitative assessment of inflammatory and destructive changes in arthritis by MRI. J Rheumatol 1996;23:1151-61.

Personal, non-commercial use only. The Journal of Rheumatology Copyright © 2004. All rights reserved.

Downloaded on April 18, 2024 from www.jrheum.org

7. Klarlund M, Ostergaard M, Gideon P, Sorensen K, Jensen KE, Lorenzen I. Wrist and finger joint MR imaging in rheumatoid arthritis. Acta Radiol 1999;40:400-9.
8. McQueen FM. Magnetic resonance imaging in early inflammatory arthritis: what is its role? Rheumatology 2000;39:700-6.
9. Backhaus M, Kamradt T, Sandrock D, et al. Arthritis of the finger joints: a comprehensive approach comparing conventional radiography, scintigraphy, ultrasound, and contrast-enhanced magnetic resonance imaging. Arthritis Rheum 1999;42:1232-45.
10. McGonagle D, Conaghan PG, O'Connor P, et al. The relationship between synovitis and bone changes in early untreated rheumatoid arthritis: a controlled magnetic resonance imaging study. Arthritis Rheum 1999;42:1706-11.
11. McQueen FM, Stewart N, Crabbe J, et al. Magnetic resonance imaging of the wrist in early rheumatoid arthritis reveals progression of erosions despite clinical improvement. Ann Rheum Dis 1999;58:156-63.
12. Hug C, Huber H, Terrier F, et al. Detection of flexor tenosynovitis by magnetic resonance imaging: its relationship to diurnal variation of symptoms. J Rheumatol 1991;18:1055-9.
13. Bianchi S, Martinoli C, Sureda D, Rizzatto G. Ultrasound of the hand. Eur J Ultrasound 2001;14:29-34.
14. Wakefield RJ, Gibbon WW, Conaghan PG, et al. The value of sonography in the detection of bone erosions in patients with rheumatoid arthritis: a comparison with conventional radiography. Arthritis Rheum 2000;43:2762-70.
15. Grassi W, Filippucci E, Farina A, Salaffi F, Cervini C. Ultrasonography in the evaluation of bone erosions. Ann Rheum Dis 2001;60:98-103.
16. Arnett FC, Edworthy SM, Bloch DA, et al. The American Rheumatism Association 1987 revised criteria for the classification of rheumatoid arthritis. Arthritis Rheum 1988;31:315-24.
17. Pincus T, Summey JA, Soraci SA Jr, Wallston KA, Hummon NP. Assessment of patient satisfaction in activities of daily living using a modified Stanford Health Assessment Questionnaire. Arthritis Rheum 1983;26:1346-53.
18. Duruoz MT, Poiraudeau S, Fermanian J, et al. Development and validation of a rheumatoid hand functional disability scale that assesses functional handicap. J Rheumatol 1996;23:1167-72.
19. Kalla AA, Kotze TJ, Meyers OL, Parkyn ND. Clinical assessment of disease activity in rheumatoid arthritis: evaluation of a functional test. Ann Rheum Dis 1988;47:773-9.
20. McQueen FM, Stewart N, Crabbe J, et al. Magnetic resonance imaging of the wrist in early rheumatoid arthritis reveals a high prevalence of erosions at four months after symptom onset. Ann Rheum Dis 1998;57:350-6.
21. Conaghan P, Edmonds J, Emery P, et al. Magnetic resonance imaging in rheumatoid arthritis: summary of OMERACT activities, current status, and plans. J Rheumatol 2001;28:1158-62.
22. Van der Heijde D. How to read radiographs according to the Sharp/van der Heijde method. J Rheumatol 1999;26:743-5.
23. Atkinson G, Nevill AM. Statistical methods for assessing measurement error (reliability) in variables relevant to sports medicine. Sports Med 1998;26:217-38.
24. Cohen J. A coefficient of agreement for nominal scales. Educ Psychol Meas 1960;20:37-46.
25. McQueen FM, Benton N, Crabbe J, et al. What is the fate of erosions in early rheumatoid arthritis? Tracking individual lesions using x rays and magnetic resonance imaging over the first two years of disease. Ann Rheum Dis 2001;60:859-68.
26. Klarlund M, Ostergaard M, Jensen KE, Madsen JL, Skjodt H, Lorenzen I. Magnetic resonance imaging, radiography, and scintigraphy of the finger joints: one year follow up of patients with early arthritis. The TIRA Group. Ann Rheum Dis 2000;59:521-8.
27. Backhaus M, Burmester GR, Sandrock D, et al. Prospective two year follow up study comparing novel and conventional imaging procedures in patients with arthritic finger joint. Ann Rheum Dis 2002;61:895-904.
28. Disler DG. Fat-suppressed three-dimensional spoiled gradient-recalled MR imaging: assessment of articular and physeal hyaline cartilage. AJR Am J Roentgenol 1997;169:1117-23.
29. Savnik A, Malmskov H, Thomsen HS, et al. Magnetic resonance imaging of the wrist and finger joints in patients with inflammatory joint diseases. J Rheumatol 2001;28:2193-200.
30. Ostergaard M, Gideon P, Sorensen K, et al. Scoring of synovial membrane hypertrophy and bone erosions by MR imaging in clinically active and inactive rheumatoid arthritis of the wrist. Scand J Rheumatol 1995;24:212-8.
31. Cimmino MA, Bountis C, Silvestri E, Garlaschi G, Accardo S. An appraisal of magnetic resonance imaging of the wrist in rheumatoid arthritis. Semin Arthritis Rheum 2000;30:180-95.

Personal, non-commercial use only. The Journal of Rheumatology Copyright © 2004. All rights reserved.

Personal, non-commercial use only. The Journal of Rheumatology Copyright © 2004. All rights reserved.

Downloaded on April 18, 2024 from www.jrheum.org