Case Report

Staphylococcal Endocarditis and Multiple Emboli in a Patient with Systemic Lupus Erythematosus

CHIANG-HUA LIAO, TSUNG-CHIEH YAO, HUNG-TAO CHUNG, REY-IN LIEN, and JING-LONG HUANG

ABSTRACT. We describe a patient with systemic lupus erythematosus who developed *Staphylococcus aureus* endocarditis following dental work. Multiple brain and cutaneous septic emboli developed despite aggressive antibiotic therapy. (J Rheumatol 2004;31:2305–6)

Key Indexing Terms:
INFECTIVE ENDOCARDITIS STAPHYLOCOCCUS AUREUS EMBOLI
INTRACRANIAL HEMORRHAGE SYSTEMIC LUPUS ERYTHEMATOSUS

Infection is an important risk factor for morbidity and mortality in patients with systemic lupus erythematosus (SLE) and major infection[1] accounts for 32% of deaths in SLE. The longterm use of corticosteroids and immunosuppressive agents contributes to this risk[2-4]. Corticosteroids lead to fibrotic and retracted cardiac valve leaflet tissue, which increases the risk of valvular dysfunction and infective endocarditis (IE) in patients with SLE[5]. We describe a patient with SLE who developed *Staphylococcus aureus* endocarditis with multiple brain and cutaneous septic emboli following dental work.

CASE REPORT

A 12-year-old girl diagnosed with SLE at age 6, who subsequently received continuous ambulatory peritoneal dialysis because of endstage renal disease, presented with complaints of fever, dyspnea, tachycardia, severe abdominal pain, and new malar rashes. Two weeks before admission, she had undergone several dental procedures. Hypertension and congestive heart failure (CHF), proven by cardiac echocardiography, worsened progressively.

On admission she was alert with respiratory distress and orthopnea. Her temperature was 38.6°C, heart rate 125 beats/minute, respiratory rate 35 breaths/minute, and blood pressure 171/97 mm Hg. Bilateral jugular veins were engorged; decreased breathing sounds in the left lung field and a 3/6 systolic murmur over the left sternal border were heard; her abdomen had muscle guarding, diffuse tenderness, and rebounding pain. Erythema of bilateral palms and nonpitting edema of both lower extremities were also noted. Laboratory investigations showed the following: white blood cell count 16.0 × 10^9/l, hemoglobin 8.9 g/dl, platelet count 110 × 10^9/l, C-reactive protein 155 mg/l, blood urea nitrogen 123 mg/dl, creatinine 5 mg/dl, albumin 3 g/dl, creatine kinase 163 U/l, troponin-I 27.5 ng/ml, alkaline phosphatase 119 U/l, C3 35 mg/dl, and C4 < 5.4 mg/dl. Antinuclear antibody was 1/320 and anti-dsDNA antibody was 178 IU/ml. Urinalysis revealed hematuria (red blood cells > 500/µl) and proteinuria (25 mg/dl). Chest radiography showed bilateral increased lung infiltrates and cardiomegaly.

She was initially treated with methylprednisolone pulse therapy, inotropic agents, and ceftriaxone for a perceived SLE flare, CHF, and bacterial peritonitis. On day 2, transthoracic echocardiography showed poor ejection fraction (49%) and a vegetation, measuring 3.83 cm in circumference and 0.96 cm^2 in area, on the posterior leaflet of mitral valve (Figure 1). Vancomycin was added to her treatment regimen on suspicion of bacterial endocarditis and the fever subsided within 48 hours. Oxacillin-resistant *S. aureus* was isolated from 4 separate blood cultures and ceftriaxone was discontinued. No bacteria were cultured from the urine and peritoneal fluid.

Unexpectedly, fever recurred on day 5 and a generalized tonic-clonic seizure occurred on the same day. Splinter hemorrhages beneath her fingernails and toenails, and Janeway's lesions on her fingers, palms, and soles were also noted. Brain computed tomography (CT) showed multiple intracranial hemorrhages and calcifications at the basal ganglion. Phenytoin was added to control seizure activity. The fever resolved 3 weeks later and a repeat echocardiogram showed improved ejection fraction (67%) and decreased vegetation size. Chest radiography also showed both improved lung infiltrates and a decreased cardiac size. Vancomycin was continued for 6 weeks and she was discharged in stable condition. No vegetation was found on echocardiogram 2 months later.

DISCUSSION

Among the cardiovascular abnormalities associated with SLE, Libman-Sacks lesions are the most common endocardial lesions and consist of sterile fibrin and platelet accumulations[6]. These lesions may change the hemodynamic system and serve as a nidus for microbial infection, placing patients at risk of developing IE. Our patient had undergone dental procedures without receiving antibiotic prophylaxis. Her nasopharynx might have been inhabited by *S. aureus*, which is uncommonly isolated from the oral cavity in some patients with serious underlying illnesses[7]. *S. aureus* might have entered the bloodstream during the dental work. Host immunity is depressed in patients with SLE as a result of corticosteroids and complement deficiency, and abnormalities of the reticuloendothelial system[8], which might contribute to the impaired clearance of bacteria, leading to the later development of IE.

Systemic embolization occurs in 24% to 44% of IE cases, and up to 65% of embolic events involve the central nervous

From the Department of Pediatrics, Chang Gung Children's Hospital and Chang Gung University, Taoyuan, Taiwan.

C.H. Liao, MD, Fellow; T.C. Yao, MD, Attending Physician; H.T. Chung, MD, Attending Physician; R.I. Lien, MD, Assistant Professor; J.L. Huang, MD, Professor.

Address reprint requests to Dr. J.L. Huang, Division of Allergy, Asthma and Rheumatology, Department of Pediatrics, Chang Gung Children's Hospital, 5 Fu-Hsin Street, Kueishan, Taoyuan, Taiwan. E-mail: long@adm.cgmh.org.tw

Submitted November 19, 2003; revision accepted June 9, 2004.

Personal, non-commercial use only. The Journal of Rheumatology. Copyright © 2004. All rights reserved.

Downloaded on April 19, 2024 from www.jrheum.org

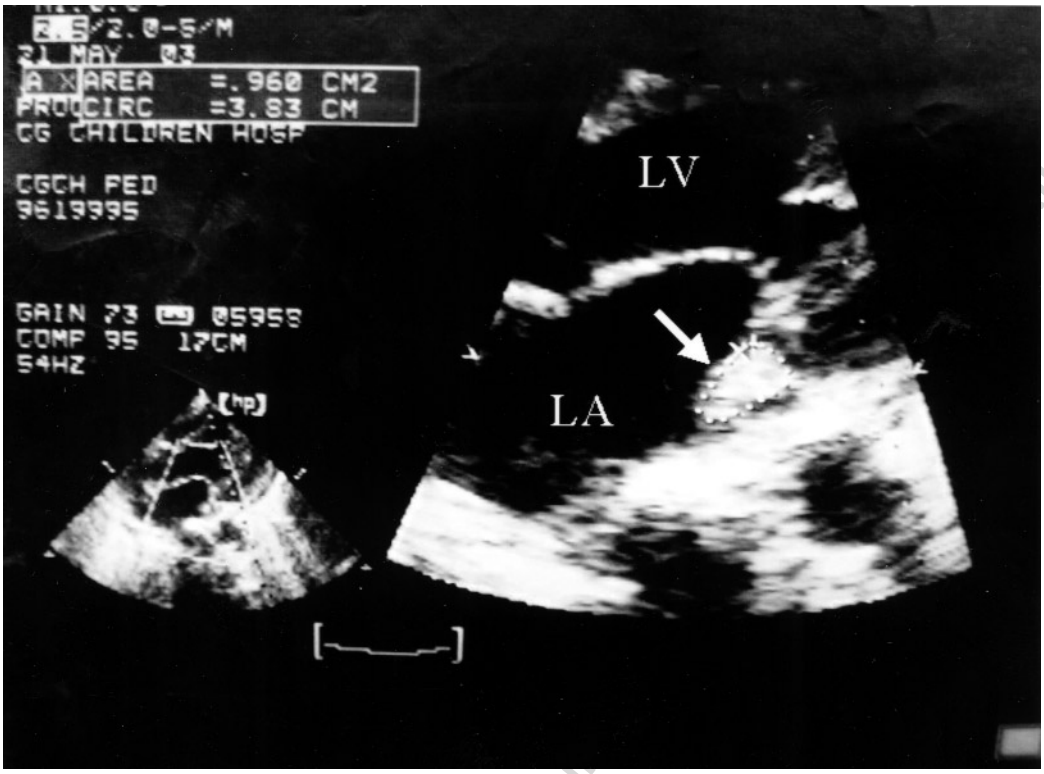

Figure 1. Transthoracic echocardiography showed a vegetation (arrow) on the insertion of the posterior leaflet of the mitral valve on the left atrial side.

system (CNS)[9,10]. Intracranial hemorrhage occurs in about 7% of patients with IE, and it often leads to death[11]. The incidence of embolic complications of IE is the highest among patients with *S. aureus* infection of the mitral valve. Most embolizations occur within the first 2 to 4 weeks of antimicrobial therapy[12]. In our patient, seizure and cutaneous emboli occurred despite aggressive antibiotic therapy. Brain CT showed multiple intracranial hemorrhages in the cortical and subcortical areas that may be caused by lupus vasculitis of the CNS or cerebral emboli. Notably, the seizure was associated with the occurrence of splinter hemorrhages and Janeway's lesions. Therefore, we believed these intracranial hemorrhages were compatible with secondary hemorrhagic transformation of ischemic infarcts caused by septic embolization.

We emphasize that recognizing the possibility of infectious endocarditis in patients with SLE with fever and CHF can avoid delay in diagnosis. Septic emboli may develop despite aggressive antibiotic therapy. Our case further highlights the question of antibiotic prophylaxis for dental work in patients with SLE.

REFERENCES

1. Abu-Shakra M, Urowitz MB, Gladman DD, Gough J. Mortality studies in systemic lupus erythematosus. Results from a single center. I. Causes of death. J Rheumatol 1995;22:1259-64.
2. Tsao CH, Chen CY, Ou LS, Huang JL. Risk factors of mortality for Salmonella infection in systemic lupus erythematosus. J Rheumatol 2002;29:1214-8.
3. Huang JL, Lin CJ, Hung IJ, Luo SF. The morbidity and mortality associated with childhood onset systemic lupus erythematosus. Chang Gung Med J 1994;17:113-20.
4. Wu KC, Yao TC, Yeh KW, Huang JL. Osteomyelitis among patients with systemic lupus erythematosus. J Rheumatol 2004;31:1340-3.
5. Morin AM, Boyer AS, Nataf P, Gandjbakhch I. Mitral insufficiency caused by systemic lupus erythematosus requiring valve replacement: three case reports and a review of the literature. Thorac Cardiovasc Surg 1996;44:313-6.
6. Roldan CA, Shively BK, Crawford MH. An echocardiographic study of valvular heart disease associated with systemic lupus erythematosus. N Engl J Med 1996;335:1424-30.
7. Baker AS, Montgomery WW. Oropharyngeal space infections. Curr Clin Top Infect Dis 1987;8:227-65.
8. Walport MJ. Complement deficiency and disease. Br J Rheumatol 1993;32:269-73.
9. De Castro S, Magni G, Beni S, et al. Role of transthoracic and transesophageal echocardiography in predicting embolic events in patients with active infective endocarditis involving native cardiac valves. Am J Cardiol 1997;80:1030-4.
10. Pruitt AA, Rubin RH, Karchmer AW, Duncan GW. Neurologic complications of bacterial endocarditis. Medicine 1978;57:329-43.
11. Hart RG, Foster JW, Luther MF, Kanter MC. Stroke in infective endocarditis. Stroke 1990;21:695-700.
12. Garvey GJ, Neu HC. Infective endocarditis — an evolving disease. A review of endocarditis at the Columbia-Presbyterian Medical Center, 1968-1973. Medicine 1978;57:105-27.

Personal, non-commercial use only. The Journal of Rheumatology. Copyright © 2004. All rights reserved.

Downloaded on April 19, 2024 from www.jrheum.org