Expression of a Wide Range of Fibrocartilage Molecules at the Entheses of the Alar Ligaments — Possible Antigenic Targets for Rheumatoid Arthritis?

ALEXANDRAA. BOSZCZYK, BRONEK M. BOSZCZYK, REINHARD PUTZ, MICHAEL BENJAMIN, and STEFAN MILZ

ABSTRACT. ***Objective.*** To provide evidence for the existence of a wide range of molecules characteristic of fibrocartilage at normal alar ligament entheses, that may have a bearing on the pathogenesis of rheumatoid arthritis. The alar ligaments provide the mechanical restraint for head rotation and their integrity can be compromised in patients with RAand occasionally in those with spondyloarthropathy.

Methods. Both alar ligaments from 6 cadavers were fixed in 90% methanol and cryosectioned longitudinally. Sections were immunolabelled with antibodies against collagens, glycosaminoglycans, and proteoglycans. The immunohistochemical data were related to estimates of insertional angle change at the entheses that were calculated from measurements of ligament length and dens diameter.

Results. Molecules typical of fibrocartilage (including type II collagen, link protein, and aggrecan) were found at both entheses, but labelling was more prominent at the odontoid end. This correlated with a 3-fold greater insertional angle change during 40° of head rotation at the attachment of the ligament to the dens. At the odontoid enthesis, fibrocartilage differentiation was most conspicuous posteriorly.

Conclusion. The changes in insertional angle mean that compressive forces are prominent at both entheses, but particularly at the odontoid end, where the ligament partly wraps around the dens during head rotation. Thus, mechanical conditions are created that lead to pronounced fibrocartilage development, hence the expression of type II collagen, link protein, and aggrecan. The prominence of these molecules at the entheses raises the possibility that they could be antigenic targets for an autoimmune response in rheumatic diseases. (J Rheumatol 2003;30:1420–5)

Key Indexing Terms:

ALAR LIGAMENT	FIBROCARTILAGE	IMMUNOHISTOCHEMISTRY
UPPER CERVICAL SPINE	ATLANTOAXIAL ROTATION	RHEUMATOID ARTHRITIS

The range of axial rotation between the atlas and the axis is the greatest between any 2 adjacent vertebrae in the entire spine[1]. The movement is facilitated by the alar ligaments, which also provide a definitive restraint for head rotation at the extremes of motion. The alar ligaments are significant to rheumatologists because the integrity of the craniocervical region can be compromised in patients with rheumatoid arthritis (RA) or the seronegative spondyloarthropathies (SpA). According to Zoli, *et al*[2] craniocervical involvement in RA can be depicted by computed tomography and magnetic resonance imaging scans in 41% and 61% of patients, respectively. In a significant number of patients with chronic disease, there is a gradual degeneration of all the ligaments of the atlantoaxial complex that compromises mechanical stability[3-5]. Indeed Moskovich, *et al*[6] have estimated that as many as 10% of all patients with RAcan have such severe atlantoaxial subluxation that they require surgical stabilization. Subluxation can also occur in patients with a variety of seronegative SpA, including ankylosing spondylitis[7,8], Reiter's syndrome[9-11], and psoriatic arthritis[9,12,13]. In all these patients, loss of function in the craniocervical region may lead to severe neurological complications including brain stem compression[6,14]. Neural compression occurs when the space available for the brain stem falls below 13–14 mm[4].

Until recently, RA has been widely regarded as an autoimmune disease of unknown etiology. However, there is now substantial evidence to suggest that there is an autoimmune response to antigens present in articular cartilage that may play a significant role in the pathogenesis of the disease[15-18]. Putative antigens include aggrecan, link protein,

From the Anatomische Anstalt, Ludwig-Maximilians-Universität, München, and the Department of Neurosurgery, Berufsgenossenschaftliche Unfallklinik, Murnau, Germany, and the School of Biosciences, University of Wales, Cardiff, Wales.

Supported by a grant from the Friedrich Baur Stiftung Munich to S. Milz and A. Boszczyk.

A.A. Boszczyk, MD; S. Milz, MD, Lecturers in Anatomy; R. Putz, MD, PhD, Professor and Head of Anatomy, Munich University; B.M. Boszczyk, MD, Neurosurgeon, Berufsgenossenschaftliche Unfallklinik; M. Benjamin, PhD, Reader in Anatomy, Cardiff University.

Address reprint requests to Dr. A. Boszczyk, Anatomische Anstalt, Ludwig-Maximilians-Universität, Pettenkoferstrasse 11, D-80336 München, Germany. E-mail: alexandra.boszczyk@gmx.net

Submitted September 23, 2002; revision accepted December 11, 2002.

Personal, non-commercial use only. The Journal of Rheumatology Copyright © 2003. All rights reserved.

Downloaded on April 17, 2024 from www.jrheum.org

and type II collagen, all molecules that are found not only in articular cartilage, but also in certain regions of tendons and ligaments. These include the sites where tendons and ligaments wrap around bony pulleys and many entheses, notably those with a wide change in the insertional angle between tendon/ligament and bone that accompanies joint movement[19-21]. As the alar ligaments are so short and the range of head rotation is so great (typically 40° on each side[22]), insertional angle changes must be large, and this is probably why the ligament is especially vulnerable to insertional injuries[22]. Further, we would predict insertional angle changes to be greater at the attachment of the dens during head rotation, because the radius of the dens is considerably less than that of the foramen magnum. If the angle change is more pronounced at the odontoid end of the ligament, then the risk of wear and tear should be greater here. This could explain the high incidence (57%) of erosions of the dens reported by Czerny, *et al*[23] in patients with RA. In SpA too, it has been suggested that the disease targets sites where fibrocartilage is present in the body, particularly tendons and ligaments[21]. Maksymowych[24] has suggested that these diseases involve an autoimmune response to antigens present in tendon/ligament fibrocartilage, while Benjamin and McGonagle[21] favor the view that the presence of fibrocartilage at sites commonly implicated in SpA is primarily related to the risk of mechanical trauma in these locations. In either scenario, the presence of fibrocartilage at targeted sites is of pivotal importance.

In view of the frequent involvement of the atlantoaxial region in patients with RA or SpA, and the putative role of fibrocartilage in both, our purpose was to characterize the distribution of molecules typical of this tissue at the entheses of the normal alar ligament and to relate this to estimates of insertional angle changes during head rotation.

MATERIALS AND METHODS

Removal and measurement of specimens. Six specimens taken from the suboccipital region of adult cadavers (men and women aged 65–89 years) donated to the Department of Anatomy at the University of Munich were removed within 48 hours of death. The specimens included the occipital condyles together with the atlas, axis, and their associated ligaments, and were removed en-bloc by a posterior dissection approach. In no case was the cause of death related to suboccipital pathology. Each entire alar ligament, including its entheses, was dissected from the specimens by removing the posterior arch of the atlas, dividing the transverse ligament, and severing the odontoid process from its vertebral body. Minor ligamentous attachments between the odontoid process and the atlas, described by Dvorak and Panjabi[25] as atlanto-dental ligaments, were severed when present. The specimens were immediately fixed in 90% methanol at 4°C and stored at –20°C. At this stage, the diameter of the odontoid process was measured with calipers, together with the length of each alar ligament (measured anteriorly). The bony attachment area occupied by each enthesis was estimated by measuring both its width and its depth. All values are expressed as means ± standard error.

Immunohistochemistry. After fixation and subsequent decalcification in 5% EDTA, specimens were cryosectioned at 12 µm. Sections from the middle of the block were cut in the direction of the ligament fibers. The sections were then stained with toluidine blue for metachromasia and with a panel of antibodies against collagens (types I, II, III, V, and VI), glycosaminoglycans (keratan sulfate, dermatan sulfate, and chondroitin 4 and 6 sulfates), and proteoglycans (versican, aggrecan including its link protein, and tenascin). Details of any necessary enzyme pretreatments, together with the antibody sources and concentrations, have been described[26,27]. Briefly, sections were treated with 0.3% hydrogen peroxide in methanol for 30 min to block the activity of any endogenous peroxidase, after appropriate enzyme pretreatment. Any nonspecific binding of the secondary antibody was minimized by treating the sections for 60 min with normal horse serum. For control purposes, either the primary antibody was omitted or the sections were incubated with nonspecific mouse immunoglobulins (10 µg/ml) or with an antibody against an antigen not present in the tissue. Antibody binding was detected with a Vectastain ABC Elite avidin/biotin kit (Vector Labs, Burlingame, CA, USA) and the sections were briefly counterstained with hematoxylin.

Estimation of insertional angle changes. Insertional angle changes were estimated for a head rotation of both 30° and 40° by simple geometry from measurements of alar ligament length (which reflect the size of the foramen magnum) and the diameter of the odontoid process.

RESULTS

Insertional angle changes. The position of the alar ligaments in the dissected gross specimens after removal of the dorsal half of the craniocervical junction is shown in Figures 1a and 1b. The average diameter of the odontoid process was 10.6 ± 0.5 mm, the mean length of the alar ligaments was 8.2 ± 1.0 mm, and the surface areas of the odontoid and occipital entheses were 60 ± 5.5 mm^2 and 50.6 ± 5.6 mm^2, respectively. From these raw data, the changes in insertional angle for 40° of head rotation were determined geometrically as 19° and 60° at the occipital and odontoid ends of the ligament, respectively (Figure 2). For 30° of rotation, the comparable values were 16° and 47°.

Immunohistochemistry. The results of the immunohistochemical survey are summarized below. Labelling patterns were generally similar for the 2 ligaments from the same individual.

Collagens. Collagens types I, III, and VI were found throughout the ligament, although in 8 odontoid and 6 occipital entheses, there was a narrow band of extracellular matrix (ECM) near the bony interface that did not label for type I collagen (Figure 1c). Type II collagen was largely restricted to the entheses and was more pronounced at the odontoid than the occipital end (Figure 1d). At the former, it was typically most conspicuous posteriorly (Figure 1d) and labelling was strongest in those specimens where type I collagen was locally absent. In the region characterized by type II collagen labelling, round fibrocartilage cells were present (Figure 1e), but elsewhere the ligament mainly contained fibroblasts.

Glycosaminoglycans and proteoglycans. Tenascin, versican, keratan sulfate, dermatan sulfate, and chondroitin 4 sulfate were found throughout the course of the ligament. Although versican was present in the enthesis fibrocartilages, it was locally absent near the bony interface in 5 odontoid and 4 occipital entheses in the region that was also devoid of type I collagen labelling (Figure 1f). Weak labelling for chon-

Personal, non-commercial use only. The Journal of Rheumatology Copyright © 2003. All rights reserved.

Downloaded on April 17, 2024 from www.jrheum.org

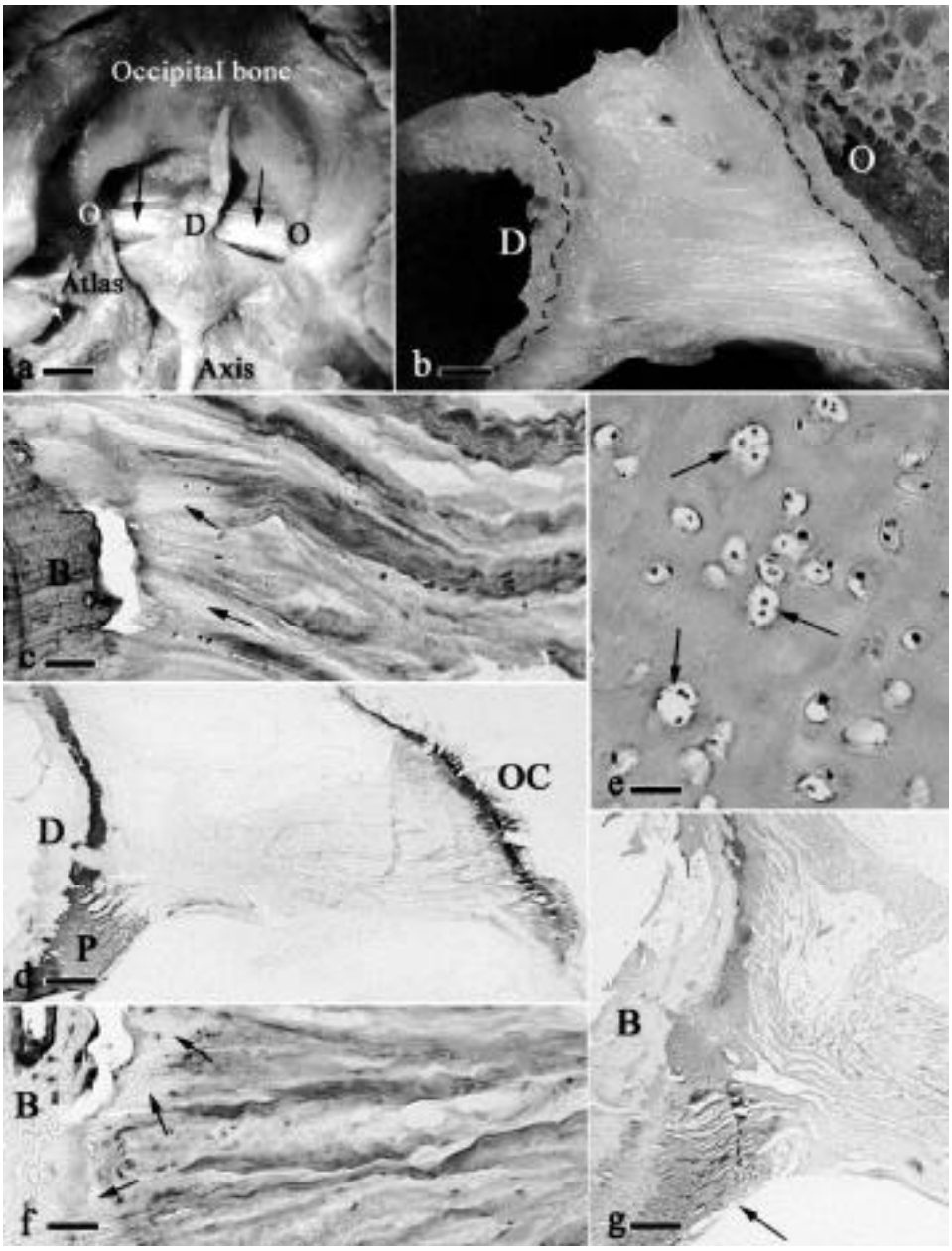

Figure 1. Macroscopic appearance of the alar ligaments and immunohistochemical labelling patterns for collagens and proteoglycans. (a) Macroscopic overview of the ventral aspect of the craniocervical complex after removal of all posterior structures, including the dorsal region of the foramen magnum, upper cervical vertebrae, brain stem, and spinal cord. The alar ligaments (arrows) extend from the dens (D) to the occipital condyles (O). Scale bar 6.5 mm. (b) Dissection of a right alar ligament to show its attachments to the dens (D) and occipital condyles (O). Note how the ligament flares out at its entheses. The interfaces between the ligament and bone are indicated by broken lines. Scale bar 1.7 mm. (c) Widespread, diffuse labelling for type I collagen at an occipital enthesis. Note, however, the local absence of labelling (arrows) near the bony interface. This is especially obvious in contrast to the positive labelling of the bone (B). Scale bar 20 µm. (d) Low power view of an alar ligament labeled for type II collagen. Although both entheses are labeled, labelling is more conspicuous at the odontoid enthesis — and particularly at its posterior margin (P). D: dens; OC: occipital condyle. Scale bar 1200 µm. (e) Higher magnification of the odontoid enthesis showing numerous round fibrocartilage cells (arrows) in a type II collagen-positive ECM. Scale bar 10 µm. (f) Versican labelling at an occipital enthesis. Note the local absence of labelling (arrows) near the bony interface. B: bone. Scale bar 20 µm. (g) Low power view of an odontoid enthesis showing pronounced labelling for aggrecan in the enthesis fibrocartilage (FC, arrow). B: bone. Scale bar 400 µm.

Personal, non-commercial use only. The Journal of Rheumatology Copyright © 2003. All rights reserved.

Downloaded on April 17, 2024 from www.jrheum.org

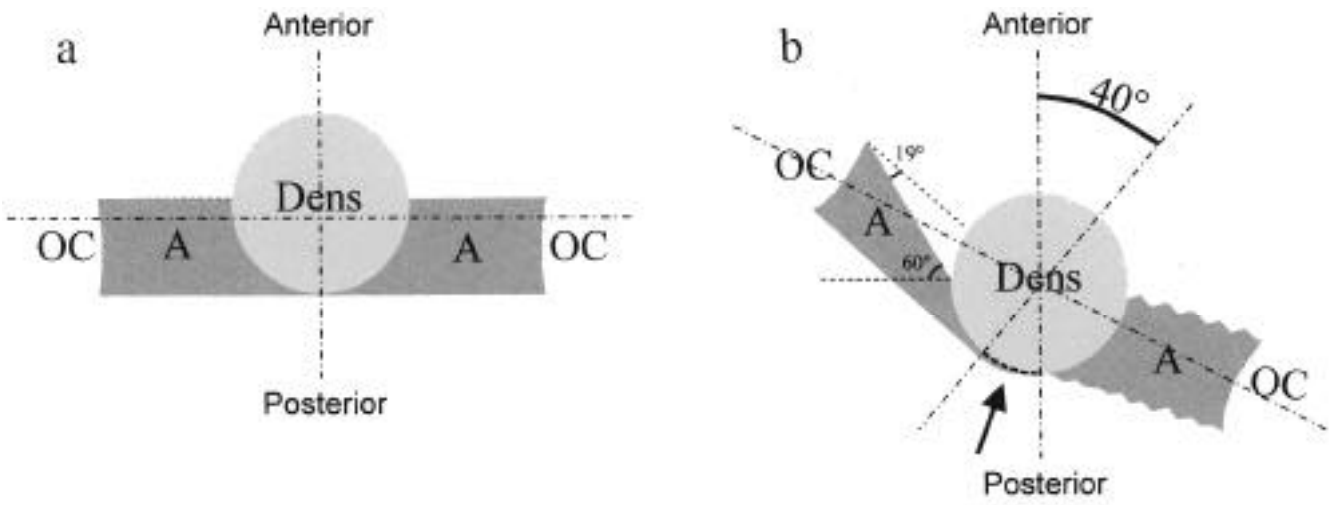

Figure 2. A simple representation of the attachments of the alar ligaments (A) to the dens and occipital condyles (OC) as seen from above, to show the change in the insertional angles of the ligament during head rotation. (a) The ligaments are depicted with the head in the anatomical position (0° rotation). (b) The ligaments are shown with the head rotated clockwise through 40°. While this rotation results in relaxation of the ligament in the direction of rotation, tension is induced in the contralateral ligament, resulting in a 60° change in angle at the odontoid enthesis, but a 19° change at the occipital enthesis. Note that as the head is rotated, the posterior aspect of the tensed ligament is partly wrapped around the dens (arrow).

droitin 6 sulfate was also generally distributed, but enhanced labelling was seen at the entheses. The labelling pattern for aggrecan and link protein typically followed the distribution of collagen type II and was thus most extensive in the posterior aspect of the odontoid enthesis (Figure 1g).

DISCUSSION

Although the presence of fibrocartilage has been reported previously in the alar ligaments[28], this is the first account of differences in the extent of immunohistochemical labelling for molecules typical of fibrocartilage (type II collagen, aggrecan, and link protein) at its 2 entheses. We suggest these differences relate to the insertional angle changes occurring in the alar ligaments during maximal rotation of the head. We have shown that the change is roughly 3 times greater at the dens than at the occipital enthesis. Consequently, the ligament must be subject to greater levels of compression at its attachment to the dens than the skull, and this accounts for the greater prominence of fibrocartilage at the odontoid enthesis. Whether there are also age/sex-related differences in enthesis fibrocartilage is unclear, for insufficient specimens were examined for meaningful comment.

Type II collagen, aggrecan, and link protein are typical of fibrocartilage rather than dense fibrous connective tissue and have been widely reported at numerous tendon and ligament entheses (see review[21]). Aggrecan is the ECM molecule that gives articular cartilage its ability to resist compression[29] and link protein is a small glycoprotein that stabilizes the interaction between aggrecan and hyaluronan[30,31]. Our observation of aggrecan, link protein, and type II collagen raises the possibility that one or more of these molecules could be antigenic targets for an autoimmune response in RA within the alar ligaments. This hypothesis has attracted considerable interest in understanding the etiology of articular cartilage degeneration in RA[15,16,32-35]. The autoimmune concept has also led to the suggestion that similar changes could occur in the transverse ligament of the atlas in patients with RA[27], and evidently the same could apply to the alar ligaments as well. Although we lack any data on molecular changes in the alar ligaments of patients with RA, studies on the extensor tendon of patients undergoing arthrodesis of the proximal interphalangeal joint of the fingers[36] have shown that there is a marked erosion of enthesis fibrocartilage in RA patients and reduced labelling for type II collagen. The prominence of enthesis fibrocartilage can also explain the involvement of the alar ligaments in SpA, for other highly fibrocartilaginous entheses, e.g., the Achilles tendon and plantar fascia, are well known sites of these diseases in the appendicular skeleton[21]. The prominence of fibrocartilage at entheses generally relates to an increased risk of wear and tear, for the fibrocartilage dissipates insertional angle changes gradually away from the bony interface, into the soft tissue of the tendon or ligament[19-21]. Thus, enthesis fibrocartilage reduces stress concentration at the hard tissue interface and plays a role rather like that of a rubber grommet in an electrical plug[37]. Perhaps it is these mechanical implications that stem from the presence of fibrocartilage, rather than the antigenicity of tissue *per se*, that underpin differences in the anatomical predilection for disease between SpA and RA[21].

Stress is also reduced by the flaring of the ligament as it approaches the bone. This is evident both in Figure 1b and from our greater estimates of the cross sectional areas of the

Personal, non-commercial use only. The Journal of Rheumatology Copyright © 2003. All rights reserved.

Downloaded on April 17, 2024 from www.jrheum.org

entheses (50–60 mm^2) compared with data provided by Dvorak, *et al*[22] for the mid-ligament (22 mm^2). The increase in surface area may reflect a divergence of collagen fiber bundles as the ligament approaches the bone, but could also be associated with the presence of a fibrocartilaginous ECM. As entheses serve to reduce stress concentration, it is not surprising that enthesopathies are common among athletes and that their frequency increases with age[21]. Evidence for an age-related increase in wear and tear in the craniocervical ligaments in particular is suggested by the work of Crockard, *et al*[38]. In 5 elderly patients, they found a fibrocartilaginous, extradural mass that mimics a tumour, but which is derived from degeneration of atlantoaxial ligaments. The greater change in insertional angle of the alar ligaments at the odontoid enthesis, and the more extensive labelling for fibrocartilage molecules at this site, suggest that it is more vulnerable to wear and tear during head rotation than the occipital attachment. The prominent labelling for type II collagen and aggrecan at the posterior aspect of the odontoid enthesis may relate to the fact that this region of the ligament is partly wrapped around the dens during maximal head rotation and is thus compressed against the bone (Figure 2). The greater prominence of fibrocartilage at the odontoid compared with the occipital enthesis illuminates the observations of Saternus and Thrun[39] that rotational injuries generally damage the alar ligaments near the dens, but indirect fractures at the base of the skull typically tear the occipital end of the ligament. It may also relate to reports of odontoid erosion in a patient with RA[23] and alar ligament enthesopathy in a patient with a hypertrophic dens, a narrow atlas ring, and associated cervical myelopathy[40]. Not only is fibrocartilage prominent near the apices of the odontoid process (i.e., at the alar ligament attachments), but a cartilaginous periosteum covers the base of the dens where the odontoid peg presses against the transverse ligament[41].

Functional integrity of the transverse and alar ligaments at the molecular level is crucial for maintaining the balance between physiological motion and mechanical stability of the craniocervical junction. Knowledge of the structural details of the ligaments allows improved biomechanical appraisal of physiological and pathological motion patterns of the upper cervical spine.

ACKNOWLEDGMENT

Dissection of the specimen illustrated in Figure 1a was performed by Dr N. Sokolov. The monoclonal antibodies CIICI, 5C6, and 12C5 were obtained from the Developmental Studies Hybridoma Bank maintained by The University of Iowa, Department of Biological Sciences, Iowa City, Iowa, USA, under contract NO1-HD-7-3263 from the NICHD.

REFERENCES

1. Dickman CA, Crawford NR. Biomechanics of the craniovertebral junction. In: Dickman CA, Spetzler RF, Sonntag VKH, editors. Surgery of the craniovertebral junction. New York, Stuttgart: Thieme; 1998:59-80.
2. Zoli A, Priolo F, Galossi A, et al. Craniocervical junction involvement in rheumatoid arthritis: a clinical and radiological study. J Rheumatol 2000;27:1178-82.
3. Castor WR, Miller JD, Russell AS, Chiu PL, Grace M, Hanson J. Computed tomography of the craniocervical junction in rheumatoid arthritis. J Comput Assist Tomogr 1983;7:31-6.
4. Zeidman SM, Ducker TB. Rheumatoid arthritis. Neuroanatomy, compression, and grading of deficits. Spine 1994;19:2259-66.
5. Puttlitz CM, Goel VK, Clark CR, Traynelis VC, Scifert JL, Grosland NM. Biomechanical rationale for the pathology of rheumatoid arthritis in the craniovertebral junction. Spine 2000;25:1607-16.
6. Moskovich R, Crockard HA, Shott S, Ransford AO. Occipitocervical stabilization for myelopathy in patients with rheumatoid arthritis. Implications of not bone-grafting. J Bone Joint Surg Am 2000;82:349-65.
7. Suarez-Almazor ME, Russell AS. Anterior atlantoaxial subluxation in patients with spondyloarthropathies: association with peripheral disease. J Rheumatol 1988;15:973-5.
8. Ramos-Remus C, Gomez-Vargas A, Hernandez-Chavez A, Gamez-Nava JI, Gonzalez-Lopez L, Russell AS. Two year followup of anterior and vertical atlantoaxial subluxation in ankylosing spondylitis. J Rheumatol 1997;24:507-10.
9. Santavirta S, Slatis P, Sandelin J, Lindqvist C, Konttinen YT. Atlanto-axial subluxation in patients with seronegative spondylarthritis. Rheumatol Int 1987;7:43-6.
10. Halla JT, Bliznak J, Hardin JG. Involvement of the craniocervical junction in Reiter's syndrome. J Rheumatol 1988;15:1722-5.
11. Melsom RD, Benjamin JC, Barnes CG. Spontaneous atlantoaxial subluxation: an unusual presenting manifestation of Reiter's syndrome. Ann Rheum Dis 1989;48:170-2.
12. Blau RH, Kaufman RL. Erosive and subluxing cervical spine disease in patients with psoriatic arthritis. J Rheumatol 1987;14:111-7.
13. Lu K, Lee TC. Spontaneous regression of periodontoid pannus mass in psoriatic atlantoaxial subluxation. Case report. Spine 1999; 24:578-81.
14. Smith HP, Challa VR, Alexandra E. Odontoid compression of the brain stem in a patient with rheumatoid arthritis. Case report. J Neurosurg 1980;53:841-5.
15. Ronnelid J, Lysholm J, Engstrom-Laurent A, Klareskog L, Heyman B. Local anti-type II collagen antibody production in rheumatoid arthritis synovial fluid. Evidence for an HLA-DR4-restricted IgG response. Arthritis Rheum 1994;37:1023-9.
16. Kim HY, Kim WU, Cho ML, et al. Enhanced T cell proliferative response to type II collagen and synthetic peptide CII (255-274) in patients with rheumatoid arthritis. Arthritis Rheum 1999; 42:2085-93.
17. Li NL, ZhangDQ, ZhouKY, et al. Isolation and characteristics of autoreactive T cells specific to aggrecan G1 domain from rheumatoid arthritis patients. Cell Res 2000;10:39-49.
18. Myers LK, Higgins GC, Finkel TH, et al. Juvenile arthritis and autoimmunity to type II collagen. Arthritis Rheum 2001; 44:1775-81.
19. Benjamin M, Ralphs JR. Functional and developmental anatomy of tendons and ligaments. In: Gordon SL, Blair SJ, Fine LJ, editors. Repetitive motion disorders of the upper extremity. Chicago: American Academy of Orthopaedic Surgeons; 1995:185-203.
20. Benjamin M, Ralphs JR. Tendons and ligaments — an overview. Histol Histopathol 1997;12:1135-44.
21. Benjamin M, McGonagle D. The anatomical basis for disease localisation in seronegative spondyloarthropathy at entheses and related sites. J Anat 2001;199:503-26.
22. Dvorak J, Schneider E, Saldinger P, Rahn B. Biomechanics of the craniocervical region: The alar and transverse ligaments. J Orthop Res 1988;6:452-61.

Personal, non-commercial use only. The Journal of Rheumatology Copyright © 2003. All rights reserved.

Downloaded on April 17, 2024 from www.jrheum.org

23. Czerny C, Grampp S, Henk CB, Neuhold A, Stiskal M, Smolen J. Rheumatoid arthritis of the craniocervical region: assessment and characterization of inflammatory soft tissue proliferations with unenhanced and contrast-enhanced CT. Eur Radiol 2000; 10:1416-22.
24. Maksymowych WP. Ankylosing spondylitis — at the interface of bone and cartilage [editorial]. J Rheumatol 2000;27:2295-301.
25. Dvorak J, Panjabi M. Functional anatomy of the alar ligaments. Spine 1987;12:183-9.
26. Boszczyk BM, Boszczyk AA, Putz R, Buttner A, Benjamin M, Milz S. An immunohistochemical study of the dorsal capsule of the lumbar and thoracic facet joints. Spine 2001;26:E338-43.
27. Milz S, Schlüter T, Putz R, Moriggl B, Ralphs JR, Benjamin M. Fibrocartilage in the transverse ligament of the human atlas. Spine 2001;26:1765-71.
28. Saldinger P, Dvorak J, Rahn BA, Perren SM. Histology of the alar and transverse ligaments. Spine 1990;15:257-61.
29. Heinegard D, Oldberg O. Glycosylated matrix proteins. In: Royce PM, Steinmann B, editors. Connective tissue and its heritable disorders. New York: Wiley-Liss; 1993:189-209.
30. Doege K, Hassell JR, Caterson B, Yamada Y. Link protein cDNA sequence reveals a tandemly repeated protein structure. Proc Natl Acad Sci USA1986;83:3761-5.
31. Goetinck PF. Link protein. In: Kreis T, Vale R, editors. Guidebook to the extracellular matrix and adhesion proteins. Oxford: Oxford University Press; 1993:68-72.
32. Guerassimov A, Duffy C, Zhang Y, et al. Immunity to cartilage link protein in patients with juvenile rheumatoid arthritis. J Rheumatol 1997;24:959-64.
33. Guerassimov A, Zhang Y, Banerjee S, et al. Autoimmunity to cartilage link protein in patients with rheumatoid arthritis and ankylosing spondylitis. J Rheumatol 1998;25:1480-4.
34. Glant TT, Buzas EI, Finnegan A, Negroiu G, Cs-Szabo G, Mikecz K. Critical roles of glycosaminoglycan side chains of cartilage proteoglycan (aggrecan) in antigen recognition and presentation. J Immunol 1998;160:3812-9.
35. Menge T, Rzepka R, Melchers I. Monoclonal autoantibodies from patients with autoimmune diseases: specificity, affinity and crossreactivity of MAbs binding to cytoskeletal and nucleolar epitopes, cartilage antigens and mycobacterial heat-shock protein 60. Immunobiol 2002;205:1-16.
36. Benjamin M, Ralphs JR, Shibu M, Irwin M. Capsular tissues of the proximal interphalangeal joint: normal composition and effects of Dupuytren's disease and rheumatoid arthritis. J Hand Surg 1993;18B:371-76.
37. Schneider H. Zur struktur der sehnenansatzzonen. Z Anat Entwicklgesch 1956;119:431-56.
38. Crockard HA, Sett P, Geddes JF, Stevens JM, Kendall BE, Pringle JA. Damaged ligaments at the craniocervical junction presenting as an extradural tumour: a differential diagnosis in the elderly. J Neurol Neurosurg Psychiatry 1991;54:817-21.
39. Saternus KS, Thrun C. [Traumatology of the alar ligaments]. Aktuelle Traumatol 1987;17:214-8.
40. Okada K, Sato K, Abe E. Hypertrophic dens resulting in cervical myelopathy: histologic features of the hypertrophic dens. Spine 2000;25:1303-7.
41. Ebraheim NA, Yang H, Lu J, Biyani A, Yeasting RA. Cartilage and synovium of the human atlanto-odontoid joint. An anatomic and histological study. Acta Anat 1997;159:48-56.

Personal, non-commercial use only. The Journal of Rheumatology Copyright © 2003. All rights reserved.

Downloaded on April 17, 2024 from www.jrheum.org