

Acute Synovial Rupture of the Rheumatoid Knee Presenting as a Pretibial Mass: MRI Appearance

TETSUJI YAMAMOTO, MD, Assistant Professor; TAKASHI MARUI, MD, Assistant Professor; TOSHIHIRO AKISUE, MD, Senior Resident; TOSHIKI HITORA, MD, Postgraduate Student; KEIKO NAGIRA, MD, Senior Resident; TERUYA KAWAMOTO, MD, Postgraduate Student; SHINICHI YOSHIYA, MD, Associate Professor; MASAHIRO KUROSAKA, MD, Director and Chairman, Department of Orthopaedic Surgery, Kobe University Graduate School of Medicine, 7-5-1 Kusunoki-cho, Chuo-ku, Kobe 650-0017, Japan. Address reprint requests to Dr. T. Yamamoto. E-mail: yamatetu@med.kobe-u.ac.jp

A 78-year-old man who had had rheumatoid arthritis (RA) for 3 years presented with a 3 month history of increasing right knee pain. Examination revealed diffuse swelling, local warmth, and limitation of joint motion in the right knee. Laboratory data showed C-reactive protein 9.7 mg/dl (normal 0–0.6) and rheumatoid factor of 600 units (normal 0–27). Initial magnetic resonance imaging (MRI) examination of the right knee revealed a distended suprapatellar pouch with hypointensity on T1 weighted images and marked hyperintensity on T2 weighted images, suggesting massive joint effusion (Figure 1). He was treated with multiple joint aspirations and intraarticular corticosteroid injections. Two weeks later, he suddenly developed severe

pain and swelling in the anterior aspect of the right lower leg. Examination at that time revealed diffuse swelling, local warmth, redness, and a palpable mass in the pretibial region (Figure 2). The mass, measuring 3 × 4 cm, was soft, ill-defined, tender, and fluctuant. On palpation, the knee joint effusion reduced. Followup MRI studies revealed a cystic mass in the posteromedial aspect of the proximal tibia, extending to the anterior aspect of the midshaft of the tibia (Figure 3). The mass was attached to the anterior tibial

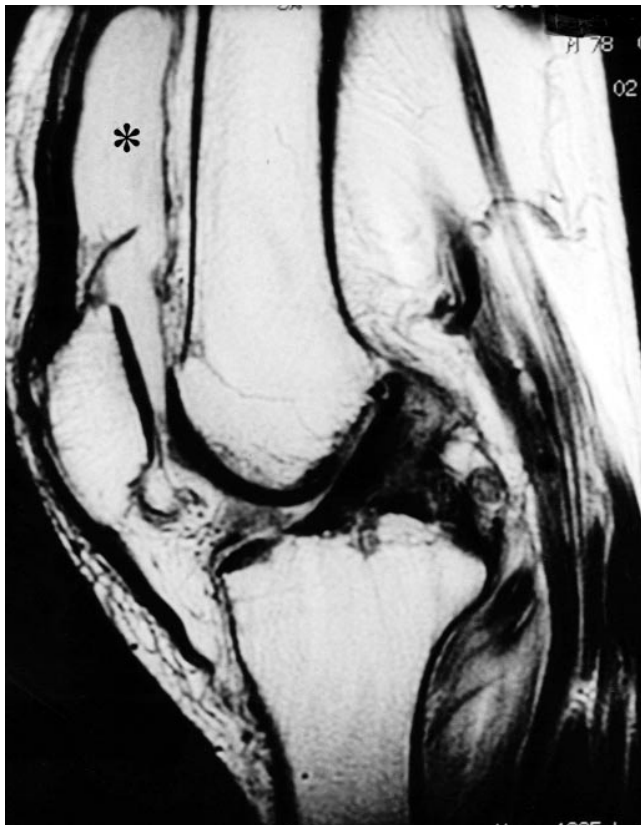

Figure 1. Sagittal T2 weighted MRI scan of the right knee before synovial rupture shows massive joint effusion in the suprapatellar pouch (asterisk).

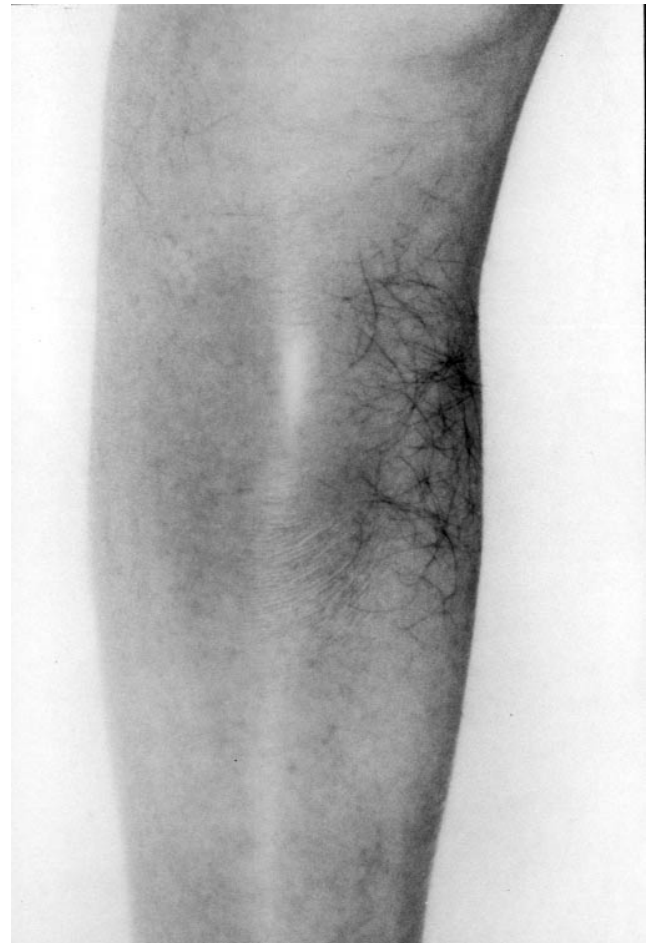


Figure 2. Right leg shows diffuse swelling and redness in the pretibial region.

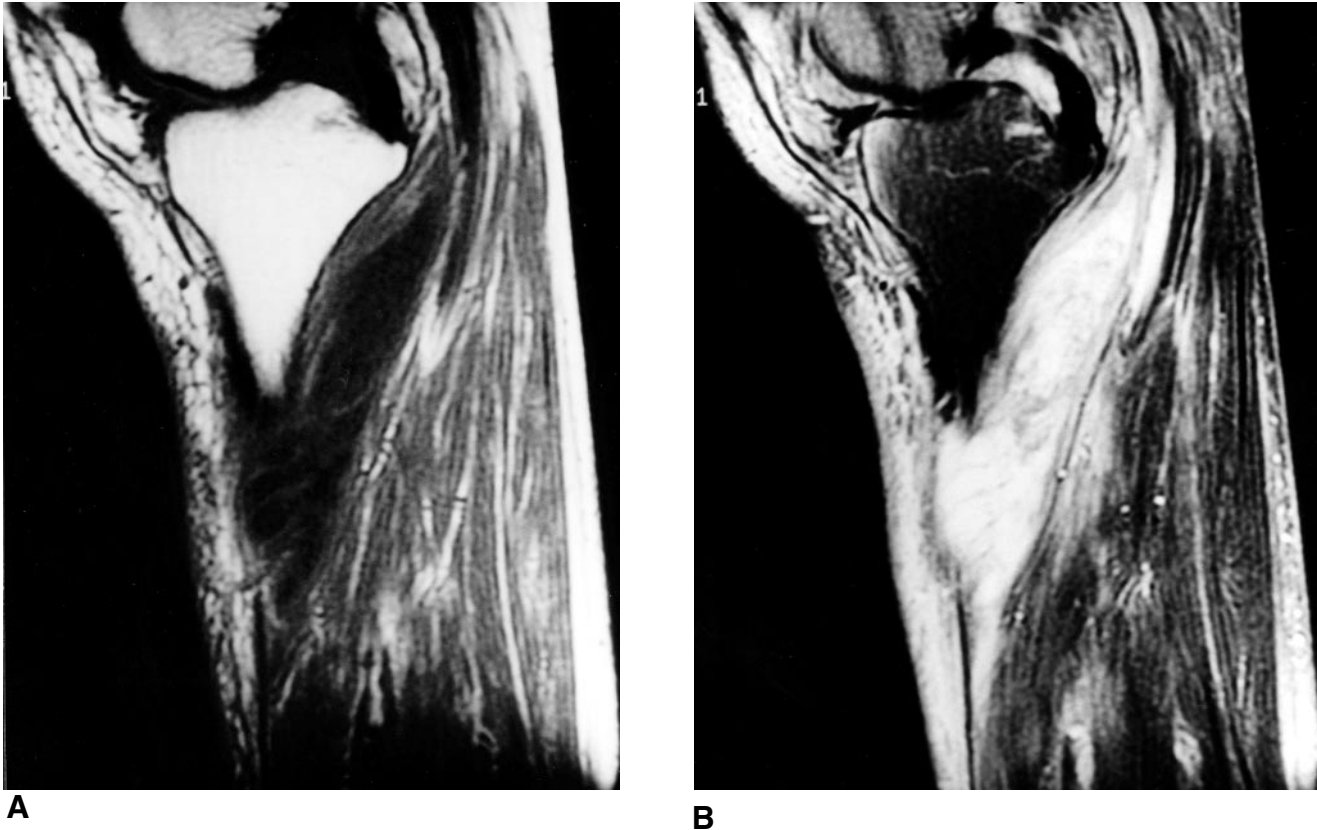


Figure 3. Sagittal MRI scans of the right leg after synovial rupture show wide areas of extravasated joint fluid in the gastrocnemius muscles extending to the anterior aspect of the tibia. The areas show hypointensity on T1 weighted images (A), and marked hyperintensity on T2 weighted fat suppression images (B).

periosteum (Figure 4). T1 weighted images showed the cystic mass to be homogeneously hypointense, and T2 weighted fat suppression images showed the lesion to be markedly hyperintense, containing focal areas with inhomogeneous hypointensity. Aspiration of the mass yielded yellow, turbid fluid containing debris. A histologic specimen of the aspirate showed numerous inflammatory cells and fibrinoid material. Acute synovial rupture of the knee was diagnosed. He was subsequently treated with repeated aspirations of the mass and intralesional corticosteroid injections; 5 mg daily doses of orally administered prednisolone were started. The acute symptoms subsided within the next 4 weeks, and the prednisolone was tapered over 10 weeks. However, the chronic mild knee pain and swelling persisted; this has subsequently been controlled by a nonsteroidal anti-inflammatory drug.

Synovial rupture has been reported in various joint diseases, and is most commonly encountered in RA¹⁻³. The knee joint is most frequently affected¹⁻⁴, and, rarely, the shoulder, elbow, and hand are also involved. The phenomenon occurs in association with persistent, massive joint effusion. When it occurs in the knee, increased intraarticular pressure during exercise of the affected lower limb is considered to result in a posterior capsular tear¹. In most

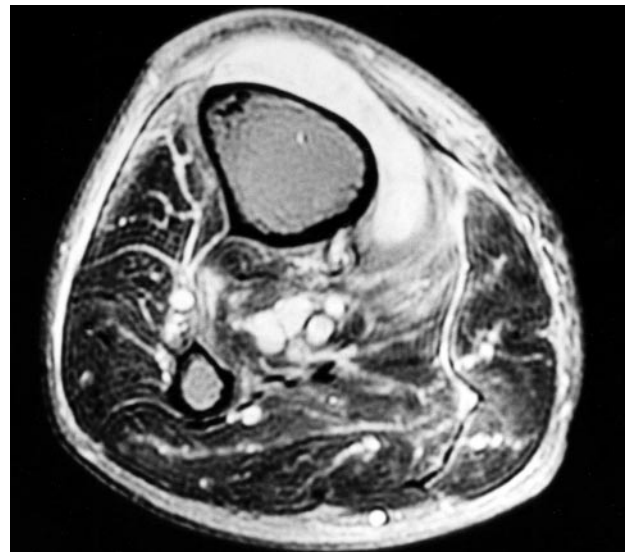


Figure 4. An axial T2 weighted fat suppression MRI scan shows the hyperintense pretibial mass. Diffuse, inhomogeneous hyperintensity is observed in the subcutis and the gastrocnemius and soleus muscles, suggesting inflammatory changes.

cases, synovial rupture of the knee with extrusion of joint fluid into the gastrocnemius muscles causes sudden pain,

swelling, and localized redness of the overlying skin in the calf. These symptoms are often confused with those of deep vein thrombosis in the calf¹⁻⁴. This case is unusual in that synovial rupture of the knee initially manifested as a painful, pretibial mass.

Acute synovial rupture of the knee has traditionally been diagnosed using contrast arthrography or ultrasonography¹⁻³. Contrast arthrography shows diffuse extravasation of contrast medium into the calf^{1,2}. The contrast has a streaky or feathery appearance as it spreads between muscle bundles². Ultrasonography can reveal a popliteal cyst with an attenuated lower margin, suggestive of rupture, and a hypoechoic, superficial fluid collection in the calf³. MRI features of acute synovial rupture in the knee have rarely been described⁴.

In our patient, initial MRI study showed massive joint effusion in the suprapatellar pouch, with no evidence of a distended popliteal cyst. MRI scans performed after synovial rupture revealed wide, markedly hyperintense areas from the posteromedial aspect of the knee to the anterior aspect of the lower leg, consistent with extravasated

joint fluid from the knee. In addition, the surrounding muscular and subcutaneous tissues showed diffuse, inhomogeneous hyperintensity on T2 weighted fat suppression images, suggesting inflammatory changes. Thus, MRI is a noninvasive and sensitive tool in investigating soft tissue pathologies in this condition.

REFERENCES

1. Solomon L, Berman L. Synovial rupture of the knee joint. *J Bone Joint Surg Br* 1972;54:460-7.
2. Rosewarne MD. Synovial rupture of the knee joint: confusion with deep vein thrombosis. *Clin Radiol* 1978;29:417-20.
3. Gompels BM, Darlington LG. Evaluation of popliteal cysts and painful calves with ultrasonography: comparison with arthrography. *Ann Rheum Dis* 1982;41:355-9.
4. Ozgocmen S, Kocakoc E, Kiris A, Ardicoglu O. Pseudothrombophlebitis in a patient with Behcet's syndrome: Doppler ultrasound and magnetic resonance imaging findings. *Clin Rheumatol* 2002;21:60-2.