

Case Report

Bilateral Optic Nerve Sheath Enhancement from Giant Cell Arteritis

KENNETH E. MORGENSTERN, BRIAN D. ELLIS, SIDNEY S. SCHOCHET, and JOHN V. LINBERG

ABSTRACT. An 83-year-old man presented with acute bilateral visual loss to no light perception (NLP) OD and 20/50 OS. His fundus examination showed moderate bilateral pallid disc edema. A sedimentation rate was 60 mm/h. Magnetic resonance imaging of the brain and orbits with gadolinium revealed marked bilateral enhancement of the optic nerve sheaths and adjacent orbital fat. He underwent biopsies of the optic sheath OD and bilateral temporal arteries. Histopathology of the optic nerve sheath area revealed fibroadipose tissue containing numerous arteries with intimal thickening, and mild mural inflammation consisting predominantly of lymphocytes with occasional giant cells. The bilateral temporal artery biopsies revealed focal disruption of the elastic lamina with rare giant cells. His vision had since stabilized on IV methylprednisolone therapy. The biopsies of the nerve sheath suggest that the radiologic finding of optic nerve sheath enhancement in giant cell arteritis is caused by the same pathophysiology, and therefore may be a manifestation of this systemic disease. (J Rheumatol 2003;30:625–7)

Key Indexing Terms:
OPTIC NERVE SHEATH
VISUAL LOSS

GIANT CELL ARTERITIS
OPTIC NEUROPATHY

Acute loss of vision due to arteritic ischemic optic neuropathy can be a devastating condition in which both rapid treatment and accurate diagnosis are essential. Magnetic resonance imaging (MRI) of the orbits may sometimes be included in the investigation of atypical cases. These imaging studies have been reported to show optic nerve sheath and/or optic nerve enhancement in arteritic ischemic optic neuropathy.

We describe a case of bilateral optic nerve sheath enhancement in a patient with temporal arteritis; biopsy of the optic nerve sheath revealed findings consistent with giant cell arteritis (GCA).

CASE REPORT

An 83-year-old white man presented to our clinic with the complaint of bilateral visual loss. Although he was a poor historian, he stated that roughly 6 weeks before, he began having neck pain and consulted a chiropractor. Three weeks later, he awoke from sleep with a slight temperature (101°F) and watery swollen eyes, stating that he “could not see.”

His history was significant for coronary artery bypass surgery in 1994 and chronic anemia. He did not drink or smoke and had no family history of glaucoma or other ocular abnormalities. He was taking no eye medications, but was taking lanoxin and vasotec, as well as an aspirin every day.

From the Departments of Ophthalmology and Neuropathology, West Virginia University Hospitals, Morgantown, West Virginia, USA.

K.E. Morgenstern, MD; B.D. Ellis, MD; J.V. Linberg, MD, Department of Ophthalmology; S.S. Schochet, MD, Department of Neuropathology.

Address reprint requests to Dr. K. Morgenstern, Department of Ophthalmology, West Virginia University Hospital, PO Box 9193, Morgantown, WV 26506. E-mail: Kmorgenstern@hsc.wvu.edu

Submitted April 3, 2002; revision accepted August 30, 2002.

Review of systems failed to reveal any headache, jaw claudication, fatigue, or weight loss.

His ocular examination was significant for a visual acuity of no light perception (NLP) OD and 20/50 OS. Intraocular pressures were 13 mm Hg OD and 12 mm Hg OS (normal 10–20 mm Hg). He had full motility and no significant ptosis of either eyelid. Slit lamp biomicroscopy showed bilateral nuclear sclerotic cataracts. Fundus examination was significant for bilateral pallid disc edema (Figure 1).

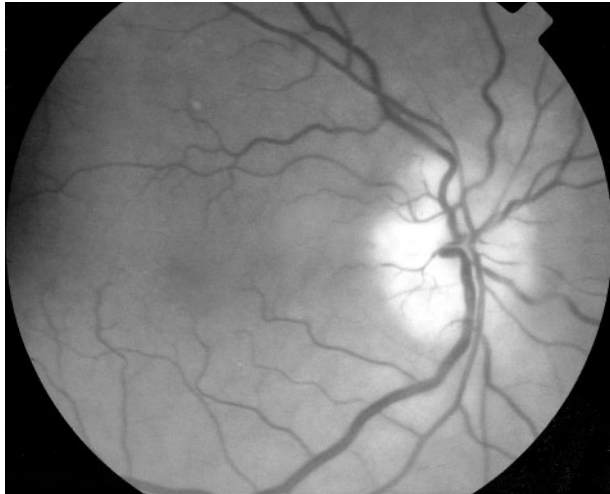A Goldmann visual field performed OS showed a loss of the inferior half of the visual field. A sedimentation rate was 60 mm/h. He was then treated with high dose IV methylprednisolone (250 mg q60) based on a possible diagnosis of temporal arteritis. Despite steroid treatment for 48 h, his visual acuity continued to decrease and was recorded at 20/70 OS. Because he had bilateral pallid disc edema and rapidly progressive loss of vision, an MRI scan was obtained.

MRI of the head and orbits with gadolinium revealed bilateral enhancement of the optic nerve sheaths (Figure 2). A lumbar puncture was performed and revealed a normal opening pressure, normal cerebrospinal fluid composition and cytology, which was negative for malignancy. Serology studies for rapid plasma reagin and microhemagglutination assay-Treponema pallidum were also negative. Given the patient's questionable history for temporal arteritis, lack of response to steroids, and the abnormal MRI images, we decided to obtain an optic nerve sheath biopsy in hopes of establishing a clear diagnosis.

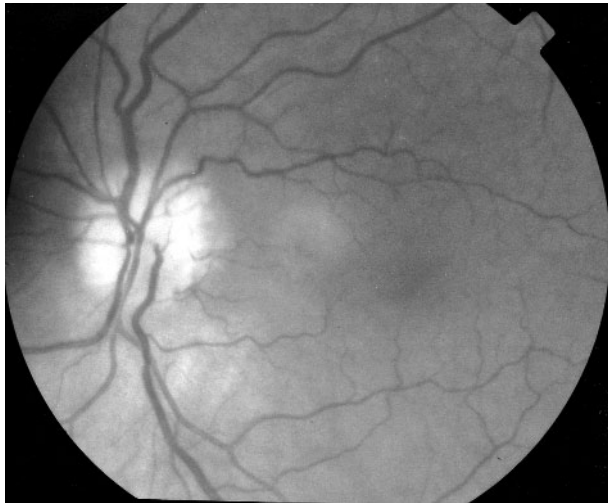Review of the pathology showed giant cells within the tissue specimen (Figure 3). Bilateral temporal artery biopsies were also performed and the diagnosis of GCA was confirmed (Figure 4). The patient's vision stabilized at NLP OD and 20/40 OS. Oral corticosteroids were tapered over the next 18 months. His sedimentation rate normalized with treatment.

DISCUSSION

Kelley, *et al* report that the annual incidence of temporal arteritis ranges from 0.49 to 23.3 per 100,000 persons¹. Traditionally, the diagnosis is based on temporal artery biopsies showing inflammatory changes in the area of the



A



B

Figure 1. Fundus photography was performed for each eye. Examination revealed bilateral pallid disc edema without hemorrhage or retinal detachment (A, right eye; B, left eye).

internal elastic lamina. Lymphocytes and monocytes usually predominate, but giant cells are considered diagnostic. Systemic effects and local findings are most likely a result of narrowing of vascular lumens secondary to intimal edema, and occasional vessel thrombosis. Orbital arteries that are not contained within the optic nerve itself, such as the ophthalmic and posterior ciliary vessels, have a reasonable amount of elastic tissue in their walls, and are thus prone to severe arteritic involvement². This histopathology is probably responsible for the clinical manifestations seen in patients with arteritic ischemic optic neuropathy.

Radiologic abnormalities have been reported in association with GCA, including enhancement of the orbital fat, optic nerve, and/or optic nerve sheath. These findings are thought to result from a breakdown of the blood-brain barrier, as reported in infiltrative, inflammatory, demyelinating, infectious, or even neoplastic conditions³⁻⁶.

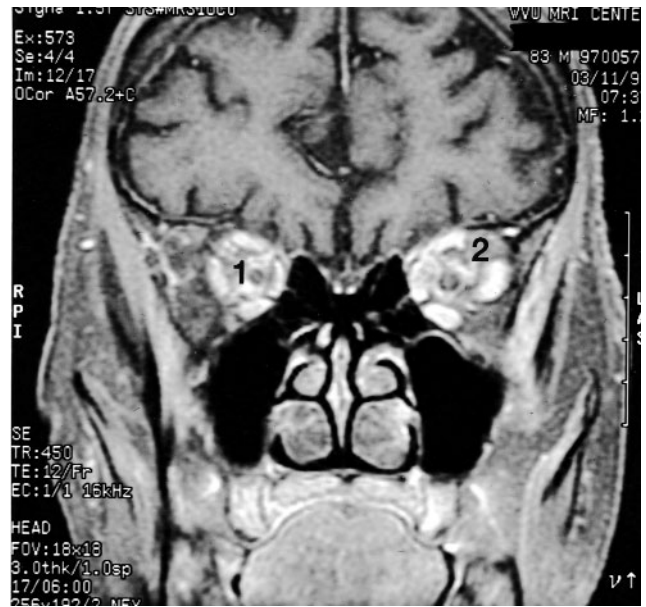

Figure 2. MRI of the brain and orbits was performed with gadolinium and fat saturation. T1 weighted coronal image shows bilateral enhancement of the optic nerve sheaths (1) and adjacent orbital fat (2).

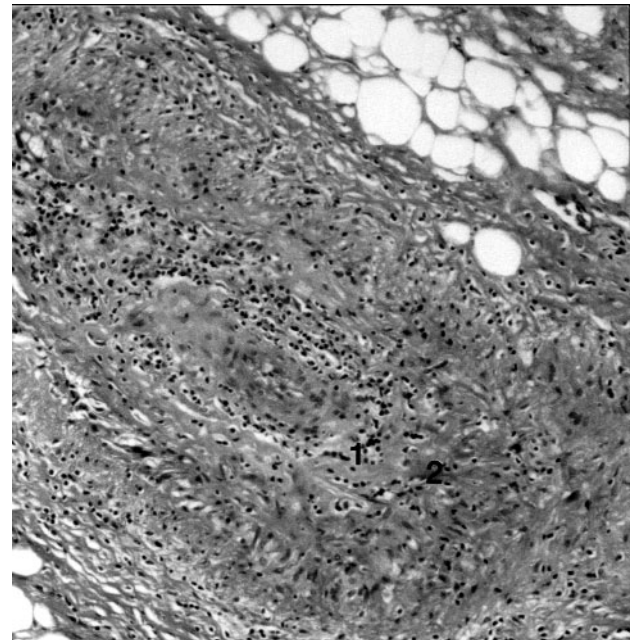


Figure 3. An optic nerve sheath biopsy was performed. The specimen shows an artery with intimal proliferation and pan-mural inflammation including multinucleated giant cells (1) along the partially disrupted elastica (2) (H&E stain; original magnification $\times 150$).

Interestingly, we know of no reported cases of non-arteritic anterior ischemic optic neuropathy (AION) with optic nerve enhancement on MRI scan.

To our knowledge, this is the first report of a biopsy of the optic nerve sheath confirming that GCA may indeed be responsible for optic nerve sheath enhancement on MRI in

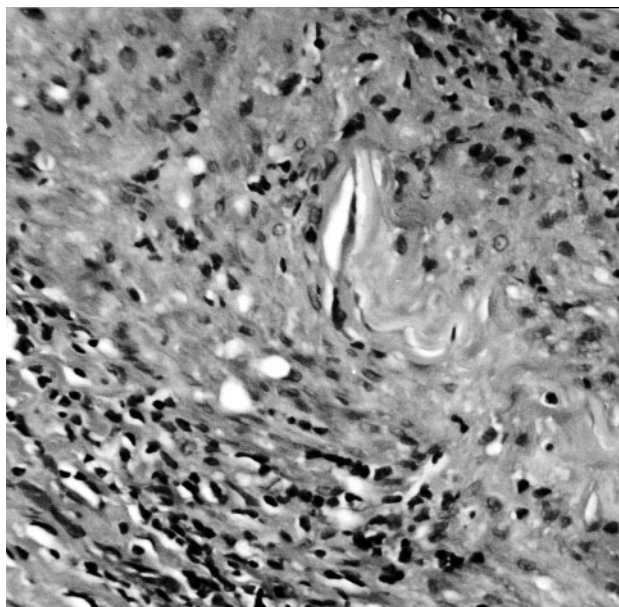


Figure 4. Bilateral temporal artery biopsies were performed; section of the left temporal artery showing multinucleated giant cells along the partially disrupted elastica (H&E stain; original magnification $\times 375$).

the clinical setting of arteritic ischemic optic neuropathy. We are not proposing that MRI should be standard in the investigation of GCA, but in patients with an atypical presentation, the finding of optic nerve sheath enhancement could support the diagnosis of an arteritic rather than non-arteritic ischemic optic neuropathy.

REFERENCES

1. Hunder GG. Giant cell arteritis and polymyalgia rheumatica. In: Kelley WN, Harris ED, Ruddy S, Sledge CB, editors. Textbook of rheumatology. 4th ed. Philadelphia: W.B. Saunders Co., 1993:1103-12.
2. Wilkinson IMS, Russell RWR. Arteries and head and neck in giant cell arteritis: a pathological study to show the pattern of arterial involvement. *Arch Neurol* 1972;27:278-91.
3. Clark AE, Warren H, Victor H. An unusual presentation of temporal arteritis. *Ann Ophthalmol* 1987;19:343-6.
4. Laidlaw DA, Smith PE, Hodgson P. Orbital pseudotumor secondary to giant cell arteritis: an unreported condition. *BMJ* 1990;300:784.
5. Nassani S, Cocio I, Arcuri T, Favale E. Orbital pseudotumor as a presenting sign of temporal arteritis. *Clin Exp Rheumatol* 1995;13:367-9.
6. Lee AG, Eggenberger ER, Kaufman DI, Manrique C. Optic nerve enhancement on magnetic resonance imaging in arteritic ischemic optic neuropathy. *J Neuroophthalmol* 1999;19:235-7.

