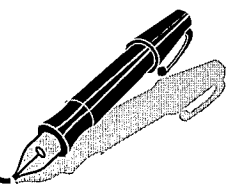


Correspondence



INSTRUCTIONS FOR LETTERS TO THE EDITOR

Editorial comment in the form of a Letter to the Editor is invited; however, it should not exceed 800 words, with a maximum of 10 references and no more than 2 figures (submitted as camera ready hard copy per Journal Guidelines) or tables and no subdivision for an Abstract, Methods, or Results. Letters should have no more than 3 authors. Full name(s) and address of the author(s) should accompany the letter as well as the telephone number, fax number, or E-mail address.

Contact: The Managing Editor, The Journal of Rheumatology, 920 Yonge Street, Suite 115, Toronto, Ontario M6J 3G7, CANADA. Tel: 416-967-5155; Fax: 416-967-7556; E-mail: jrheum@jrheum.com Financial associations or other possible conflicts of interest should always be disclosed.

Local Injections in Polymyalgia Rheumatica

To the Editor:

We read with interest the article by Salvarani and colleagues¹. The authors postulate that shoulder corticosteroid injections seem to be an effective and safe therapy for polymyalgia rheumatica (PMR). They expound that the shoulder bursitis, joint synovitis, and tenosynovitis seen in PMR respond very well to corticosteroid therapy. They also claim that the bicipital tendon, subacromial and subdeltoid bursae, and glenohumeral joint, which are especially affected by the inflammatory process, are communicating synovial structures, so that just a single injection into the glenohumeral joint would be adequate. Moreover, at the very end of the article, it is stressed that the articular and extraarticular synovial structures of the hip are not in communication, in contradistinction to the shoulder, and thus multiple site injections could be required for hip infiltrative corticosteroid therapy.

However, it has already been established that the bursae lie between the rotator cuff (mainly supraspinatus muscle) and the overlying acromion; they do not communicate with the joint^{2,3}. If there is a communication, it implies a complete rupture of the rotator cuff (mainly supraspinatus). Full thickness tears of supraspinatus tendon are found in 7–27% of patients at autopsy⁴. The number of these tears increases with age and PMR can be considered as a disease of the elderly. The incidence of full thickness tears is about 20–30%⁵. Magnetic resonance imaging evaluation of elder asymptomatic patients (60 years of age and above) showed an incidence of 28% full thickness tears⁶. Consequently, the probability of an injection into the joint reaching the subacromial bursa is only one in three patients. Furthermore, in the study by Salvarani, *et al* the patients with MRI reportedly did not show any full thickness tears; however, the injection into the joint still led to the correction of the subacromial bursitis. This brings up the question whether the response is due to the systemic effects of the corticosteroid injection or not. We think that the answer to this question lies in a study that compares the effects of systemic corticosteroid administration, local corticosteroid injection, and multiple site injection, including the subacromial space.

KENAN AKGUN, MD, Department of Physical Medicine and Rehabilitation; ONDER AYDINGOZ, MD, Department of Orthopaedics and Traumatology, Cerrahpasa Medical Faculty, Istanbul, Turkey.

REFERENCES

1. Salvarani C, Cantini F, Olivieri I, et al. Corticosteroid injections in polymyalgia rheumatica: a double blind, prospective, randomized, placebo controlled study. *J Rheumatol* 2000;27:1470-6.
2. Williams PL, Warwick R. Arthrology. In: Williams PL, Warwick R, editors. *Gray's anatomy*. Edinburgh: Livingstone; 1980:420-73.
3. Dalton SE. Shoulder. In: Klippel JH, Dieppe PA, editors. *Rheumatology*. London: Mosby; 1998;4:7.1-14.
4. Grant JCB, Smith CG. Age incidence of rupture of the supraspinatus tendon. *Anat Rec* 1948;100:666-9.
5. Fukuda H, Mikasa M, Yamanaka K. Incomplete thickness rotator cuff tears diagnosed by subacromial bursography. *Clin Orthop* 1987;223:51-8.
6. Sher JS, Uribe JW, Posada A, et al. Abnormal findings on magnetic resonance images of asymptomatic shoulders. *J Bone Joint Surg Am* 1995;77:10-5.

Dr. Salvarani, *et al* reply

To the Editor:

We are grateful to Akgun and Aydingoz for their interesting comment on our paper¹. As they underline, there is an increased incidence in polymyalgia rheumatica (PMR) of rotator cuff tears with aging. In autopsy series rotator cuff defects were observed in 30% of subjects who were in their 50s and 60s, and in 90% to 100% of those who were over the age of 70².

As most of our patients with PMR were in their 70s, a communication between glenohumeral joint cavity and subacromial and subdeltoid bursae was probable. However, as mentioned in our report, we cannot exclude that part of the efficacy of the therapy could be related to the systemic absorption of corticosteroids.

CARLO SALVARANI, MD, Divisione di Reumatologia, Arcispedale S. Maria Nuova, Reggio Emilia; FABRIZIO CANTINI, MD, Unità di Reumatologia, Medicina 2, Ospedale Civile, Prato; IGNAZIO OLIVIERI, MD, Dipartimento di Reumatologia, Ospedale San Carlo, Potenza, Italy.

REFERENCES

1. Salvarani C, Cantini F, Olivieri I, et al. Corticosteroid injections in polymyalgia rheumatica: a double blind, prospective, randomized, placebo controlled study. *J Rheumatol* 2000;27:1470-6.
2. De Palma AF, Callery G, Bennett CA. Variational anatomy and degenerative lesions of the shoulder joint. In: *Instructional course lectures*. Chicago: American Academy of Orthopaedic Surgeons; 1949;6:255-81.

Visual Hallucinations and the Risk of Visual Loss in Patients with Giant Cell (Temporal) Arteritis.

To the Editor:

In a recent issue of *The Journal*, Neshet, *et al*¹ stressed the value of visual hallucinations (VH) as a harbinger of permanent visual loss (PVL) in patients with giant cell arteritis (GCA). These authors found that intermittent VH preceded PVL in 4 out of 5 patients with that severe manifestation. If their finding is confirmed, the report of VH by a patient with suspected GCA will have important implications for ophthalmologic investigation and treatment urgency. We describe our experience based on a large series of patients with GCA, which might clarify the relationship between VH and PVL.

Between 1977 and 2001, we diagnosed 203 patients as having temporal arteritis, including 165 biopsy proven cases. Specifically, patients were asked if they had noticed transient eye manifestations such as pain, visual loss, blurred vision, diplopia, and VH, including dazzling flash, glittering, colored pastille illusions or more complex hallucinations. Date of onset and

duration and recurrence of eye symptoms were also prospectively recorded, using a comprehensive questionnaire. Visual events occurred in 54 patients (27% of cases), including transient symptoms in 39 and PVL in 26 (anterior ischemic optic neuropathy in 23, central retinal artery occlusion in one, and retrobulbar ischemic neuropathy in 2). Only 4 patients improved their vision upon starting glucocorticoid treatment, while 4 became definitively and bilaterally blind. Most of these cases have been published^{2,3}. The figures show the relative frequency of VH and other transient visual symptoms, according to whether the patients developed PVL or not. The most frequently reported type of transient visual symptom was amaurosis fugax (19 cases), followed by VH (14 cases). Transient visual symptoms heralded PVL in 11 patients (42% of cases). The delay to PVL from the first episode of visual symptom ranged from less than one day to 18 days (average 6 days). All 3 patients with VH preceding PVL also recalled at the same time concurrent amaurosis fugax or diplopia. As shown in Table 1 the risk of PVL was significantly associated with a history of transient visual symptoms, amaurosis fugax, more than one type of symptom in the same patient, and symptom recurrence, but not with blurred vision, diplopia, or VH ($p = 0.39$).

Our results confirm the relatively high frequency of VH in patients with GCA, but do not support the value of VH alone as a harbinger of impending PVL. We showed recently, using logistic regression analysis, that the only risk factor for the development of PVL was an elevated blood platelet count, although a history of transient visual ischemic symptoms had marginal significance³. However, a stronger association might have been overshadowed. For example, nonrelapsing, fleeting, or bizarre symptoms may have been underreported or underrecognized by patients, especially those with already impaired vision or memory problems. Moreover, the risk of developing PVL after VH may be underestimated in our series, since many such patients recalled additional amaurosis fugax, blurred vision, or transient diplopia and therefore received prophylactic pulse glucocorticoids. Nevertheless, before the relationship between VH and PVL in patients with GCA is fully elucidated, a thorough ophthalmologic anamnesis, including

Table 1. Value of transient visual ischemic symptoms in predicting permanent loss in 203 patients with temporal arteritis.

| | Permanent Visual Loss, n = 26 | No Permanent Visual Loss, n = 177 | p# |
|------------------------------------|-------------------------------|-----------------------------------|------|
| Transient visual ischemic symptoms | 11 | 28 | 0.01 |
| Amaurosis fugax | 7 | 12 | 0.02 |
| Blurred vision | 2 | 9 | NS |
| Diplopia | 2 | 10 | NS |
| Visual hallucinations | 3 | 11 | NS |
| Eye pain | 1 | 2 | NS |
| More than one type of symptom | 3 | 9 | 0.02 |
| Recurrence of symptoms* | 4 | 8 | 0.01 |

* Identical or new symptom. † Data were missing for 1 patient with PVL and 3 patients with transient visual symptoms alone. # Fisher's exact test. NS not significant ($p > 0.1$).

VH, should be part of the clinical assessment of patients with suspected GCA.

ERIC LIOZON, MD; KIM LY, MD; VÉRONIQUE LOUSTAUD, MD; ELISABETH VIDAL, MD, Professor and Head, Service de Médecine Interne A, Hôpital Universitaire Dupuytren, 87042 Limoges, France. E-mail: eric.liozon@unilim.fr

REFERENCES

1. Neshet G, Neshet R, Rozenman Y, Sonnenblick M. Visual hallucination in giant cell arteritis: association with visual loss. *J Rheumatol* 2001;28:2046-8.
2. Liozon E, Herrmann FR, Jauberteau MO, et al. Facteurs prédictifs de complications céphaliques ischémiques irréversibles au cours de

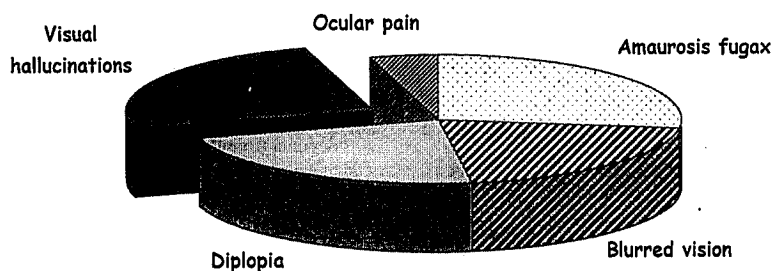


Figure 1. Relative frequency of various transient visual manifestations in 28 patients who did not develop permanent visual loss.

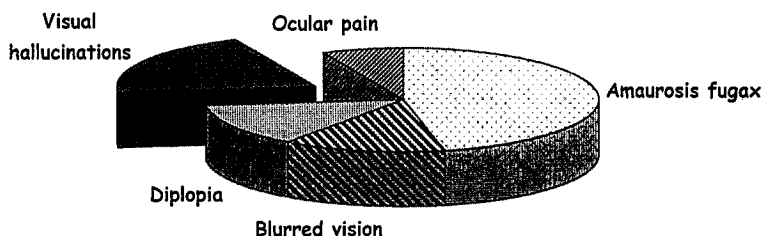


Figure 2. Relative frequency of various transient visual manifestations in 11 patients who developed permanent visual loss.

la maladie de Horton: étude prospective sur 178 patients. *Rev Méd Interne* 2001;22:1-12.

3. Liozon E, Herrmann FR, Ly K, et al. Risk factors for visual loss in giant cell (temporal) arteritis: a prospective study of 174 patients. *Am J Med* 2001;111:211-7.

Dr. Neshet, *et al* reply

To the Editor:

We thank Dr. Liozon and colleagues for their comments and additional data. The main purpose of our report was to draw attention to visual hallucinations being part of the ophthalmologic symptoms associated with giant cell arteritis (GCA), and their letter contributes to this purpose.

In our report, visual hallucinations were common among GCA patients with ophthalmologic manifestation, and preceded visual loss in 4 of them. The data reported by Liozon, *et al* are not in contradiction with our data. They also showed that visual hallucinations occur quite frequently, in 14 of 54 GCA patients with eye symptoms. This figure supports our impression that this phenomenon is much more common than previously estimated. In our experience patients are initially quite reluctant to disclose such information, fearing they would be labeled as "insane," and describe their experience only after establishing good rapport with the physician and being reassured that those visions can be part of their vasculitis.

In Liozon's study visual loss developed in only 3 of the 14 cases that experienced hallucinations, while in our report all 4 patients developed permanent visual loss. This difference is likely to be the result of the therapeutic intervention with steroids: no patient reported by us received steroid treatment prior to the visual loss, while many of the patients reported here received prophylactic pulse glucocorticoids after the initial visual symptom. This explanation is supported by our recent observation of 2 patients presenting with new onset headaches, slight blurring of vision, and visual hallucinations. Prompt treatment with 60 mg/day prednisone resulted in rapid improvement of symptoms and cessation of the hallucinations. No patient developed further visual impairment. Temporal artery biopsies subsequently showed arteritis in both cases.

Both reports suggest that visual hallucinations are not rare in GCA, and along with amaurosis fugax, blurred vision, and diplopia, should be regarded as symptoms necessitating prompt treatment with steroids to prevent irreversible visual loss.

GIDEON NESHER, MD; RONIT NESHER, MD; YAACOV ROZENMAN, MD; MOSHE SONNENBLICK, MD, Shaare-Zedek Medical Center, Jerusalem 91031, and Sapir Medical Center, Kfar-Saba 44281, Israel.

Isolated Tuberculosis Monoarthritis Mimicking Juvenile Rheumatoid Arthritis

To the Editor:

We read with interest the cases of childhood onset tuberculous arthritis presented by Al-Matar, *et al*¹, and would like to report another case that highlights the resurgence of this disease, not only in North America but also in the United Kingdom, Europe, and other areas². This case highlights also the potential for mimicry of more than one type of juvenile idiopathic arthritis (JIA) (formerly juvenile rheumatoid arthritis).

Case history. A 13-year-old UK born Asian girl was referred to our tertiary level pediatric rheumatology unit in July 1998 with a provisional diagnosis from the referring unit of probable JIA, unresponsive to treatment. The relevant history started 6 months previously in January 1998, when she developed persistent pain, swelling, and a decreased range of motion (ROM) of her right elbow joint. Shortly thereafter she developed an abscess in the

right buttock that required surgical drainage and she was treated with flu-cloxacillin at the referring hospital. Over the following 3 months she also progressed to develop pain and swelling of the right shoulder (anterior glenohumeral and acromioclavicular region), discomfort in both knees, and increasing deformity of the right elbow. She was treated with nonsteroidal antiinflammatory drugs with little improvement. In addition to this she developed further series of deep seated abscesses in the left buttock, left thigh, left breast, and a 5 × 5 cm abscess on the scalp. Although she was treated with broad spectrum antibiotics and surgical drainage, healing was slow.

During the 6 months prior to her referral she had a low grade pyrexia and occasional mouth ulcers. Initial investigations at her local pediatric unit showed hemoglobin 9.1 g/dl, white blood cells (WBC) $8.2 \times 10^9/l$, and erythrocyte sedimentation rate (ESR) 131 mm/h. The previous medical history was unremarkable; there was no history of contact with tuberculosis on admission to our hospital (although language difficulties made ascertainment difficult), and she had received Bacillus Calmette-Guérin (BCG) at birth.

On general examination at our unit, she was found to have low grade pyrexia with maximum temperature of 38.5°C, but no lymphadenopathy, rash, oral ulcers, or alopecia. Skin examination revealed a 2 × 2 cm ulcerated area on the right buttock, with healing scars on the thigh, breast, and scalp at the site of previous abscesses. She also had a 3 × 3 cm subcutaneous swelling over the posterolateral aspect of the right thorax (Figure 1). General examination was otherwise unremarkable. On musculoskeletal review she had a markedly swollen and warm right elbow with ROM of only 80°–100° of flexion, indicating a marked fixed flexion deformity. The right acromioclavicular joint was warm and swollen, with painful but full movement of the adjacent glenohumeral joint. The right wrist joint was swollen, with reduced extension, and both knees had small effusions. All other joints including the spine were normal on initial examination.

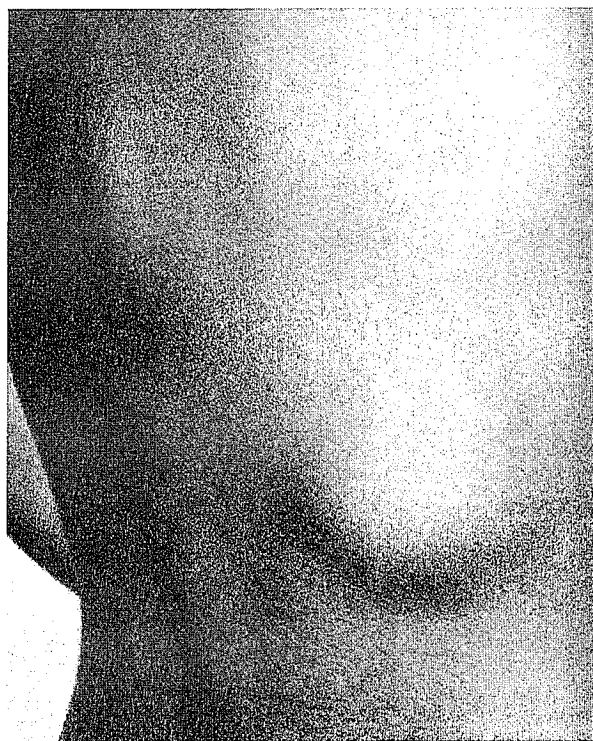


Figure 1. Posterior view of the trunk one week after presentation showing a soft tissue swelling over the posterolateral ribs on the right and a mid-thoracic swelling as well, representing 2 cold abscesses.

The initial working diagnosis in our unit was “partially treated” infectious (septic) arthritis, with multiple associated abscesses. In view of the unusual nature of presentation, other underlying diagnoses were considered, including a primary immune deficiency presenting at an older age, or an evolving autoimmune disease with or without coexistent chronic inflammatory joint disease.

Investigations revealed normocytic normochromic anemia with a hemoglobin of 9.6 g/dl, WBC $8.0 \times 10^9/l$, platelets $211 \times 10^9/l$, elevated acute phase response with both ESR and C-reactive protein significantly elevated to 100 mm/h and 100 μ/l , respectively. Radiographs of the involved joints showed periarticular osteoporosis, reduced joint space, and deformity of subchondral bone (Figure 2). Electrolytes, blood sugar, and renal function were normal and blood cultures were negative. She was negative for rheumatoid factor, antinuclear antibody, extractable nuclear antigen, and dsDNA. Complement levels were normal, as were a lymphocyte subset panel, nitroblue tetrazolium test, and neutrophil adhesion test.

Arthrocentesis revealed frank pus from the right elbow and the right acromioclavicular joint. She thus underwent formal arthrotomy, synovial biopsy, and washout of the 2 involved joints.

A Mantoux test with 1:1000 PPD (purified protein derivative) on day 2 was, however, strongly positive at 23 mm, and antituberculous treatment was started the following day. A chest radiograph was normal. The synovial biopsy revealed multiple tubercular granulomata (Figure 3) and a punch biopsy from the ulcer on the right buttock showed multiple giant cells with epithelioid granulomata. Polymerase chain reaction (PCR) from the pus aspirated from right elbow was positive for *Mycobacterium tuberculosis*, and culture from the elbow and the shoulder was subsequently positive.

The final diagnosis was thus multifocal osteoarticular tuberculosis. It was at this stage the family revealed that the maternal grandmother had had pulmonary tuberculosis in the last year, and indeed that she had been in close contact with our patient! As she had previously received BCG vac-

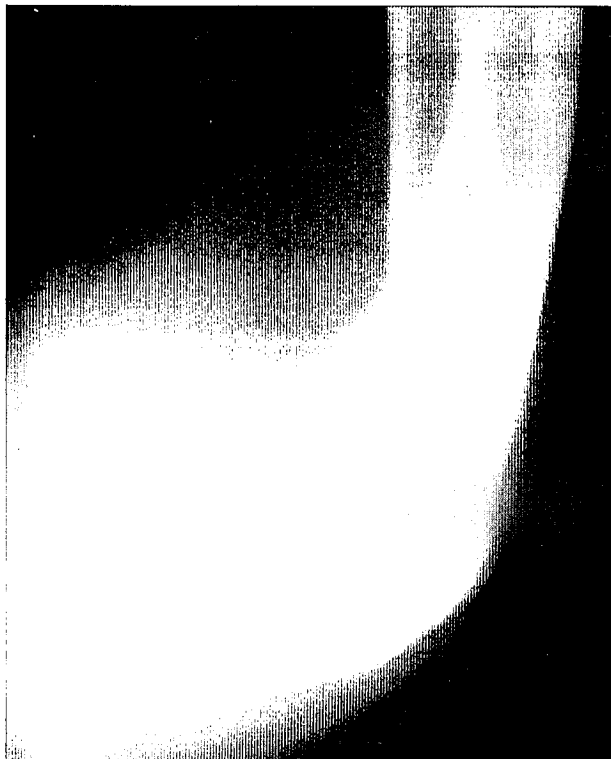


Figure 2. Plain radiograph of the right elbow joint revealing marked abnormalities of the bony contours and density. There is significant soft tissue swelling overlying and enlargement of all bony components of the elbow with some periosteal reaction.

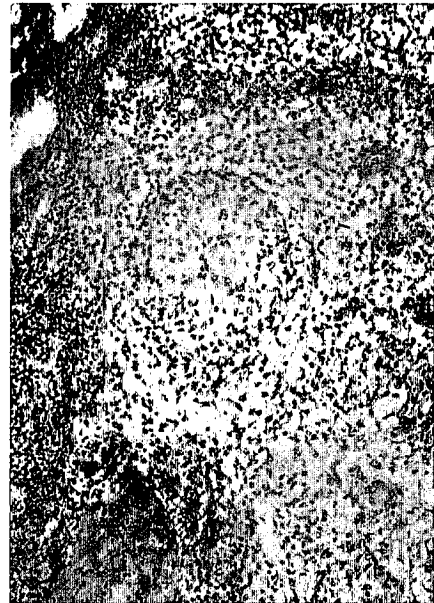

Figure 3. Photomicrograph of synovial tissue from the right acromioclavicular joint at presentation. The histology reveals a typical tubercular granuloma.

nation and had a borderline positive Mantoux test locally she had not been offered prophylaxis as, had the rest of the family.

The patient was started on 4 drug antituberculous therapy, with a combination of isoniazid, rifampicin, pyrazinamide, and ethambutol. In the first 2 months following her treatment she continued to develop new lesions in the form of cold abscesses, including a paraspinous abscess in the thoracolumbar area. She did not have any neurological signs and as magnetic resonance imaging did not reveal cord compression, this was treated conservatively (Figure 4). On followup visits over the next 18 months she showed steady improvement in her general health, resolution of abscesses, and joint disease. When last seen, at 30 months after diagnosis, she was finished all medication and was symptom-free, except for a modest loss of extension of the right elbow joint. She had a normal spine with full ROM, and repeat imaging of the spine was normal.

The co-occurrence of soft tissue involvement and joint disease in this case certainly should be an alert to a possible cause other than the presumption of an idiopathic inflammatory arthritis.

Retrospectively, it is evident that our patient had an atypical age of onset and pattern of joint involvement for JIA. The significant systemic features and the marked inflammatory response, however, might have been suggestive of a systemic onset form of JIA. The lack of a typical rash, lymphadenopathy, or hepatosplenomegaly and the atypical fever pattern would argue against this diagnosis.

Since 1985 there has been an increase in the incidence of osteoarticular tuberculosis reported in Europe and the USA². Bone and joint tuberculosis account for 2–10% of cases of extrapulmonary manifestations of this disease³⁻⁵. The infrequent occurrence of this form of tuberculosis and the lack of pathognomonic signs pose a diagnostic challenge to physicians, often resulting in delayed recognition and treatment⁶. Rheumatological or musculoskeletal manifestations of tuberculosis are many, and range from infection (Pott’s disease, septic or infectious arthritis, subcutaneous abscesses) and immunological reactions (Poncet’s disease, i.e., reactive arthritis, erythema nodosum) to drug induced syndromes such as isoniazid induced systemic lupus erythematosus⁵. The overall osteoarticular pattern of involvement here suggested to us a mixture of both primary osteoarticular TB and the reactive phenomenon called Poncet’s disease (the wrist and knee involvement in particular). The soft tissue abscess may have acted as the

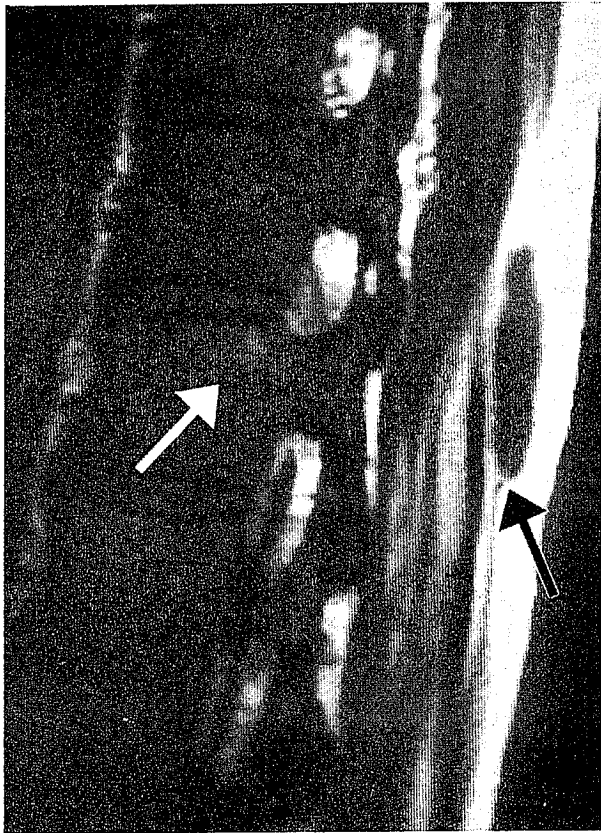


Figure 4. MRI of the midthoracic spine one week after presentation reveals a soft tissue abscess in the superficial planes (black arrow) with extension into the posterior aspect of the vertebral body (white arrow).

visceral component, which is usually associated with this reactive component⁶.

The early occurrence and type of bony involvement, as evidenced on plain radiographs, could be considered unusual for JIA and more typical of an infective or other process. Radiological findings are usually nonspecific and include soft tissue swelling, osteopenia, periarticular bony destruction, and periosteal thickening. Generally these changes are much more rapid than one would see in JIA. Cystic tuberculosis and tubercular dactylitis are being increasingly recognized in childhood, and should be distinguished from pyogenic infections^{3,10,11}. This timing is in contrast to the suggestion by Al-Matar, *et al* that such changes are usually late in tuberculous disease¹. The distribution of joint involvement in our case is also atypical of TB in that it involved predominantly non-weight-bearing joints.

The mean time to diagnosis of patients with osteoarticular TB is reported to be one year⁵ and thus both our case and the reported case¹ could be considered to have been diagnosed relatively early. The arthritis in such patients is said to be monoarticular (or "mono-regional") in 90%, and most commonly affects the spine, followed by weight-bearing joints such as the hip or knee^{7,8}. A changing pattern of osteoarticular tuberculosis has been reported⁹, and such cases can therefore mimic different forms of JIA, including polyarticular and systemic, as in our patient.

Although our patient was unwell she was not "toxic" as might be expected with multifocal septic arthritis. In children the arthritis related to tuberculosis may present acutely, and it is the lack of response to broad spectrum antibiotics that prompts a search for tuberculosis⁶. Our patient had simultaneous involvement of soft tissue areas, discrete from the bony involvement, which have been reported in up to 10% of cases⁵. The absence of pulmonary disease in our case is consistent with its infrequent association with osteoarticular TB^{7,8}.

An elevated ESR, unusual patterns of joint involvement in childhood arthritides, or resistance to initial therapy should prompt the attending physician to consider a Mantoux test to help exclude TB. The test was positive in our patient, as has been previously reported in the majority of children and adults with osteoarticular TB¹⁰.

An elevated ESR and positive Mantoux, while helpful, are neither specific nor completely reliable. The definitive diagnosis of osteoarticular TB requires the identification of *M. tuberculosis* from the site. Optimally the patient should have a synovial biopsy, as histological examination reveals granulomata in 88% of cases, and the culture from tissue is positive in over 90%. Our patient had a positive biopsy and culture and was also smear positive, which has been noted in 25 to 33% of specimens^{9,10}.

PCR techniques are being used increasingly for diagnosis of a number of different conditions that previously relied on laborious culture methods, and in this case provided rapid confirmation of strongly suggestive pathology. As the incidence of multi-drug resistant TB increases, recovery of the specific organism is important, especially if the index case is not identified⁶. Most patients respond well to drug therapy, and surgery is rarely required^{5,12}.

In conclusion, although this case differs from that of Al-Matar, *et al* in several respects, it highlights the increasing diagnostic challenge facing physicians dealing with joint problems in childhood; moreover TB, one of the great "mimics," may appear initially to be one of several different forms of JIA. Vigilance and careful history taking and clinical examination should prompt early recognition, treatment, and an optimal outcome.

SUJATA SAWHNEY, MBBS, MRCP; KEVIN J. MURRAY, MBBS, FRACP, Pediatric Rheumatology Unit, Great Ormond Street Hospital, London, UK.

REFERENCES

1. Al-Matar MJ, Cabral DA, Petty RE. Isolated tuberculous monoarthritis mimicking oligoarticular juvenile rheumatoid arthritis. *J Rheumatol* 2000;27:204-6.
2. Espinal MA, Laszlo A, Simonsen L, et al. Global trends in resistance to antituberculosis drugs. *N Engl J Med* 2001; 344:1294-303.
3. Haygood TM, Williamson SL. Radiographic findings of extremity tuberculosis in childhood: back to the future? *Radiographics* 1994; 14:561-70.
4. Vallejo JG, Ong LT, Starke JR. Tuberculous osteomyelitis of the long bones in children. *Pediatr Infect Dis J* 1995;14:542-6.
5. Kramer N, Rosenstein ED. Rheumatologic manifestations of tuberculosis [review]. *Bull Rheum Dis* 1997;46:5-8.
6. Southwood TR, Hancock EJ, Petty RE, Malleson PN, Thiessen PN. Tuberculous rheumatism (Poncet's disease) in a child. *Arthritis Rheum* 1988;31:1311-3.
7. Zahraa J, Johnson D, Lim-Dunham JE, Herold BC. Unusual features of osteoarticular tuberculosis in children. *J Pediatr* 1996; 129:597-602.
8. Davidson PT, Horowitz I. Skeletal tuberculosis. A review with patient presentations and discussion. *Am J Med* 1970;48:77-84.
9. Singh SB, Saraf SK, Singh LI, Srivastava TP. Osteoarticular tuberculosis in children. *Indian Pediatr* 1992;29:1133-7.
10. Garrido G, Gomez-Reino JJ, Fernandez-Dapica P, Palenque E, Prieto S. A review of peripheral tuberculous arthritis. *Semin Arthritis Rheum* 1988;18:142-9.
11. Berney S, Goldstein M, Bishko F. Clinical and diagnostic features of tuberculous arthritis. *Am J Med* 1972;53:36-42.
12. Yao DC, Sartoris DJ. Musculoskeletal tuberculosis. *Radiol Clin North Am* 1995;33:679-89.
13. Harrington JT. The evolving role of direct amplification tests in diagnosing osteoarticular infections caused by mycobacteria and fungi. *Curr Opin Rheumatol* 1999;11:289-92.
14. Martini M, Ouahes M. Bone and joint tuberculosis: a review of 652 cases. *Orthopedics* 1988;11:861-6.

To the Editor:

We read with interest the letter by Sawhey and Murray describing a child with severe tuberculous arthritis. This diagnosis, recently considered to be a rare event in the developed world, is emerging as a disease to seriously consider in the differential diagnosis of chronic arthritis of childhood.

The patients we reported¹ were very different from the patient described by Sawhey and Murray in that they had monoarthritis and no extraarticular disease. The patient they describe had monoarthritis of the elbow quickly followed by multiple soft tissue abscesses. In hindsight a diagnosis of tuberculous arthritis was likely. (Wouldn't we all like to exchange hindsight for foresight?) The systemic nature of this patient's illness — fever, multiple abscesses, very high erythrocyte sedimentation rate and C-reactive protein — all pointed to an infectious or malignant disease. Our patients were systemically entirely well and looked like oligoarticular juvenile idiopathic arthritis. The indicator that this was not the case was their nonresponsiveness to intraarticular corticosteroids. The difficulty in obtaining a history of exposure to tuberculosis was our experience as well.

It could be argued that the application of a Mantoux test should be a standard practice in dealing with any child with monoarthritis if it is in any way atypical, or in children with atypical polyarthritis, even if there is history of bacillus Calmette-Guérin immunization and denial of exposure to active tuberculosis. We must routinely consider the possibility of tuberculous arthritis in this patient population.

MOHAMMED AL-MATAR, MBBS, FAAP; DAVID A. CABRAL, MBBS, FRCPC; ROSS E. PETTY, MD, PhD, Department of Pediatrics, University of British Columbia, Vancouver BC, Canada.

REFERENCE

1. Al Matar M, Cabral DA, Petty RE. Isolated tuberculous monoarthritis mimicking oligoarticular juvenile rheumatoid arthritis. *J Rheumatol* 2000;27:204–6.



Termination of Disease Modifying Antirheumatic Drugs in Psoriatic Arthritis

To the Editor:

The experience reported by Ujfalussy, *et al* on the use of intramuscular (im) gold, methotrexate (MTX), and sulfasalazine (SSZ) in psoriatic arthritis (PsA) is very interesting¹. The lack of difference between time on treatment, calculated by survival analysis, with im gold and MTX observed in this study, contrasts with the results obtained in our study and with other reports^{2,3}.

It is always difficult to explain differences across studies, even more so when treatment is not randomized and the outcome, treatment discontinuation, could be influenced by practice patterns differing across countries. Also, more information about the clinical characteristics of both treatment groups at baseline, about the treatment doses received, and about the results is needed to explore potential reasons for the differences.

I agree with the authors of the letter that non-random allocation of treatment and the fact that some patients having received MTX had failed either im gold or SSZ, are potential explanations for the difference in results

observed. If the practice pattern during the study was to reserve MTX for more severe cases or cases refractory to other treatments, this could explain why their results with MTX were less favorable than ours. The authors present information at baseline on age, sex, and disease duration, showing a longer disease duration in the MTX group, but no information regarding disease activity or disease severity. If differences exist at baseline, it would be important to control for them in a multivariate regression analysis, such as a Cox regression analysis, to prevent a confounding effect. To assess whether having used MTX after failure with im gold or SSZ in some of the patients may explain a poorer performance with MTX treatment, one could include order of therapy as a covariate in the Cox regression analysis. Both these analyses were performed in our study and showed that baseline characteristics, other than previous DMARD use, and order of therapy were not significant in our sample. Also, not controlling for repeat observations within patients potentially could dampen a true treatment difference, as patients refractory to all treatments provide multiple observations. The Cox regression method we used allowed the data to be stratified according to first or second treatment course.

It appears that the main difference in the survival results between the 2 studies stems from a shorter survival observed by Ujfalussy, *et al* for the group receiving MTX [median survival with MTX was 12 months vs more than 5 years in our study (median survival cannot be calculated in our study since less than 50% discontinued treatment, but at 5 years, 54% remained on treatment); whereas median survival with gold was 12 and 14 months, respectively]. Information on the reason for discontinuation may help understand why this difference was observed. Were there more discontinuations for side-effects? If so, it would be interesting to look for differences in practice patterns when dealing with side effects. Or were there more discontinuations for lack of effect? In which case the doses of MTX used in both studies need to be compared. It has been our clinical impression that patients with PsA tend to require higher doses than patients with rheumatoid arthritis.

Finally, the last question to be raised is whether there was a sufficient number of patients taking MTX followed for 2 or more years to have the necessary power to show a difference between the 2 survival curves. Without confidence intervals or number of subjects at risk at different times, it is difficult to assess the certainty of the estimates of survival at 2 years and beyond. The only indication provided is the size of the downward steps on the survival curve, which suggest that the estimates from 2 years onwards are based on relatively small numbers. In our study, although the survival curves appeared different even within the first year, the 95% confidence interval overlapped. The difference between the 2 survival curves became statistically significant only after 1.5 years.

We agree with the conclusion of the authors, that both MTX and im gold are effective treatments, that gold is a good alternative where MTX fails or is contraindicated, and that SSZ, which was not assessed in our study, is another effective treatment, as shown in other controlled studies^{4,5}.

DIANE LACAILLE, MD, MHS, FRCPC; HOWARD B. STEIN, MD, FRCPC; JANET RABOUD, PhD; ALICE V. KLINKHOFF, MD, FRCPC, Arthritis Research Centre of Canada; University of British Columbia, Vancouver, Canada.

REFERENCES

1. Ujfalussy I, Koo E, Szesztak M. Termination of disease modifying antirheumatic drugs in psoriatic arthritis. *J Rheumatol* 2001;28:682–3.
2. Sparado A, Taccari E, Mohtadi B, Riccieri V, Sensi F, Zoppini A. Life-table analysis of cyclosporine A treatment in psoriatic arthritis: comparison with other disease-modifying antirheumatic drugs. *Clin Exp Rheumatol* 1997;15(6):609–14.
3. Gomez-Vaquero C, Rodriguez-Moreno J, Ros S, Marcos R, Fiter J, Roig Escofet D. Termination of disease-modifying drugs in psoriatic arthritis: study of 109 courses of treatment. *Br J Rheumatol*

4. Dougados M, Van Der Linden S, Leirisalo-Repo M. Sulfasalazine in the treatment of spondyloarthritis: a randomized multicentre, double-blind placebo-controlled study. *Arthritis Rheum* 1995;38: 618-27.
5. Jones G, Crotty M, Brooks P and the Psoriatic Arthritis Meta-analysis Study Group. Psoriatic arthritis: a quantitative overview of therapeutic options. *Br J Rheumatol* 1997;36:95-9.

Myocarditis Associated with Polymyositis Diagnosed by Gadolinium-DTPA Enhanced Magnetic Resonance Imaging

To the Editor:

Cardiac manifestations of polymyositis include congestive heart failure, pericarditis, pulmonary hypertension, mitral valve prolapse, and dissecting aneurysm, and a variety of arrhythmias have been reported^(1,2).

We describe a case of polymyositis manifesting myocardial insult due to myocarditis, suggested by gadolinium diethylenetriaminepentaacetic acid enhanced magnetic resonance imaging (Gd-DTPA MRI) and histologically diagnosed by endomyocardial biopsy.

In November 1998, a 58-year-old man was admitted to hospital due to worsening dyspnea because of congestive heart failure. Symmetric proximal muscle wasting and weakness were found in both upper and lower limbs. Right cardiac catheterization showed moderate pulmonary hyperten-

sion. Laboratory examination showed a marked elevation of serum muscle enzymes: 1000–1200 IU/l creatine phosphokinase (CPK)(normal < 150 IU/l), 12.3 IU/l aldolase (normal 1.7–5.7 IU/l), and 770 ng/ml myoglobin (normal < 60 ng/ml). His condition improved almost one week after drug treatment, and he was discharged.

In January 1999, he was referred to our university hospital for further examination and treatment. On admission, blood pressure was 132/70 mm/Hg and his body temperature was 36.8°C. A chest radiograph showed mild cardiomegaly (cardiothoracic ratio 51.9%). The electrocardiogram showed sinus rhythm (heart rate 77 beats/min), negative T waves in leads I, aVL and V4 through V6, and ST depression in leads V4 through V6. Laboratory studies showed 1827 IU/l CPK (muscle origin, MM band, normal 36–216 IU/l), 5.0 IU/l aldolase (normal 0.5–3.1), 988 ng/ml myoglobin (normal < 73 ng/ml), 0.18 ng/ml troponin T (normal < 0.25 ng/ml), and 14 ng/ml myosin light chain (normal < 2.5 ng/ml). He was in NYHA class II. Gd-DTPA MRI performed 4 days after admission revealed transmural contrast enhancement in the anterior, lateral, and posterior wall in the left ventricle (Figure 1A, 1B).

Electromyography revealed a characteristic myopathic pattern. Left deltoid muscle biopsy specimens showed hyaline degeneration, or severely degenerated single muscle fibers mixed with normal muscle fibers (Figure 1C). An echocardiogram showed left ventricular dilatation and diffuse hypokinetic wall motion of the left ventricle. There was no valvular disease. Cardiac catheterization was hemodynamically normal. Biplane left ventriculograms revealed generalized hypokinesis in the wall motion. The ejection fraction was 34%. Selective coronary angiograms showed normal

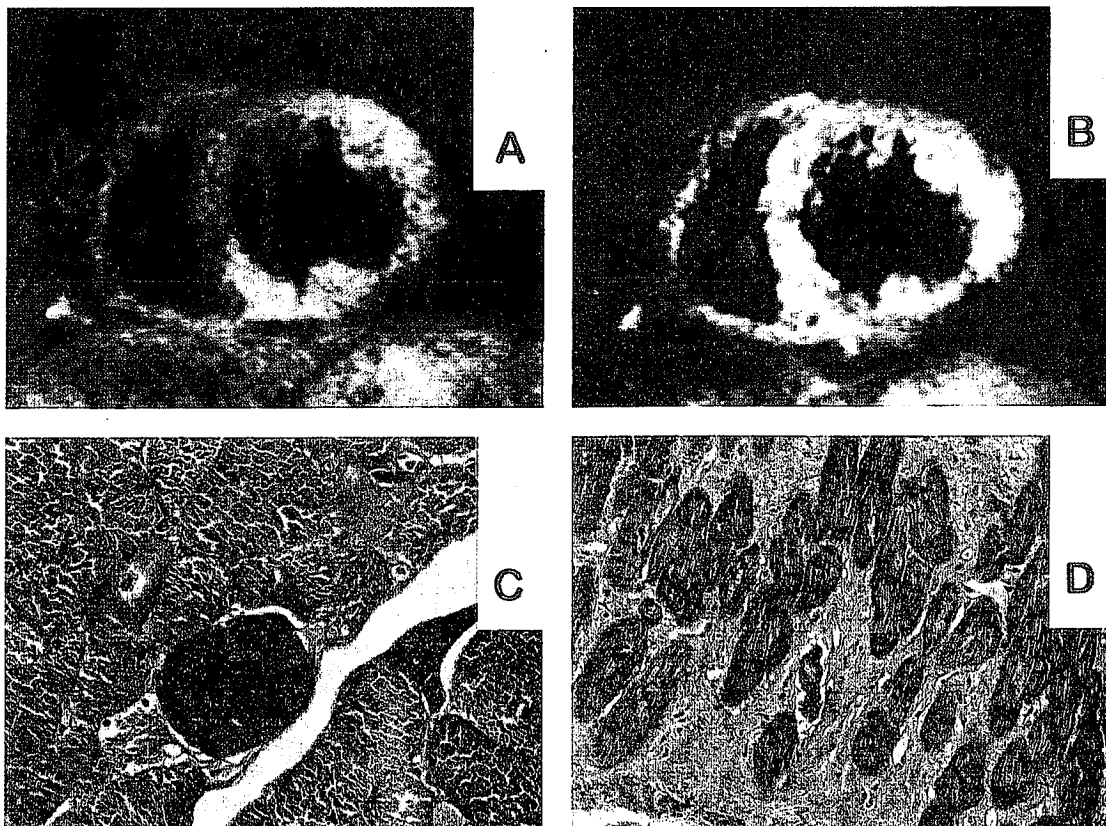


Figure 1. A, B: MRI reveal transmural contrast enhancement in the anterior, lateral, and posterior wall in the left ventricle. C. Left deltoid muscle specimen shows hyaline degeneration or severely degenerated single muscle fibers mixed with normal muscle fibers. D. Left ventricular endomyocardial biopsy specimen shows interstitial fibrosis, edema, cellular cluster, and hypertrophy.

epicardial coronary vasospasm. The left ventricular endomyocardial biopsy specimens showed interstitial fibrosis, edema, cellular cluster, and hypertrophy (Figure 1D).

According to the criteria of Bohan and Peter³, the diagnosis was "probable polymyositis" and the case was diagnosed positive based on the criteria of the Japanese Ministry of Health and Welfare⁴.

We diagnosed this patient had cardiac involvement due to polymyositis. Prednisone 60 mg/day was started. On February 15, 1999, because plasma CPK level was still high (688 IU/l), methotrexate 5 mg/week started from the next day. On February 20, 1999, he committed suicide.

Cardiac involvement is one of the most significant clinical factors associated with a poor prognosis for polymyositis. The incidence of cardiac disease in polymyositis was formerly thought to be low, but careful cardiac evaluation has shown it to be much higher. The incidence has been reported as from 37% to 49% in large series^{5,6}.

Haupt, *et al* reported that pathological evidence of cardiac involvement in patients with polymyositis included active myocarditis, focal fibrosis, vasculitis, intimal proliferation, and medial sclerosis of vessels⁷. On the other hand, Denbow, *et al* demonstrated that some patients have histological findings of active myocarditis and others show replacement fibrosis and small vessel disease in the myocardium⁸. In the present case, the pathological findings included interstitial fibrosis, edema, and degeneration of the contractile band. These findings suggested the presence of myocardial inflammatory damage.

Gd-DTPA MRI has been used to detect myocardial damage from active myocardial inflammation⁹. A study using a rodent myocarditis model has shown that accumulation of Gd-DTPA is observable in myocarditis with ongoing replacement fibrosis, in both the active inflammation and the healing stage, but not in scar tissue¹⁰. We have reported that Gd-DTPA is a helpful tool to detect sarcoid heart, eosinophilic myocarditis, ischemic myocardial injury, and subendocardial damage due to aortic valve stenosis¹¹⁻¹³.

Gd-DTPA MRI shows the extent and location of inflammation and fibrosis of the myocardium more clearly than myocardium more clearly than myocardial scintigraphy and echocardiography. We should therefore take the possibility of cardiac involvement into consideration when treating patients with polymyositis. Our case demonstrates that Gd-DTPA MRI may be a helpful and safe tool and is more specific for the evaluation of myocardial damage than conventional noninvasive techniques.

Gd-DTPA MRI may be a useful screening tool for the diagnosis of myocarditis associated with polymyositis, and can be helpful in providing an appropriate treatment.

SHUZO OHATA, MD; TOSHIO SHIMADA, MD; HIROMI SHIMIZU, MD; YO MURAKAMI, MD; Cardiovascular Division, Fourth Department of Internal Medicine, Shimane Medical University, 89-1, Enya-cho, Izumo, Shimane 693-8501; YOSHIO MATSUNO, Division of Cardiology, Matsue City Hospital, 101 Nada-machi, Matsue, Shimane 690-8509, Japan.

REFERENCES

1. Askari AD. Inflammatory disorders of muscle: Cardiac abnormalities. *Clin Rheum Dis* 1984;10:131-49.
2. Yale SH, Adlakha A, Stanton MS. Dermatomyositis with pericardial tamponade and polymyositis with pericardial effusion. *Am Heart J* 1993;126:997-9.
3. Bohan A, Peter JB, Bowman RL, Pearson CM. Computer-assisted analysis of 153 patients with polymyositis and dermatomyositis. *Medicine* 1977;56:255-86.
4. Nakano K, Tanimoto K, Kano S, Nishitani H, Saito T. Classification criteria for the diagnosis of dermatomyositis and polymyositis. Tokyo: Japanese Ministry of Health and Welfare, Research Committee for the Autoimmune Diseases; 1992:25-8.
5. Hochberg MC, Feldman D, Stevens MB. Adult onset polymyositis/dermatomyositis: and analysis of clinical and laboratory features and survival in 76 patients with a review of the

literature. *Semin Arthritis Rheum* 1986;15:168-71.

6. Henriksson KG, Standstedt P. Polymyositis-treatment and prognosis: a study of 107 patients. *Acta Neurol Scand* 1982;65:280-300.
7. Haupt HM, Hutchins GM. The heart and cardiac conduction system in polymyositis-dermatomyositis: A clinicopathologic study of 16 autopsied patients. *Am J Cardiol* 1982;50:998-1006.
8. Denbow CE, Lie JT, Tandcredi RG, Burch TW. Cardiac involvement in polymyositis: A clinicopathologic study of 20 autopsied patients. *Arthritis Rheum* 1979;27:1088-92.
9. Friedrich MG, Strohm O, Schulz-Menger J, *et al*. Contrast media enhanced magnetic resonance imaging visualizes myocardial changes in the course of viral myocarditis. *Circulation* 1998;97:1802-9.
10. Aso H, Takeda K, Ito T, *et al*. Assessment of myocardial fibrosis in cardiomyopathic hamsters with gadolinium-DTPA enhanced magnetic resonance imaging. *Invest Radiol* 1998;33:22-32.
11. Shimada T, Shimada K, Sakane T *et al*. Diagnosis of cardiac sarcoidosis and evaluation of the effects of steroid therapy by gadolinium-DTPA-enhanced magnetic resonance imaging. *Am J Med* 2001;110:520-9.
12. Kitamura J, Shimada T, Murakami Y, *et al*. Gadolinium-DTPA-enhanced magnetic resonance imaging and functional outcome in patients with acute myocardial infarction. *Jpn Circ J* 1999;63:453-8.
13. Ochiai K, Ishibashi Y, Shimada T, *et al*. Subendocardial enhancement in gadolinium-diethylene-triamine-pentaacetic acid-enhanced magnetic resonance imaging in aortic stenosis. *Am J Cardiol* 1999;83:1443-6.

Ultrasound Imaging — a Requirement for Rheumatologists

To the Editor:

In an editorial entitled "Ultrasound imaging: A rheumatologist's dream" I speculated on the impact ultrasonography could have in rheumatologic training¹. While on the one hand my dream has recently come true, I have also learned that it was no dream at all but ignorance of what is going on in European rheumatology.

My dream was realized when I attended a workshop organized by Dr. Antonio Reginato from The Cooper Health System and the Division of Rheumatology, UMDNJ/Robert Wood Johnson Medical School at Camden, New Jersey, to honor the late Dr. Joseph L. Hollander. The workshop, "Cutting Edge Diagnostic Techniques and Invasive Rheumatology for the Millennium," took place just before the 2000 American College of Rheumatology Meeting in October in Philadelphia. There were 2 eight-hour sessions devoted to arthroscopy, 2 eight-hour sessions on musculoskeletal ultrasound, plus an eight-hour session on synovial infiltrations, subcutaneous fat aspiration, skin biopsy, salivary gland biopsy, needle muscle biopsy, anterior iliac crest biopsy, and capillaroscopy. Although I did not attend the arthroscopy sessions those who did were delighted with the hands-on approach in realistic plastic models under the authoritative guidance of Drs. Gil A. Reyes and Angel Checa from Havana, Cuba, and Robert W. Ike from Ann Arbor, Michigan. The ultrasound sessions, which I attended, allowed participants to perform a full upper and lower extremity joint ultrasound in healthy persons plus selected joints in patients with inflammatory joint disease. The superb instructors included Drs. Esperanza Naredo and Jacqueline Uson from Madrid, Spain, Antonio Bouffard from Detroit, Michigan, and Walter Grassi from Ancona, Italy. Please note that of the 4 ultrasound instructors one was an American radiologist while the 3 European instructors were rheumatologists with ample experience in musculoskeletal ultrasonography. This session obviously did not make us ultrasonographers, but was enticing enough to send us back trying to figure how to get hold of an ultrasound machine and start exploring the soft tissues. Lecturers in the third session included Drs. Warren R. Heymann, Joseph V.

Campelone, Gerald Falasca, and Antonio J. Reginato from Camden, New Jersey, and Drs. Mary-Carmen Amigo and myself from México City, México. Thanks to Dr. Reginato's enterprise this session allowed attendants to practice synovial needle placement using realistic plastic models with an internal sensor that indicated accurate placement, and a hands-on true-cut muscle biopsy session in which attendants tried their hand on a Purdue turkey! Truly, I have never seen a workshop like this, in which the fuzzy fringes of our specialty were probed with vigor and knowhow.

That my ultrasonography dream was only ignorance I learned from our European instructors. At present, to qualify as a rheumatologist in Italy one has to provide evidence of having performed 200 ultrasonic examinations plus 200 capillaroscopic examinations. Ultrasound proficiency is also required in Austria, Germany, and Switzerland. Work is in progress to require ultrasonography proficiency in other European countries.

There is no question that emphasis on biology and experimental medicine, and more recently clinical epidemiology, has built the greatness of rheumatology in the New World. However, to fulfill our duty as specialists in diseases of the musculoskeletal system (which comprise about 30% of our day to day practice) we must become proficient in musculoskeletal medicine. To this end, musculoskeletal ultrasonography provides an unmatched medium. Dr. Reginato's far-seeing, successful workshop should be replicated and expanded by American (in the broad sense) academic rheumatology. The 3 workshop sessions on ultrasonography featured at the San Francisco ACR meeting with a German instructor, Prof. Wolfgang Schmidt, and the musculoskeletal ultrasound study group, represent steps in the right direction.

JUAN J. CANOSO, MD, ABC Hospital, México City, México. E-mail: juan123canoso@prodigy.net.mx

REFERENCE

1. Canoso JJ. Ultrasound imaging: A rheumatologist's dream [editorial]. *J Rheumatol* 2000;27:2063-4.

Canadian Consensus Conference on Hydroxychloroquine

To the Editor:

In the December 2000 issue the report of the Canadian Consensus Conference on hydroxychloroquine, chaired by Dr. John Esdaile, was published. One of the key recommendations was the need to develop up-to-date "patient friendly" information to meet the needs of consumers. In followup to this recommendation, a consumer led workshop was held recently that included representatives of the Canadian Rheumatology Association, Canadian Pharmacists Association, Canadian Ophthalmology Society, Canadian Paediatric Rheumatology Association, Motherisk Canada, Lupus Canada, Canadian Arthritis Patient Alliance, The Arthritis Society, and Health Canada.

In keeping with emerging Therapeutic Products Directorate guidelines, the patient information drafted by this group will be submitted to Health Canada for inclusion in the hydroxychloroquine product monograph that is currently being developed between Health Canada and the manufacturer.

This group process represented an effective prototype for the development of information that will meet the needs of patients and consumers.

CHERYL L. KOEHN, Chair, Workshop Group, Information to the Patient and Physician on Hydroxychloroquine, ACE Planning & Consulting Inc., 4038 West 38th Avenue, Vancouver, BC V6N 2Y9, Canada.
E-mail: cherylkoehn@telus.net

Corrections

Patberg WR, Rasker JJ. Beneficial effect of being outdoors in rheumatoid arthritis [letter]. *J Rheumatol* 2002;29:202-4. Labels identifying time periods were omitted from Figure 1, and are printed correctly here. We regret the error.

Lee YH, Kim YR, Ji JD, Sohn J, Song GG. p53 codon 72 polymorphism and rheumatoid arthritis. *J Rheumatol* 2001;11:2392-4. Acknowledgment of support for this article by a grant from the Korea Ministry of Health and Welfare was omitted. We regret the error.

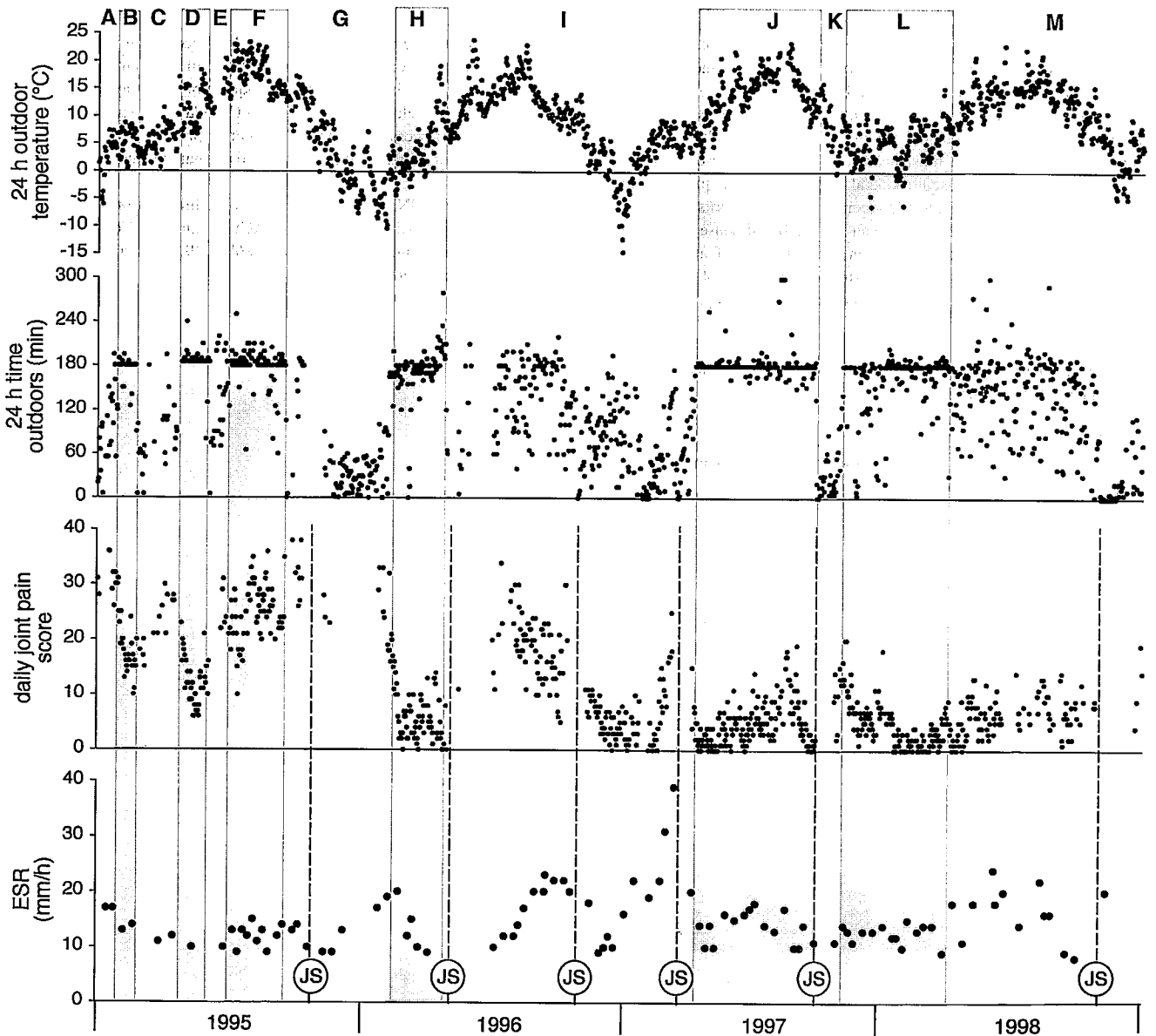


Figure 1. Plot of 24 hour mean outdoor temperature, time outdoors per 24 hours, daily joint pain score, and ESR. Periods during which the daily time outdoors was about 3 hours are shaded. Broken lines (JS) indicate days on which joint surgery was carried out.