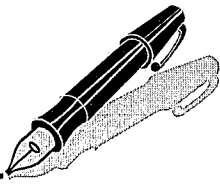


Correspondence



INSTRUCTIONS FOR LETTERS TO THE EDITOR

Editorial comment in the form of a Letter to the Editor is invited; however, it should not exceed 800 words, with a maximum of 10 references and no more than 2 figures (submitted as camera ready hard copy per Journal Guidelines) or tables and no subdivision for an Abstract, Methods, or Results. Letters should have no more than 3 authors. Full name(s) and address of the author(s) should accompany the letter as well as the telephone number, fax number, or E-mail address.

Contact. The Managing Editor, The Journal of Rheumatology, 920 Yonge Street, Suite 115, Toronto, Ontario M6J 3G7, CANADA. Tel: 416-967-5155; Fax: 416-967-7556; E-mail: jrheum@jrheum.com Financial associations or other possible conflicts of interest should always be disclosed.

Helicobacter pylori Infection in Rheumatoid Arthritis

To the Editor:

We read with great interest the letter by Danese, *et al* concerning the high serological positivity of *Helicobacter pylori* type I virulent strains carrying the cytotoxin associated gene A (*cagA*) in patients with systemic sclerosis infected by *H. pylori*¹. The authors suggested that pathogenetic effects of *H. pylori* positive CagA strains might influence clinical status slowly over the long term, rather than abruptly as in peptic ulcer disease. In particular, *H. pylori* infection might be a potential trigger of inflammation.

On the other hand, it has long been postulated that some infectious agents may be responsible, at least in part, for the worsening of the course of some autoimmune diseases, such as systemic sclerosis and rheumatoid arthritis (RA). In addition, chronic gastritis is also frequently found in patients with RA and is often associated with *H. pylori* infection, which is characterized by a generalized increase in cytokine production².

In light of these observations, we describe our experience concerning the prevalence of *H. pylori* in relation to the course of disease activity in patients with RA.

We studied 52 patients fulfilling the 1987 American Rheumatism Association criteria for adult RA (42 women, 10 men)³. These patients had dyspeptic symptoms such as upper abdominal pain, nausea, vomiting, and epigastric pyrosis. They underwent esophagogastroduodenoscopy after overnight fast and were grouped as *H. pylori* positive and negative patients on the basis of both CLO test and histology on 3 antral and 2 fundus biopsies performed at the beginning of the study. All patients with histological evidence of chronic gastritis and *H. pylori* infection were treated with *H. pylori* eradication therapy. The success of treatment was evaluated on the basis of negative results of CLO test and histology on antral and fundus biopsies performed at least 4 weeks after stopping therapy. Patients were treated with antiinflammatory and disease modifying antirheumatic drugs and/or with prednisolone or its equivalent, which did not exceed 7.5 mg/day, and were stabilized for at least 6 months.

Patients with RA were evaluated before enrollment and during a 4 month followup period, comparing clinical and laboratory findings for evaluation of disease activity. Clinical variables included tender and swollen joint counts (28 joint evaluation), visual analog scale (VAS) on a 10 cm horizontal line for measurement of pain, duration of morning stiffness, and functional ability assessed by the Health Assessment Questionnaire (HAQ). Other laboratory findings included erythrocyte sedimentation rate (ESR), levels of C-reactive protein (CRP), and fibrinogen. Statistical analysis was carried out by Friedman test and Kruskal-Wallis nonparametric ANOVA test. The level of significance was set at $p < 0.05$.

H. pylori infection was present in 34 patients. There were no significant differences in sex, age, height, weight, duration of disease, or disease activity between RA infected and uninfected patients at start of study. Twenty-two of the 34 *H. pylori* positive patients had the bacterium eradicated after treatment. The 12 patients unresponsive to the eradicating therapy were not considered in this study. The 10 *H. pylori* positive RA patients, who did not consistently take therapy against the bacterium, were considered as a control group. Patients in whom *H. pylori* was eradicated were found to have a significant improvement of clinical and laboratory variables after eradication, compared to *H. pylori* negative and positive patients (see Table 1).

Our results suggest that persistent *H. pylori* infection may influence the course of RA, probably through activation of the inflammatory cascade secondary to the antigenic stimulus induced by the presence of the bacterium, in agreement with the conclusions of Danese, *et al*¹. Indeed, after *H. pylori* eradication, patients with RA had a significant improvement in both clinical and laboratory variables compared to *H. pylori* negative patients and the control group of untreated *H. pylori* positive patients. In addition, our findings confirm previous observations showing an association between presence of *H. pylori* and autoimmune diseases such as Raynaud's syndrome, Sjögren's syndrome, and RA⁴⁻⁶.

If these data are confirmed in the subsequent followup, eradication of *H. pylori* should be strongly recommended in patients with RA who are infected with *H. pylori*.

University of Genova,
Genova, Italy.

Bruno Seriola, MD;
Maurizio Cutolo, MD;
Patrizia Zentilin, MD;
Vincenzo Savarino, MD.

REFERENCES

1. Danese S, Zoli A, Cremonini F, Gasbarrini A. High prevalence of *Helicobacter pylori* type I virulent strains in patients with systemic sclerosis. *J Rheumatol* 2000;27:1568-9.
2. Gasbarrini A, Franceschi F, Armuzzi A, et al. Extradigestive manifestations of *Helicobacter pylori* gastric infection. *Gut* 1999; 45 (Suppl 1) 9-12.
3. Arnett FC, Edworthy SM, Bloch DA, et al. The American Rheumatism Association 1987 revised criteria for the classification of rheumatoid arthritis. *Arthritis Rheum* 1988;31:315-24.
4. Gasbarrini A, Serricchio M, Tondi P, Gasbarrini G, Pola P. Association of *Helicobacter pylori* with primary Raynaud phenomenon. *Lancet* 1996;348:966-7.
5. Aragona P, Magazzù G, Macchia G, et al. Presence of antibodies against *Helicobacter pylori* and its heat-shock protein 60 in the serum of patients with Sjögren's syndrome. *J Rheumatol* 1999;26:1306-11.
6. Zentilin P, Savarino V, Garnerò A, Accardo S, Seriola B. Is *Helicobacter pylori* infection a risk factor for disease severity in rheumatoid arthritis? *Gastroenterology* 1999;2:503-4.

Table 1. Clinical and laboratory variables at baseline and at 4 month control. Values are shown as mean \pm SD.

	<i>H. pylori</i> Positive		<i>H. pylori</i> Negative (n = 22)	p*	p [†]
	Eradicated (n = 20)	Not Eradicated (n = 10)			
ERS (mm/h)					
Baseline	48 \pm 17	42 \pm 14	47 \pm 9	0.001	0.009
After 4 mo	29 \pm 11	34 \pm 19	39 \pm 16		
CRP (mg/l)					
Baseline	40 \pm 29	35 \pm 26	39 \pm 24	0.03	0.03
After 4 mo	23 \pm 20	31 \pm 25	32 \pm 18		
Fibrinogen (mg/dl)					
Baseline	454 \pm 46	425 \pm 47	436 \pm 50	0.04	NS
After 4 mo	398 \pm 46	401 \pm 51	404 \pm 61		
Morning stiffness (min)					
Baseline	107 \pm 37	118 \pm 45	100 \pm 46	0.008	0.0007
After 4 mo	63 \pm 17	97 \pm 49	87 \pm 40		
Pain (VAS, mm)					
Baseline	63 \pm 10	61 \pm 12	61 \pm 9	NS	NS
After 4 mo	51 \pm 12	56 \pm 13	54 \pm 12		
Tender joint count					
Baseline	18.9 \pm 4.7	18.8 \pm 3.9	18.8 \pm 4.5	0.08	0.007
After 4 mo	15.5 \pm 5.1	16.8 \pm 5.1	17.1 \pm 4.9		
Swollen joint count					
Baseline	16.7 \pm 4.4	16.9 \pm 3.2	17.7 \pm 3.9	0.004	0.001
After 4 mo	12.9 \pm 3.4	15.1 \pm 3.5	15.9 \pm 4.1		
HAQ					
Baseline	1.17 \pm 0.28	1.09 \pm 0.24	1.18 \pm 0.31	0.01	0.02
After 4 mo	0.93 \pm 0.19	0.96 \pm 0.23	1.02 \pm 0.33		

*comparison of *H. pylori* positive patients in whom infection was eradicated vs not eradicated; [†]comparison of *H. pylori* positive patients in whom infection was eradicated vs *H. pylori* negative patients. ERS: erythrocyte sedimentation rate. CRP: C-reactive protein. HAQ: Health Assessment Questionnaire. NS: not significant.

Drs. Danese and Gasbarrini reply

To the Editor:

Seriolo, *et al* focus on a possible role for *Helicobacter pylori* in the pathogenesis of rheumatoid arthritis, reporting significant improvement in disease activity variables in patients treated for *H. pylori* infection during a 4 month followup. The study is intriguing and adds a new clue to other studies that have recently hypothesized a role of *H. pylori* in some diseases outside the digestive tract^{1,2}. However, the exact role of the bacterium in the pathogenesis of autoimmune diseases remains unclear. One hypothesis for the pathway is that *H. pylori*, responsible for a chronic persistent infection, causes a longlasting stimulation of both the gastric and extragastric immune system. In particular, the more virulent strains carrying the cytotoxic associated gene A (*cagA*) have been reported to induce an intense mucosal reaction that is associated with higher degrees of gastric inflammation and increased mucosal levels of cytokines^{3,4}. This robust activation of the immune system could, in susceptible subjects, play a role in increasing and/or maintaining autoimmune disease activity. An alternative hypothesis is the development of a cross-mimicry between bacterium and host antigens; in particular, studies have found a cross-reaction between monoclonal anti-*H. pylori* antibodies and ductal cells of the salivary glands, glomerular capillary walls, and renal tubular cells^{5,6}.

Some limits of the study by Seriolo, *et al*, however, are the lack of screening for the presence of pathogenic strains of *H. pylori* (*CagA*+), the shortness of the followup period, and the lack of a placebo arm. In particular, 4 month followup is a limited period to assess prolonged beneficial effects of such a therapy free from a certain degree of placebo effect. Indeed, improvement of a chronic disease may be individually perceived in the short term, especially if gastrointestinal symptoms (very often associat-

ed with longterm NSAID use) improve soon after eradication. A final consideration is on the usage of clarithromycin, a drug that is often used in *H. pylori* eradication regimens, which also has some immunosuppressive properties that could partially explain the short term beneficial effects of eradication on clinical variables of rheumatoid arthritis.

Gemelli Hospital,
Catholic University, Rome, Italy.

Silvio Danese, MD;
Antonio Gasbarrini, MD.

REFERENCES

1. Gasbarrini A, Franceschi F, Armuzzi A, et al. Extradigestive manifestations of *Helicobacter pylori* gastric infection. *Gut* 1999;45 Suppl 1:19–112.
2. Danesh J, Gasbarrini A, Cremonini F, Gasbarrini G. *Helicobacter pylori* and estradigestive diseases. *Curr Opin Gastroenterol* 2000;S52–S55.
3. Danese S, Cremonini F, Armuzzi A, et al. *Helicobacter pylori* *CagA*-positive strains affects oxygen free radical generation by gastric mucosa. *Scand J Gastroenterol*, in press.
4. Crabtree JE. Gastric mucosal inflammatory responses to *Helicobacter pylori*. *Aliment Pharmacol Ther* 1996;10 Suppl 1:29–37.
5. Ko GH, Park HB, Shin MK, et al. Monoclonal antibodies against *Helicobacter pylori* cross-react with human tissue. *Helicobacter* 1997;2:210–5.
6. Nagashima R, Maeda K, Yuda F, et al. *Helicobacter pylori* antigen in the glomeruli of patients with membranous nephropathy. *Virchows Arch* 1997;431:235–9.



Association Between Infection and Onset of Giant Cell Arteritis: Can Seasonal Patterns Provide the Answer?

To the Editor:

Giant cell arteritis (GCA) is a systemic vasculitis of unknown etiology; its pathogenesis involves a T cell response directed at an as yet unknown antigen^{1,2}. Although it has been postulated for years that infection may trigger GCA, direct evidence of an infectious cause is still lacking and the existence of a cyclic or seasonal pattern of onset is debated. Narvaez, *et al* recently reported no seasonal pattern or association between infection and disease onset in a series of 143 patients with GCA that included 85 cases of isolated polymyalgia rheumatica (PMR)³. The authors concluded that "the hypothesis of an infectious cause for GCA seems highly improbable." Our own experience, based on a large, single center series of patients with temporal arteritis (TA), does not fully support this view⁴.

Since 1976, we have diagnosed and followed 184 patients with TA (153 biopsy proven, 45 with associated PMR, 12 with constitutional symptoms alone). Data were collected prospectively using a comprehensive 174 item questionnaire. Pertinent information regarding disease onset (acute or progressive), the duration of symptoms before the diagnostic procedure, and a history of recent (< 3 months) infection or dental extraction were available in 95%, 93%, and 83% of the cases, respectively. The annual incidence of new cases varied widely from 3 to 16 cases, without any cyclic pattern of variation. The cumulative seasonal incidence rates of GCA were 28% in the winter, 27% in spring, 19% in summer (with only 2 cases observed in July, vs 14 expected), and 24% in the autumn. A recent history of infection or dental extraction was elicited in 22% of the cases, contrasting with the findings of Narvaez, *et al* (0.7%), but consistent with those of others⁵. This discrepancy may be due, at least partially, to different methodological approaches and to the characteristics of the disease.

All patients in our series had TA, in contrast to only 41% of the patients presented by Narvaez, *et al*. Although closely linked, TA and PMR may not be identical diseases and might not share identical causative or triggering environmental factors. Thus, a seasonal pattern of onset in one group may theoretically become blurred by the lack of such a pattern in the other. However, we also could not identify any seasonal incidence of disease in our large homogeneous sample of patients with GCA. More important, only 37% of the cases in our prospective series presented with acute disease onset and 19% of the patients could not recall which week or even which month their illness had begun. The median duration of symptoms before diagnosis was 68 days (range 4 to 430) and the delay exceeded 2 months in 40% of cases. Thus precise dating of disease onset can be quite challenging, particularly in cases with a progressive onset of GCA and a long latency period prior to diagnosis. In some cases, the lack of clear-cut temporal boundaries between recovery from infection and the onset of subsequent vasculitis is also an issue.

Although strong evidence of a relationship between infection and GCA has already come from several prospective, case-control or population based studies⁶⁻⁹, pooled results on monthly and seasonal incidence of GCA^{3,8-11} tend to yield inconsistent data (Table 1). This is not surprising since GCA is clinically a highly protean disease, of often progressive onset, marked initially by ill defined complaints and followed gradually by suggestive cephalic or rheumatic symptoms. The possibility of a relationship

Table 1. Clinical studies on giant cell arteritis investigating a monthly or seasonal incidence of onset.

Author	Number of Cases	Findings
Raynauld, <i>et al</i> ¹⁰	213	No seasonal variation
Ramassamy, <i>et al</i> ¹¹	109	No seasonal variation but peak incidence in December
Petersdottir, <i>et al</i> ⁹	665	Peak incidence in late winter and autumn
Duhaut, <i>et al</i> ⁸	207*	58% of cases diagnosed in autumn or winter
Narvaez, <i>et al</i> ³	143	No seasonal variation but peak incidence in August
Liozon, <i>et al</i>	184	No seasonal variation but low incidence in July

* Biopsy proven temporal arteritis only.

between vasculitis and chronic or recurrent bacterial or viral infection^{8,12,13}, which is not accessible to clinical epidemiological tools, should also be borne in mind. These methodological pitfalls suggest that the search for a link between infection and GCA may need to move beyond the simple exploration of seasonal patterns and follow another path.

Dupuytren's University Hospital,
Limoges, France.

Eric Liozon, MD;
Véronique Loustaud, MD;
Kim Ly, MD;
Elisabeth Vidal, MD.

REFERENCES

- Weyand CM, Goronzy JJ. Giant cell arteritis as an antigen-driven disease. *Rheum Dis Clin North Am* 1995;21:1027-39.
- Weyand CM. The pathogenesis of giant cell arteritis. *J Rheumatol* 2000;27:517-22.
- Narvaez J, Clavaguera MT, Nolla-Sollé JM, Valverde-Garcia J, Roig-Escofet D. Lack of association between infection and polymyalgia rheumatica. *J Rheumatol* 2000;27:953-7.
- Liozon E, Loustaud V, Vidal E. Incidence saisonnière de la maladie de Horton: que conclure? *Rev Méd Interne* 1999;20:372-3.
- Russo MG, Waxman J, Abdoh AA, Serebro LH. Correlation between infection and the onset of the giant cell (temporal) arteritis syndrome. A trigger mechanism? *Arthritis Rheum* 1995;38:374-80.
- Salvarani C, Gabriel SE, O'Fallon WM, Hunder GG. The incidence of giant cell arteritis in Olmsted County, Minnesota: apparent fluctuations in a cyclic pattern. *Ann Med Interne* 1995;123:192-4.
- Elling P, Olsson AT, Elling H. Synchronous variations of the incidence of temporal arteritis and polymyalgia rheumatica in different regions of Denmark; association with epidemics of mycoplasma pneumoniae infection. *J Rheumatol* 1996;23:112-9.
- Duhaut P, Bosshard S, Calvet A, et al. Giant cell arteritis, polymyalgia rheumatica, and viral hypotheses: a multicenter, prospective case-control study. Groupe de Recherche sur l'Artérite à Cellules Géantes. *J Rheumatol* 1999;26:361-9.
- Petersdottir V, Johansson H, Nordborg E, Nordborg C. The epidemiology of biopsy-positive giant cell arteritis: special references to cyclic fluctuations. *Rheumatology* 1999;38:1208-12.
- Raynauld JP, Bloch DA, Fries JF. Seasonal variation in the onset of Wegener's granulomatosis, polyarteritis nodosa and giant cell arteritis. *J Rheumatol* 1993;20:1524-6.
- Duhaut P, Pinede L, Bornet H, et al. Biopsy-proven and biopsy-negative temporal arteritis: differences in clinical spectrum at the onset of the disease. *Ann Rheum Dis* 1999;58:335-41.

12. Ljungstrom L, Franzen C, Schlaug M, Elowson S, Viidas U. Reinfection with *Chlamydia pneumoniae* may induce isolated and systemic vasculitis in small and large vessels. *Scand J Infect Dis* 1997;104 Suppl:37-40.
13. Gabriel SE, Espy M, Erdman DD, Bjornsson J, Smith TF, Hunder GG. The role of parvovirus B19 in the pathogenesis of giant cell arteritis. A preliminary evaluation. *Arthritis Rheum* 1999;42: 1255-8.

Enlargement of Iliopsoas Bursa in a Patient with Polymyalgia Rheumatica

To the Editor:

Polymyalgia rheumatica (PMR) is a clinical syndrome characterized by aching and stiffness in the neck, shoulder, and pelvic girdle, along with evidence of underlying systemic inflammatory reactions (fever, anorexia, weight loss). No radiographic abnormality has been observed in patients with PMR. In contrast, proximal bursitis around the shoulder and hip joints was recently observed using magnetic resonance imaging (MRI)^{1,2}. We describe a patient who presented with enlargement of an iliopsoas bursa due to active PMR.

A 63-year-old woman presented with a 2 week history of increasingly severe aching and stiffness in the left pelvic girdle and a one week history of left inguinal mass associated with low grade fever. She also was anorexic. Examination showed tenderness in the left trochanter, groin, and thigh. Laboratory investigations showed increased erythrocyte sedimentation rate (ESR) of 117 mm/h, C-reactive protein (CRP) 278 mg/l, platelets > 50,000, alkaline phosphatase 486 IU/ml. However, white blood cell count, creatine kinase, and aldolase were within normal ranges. Rheumatoid factor was negative. Although plain radiography showed no abnormal finding in the left hip joint, T2 weighted MRI revealed a high intensity fluid cyst anterior to the left hip (Figure 1). The cyst lay medial to the iliopsoas muscle and lateral to the femoral vessels. Aspiration of the cyst was performed, and roughly 10 ml of clear fluid was drained, which contained leukocytes (5717/mm³). Crystals were absent and culture failed to grow any organisms. Aching and stiffness expanded into the neck and the shoulders progressively. We diagnosed her as having PMR and started low dose corticosteroid therapy, prednisolone 20 mg/day. The clinical findings rapidly remitted, and ESR and serum CRP levels decreased to normal ranges. MRI after 2 months of corticosteroid therapy revealed complete resolution of iliopsoas bursitis.

The iliopsoas bursa is the largest synovial bursa in the body and communicates with the hip joint in 15% of individuals³. The frequency of this communication increases with age and may be more common in patients with hip abnormalities⁴. Iliopsoas bursitis is associated with both inflammatory and degenerative disorders of the hip joint. Enlargement of this bursa has been described in rheumatoid arthritis (RA), synovial chondromatosis, pigmented villonodular synovitis, osteoarthritis, trauma, gout, pyogenic infection, tuberculosis, and avascular necrosis^{3,5}. However, this is the first report of enlargement of iliopsoas bursa due to PMR.

There are 2 possibilities explaining this bursal enlargement. Increased intraarticular pressure due to production of synovial fluid can cause enlargement of the bursa if such a communication exists. Another possible mechanism is excessive production of fluid by the synovia of the iliopsoas bursa. In our patient, communication between the hip joint and the iliopsoas bursa or massive hip joint effusion was not observed using MRI. Moreover, the duration from the onset of symptoms was short. Thus we suspect that acute synovitis originated in the iliopsoas bursa and production of massive quantities of synovial fluid led to its rapid enlargement.

Although several infectious agents and genetic factors have been suggested, the pathogenesis of PMR remains unknown⁶. In some cases, nonerosive arthritis, tenosynovitis, and distal extremity swelling with pitting edema have been observed^{7,8}. Recently, periarticular bursitis was seen in patients with active PMR using MRI and sonography^{1,2,9}. Salvarani, *et al* suggested that involvement of extraarticular synovial structures is a predominant part of the inflammatory process of PMR and related disorders, such as seronegative symmetrical synovitis with pitting edema and elderly onset seronegative RA¹⁰. We detected enlargement of the iliopsoas bursa and improvement of bursitis after low dose corticosteroid therapy using MRI for assessment. Therefore we support the idea that MRI may be useful in some cases for the early diagnosis and management of PMR.

Department of Orthopaedic Surgery,
Shiga University of Medical Science,
Murakami Orthopaedic Clinic,
Shiga, Japan.

Yoshitaka Tani, MD;
Ichiro Nishimura, MD;
Tomohiro Mimura, MD;
Toshio Ushiyama, MD;
Koji Inoue, MD;
Mototsune Murakami, MD.

REFERENCES

1. Salvarani C, Cantini F, Olivieri I, et al. Proximal bursitis in active polymyalgia rheumatica. *Ann Intern Med* 1997;127:27-31.
2. Cantini F, Salvarani C, Olivieri I, Niccoli L, Padula A, Bozza A.

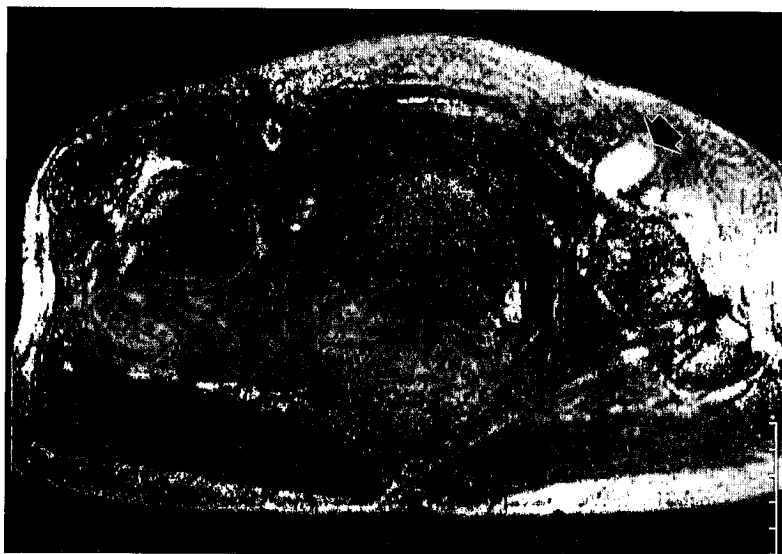

Figure 1. Axial T2 weighted MRI (2000/90) revealed the enlarged iliopsoas bursa at high intensity (arrow).

Hip bursitis in active polymyalgia rheumatica: Report of a case. *Clin Exp Rheumatol* 1999;17:512-3.

3. Armstrong P, Saxton H. Iliopsoas bursa. *Br J Radiol* 1972;45:493-5.
4. Warren R, Kay JJ, Salvati EA. Arthrographic demonstration of an enlarged iliopsoas bursa complicating osteoarthritis of the hip. *J Bone Joint Surg Am* 1975;57:413-5.
5. Lupetin AR, Daffner RH. Rheumatoid iliopsoas bursitis: MR findings. *J Comput Assist Tomogr* 1990;14:1035-6.
6. Salvarani C, Macchioni P, Boiardi L. Polymyalgia rheumatica. *Lancet* 1997;350:43-7.
7. Healey LA. Long-term follow-up of polymyalgia rheumatica: evidence for synovitis. *Semin Arthritis Rheum* 1984;13:322-8.
8. Salvarani C, Gabriel S, Hunder GG. Distal extremity swelling with pitting edema in polymyalgia rheumatica. Report of nineteen cases. *Arthritis Rheum* 1996;39:73-80.
9. Coari G, Paoletti F, Iagnocco A. Shoulder involvement in rheumatoid diseases. Sonographic findings. *J Rheumatol* 1999;26:668-73.
10. Salvarani C, Cantini F, Olivieri I, Hunder GS. Polymyalgia rheumatica: A disorder of extraarticular synovial structures? [editorial]. *J Rheumatol* 1999;26:517-21.

Colchicine Induced Toxicity and Pancytopenia at Usual Doses and Treatment with Granulocyte Colony-Stimulating Factor

To the Editor:

Colchicine is an established treatment for gouty arthritis and is also used in a variety of conditions such as familial Mediterranean fever, Behçet's disease, amyloidosis, and palmar and plantar pustulosis. Whereas the gastrointestinal side effects of oral colchicine are common and well known, colchicine toxicity with pancytopenia is rare in patients given ordinary therapeutic doses. I describe a patient who developed colchicine toxicity with pancytopenia shortly after taking oral colchicine prescribed for acute polyarthritis.

A 46-year-old Chinese woman with a 20 year history of diabetes was admitted to hospital for acute onset of polyarthritis affecting the wrists, hands, and ankles. Her diabetes was complicated by retinopathy and nephropathy. Significant investigations included white blood cell (WBC) count $18.78 \times 10^9/l$, hemoglobin 10.9 g/dl, platelet count 379,000, urea 18 mmol/l, creatinine 134 $\mu\text{mol/l}$, serum uric acid 442 $\mu\text{mol/l}$, 24 h urinary uric acid 3.5 mmol/day (normal 1.9–4.5). She was diagnosed to have polyarticular gouty arthritis by her endocrinologists and was given prednisolone 20 mg bid, colchicine 0.5 mg tid, and tramadol 50 mg tid. Three days after starting colchicine, having a total dose of 4.5 mg, she developed progressive pancytopenia, reaching a nadir WBC count of $0.24 \times 10^9/l$, hemoglobin 8.4 g/dl, platelet count 54,000 at the end of one week. Bone marrow aspiration and trephine biopsy showed moderate hypocellularity with predominant decrease in WBC precursors. The impression was that of a drug induced marrow suppression and colchicine was stopped. Her course was also complicated by concomitant pneumonia and hepatobiliary sepsis. She was then transferred to our hospital for further management.

On admission she was noted to be ill, febrile, and jaundiced. She complained of diarrhea, averaging 8 bowel movements a day, and abdominal pain. This lasted 3 days. There was synovitis of her ankles, wrists, and proximal interphalangeal joints. Investigations showed WBC count $0.21 \times 10^9/l$, hemoglobin 8.2 g/dl, platelets 49,000, albumin 27 g/l, alkaline phosphatase 222 U/l (40–130), total bilirubin 80 $\mu\text{mol/l}$ (5–30), ALT 66 U/l, AST 70 U/l, uric acid 345 $\mu\text{mol/l}$, 24 h creatinine clearance 30 ml/min, 24 h urinary protein 2.6 g/d. Antinuclear antibody, anti-dsDNA, anti-Ro, antinuclear cytoplasmic antibody, rheumatoid factor, HBsAg, anti-HCV IgG, and parvovirus IgM were all negative. The assessment at this point was that she had reactive arthritis and colchicine induced toxicity and pancytopenia. She was given subcutaneous granulocyte colony-stimulating factor

(G-CSF) at 300 $\mu\text{g/day}$ and continued her antibiotic therapy. Tramadol was discontinued and she was maintained with low dose prednisolone 2 mg bid. Her neutropenia recovered after 4 days of G-CSF with WBC count $3.63 \times 10^9/l$, hemoglobin 8.1 g/dl, platelet count 58,000. She had a rebound leukocytosis with WBC count of $44.83 \times 10^9/l$ two days after G-CSF was stopped. She then developed proximal weakness and paresthesia of both her lower limbs, with raised serum aldolase and myoglobin in the second week of her hospitalization. Electromyography showed moderate sensorimotor polyneuropathy. She started to have hair loss in the third week of her illness, which became alopecia totalis by the end of the fifth week. She was subsequently discharged after a month of hospitalization. At the time of discharge, she was wheelchair bound and required assistance in the activities of daily living. On outpatient followup, she had gradual recovery of her alopecia and muscle strength after 2 months and total recovery after 7 months. Her arthritis resolved gradually over a period of 6 months and the low dose prednisolone was eventually discontinued.

Colchicine toxicity and death is usually a consequence of oral colchicine overdosage exceeding 0.5 mg/kg, the lowest reported overdose fatality being 7.5 mg¹. Toxicity and pancytopenia is rare in patients given the usual therapeutic doses. Our patient received a total dose of 4.5 mg over 3 days and developed toxicity very shortly after. The risk factors for colchicine toxicity include (1) intravenous use; (2) use of loading doses; (3) use in elderly patients; (4) renal insufficiency; (5) hepatic dysfunction; (6) drug interactions (cimetidine, erythromycin, tolbutamide)². This patient had renal insufficiency and liver dysfunction as the risk factors for toxicity.

Colchicine toxicity is a relatively distinct syndrome characterized by multiorgan involvement. It can be divided into 3 stages³. The first stage occurs during the first 24 h after ingestion and is dominated by gastrointestinal symptoms. The second stage is characterized by multiorgan failure, developing 24 to 72 h later. Organ derangements include bone marrow suppression, renal failure, fever, heart failure, respiratory distress, and neuromyopathy. The third stage is the recovery phase, where there is marrow recovery with rebound leukocytosis, resolution of organ dysfunction, and development of alopecia. Our patient went through all 3 stages, although there were overlapping periods between the 3 stages. The characteristic features of colchicine toxicity were severe pancytopenia, neuromyopathy, and total alopecia during the recovery phase.

Management of colchicine toxicity can be difficult because of widespread organ involvement. Therapy is mainly supportive. Serial dosing with activated charcoal may enhance elimination. Because of colchicine's rapid tissue distribution and high affinity binding at intracellular sites, hemodialysis, charcoal hemoperfusion, and plasma exchange are not effective. Fluids and antibiotics are administered, as neutropenia can predispose to severe bacterial sepsis and be the direct cause of death, as in 6 out of 16 fatal cases reported in one series⁴. Hemodynamic monitoring is essential in the initial 24–72 h for potential cardiovascular collapse. In recent years granulocyte-colony stimulating factor has been used in the treatment of pancytopenia secondary to colchicine overdose⁵. In this patient, G-CSF was also successfully used to hasten the marrow recovery to 5 days, which would take up to 10 days without treatment. Immunotoxicotherapy using IgG colchicine antibodies, which has been promising in animal experiments, is currently being developed for treatment of colchicine poisoning¹.

It is hoped that this report will raise clinicians' awareness of the potentially serious toxicity of colchicine, a drug that is so widely used, to avoid its use in patients with risk factors for toxicity.

Department of Medicine,
National University Hospital,
National University of Singapore, Singapore.
E-mail: mdcykh@nus.edu.sg

Kam Hon Yoon, MBBS(Singapore),
MMed (Int Med), MRCP(UK).

REFERENCES

1. Putterman C, Ben-Chetrit E, Caraco Y, Levy M. Colchicine intoxication: clinical pharmacology, risk factors, features, and management. *Semin Arthritis Rheum* 1991;3:143-55.

2. Caraco Y, Putterman C, Rahamimov R, Ben-Chetrit E. Acute colchicine intoxication — possible role of erythromycin administration. *J Rheumatol* 1992;19:494-6.
 3. Simons RJ, Kingma DW. Fatal colchicine toxicity. *Am J Med* 1989;86:356-7.
 4. Katz R, Chuang LC, Sutton JD. Use of granulocyte colony-stimulating factor in the treatment of pancytopenia secondary to colchicine overdose. *Ann Pharmacol* 1992;26:1087-8.
 5. Critchley JA, Critchley LA, Yeung EA, et al. Granulocyte-colony-stimulating factor in the treatment of colchicine poisoning. *Hum Exp Toxicol* 1997;16:229-32.
-

Corrections

Gordon PA, Rosenthal E, Khamashta MA, Hughes GRV. Absence of conduction defects in the echocardiograms of mothers with children with congenital complete heart block. *J Rheumatol* 2001;28:366-9. The title should read: Absence of conduction defects in the electrocardiograms of mothers with children with congenital complete heart block. We regret the error.

Delgado J, Gomez-Cerezo J, Barbado FJ, Vazquez JJ, Sigüenza M, Dupond J-L. Relapsing polychondritis and erythema elevatum diutinum: an unusual association refractory to dapsone. *J Rheumatol* 2001;28:634-5. The authors' names should have been listed in the following order: Delgado J, Gómez-Cerezo J, Sigüenza M, Barbado FJ, Dupond J-L, Vázquez JJ. We regret the error.