Bone and Joint Destruction in Rheumatoid Arthritis: What Is Really Happening?

STEVEN R. GOLDRING

ABSTRACT. Focal bone erosions occur at the joint margins and in subchondral bone of patients with rheumatoid arthritis (RA). These erosions progress throughout the course of disease and generally correlate with disease severity. Tissue sections from sites of bone erosion in the rheumatoid joint show multinucleated cells with phenotypic characteristics of osteoclasts, the cells responsible for resorbing bone during physiologic remodeling. Factors known to directly or indirectly induce osteoclast differentiation and activation are found in the rheumatoid synovium. These include receptor activator of NF-κB ligand (RANKL), which plays a critical role in osteoclast differentiation, as well as a variety of proinflammatory cytokines, including intereukin 1 (IL-1) and tumor necrosis factor-α (TNF-α), which upregulate RANKL. IL-1 also augments osteoclast activation, and TNF-α induces differentiation of early osteoclast precursors. In animal models of RA, RANKL is expressed at sites of bone erosion. Moreover, in a serum transfer model of inflammatory arthritis, animals unable to produce osteoclasts did not show evidence of bone resorption despite the presence of intense inflammation. These observations suggest that osteoclasts mediate focal bone erosions in RA and that targeting of osteoclasts and osteoclast mediated bone resorption represents a rational approach to preventing or reducing focal bone loss in RA. (J Rheumatol 2002;29 Suppl 65:44–48)

Key Indexing Terms:
BONE EROSION BONE RESORPTION CYTOKINES
OSTEOCLAST NUCLEAR FACTOR-κB, RHEUMATOID ARTHRITIS

Focal and systemic bone loss contribute to the morbidity associated with rheumatoid arthritis (RA)[1,2]. In the joint, focal erosions occur at 2 principal sites: at the joint margins and in subchondral bone[3]. The inflammatory synovial tissue (pannus) is directly responsible for the development of marginal bone erosions that are clearly evident on radiographic evaluation. However, the pannus has access to the bone marrow as well, where inflammatory changes can enhance osteoclastic resorption at the subchondral bone surface. As a result, articular cartilage is subject to inflammatory attack from below through subchondral bone, as well as from above, as the pannus moves across the articular surface. Standard radiographs do not accurately identify the extent of subchondral bone erosion and subsequent cartilage destruction from below, but recent evidence provided by magnetic resonance imaging (MRI) indicates the importance of this site of attack. It follows that agents capable of protecting against subchondral bone resorption should also have chrondroprotective properties.

Two other forms of bone loss are also seen in RA. Juxtaarticular osteopenia occurs within or juxtaposed to the inflamed joint. Reduced joint use likely contributes to this local disturbance in bone remodeling. More importantly, systemic osteoporosis is seen in the axial and appendicular skeleton, reflecting the systemic inflammation of RA as well as the sedentary lifestyle of patients with significant disability. Moreover, some commonly used medications in RA, notably corticosteroids and methotrexate, can also exacerbate bone mineral density (BMD) loss. Even after correcting for medication usage, patients with RA have lower BMD than nonarthritic populations[2,4-7]. This reduction in BMD is associated with an increased risk of hip and vertebral fracture[6,8,9].

The extent of focal bone erosions generally correlates with the severity of RA and progresses throughout the course of disease[10-12]. They are often used as a marker for response to therapeutic interventions. Recent studies show that biologic therapies targeting IL-1 and TNF-α as well as several disease modifying antirheumatic drugs can alter the progression of these bone erosions[13-16]. MRI evaluations show that focal erosions occur very early in RA, probably before they can be appreciated on standard radiographs[17,18]. Accordingly, therapeutic interventions need to be considered in early stage disease before the structural elements of bone have been irreversibly destroyed, thereby creating a situation where healing of bone erosions may be possible.

Critical to developing rational therapies that block bone resorption is an understanding of the cellular, biochemical, and molecular events that are associated with bone loss in RA. One of the hallmarks of focal bone erosion in the rheumatoid joint is a reduction in new bone formation. In

From Harvard Medical School, New England Baptist Bone and Joint Institute, Boston, Massachusetts, USA.

Supported by an unrestricted educational grant from Amgen, Inc.

S.R. Goldring, MD.

Address reprint requests to Dr. S.R. Goldring, Beth Israel Deaconess Medical Center and New England Baptist Hospital, 110 Francis St., 5A, Boston, MA 02215. E-mail: sgoldrin@caregroup.harvard.edu

Personal non-commercial use only. The Journal of Rheumatology Copyright © 2002. All rights reserved.

Downloaded on April 18, 2024 from www.jrheum.org

this way, RA is clearly distinguished from osteoarthritis, where the principal radiographic features of subchondral sclerosis and osteophyte formation are reflective of excessive bone repair mechanisms.

PHYSIOLOGIC AND PATHOLOGIC BONE REMODELING

Physiologic bone remodeling involves the coupling of bone resorption to new bone formation (Figure 1). Signals for increasing bone resorption are likely initiated by bone lining cells. This process is believed to involve release of matrix metalloproteinases, which prepare the bone surface for recognition by osteoclast precursor cells. These precursors are derived from the same hematopoietic stem cells that give rise to the monocyte–macrophage lineage. The osteoclast precursor cells differentiate into mature, multinucleated osteoclasts that remove mineral and matrix from bone during the resorptive phase. After this period of resorption, osteoblasts or pre-osteoblasts that subsequently differentiate into mature osteoblasts attach to regions of resorbed bone and deposit mineral and matrix, leading to formation of new bone. After completing their tasks, the osteoclasts and osteoblasts are believed to undergo apoptosis. In the case of osteoblasts, some cells may be incorporated into the bone matrix as osteocytes or repopulate the resting bone surfaces as bone lining cells.

At the end of this cycle, the amount of new bone that is formed matches exactly the amount of bone that had been resorbed. However, implicit in the erosive changes characteristic of the rheumatoid lesion is an imbalance between bone resorption and formation. On the basis of histopathologic and biochemical evidence, it appears that both increased resorption as well as decreased formation occur in the rheumatoid joint[19].

In order to determine whether osteoclasts also mediate focal bone erosion in the rheumatoid joint, at least on morphological grounds, a series of definitive markers are needed to distinguish osteoclasts from other cells of the monocyte–macrophage lineage and from other bone cell types. Osteoclasts can be identified on tissue sections through characteristic functional and phenotypic markers (Table 1). Osteoclasts are multinucleated cells with a specialized ruffled border found at sites of bone attachment. These cells have biochemical activities, such as carbonic anhydrase and proton pump ATPase, that permit generation of an acidic microenvironment for dissolving the mineral phase of bone. Osteoclasts produce acid proteases, including tartrate resistant acid phosphatase (TRAP) and cathepsin K, which degrade the organic bone matrix. Finally, osteoclasts express receptors involved in attachment, such as the vitronectin receptor. The osteoclast also expresses the calcitonin receptor that mediates cell detachment and apoptosis. The calcitonin receptor is a particularly useful marker, because its expression is upregulated at the same time as the osteoclast is induced to full resorbing capacity.

The phenotype of bone-resorbing cells at the bone–pannus interface was evaluated by *in situ* hybridization of tissue sections from patients with RA[20]. Multinucleated cells expressing mRNA for TRAP and cathepsin K were found in resorption lacunae in regions where the pannus invaded into bone. Moreover, these cells expressed calcitonin mRNA. Cells expressing TRAP and cathepsin K mRNA were also found in the bone marrow in regions adjacent to the sites of pannus invasion. Thus, these phenotypic markers show that cells with features characteristic of osteoclasts are found at active sites of focal bone erosion in the rheumatoid joint. However, this analysis does not address the issue of whether other cell types can also resorb bone in RA.

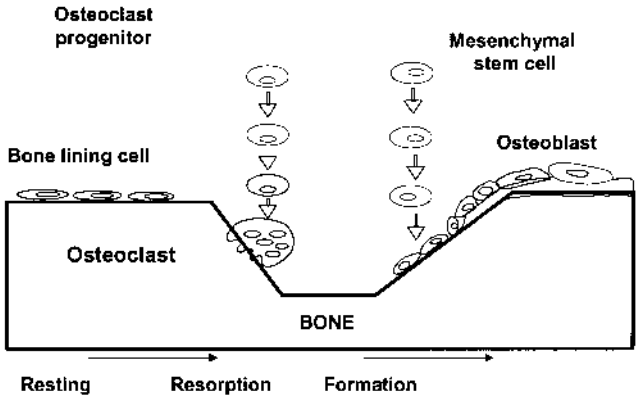

Figure 1. Schematic of physiologic bone remodeling.

REGULATION OF BONE REMODELING

Osteoclast mediated resorption is regulated at 3 different points[21]. First, some factors enhance resorption indirectly by acting on the bone lining cells, which in turn release osteoclastogenic differentiation factors that act on osteoclast precursor cells. Among the factors that act on bone lining cells are parathyroid hormone (PTH), PTH related peptide, 1,25-OH_2-vitamin D_3, prostaglandin E_2, and several cytokines, including IL-1, TNF-α, IL-11, and IL-17. Second, some factors act directly on the osteoclast precursor cells to stimulate their differentiation into mature osteoclasts. These include macrophage-colony stimulating factor (M-CSF), receptor activator of NF-κB ligand (RANKL),

Table 1. Phenotypic features of osteoclasts.

Multinucleation
Ruffled border at zones of attachment
Carbonic anhydrase activity
Proton pump ATPase activity
Tartrate resistant acid phosphatase activity
Cathepsin K activity
Bone resorbing activity
Vitronectin receptor expression
Calcitonin receptor expression

Personal non-commercial use only. The Journal of Rheumatology Copyright © 2002. All rights reserved.

Downloaded on April 18, 2024 from www.jrheum.org

TNF-α, IL-6, IL-11, and IL-15. Finally, some factors, such as IL-1 and RANKL, can act directly on mature osteoclasts to regulate their bone resorbing activity.

RANKL is a member of the TNF family of ligands, which is also known as osteoclast differentiating factor, TNF-related activation-induced cytokine, and osteoprotegerin ligand[22,23]. RANKL was first identified as a factor that regulates interactions between T cells and dendritic cells. It induces osteoclast differentiation, but it also acts directly on mature osteoclasts to regulate their activity. It is both necessary and sufficient for inducing osteoclast differentiation. RANKL binds to a member of the TNF receptor family known as receptor activator of NF-κB (RANK), which is expressed on osteoclast precursors, osteoclasts, dendritic cells, and certain nonimmune cells, notably chondrocytes.

Factors that indirectly promote bone resorption act on the bone lining cells to stimulate production of M-CSF, expression of RANKL on the cell surface, and release of soluble RANKL (Figure 2). M-CSF induces proliferation and expansion of early osteoclast precursors, leading to expression of RANK. RANKL interacts with RANK on these precursors to stimulate their differentiation along the osteoclast pathway, and it also binds to RANK on mature osteoclasts to enhance resorptive activity. The activity of RANKL is regulated by a naturally occurring inhibitor known as osteoprotegerin (OPG), a soluble protein that is a member of the TNF receptor family[24]. Although OPG is structurally distinct from RANK, it acts like a decoy receptor by binding to RANKL, thereby preventing the normal RANKL-RANK interaction, and disrupting osteoclastogenesis.

The importance of RANKL in osteoclast differentiation is evident from studies of knockout mice. When either RANKL or RANK genes were deleted, the animals developed severe osteopetrosis[25,26]. These mice had an absolute absence of osteoclasts, and they were unable to resorb bone or calcify cartilage. In contrast, deletion of OPG, which suppresses the tonic activity of RANKL, led to development of progressive and severe osteoporosis[27].

BONE RESORPTION IN RHEUMATOID ARTHRITIS

A role for RANKL in focal bone erosions in RA is suggested by several observations. First, RANKL mRNA was expressed in synovial tissue from patients with RA, but it was not seen in normal synovial tissues[20]. Second, RANKL mRNA was detected *ex vivo* in cultured adherent synovial fibroblasts and activated T cells derived from RA synovial tissue[20]. Third, coculture of rheumatoid synovial fibroblasts with peripheral blood mononuclear cells in the presence of M-CSF and 1,25-OH_2-vitamin D_3 led to increased RANKL expression and subsequent osteoclastogenesis[28]. Fourth, mRNA encoding RANKL, RANK, and OPG was expressed in cells isolated from the pannus and synovial membrane regions of the rheumatoid joint[29]. Notably, the ratio of RANKL mRNA to OPG mRNA was significantly correlated with the number of resorption lacunae.

Results from animal arthritis models support findings in the rheumatoid synovium. In rat adjuvant arthritis, RANKL was expressed by activated T cells isolated from the inflamed synovium, and RANKL mRNA was identified in synovial and inflammatory cells by *in situ* hybridization[30]. When OPG was administered at the onset of disease in order to block RANKL, subsequent bone and cartilage destruction was prevented even though inflammation was unaffected. In collagen induced arthritis, multinucleated cells expressing TRAP and calcitonin receptors were detected in arthritic lesions with bone destruction[31]. RANKL mRNA was expressed at high levels in cells of the inflamed synovium and by osteoclasts at sites of bone erosion.

Although RANKL is upregulated in the rheumatoid lesion, it does not necessarily mean that it is driving bone resorption in RA. Many other factors that indirectly cause osteoclast differentiation have been identified in rheumatoid synovium, including IL-1α, IL-1ß, TNF-α, IL-6, M-CSF, IL-15, IL-17, and PTH related peptide. For example, IL-1 and TNF-α can synergize with low levels of RANKL, such that these cytokines may be the key mediators driving the actual resorptive process. TNF-α acts on early osteoclast precursors to induce osteoclast differentiation, but it appears that some RANKL is also required. In contrast, IL-1 acts principally on the osteoclast itself to increase resorptive activity. It is important to recognize that both IL-1 and

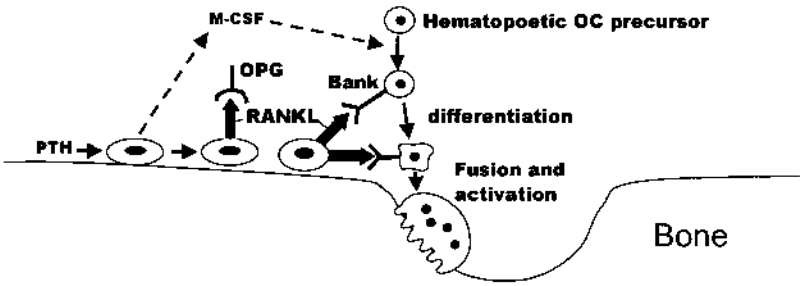

Figure 2. Regulation of bone remodeling. In this schematic, PTH stimulates bone lining cells to produce M-CSF, express RANKL on its surface, and release soluble RANKL. Factors known to stimulate bone lining cells and present in the rheumatoid joint include IL-1, TNF-α, IL-17, and PTH related peptide.

Personal non-commercial use only. The Journal of Rheumatology Copyright © 2002. All rights reserved.

Downloaded on April 18, 2024 from www.jrheum.org

TNF-α may also contribute to focal erosions by inhibiting new bone formation through increased osteoblast apoptosis.

Osteoclasts are present at the bone-pannus interface, and they are clearly capable of causing focal bone erosion in RA. However, other cell types are also present at the bone–pannus interface, notably synovial fibroblasts and macrophages. To show that osteoclasts are the major resorbing cell, a model of inflammatory arthritis is needed in which activated macrophages and T cells are present, but the capacity to form osteoclasts is lost. RANKL knockout mice cannot form osteoclasts, yet they form normal numbers of macrophages and can develop inflammatory synovitis. Using a serum transfer model of inflammatory arthritis that bypasses the need for T cell activation, RANKL knockouts developed joint inflammation that was comparable to that seen in wild-type mice whether measured by clinical signs or histopathologic criteria[32]. An intense inflammatory reaction with pannus formation was evident in control animals, leading to extensive erosion and destruction of the joint (Figure 3). In control animals, marginal and subchondral bone erosion was seen, with cartilage being degraded at the margins as well as from below at the surface of subchondral bone. In the RANKL knockouts, microcomputed tomography showed little evidence of focal bone loss, and histopathological analysis showed preservation of the bone surface. TRAP positive cells were abundant in wild-type animals but absent in the RANKL knockouts. Thus, focal bone erosion did not develop in the absence of osteoclasts despite the presence of intense inflammation and pannus. Cartilage damage was seen in the RANKL knockouts, although it was reduced somewhat in part due to the absence of subchondral bone loss.

CONCLUSION

Focal bone erosion in RA is mediated, at least in part, by osteoclasts. Cells at the bone–pannus interface express markers for osteoclasts, including TRAP, cathepsin K, and calcitonin receptor. Moreover, blocking RANKL, the key mediator of osteoclast differentiation, either by administering OPG in adjuvant arthritis or by gene deletion in the serum transfer model of arthritis, prevented bone erosions. In the latter model, the protective effect on bone was realized despite the presence of intense inflammation and pannus. On the basis of these observations, therapies targeted at osteoclast mediated bone resorption represent a rational approach for reducing focal bone loss in RA.

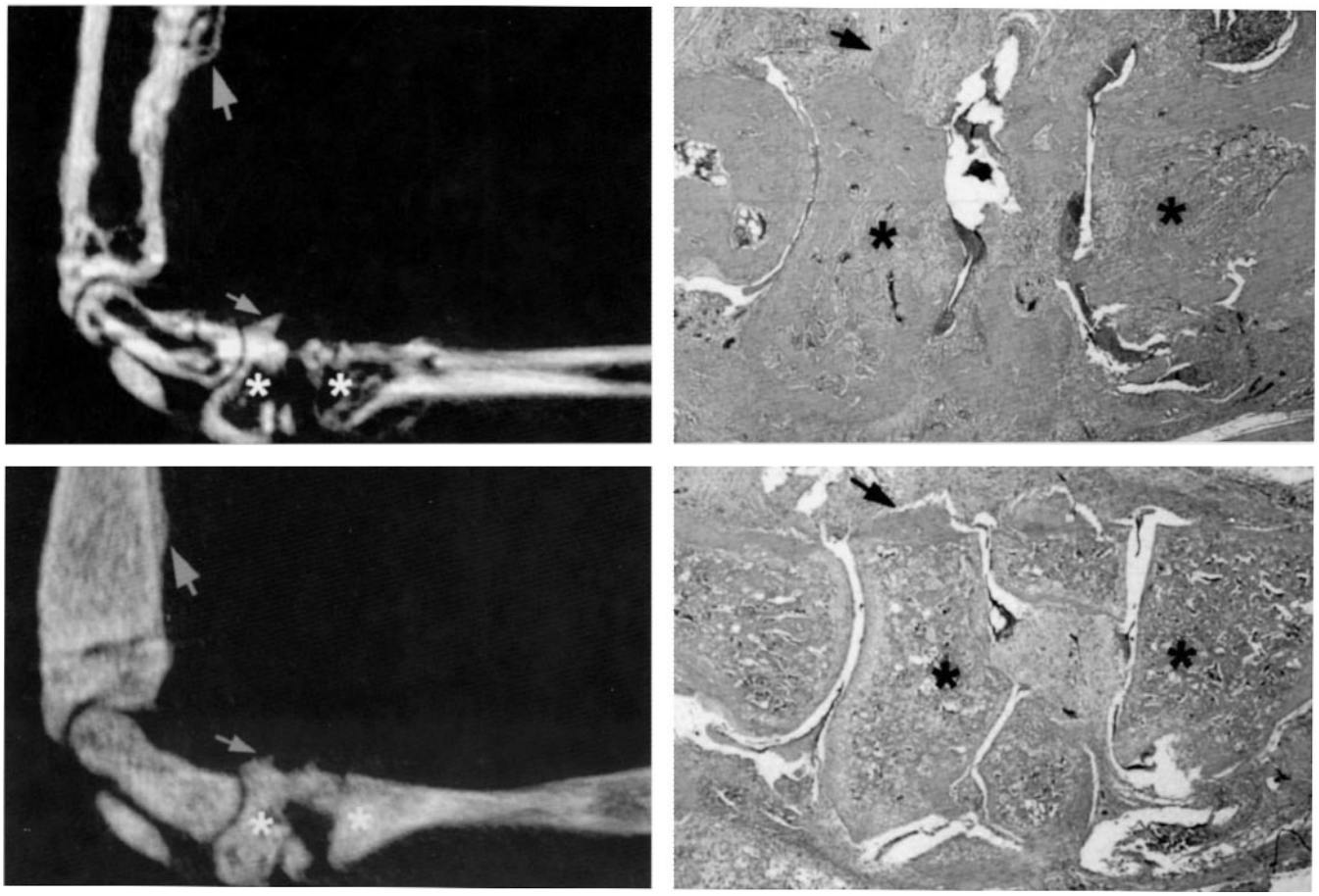

Figure 3. Microcomputed tomography (left panels) and histologic analysis (right panels) of joint damage in control (top panels) and RANKL knockouts (bottom panels) in the serum transfer model of RA. The asterisks designate comparable areas of the joint. From Pettit, *et al*[32], with permission.

Personal non-commercial use only. The Journal of Rheumatology Copyright © 2002. All rights reserved.

Downloaded on April 18, 2024 from www.jrheum.org

Blockade of synovitis, however, remains the ultimate goal for reducing the inflammatory aspects of RA as well as preventing tissue destruction. The advent of biologic therapy targeting IL-1 and TNF-α provides an important approach to controlling synovitis, but it provides the added benefit of blocking the effects of these cytokines on osteoclastic bone resorption.

REFERENCES

1. Callahan LF, Pincus T, Huston JW III, Brooks RH, Nance EP Jr, Kaye JJ. Measures of activity and damage in rheumatoid arthritis: depiction of changes and prediction of mortality over five years. Arthritis Care Res 1997;10:381-94.
2. Martin JC, Munro R, Campbell MK, Reid DM. Effects of disease and corticosteroids on appendicular bone mass in postmenopausal women with rheumatoid arthritis: comparison with axial measurements. Br J Rheumatol 1997;36:43-9.
3. Goldring SR, Gravallese EM. Pathogenesis of bone erosions in rheumatoid arthritis. Curr Opin Rheumatol 2000;12:195-9.
4. Sambrook PN, Eisman JA, Yeates MG, Pocock, NA, Eberl S, Champion GD. Osteoporosis in rheumatoid arthritis: safety of low-dose corticosteroids. Ann Rheum Dis 1986;45:950-3.
5. Hall GM, Spector TD, Griffin AJ, Jawad AS, Hall ML, Doyle DV. The effect of rheumatoid arthritis and steroid therapy on bone density in postmenopausal women. Arthritis Rheum 1993; 36:1510-6.
6. Peel NF, Moore DJ, Barrington NA, Bax DE, Eastell R. Risk of vertebral fracture and relationship to bone mineral density in steroid treated rheumatoid arthritis. Ann Rheum Dis 1995;54:801-6.
7. Haugeberg G, Uhlig T, Falch JA, Halse JI, Kvien TK. Bone mineral density and frequency of osteoporosis in female patients with rheumatoid arthritis: results from 394 patients in the Oslo County Rheumatoid Arthritis register. Arthritis Rheum 2000;43:522-30.
8. Hooyman JR, Melton LJ III, Nelson AM, O'Fallon WM, Riggs BL. Fractures after rheumatoid arthritis. A population-based study. Arthritis Rheum 1984;27:1353-61.
9. Spector TD, Hall GM, McCloskey EV, Kanis JA. Risk of vertebral fracture in women with rheumatoid arthritis. BMJ 1993;306:558.
10. Sharp JT, Wolfe F, Mitchell DM, Bloch DA. The progression of erosion and joint space narrowing scores in rheumatoid arthritis during the first twenty-five years of disease. Arthritis Rheum 1991;34:660-8.
11. van Zeben D, Hazes JM, Zwinderman AH, Vandenbroucke JP, Breedveld FC. Factors predicting outcome of rheumatoid arthritis: results of a follow-up study. J Rheumatol 1993;20:1288-96.
12. Kaarela K, Kautiainen H. Continuous progression of radiological destruction in seropositive rheumatoid arthritis. J Rheumatol 1997;24:1285-7.
13. Jiang Y, Genant HK, Watt I, Bresnihan B, Aitchison R, McCabe D. A multicenter, double-blind, dose-ranging, randomized, placebo-controlled study of recombinant human interleukin-1 receptor antagonist in patients with rheumatoid arthritis. Radiologic progression and correlation of Genant and Larsen scores. Arthritis Rheum 2000;43:1001-9.
14. Bathon JM, Martin RW, Fleischmann RM, et al. A comparison of etanercept and methotrexate in patients with early rheumatoid arthritis. N Engl J Med 2000;343:1586-93.
15. Lipsky PE, van der Heijde DM, St. Clair EW, et al. Infliximab and methotrexate in the treatment of rheumatoid arthritis. N Engl J Med 2000;343:1594-602.
16. Sharp JT, Strand V, Leung H, Hurley F, Loew-Friedrich I. Treatment with leflunomide slows radiographic progression of rheumatoid arthritis: results from three randomized controlled trials of leflunomide in patients with active rheumatoid arthritis. Arthritis Rheum 2000;43:495-505.
17. McQueen FM, Stewart N, Crabbe J, et al. Magnetic resonance imaging of the wrist in early rheumatoid arthritis reveals a high prevalence of erosions at four months after symptom onset. Ann Rheum Dis 1998;57:350-6.
18. McGonagle D, Conaghan PG, O'Connor P, et al. The relationship between synovitis and bone changes in early untreated rheumatoid arthritis: a controlled magnetic resonance imaging study. Arthritis Rheum 1999;42:1706-11.
19. Garnero P, Jouvene P, Buchs N, Delmas PD, Miossec P. Uncoupling of bone metabolism in rheumatoid arthritis patients with or without joint destruction: assessment with serum type I collagen breakdown products. Bone 1999;24:381-5.
20. Gravallese EM, Manning C, Tsay A, et al. Synovial tissue in rheumatoid arthritis is a source of osteoclast differentiation factor. Arthritis Rheum 2000;43:250-8.
21. Teitelbaum SL. Bone resorption by osteoclasts. Science 2000;289:1504-8.
22. Khosla S. Minireview: the OPG/RANKL/RANK system. Endocrinology 2001;142:5050-5.
23. Hofbauer LC, Heufelder AE. Role of receptor activator of nuclear factor-κB ligand and osteoprotegerin in bone cell biology. J Mol Med 2001;79:243-53.
24. Kostenuik PJ, Shalhoub V. Osteoprotegerin: a physiological and pharmacological inhibitor of bone resorption. Curr Pharm Des 2001;7:613-35.
25. Kong YY, Yoshida H, Sarosi I, et al. OPGL is a key regulator of osteoclastogenesis, lymphocyte development and lymph-node organogenesis. Nature 1999;397:315-23.
26. Dougall WC, Glaccum M, Charrier K, et al. RANK is essential for osteoclast and lymph node development. Genes Dev 1999; 13:2412-24.
27. Bucay N, Sarosi I, Dunstan CR, et al. Osteoprotegerin-deficient mice develop early onset osteoporosis and arterial calcification. Genes Dev 1998;12:1260-8.
28. Takayanagi H, Iizuka H, Juji T, et al. Involvement of receptor activator of nuclear factor κB ligand/osteoclast differentiation factor in osteoclastogenesis from synoviocytes in rheumatoid arthritis. Arthritis Rheum 2000;43:259-69.
29. Haynes DR, Crotti TN, Loric M, Bain GI, Atkins GJ, Findlay DM. Osteoprotegerin and receptor activator of nuclear factor κB ligand (RANKL) regulate osteoclast formation by cells in the human rheumatoid arthritic joint. Rheumatology 2001;40:623-30.
30. Kong YY, Feige U, Sarosi I, et al. Activated T cells regulate bone loss and joint destruction in adjuvant arthritis through osteoprotegerin ligand. Nature 1999;402:304-9.
31. Romas E, Bakharevski O, Hards DK, et al. Expression of osteoclast differentiation factor at sites of bone erosion in collagen-induced arthritis. Arthritis Rheum 2000;43:821-6.
32. Pettit AR, Ji H, von Stechow D, et al. TRANCE/RANKL knockout mice are protected from bone erosion in a serum transfer model of arthritis. Am J Pathol 2001;159:1689-99.

Personal non-commercial use only. The Journal of Rheumatology Copyright © 2002. All rights reserved.

Downloaded on April 18, 2024 from www.jrheum.org