

Large-vessel Vasculitis Affecting the Aorta and its Branches in Relapsing Polychondritis: Case Series and Systematic Review of the Literature

Alessandro Tomelleri, Corrado Campochiaro, Silvia Sartorelli, Maurizio Papa, Giacomo De Luca , Giulio Cavalli, Elena Baldissera, and Lorenzo Dagna

ABSTRACT. Objective. To describe the features of large-vessel vasculitis (LVV) as it affects the aorta and its branches in patients with relapsing polychondritis (RP).

Methods. Retrospective data and systematic literature review.

Results. Twenty-one patients were identified. LVV diagnosis was subsequent to RP and associated with extrachondral involvement in the majority of patients. Supraaortic vessels were more frequently involved (82%). Fourteen patients (67%) were treated with a conventional synthetic disease-modifying antirheumatic drug (csDMARD) and 7 (33%) with a biological DMARD (bDMARD). Vascular interventional procedures were performed in 10 patients (48%). Premature death due to cardiovascular complications was reported in 3 cases (14%).

Conclusion. Extraaortic LVV is a serious and overlooked RP manifestation. All patients with RP should be investigated for LVV. (J Rheumatol First Release June 1 2020; doi:10.3899/jrheum.190862)

Key Indexing Terms:

RELAPSING POLYCHONDRITIS ARTERITIS VASCULITIS BIOLOGIC

Relapsing polychondritis (RP) is a rare autoimmune disease characterized by recurrent inflammation of cartilaginous structures. All connective tissue can be involved, including that of the eye, heart, and inner ear¹. Cardiovascular involvement occurs in 24–52% of patients². It is more common in men and is associated with significant morbidity and mortality². A single study reported an incidence of 6.4% for

aortic involvement in patients with RP³. No data are available on patients with large-vessel vasculitis (LVV) affecting the aorta and its branches.

We studied the diagnostic investigations and therapy of 4 patients with RP and LVV followed in our center, and systematically reviewed available evidence to characterize this overlooked clinical entity.

From the Unit of Immunology, Rheumatology, Allergy and Rare Diseases, and the Department of Radiology, Institute for Research and Health Care (IRCCS) San Raffaele Hospital; Vita-Salute San Raffaele University, Milan, Italy.

A. Tomelleri, MD, Unit of Immunology, Rheumatology, Allergy and Rare Diseases, IRCCS San Raffaele Hospital, and Vita-Salute San Raffaele University; C. Campochiaro, MD, Unit of Immunology, Rheumatology, Allergy and Rare Diseases, IRCCS San Raffaele Hospital, and Vita-Salute San Raffaele University; S. Sartorelli, MD, Unit of Immunology, Rheumatology, Allergy and Rare Diseases, IRCCS San Raffaele Hospital, and Vita-Salute San Raffaele University; M. Papa, MD, Department of Radiology, IRCCS San Raffaele Hospital; G. De Luca, MD, Unit of Immunology, Rheumatology, Allergy and Rare Diseases, IRCCS San Raffaele Hospital, and Vita-Salute San Raffaele University; G. Cavalli, MD, PhD, Unit of Immunology, Rheumatology, Allergy and Rare Diseases, IRCCS San Raffaele Hospital, and Vita-Salute San Raffaele University; E. Baldissera, MD, Unit of Immunology, Rheumatology, Allergy and Rare Diseases, IRCCS San Raffaele Hospital; L. Dagna, MD, FACP, FEFIM(Hon), Unit of Immunology, Rheumatology, Allergy and Rare Diseases, IRCCS San Raffaele Hospital, and Vita-Salute San Raffaele University.

Address correspondence to Dr. C. Campochiaro, Unit of Immunology, Rheumatology, Allergy and Rare Diseases, IRCCS San Raffaele Hospital, Vita-Salute San Raffaele University, Via Olgettina 60, 20132 Milan, Italy. E-mail: campochiaro.corrado@hsr.it

Accepted for publication December 3, 2019.

MATERIALS AND METHODS

We performed a retrospective analysis of patients with RP diagnosed according to Michet criteria¹ and followed at our center. We identified patients with LVV affecting the aorta and its branches. The Ethical Committee approved the study (approval number DSAN854-A-OS/1). Patients' written informed consent was obtained. We made a systematic literature review with the following terms: "relapsing polychondritis," "chondritis," "vasculitis," "vessel inflammation," "Takayasu," "arteritis," and "large vessel." We included only patients with unequivocal signs of extraaortic large-vessel inflammation: circumferential thickening, aneurysms, and stenoses, disclosed by magnetic resonance angiography (MRA), computed tomography angiography (CTA), CT/positron emission tomography (PET), arterial doppler ultrasonography (US), conventional angiography (CA), or documented postmortem. We excluded patients with vascular involvement restricted to the aorta (Figure 1).

RESULTS

In our cohort of 41 patients with RP, we identified 4 (9.7%) with LVV affecting the aorta and its branches.

Case reports. Patient 1 was a 25-year-old woman who developed limb claudication and acute-phase reactant elevation. Abdominal bruits and absence of dorsalis pedis pulses were noted. MRA showed diffuse inflammatory thickening of the

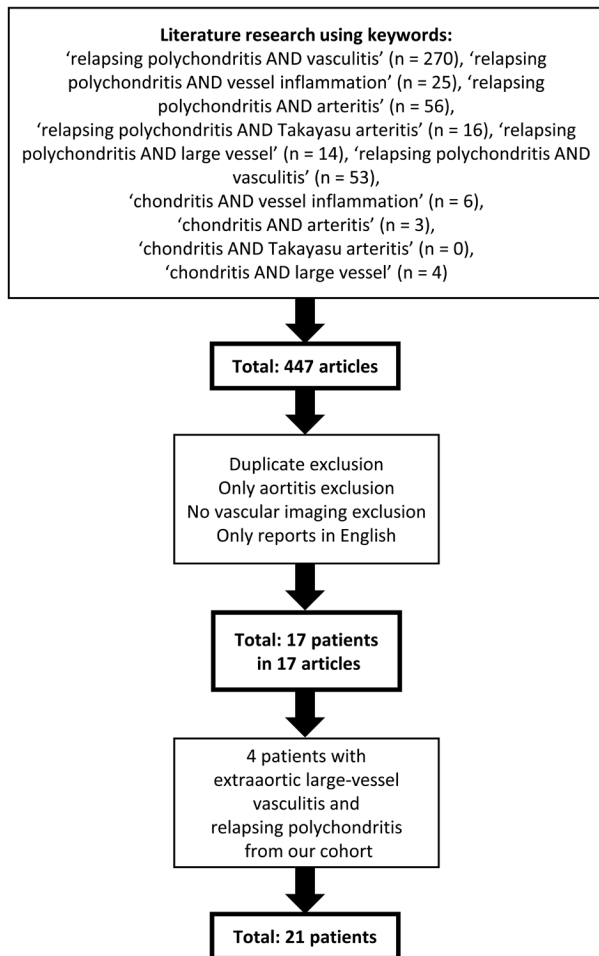


Figure 1. Flow diagram of the study selection process.

abdominal aorta, bilateral iliac arteries, superior mesenteric artery, and celiac trunk with stenosis of the infrarenal aorta and of the iliac arteries. CT/PET confirmed the presence of active inflammation. A course of steroids was started and golimumab therapy was introduced, but increased inflammatory markers persisted. After 18 months she developed

an infrarenal aorta aneurysm (Figure 2A). She underwent abdominal aneurysmectomy with aortobifemoral bypass and was switched to tocilizumab (TCZ). After 12 months, an MRA revealed no vascular progression and a CT/PET showed no signs of inflammation. After 3 years of clinical remission, TCZ was discontinued.

Patient 2 was a 37-year-old woman who developed dizziness and left upper limb paresthesia. An MRA revealed wall thickening of the ascending aorta, aortic arch, brachiocephalic artery, and left common carotid artery; occlusion of left subclavian artery, and stenosis of the celiac trunk (Figure 2B). Inflammatory markers were not increased. Because the disease was considered inactive, no immunosuppressive treatment was started. The patient then developed recurrent episodes of chondritis, so she was started on steroids and azathioprine (AZA). After 5 years, she was still asymptomatic. An MRA disclosed no vascular progression and a CT/PET showed no inflammation.

Patient 3 was a 20-year-old woman admitted for ascending aorta replacement. On admission, a significant increase of inflammatory markers with severe stenosis of the anterior descending coronary artery and active vasculitis of both common carotid arteries and abdominal aorta was noted. She was treated with steroids and cyclosporine (CSA), and then with methotrexate (MTX). Because of the persistence of systemic inflammation, she was started on cyclophosphamide (CYC). One year later, inflammatory markers were still increased and MRA showed abdominal aorta vasculitis worsening and involvement of the left iliac artery. Steroids were increased and anakinra was added, with initial benefit. After 18 months, she experienced an inflammatory flare. She was treated with pulse steroids and switched to TCZ. After 5 years she remains in good disease control.

Patient 4 was a 36-year-old man who underwent coronary revascularization. A perivascular biopsy revealed lymphoplasmacytic arteritis. CA disclosed involvement of the infrarenal aorta, celiac trunk, superior mesenteric artery, and critical stenosis of the renal arteries. He underwent bilateral renal angioplasty and AZA was introduced. Repeated

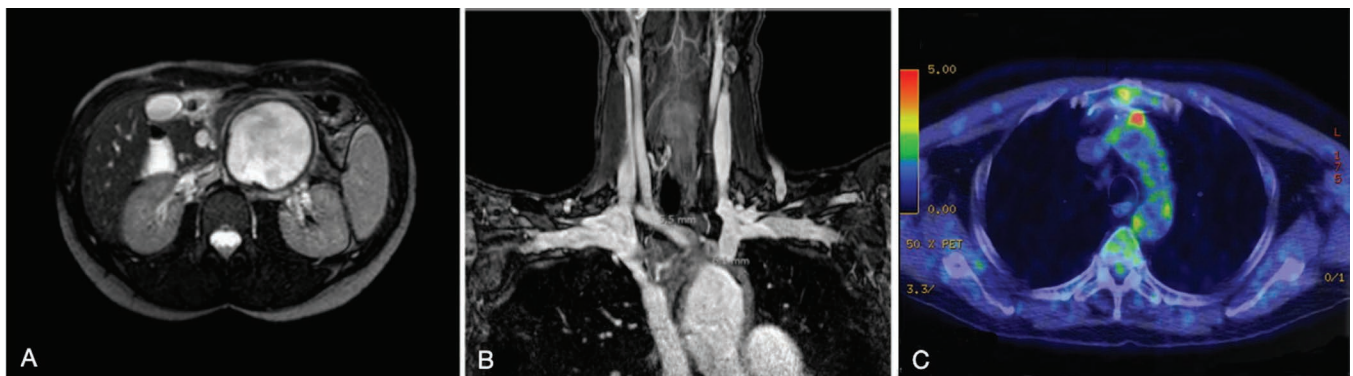


Figure 2. Balanced turbo field-echo sequence magnetic resonance angiography (MRA) showing infrarenal abdominal aorta dilation in Patient 1 (panel A). High-resolution 3-D volumetric contrast-enhanced MRA showing wall thickening of brachiocephalic trunk and aortic arch in Patient 2 (panel B). 18F-fluorodeoxyglucose positron emission tomography showing radiotracer uptake in ascending aorta and arch of aorta in Patient 4 (panel C).

attempts to titrate corticosteroids resulted in recurrent flares of systemic inflammation, so etanercept (ETN) was added. ETN had only marginal efficacy, as confirmed by a CT/PET that revealed inflammation of the arch and ascending aorta (Figure 2C), so it was substituted with infliximab (IFX), which had to be stopped because of infusion reaction. Over the years, various combinations of immunosuppressors were attempted. Only marginal results were obtained with a combination of TCZ, low-dose steroid, and mycophenolate mofetil (MMF). The patient eventually developed renal amyloidosis.

Literature review. We found 447 publications describing RP patients with vascular involvement. After application of our criteria, 17 reports about 17 patients with RP were included⁴⁻²⁰ (Table 1A and Table 1B).

Patients were more frequently female (59%), with a median age of 29 ± 14.7 years. The main cartilaginous structures involved were ears (15 patients, 88%) and nose (12 patients, 71%). Tracheal chondritis was documented in 3 patients (19%), and costochondritis and involvement of the larynx in only 1 patient each (6%).

Arthralgia/arthritis and ocular inflammatory complications were present in 7 patients (41%). Two patients developed sensorineural deafness, 2 patients were affected by pyoderma gangrenosum-like lesions, and 1 patient had recurrent oral aphthae.

In 71% of cases, extraaortic LVV was diagnosed after

the onset of the chondritis (mean delay, 48 ± 86.8 mos). In 29% of cases, the diagnosis was simultaneous. Involved arteries included subclavian (35%), common carotid (29%), internal carotid (18%), iliac (18%), renal (12%), vertebral (6%), axillary (6%), femoral (6%), inferior mesenteric (6%), and brachiocephalic trunk (12%). Supradiaphragmatic and infradiaphragmatic vessel involvement was present in 3 patients (18%), while the remaining (82%) had exclusive supradiaphragmatic involvement. In 5 patients (29%), vascular disease was limited to the branches originating from the aortic arch. Inflammatory coronary artery disease was present in 7 patients (41%) and it was isolated in 6. Ten patients (59%) had concomitant aortitis, mostly affecting the ascending aorta.

In 11 patients, vascular inflammation was diagnosed by means of CA. Three also underwent CTA, and 1 had both CTA and CT/PET. In 2 patients the imaging technique was MRA, in 2 patients CTA, and in 1 patient ultrasound. In 1 patient vascular involvement was documented postmortem.

All patients were treated with steroids as first-line therapy. In 10 patients (59%), a conventional synthetic disease-modifying antirheumatic drug (csDMARD) was added (CYC, 5; AZA, 4; MTX, 4; CSA, 2; MMF, diaminodiphenylsulfone, and chlorambucil, 1 each). A biological DMARD (bDMARD) was used in 4 patients (24%). In all cases, IFX was the initial bDMARD and in 1 case it was switched to rituximab. In 7 patients (41%), a vascular

Table 1A. Summary of the cases of relapsing polychondritis (RP) with extraaortic large-vessel vasculitis in our cohort and reported in the literature.

Study	Pt. No.	Age at RP Onset, yrs/Sex	Sites of Chondritis	Other Clinical Features	Vasculitis Diagnosis	Temporal Delay, mos	First Vascular Sign/symptom
Rabuzzi (1970)	1	25/F	Nose	Arthritis, episcleritis	Concomitant	—	Headache, ischemic stroke
Esdaille (1977)	2	46/M	Ear, costosternal	Episcleritis, iritis, orbital pseudotumor	Subsequent	36	Angina abdominis
Sohi (1981)	3	19/F	Nose, trachea	Keratitis	Subsequent	252	Heart failure
Giordano (1984)	4	28/F	Nose, ear, trachea	Arthritis, episcleritis	Subsequent	204	Vascular bruits
Bowness (1991)	5	33/M	Ear, nose, larynx	Arthritis	Subsequent	5	Heart failure
Yamazaki (2001)	6	59/F	Ear, nose	—	Subsequent	11	Headache
Barretto (2002)	7	42/M	Ear	Sensorineural deafness	Subsequent	72	Lower limb ischemia
Sasirekha (2006)	8	24/F	Ear, nose	Arthritis	Subsequent	12	Angina pectoris
Vaidyanathan (2006)	9	24/F	Ear, nose	—	Subsequent	24	Heart failure
Butterton (2007)	10	59/M	Ear, nose	Periorbital inflammation	Concomitant	—	Carotidynia
Ghosn (2008)	11	7/F	Ear, nose	Pyoderma gangrenosum	Concomitant	—	—
Stein (2008)	12	30/M	Ear, nose	Uveitis	Subsequent	60	Angina pectoris, heart failure
McCarthy (2009)	13	29/M	Ear, nose	Arthritis, sensorineural deafness	Subsequent	192	Angina pectoris, heart failure
Sugrue (2014)	14	51/M	Ear	Arthritis, oral ulcers	Subsequent	12	Heart failure
Malik (2015)	15	35/F	Ear, nose	Arthritis, ischemic optic neuropathy	Concomitant	—	Ocular ischemic syndrome
Karakaya (2016)	16	26/F	Ear, trachea	—	Concomitant	—	Upper limb numbness
Subhadarshani (2017)	17	14/F	Ear, nose	Pyoderma gangrenosum	Subsequent	96	Lower limb ischemia
Our cohort	18	25/F	Ear, nose	Oral ulcers	Subsequent	50	Lower limbs claudication
	19	37/F	Ear, nose	—	Subsequent	36	Ischemic stroke
	20	20/F	Ear, nose	Erythema nodosum	Subsequent	108	—
	21	20/M	Ear, nose	Arthritis, episcleritis, pyoderma gangrenosum	Subsequent	204	Arterial hypertension, angina pectoris

Table 1B. Additional details about cases of relapsing polychondritis with extraaortic large-vessel vasculitis in our cohort and reported in the literature.

Study	Pt. No.	Imaging for Vasculitis Diagnosis	Aortitis	Coronary Involvement	Large Arteries Vasculitis	Vascular Intervention	csDMARD	bDMARD
Rabuzzi (1970)	1	Angiography	—	—	Right CCA	—	—	—
Esdaile (1977)	2	Angiography	Ascending, abdominal	—	Bilateral RA and IA; IMA	—	AZA, CYC	—
Sohi (1981)	3	Angiography	Ascending, abdominal	—	Bilateral IA	Aortic aneurysm repair	—	—
Giordano (1984)	4	Angiography	Arch	—	BCT; left CCA; left SA	—	—	—
Bowness (1991)	5	Postmortem examination	—	Right and left CA	—	—	CYC	—
Yamazaki (2001)	6	MRA	—	—	Bilateral ICA	—	AZA	—
Barretto (2002)	7	CTA, angiography	Entire aorta	Left and circumflex CA	Bilateral IA, FA, and SA; left RA	Aortofemoral bypass	CSA, CYC, chlorambucil	—
Sasirekha (2006)	8	Angiography	Ascending	Right and left CA	—	CABG	*	—
Vaidyanathan (2006)	9	Angiography	Ascending	Right and left CA	—	—	—	—
Butterton (2007)	10	CTA	—	—	Left ICA and VA	—	MMF	—
Ghosn (2008)	11	CTA, angiography	Ascending	—	Right CCA and AA; bilateral SA	Aortic aneurysm repair	—	IFX
Stein (2008)	12	CTA, angiography	Ascending	Right and left CA	—	CABG	MTX, CYC	IFX
McCarthy (2009)	13	Angiography	—	Right and left CA	—	CABG	MTX, AZA, CSA	IFX, RTX
Sugrue (2014)	14	CTA, PET, angiography	Ascending	Left CA	—	PTCA	MTX	IFX
Malik (2015)	15	Doppler US	—	—	Bilateral CCA, VA, SA	—	—	—
Karakaya (2016)	16	MRA	—	—	Bilateral ICA; left VA; right SA	—	—	—
Subhadarshani (2017)	17	CTA	Arch	—	Bilateral SA; left CCA; BCT	—	CYC, AZA	—
Our cohort	18	MRA, PET	Abdominal	—	SMA; CT; bilateral IA	Aneurysm repair + aortofemoral bypass	AZA, MTX	GOL, TCZ
	19	MRA	Ascending, arch	—	Left CCA and SA; BCT; CT	—	AZA	—
	20	Angiography, MRA	Ascending, abdominal	Left CA	Bilateral CCA; left IA	Aortic aneurysm repair; coronary PTA	CSA, MTX, CYC	ANK, TCZ
	21	Angiography, US	—	Right and left CA	Bilateral RA; CT; SMA	CABG, Renal PTA	AZA, MMF, MTX	ETN, IFX, ADA, TCZ, ANK

* Diaminodiphenylsulfone. csDMARD: conventional synthetic disease-modifying antirheumatic drug; bDMARD: biological DMARD; AA: axillary artery; BCT: brachiocephalic trunk; CA: coronary artery; CCA: common carotid artery; MRA: magnetic resonance angiography; CT: celiac trunk; FA: femoral artery; IA: iliac artery; ICA: internal carotid artery; IMA: inferior mesenteric artery; RA: renal artery; AZA: azathioprine; CYC: cyclophosphamide; SA: subclavian artery; VA: vertebral artery; CTA: computed tomography; CSA: cyclosporine; CABG: coronary artery bypass grafting; MMF: mycophenolate mofetil; IFX: infliximab; MTX: methotrexate; RTX: rituximab; PET: positron emission tomography; PTCA: percutaneous transluminal coronary angioplasty; US: ultrasound; SMA: superior mesenteric artery; GOL: golimumab; TCZ: tocilizumab; PTA: percutaneous transluminal angioplasty; ANK: anakinra; ETN: etanercept; ADA: adalimumab.

interventional procedure was required (coronary artery bypass graft, 3; aortic aneurysm repair, 2; aortofemoral bypass and percutaneous transluminal coronary angioplasty, 1). Three patients (18%) died from RP-related cardiovascular complications.

DISCUSSION

In our review we showed that patients with RP can

develop LVV involvement of the aorta and its branches and we reported the disease features of this subgroup.

LVV diagnosis was subsequent or simultaneous to RP onset, suggesting that the RP-related systemic inflammation might also affect extraaortic large vessels. Nonetheless, because RP itself can be associated with many autoimmune diseases, it is hard to say whether LVV involvement represents a different disease complicating the course

of RP or a manifestation included in the clinical spectrum of RP.

Because the presence of LVV involvement in patients with RP is usually not actively investigated, in the majority of cases the diagnosis was made once vascular inflammation became clinically overt. Moreover, once patients are diagnosed with RP, steroid therapy is usually started, with benefits also for underlying vascular inflammation. This might explain why LVV diagnosis is usually made either concomitantly with RP onset (when a full assessment is performed), or with a significant diagnostic delay (when steroid therapy has been tapered).

In this subgroup of patients with RP, we observed a high frequency of auricular and nasal involvement and a low frequency of laryngotracheal manifestations. The majority of patients (81%) had involvement of other extrachondral sites, chiefly ocular inflammation and arthritis, indicating a higher burden of inflammation and a more severe disease phenotype. Moreover, similarly to other LVV, but dissimilarly to previous reports, a slight female preponderance seems associated with extraaortic LVV.

Heterogeneity of studies and clinical phenotypes preclude clear conclusions on the best therapeutic approach. Both csDMARD and bDMARD were used as steroid-sparing agents in refractory cases. Mixed results were obtained with CYC, AZA, and MTX. In one-third of patients, bDMARD were started after csDMARD failure. The experience with bDMARD was mainly restricted to 3 different mechanisms of action [anti-interleukin 1 (IL-1), anti-tumor necrosis factor- α , anti-IL-6r], with TCZ and IFX showing the best results.

Vascular involvement can be extremely severe in patients with RP, as documented by the significant percentage of patients undergoing vascular surgery.

We suggest that LVV involvement be clinically investigated and eventually confirmed in patients with RP both at diagnosis and during followup visits. In these patients, treatment choice should be focused both on RP and LVV manifestations, because LVV involvement can be insidious and can affect patient survival. Recent progress in imaging modalities together with emerging treatment options might open new possibilities for this orphan disease.

REFERENCES

1. Kingdon J, Roscamp J, Sangle S, D'Cruz D. Relapsing polychondritis: a clinical review for rheumatologists. *Rheumatology* 2018;57:1525-32.
2. Del Rosso A, Petix NR, Pratesi M, Bini A. Cardiovascular involvement in relapsing polychondritis. *Semin Arthritis Rheum* 1997;26:840-4.
3. Le Besnerais M, Arnaud L, Bout my J, Bienvenu B, L vesque H, Amoura Z, et al. Aortic involvement in relapsing polychondritis. *Joint Bone Spine* 2018;85:345-51.
4. Bowness P, Hawley IC, Morris T, Dearden A, Walport MJ. Complete heart block and severe aortic incompetence in relapsing polychondritis: Clinicopathologic findings. *Arthritis Rheum* 1991;34:97-100.
5. Rabuzzi DD. Relapsing polychondritis. *Arch Otolaryngol* 1970;91:188-94.
6. Esdaile J, Hawkins D, Gold P, Freedman SO, Duguid WP. Vascular involvement in relapsing polychondritis. *Can Med Assoc J* 1977;116:1019-22.
7. Sohi GS, Desai AM, Ward WW, Flowers NC. Aortic cusp involvement causing severe aortic regurgitation in a case of relapsing polychondritis. *Cathet Cardiovasc Diagn* 1981;7:79-86.
8. Giordano M, Valentini G, Sodano A. Relapsing polychondritis with aortic arch aneurysm and aortic arch syndrome. *Rheumatol Int* 1984;4:191-3.
9. Yamazaki K, Suga T, Hirata K. Large vessel arteritis in relapsing polychondritis. *J Laryngol Otol* 2001;115:836-8.
10. Barretto SN, Oliveira GH, Michet CJ, Nyman MA, Edwards WD, Kullo IJ. Multiple cardiovascular complications in a patient with relapsing polychondritis. *Mayo Clin Proc* 2002;77:971-4.
11. Sasirekha D, Meenakshi NA, Thomas JM, Jagannath BR, Nayar S, Cherian KM. Multiple cardiovascular involvement in a case of relapsing polychondritis. *J Assoc Physicians India* 2006;54:817-9.
12. Vaidyanathan RK, Byalal JR, Sundaramoorthi T, Sankar NM, Thomas JM, Meenakshi NA, et al. Rapidly progressive coronary ostial stenosis after aortic valve replacement in relapsing polychondritis. *J Thorac Cardiovasc Surg* 2006;131:1395-6.
13. Butterton JR, Collier DS, Romero JM, Zembowicz A. Case records of the Massachusetts General Hospital. Case 14-2007. A 59-year-old man with fever and pain and swelling of both eyes and the right ear. *N Engl J Med* 2007;356:1980-8.
14. Ghosn S, Malek J, Shbaklo Z, Matta M, Uthman I. Takayasu disease presenting as malignant pyoderma gangrenosum in a child with relapsing polychondritis. *J Am Acad Dermatol* 2008;59:S84-7.
15. Stein JD, Lee P, Kuriya B, Tenenbaum J, Daniel LB, Butany J, et al. Critical coronary artery stenosis and aortitis in a patient with relapsing polychondritis. *J Rheumatol* 2008;35:1898-900.
16. McCarthy EM, Cunnane G. Treatment of relapsing polychondritis in the era of biological agents. *Rheumatol Int* 2010;30:827-8.
17. Sugrue G, Durcan L, Bell L, Bolster F, Donnelly S, Kavanagh E. Unsuspected cardiovascular involvement in relapsing polychondritis: a case of aortitis with critical coronary artery stenosis secondary to relapsing polychondritis. *Circ Cardiovasc Imaging* 2014;7:409-11.
18. Malik TG, Khalil M, Ijaz AU, Bhatti MM. Ocular ischemic syndrome and ischemic optic neuropathy in Takayasu arteritis. *J Coll Physicians Surg Pak* 2015;25:S47-9.
19. Karakaya AD, Karaman A, Alper F. Multisystem imaging findings of a case with relapsing polychondritis. *Acta Medica Anatolia* 2016;4:88-90.
20. Subhadarshani S, Gupta V, Chahal A, Verma KK. Saddle-nose and bilateral cauliflower ear deformities with pyoderma gangrenosum-like ulcers, cavitary pulmonary lesions, digital gangrene and pulselessness in a young female. *BMJ Case Rep* 2017;2017:bcr-2017-220434.

