LARGE VESSEL VASCULITIS AFFECTING THE AORTA AND ITS BRANCHES IN RELAPSING POLYCHONDRITIS: CASE SERIES AND SYSTEMATIC REVIEW OF THE LITERATURE

Alessandro Tomelleri, Corrado Campochiaro, Silvia Sartorelli, Maurizio Papa, Giacomo De Luca, Giulio Cavalli, Elena Baldissera, Lorenzo Dagna

KEY INDEXING TERMS: relapsing polychondritis; arteritis; vasculitis; biologic

Unit of Immunology, Rheumatology, Allergy and Rare diseases, IRCCS San Raffaele Hospital, Milan, Italy
Vita-Salute San Raffaele University, Milan, Italy
Department of Radiology, IRCCS San Raffaele Hospital, Milan, Italy

Funding. No specific funding was received from any bodies in the public, commercial or not-for-profit sectors to carry out the work described in this article.

Declarations of interest. The authors declare that they have no competing interests.

A. Tomelleri, MD[1,2], C. Campochiaro, MD[1,2], S. Sartorelli, MD[1,2], M. Papa, MD[3], G. De Luca, MD[1,2], G. Cavalli, MD PhD[1,2], E. Baldissera, MD[1], L. Dagna, MD, FACP, FEFIM(Hon)[1,2]

[1]Unit of Immunology, Rheumatology, Allergy and Rare diseases, IRCCS San Raffaele Hospital, Milan, Italy
[2]Vita-Salute San Raffaele University, Milan, Italy
[3]Department of Radiology, IRCCS San Raffaele Hospital, Milan, Italy

Corresponding author:
Corrado Campochiaro, MD
Unit of Immunology, Rheumatology, Allergy and Rare Diseases
IRCCS San Raffaele Hospital, Vita-Salute San Raffaele University
Via Olgettina 60, 20132 Milano (MI), Italy
Phone: +390226437060 Fax: +390226433729
E-mail: campochiaro.corrado@hsr.it

Accepted Article

This article has been accepted for publication in The Journal of Rheumatology following full peer review. This version has not gone through proper copyediting, proofreading and typesetting, and therefore will not be identical to the final published version. Reprints and permissions are not available for this version. Please cite this article as doi 10.3899/jrheum.190862. This accepted article is protected by copyright. All rights reserved.

Downloaded on April 18, 2024 from www.jrheum.org

Accepted Article

ABSTRACT

Objective. To describe the features of large vessel vasculitis (LVV) affecting the aorta and its branches in relapsing polychondritis (RP) patients.

Methods. Retrospective data and systematic literature review.

Results.21 patients were identified. LVV diagnosis was subsequent to RP and associated with extra-chondral involvement in the majority of patients. Supra-aortic vessels were more frequently involved (82%). 14 (67%) patients were treated with a csDMARD and 7 (33%) with a bDMARD. Vascular interventional procedures were performed in 10 (48%) patients. Prematurely death due to cardiovascular complications was reported in 3 (14%) cases.

Conclusions. Extra-aortic LVV is a serious and overlooked RP manifestation. All RP patients should be investigated for LVV.

This accepted article is protected by copyright. All rights reserved.

Downloaded on April 18, 2024 from www.jrheum.org

Accepted Article

INTRODUCTION

Relapsing polychondritis(RP) is a rare autoimmune disease characterized by recurrent inflammation of cartilaginous structures. All connective tissue can be involved, including eye, heart, and inner ear(1). Cardiovascular involvement occurs in 24-52% of patients(2). It is more common in men and associated with significant morbidity and mortality(2). A single study reported an incidence of 6.4% for aortic involvement in RP patients(3). No data is available on patients with large-vessel vasculitis(LVV) affecting the aorta and its branches.

We described the diagnostic work-up and therapy of four patients with RP and LVV followed-up in our Centre and systematically reviewed available evidence to characterize this overlooked clinical entity.

METHODS

We performed a retrospective analysis of RP patients diagnosed according to Michet criteria(1) followed-up at our Centre. We identified patients with LVV affecting the aorta and its branches. The Ethical Committee approved the study(approval number, DSAN854-A-OS/1). Patients' written informed consent was obtained. We made a systematic literature review with the following terms: "relapsing polychondritis", "chondritis", "vasculitis", "vessel inflammation", "Takayasu", "arteritis, "large vessel". We included only patients with unequivocal signs of extra-aortic large-vessel inflammation: circumferential thickening, aneurysms, and stenoses, disclosed by magnetic-resonance angiography(MRA), computed-tomography angiography(CTA), CT/PET, arterial doppler ultrasonography(US), conventional angiography(CA) or documented *post-mortem*. We excluded patients with vascular involvement restricted to the aorta(**Figure 1**).

RESULTS

In our cohort of 41 RP patients, we identified 4 patients(9.7%) with LVV affecting the aorta and its branches.

Case series

Patient1

A 25-year-old RP woman developed limbs claudication and acute phase reactants elevation. Abdominal bruits and absence of dorsalis pedis pulses were noted. MRA showed diffuse inflammatory thickening of the abdominal aorta, bilateral iliac arteries, superior mesenteric artery, and celiac trunk with stenosis of the infrarenal aorta and of the iliac arteries. A CT/PET confirmed the presence of active inflammation. A course of steroids was started and golimumab therapy was introduced, but persistence of increased inflammatory markers was observed. After 18 months she developed an infrarenal aorta aneurysm(**Figure 2A**). She

Downloaded on April 18, 2024 from www.jrheum.org

This accepted article is protected by copyright. All rights reserved.

Accepted Article

underwent abdominal aneurysmectomy with aorto-bifemoral bypass and was switched to tocilizumab. After 12 months, an MRA revealed no vascular progression and a CT/PET showed no signs of inflammation. After 3 years of clinical remission tocilizumab was discontinued.

Patient2

A 37-year-old RP woman developed dizziness and left upper limb paresthesia. An MRA revealed wall thickening of the ascending aorta, aortic arch, brachiocephalic artery and left common carotid artery, occlusion of left subclavian artery and stenosis of the celiac trunk(**Figure 2B**). Inflammatory markers were not increased. As the disease was considered inactive, no immunosuppressive treatment was started. The patient then developed recurrent episodes of chondritis, so she was started on steroids and azathioprine. After five years, she was still asymptomatic. An MRA disclosed no vascular progression and a CT/PET showed no inflammation.

Patient3

A 20-year-old RP woman was admitted for ascending aorta replacement. On admission, a significant increase of inflammatory markers with severe stenosis of the anterior descending coronary artery and active vasculitis of both common carotid arteries and abdominal aorta was noted. She was treated with steroids and cyclosporine, and then with methotrexate. Due to the persistence of systemic inflammation, she was started on cyclophosphamide. One year later, inflammatory markers were still increased and MRA showed abdominal aorta vasculitis worsening and involvement of the left iliac artery. Steroids were increased and anakinra was added, with initial benefit. After 18 months, she experienced an inflammatory flare. She was treated with pulse steroids and switched to tocilizumab. After 5 years she remains in good disease control.

Patient4

A 36-year-old RP man underwent coronary revascularization. A peri-vascular biopsy revealed lymphoplasmacytic arteritis. CA disclosed involvement of the infrarenal aorta, celiac trunk, superior mesenteric artery and critical stenosis of the renal arteries. He underwent bilateral renal angioplasty and azathioprine was introduced. Repeated attempts to titrate corticosteroids resulted in recurrent flares of systemic inflammation, so etanercept was added. Etanercept had only marginal efficacy, as confirmed by a CT/PET which revealed inflammation of the arch and ascending aorta(**Figure 2C**), so it was substituted with infliximab, which had to be stopped due to infusion reaction. Over the years, various combinations of immunosuppressors were attempted. Only marginal results were obtained with a combination of tocilizumab, low-dose steroid and mycophenolate-mofetil. The patient eventually developed renal amyloidosis.

Literature Review

We found 447 publications describing RP patients with vascular involvement. After application of our criteria, 17 reports about 17 RP patients were included(4-20)(**Table 1**).

Downloaded on April 18, 2024 from www.jrheum.org

This accepted article is protected by copyright. All rights reserved.

Accepted Article

Patients were more frequently female(59%), with a median age of 29±14.7 years. The main cartilaginous structures involved were ears(15 patients, 88%) and nose(12 patients, 71%). Tracheal chondritis was documented in 3 patients(19%), costochondritis and involvement of the larynx only in 1 patient each(6%).

Arthralgia/arthritis and ocular inflammatory complications were present in 7 patients(41%). Two patients developed sensorineural deafness, 2 patients were affected by pyoderma gangrenosum-like lesions, and 1 patient had recurrent oral aphthae.

In 71% of cases, extra-aortic LVV was diagnosed after the onset of the chondritis(mean delay, 48±86.8 months). In 29% of cases the diagnosis was simultaneous. Involved arteries included: subclavian(35%), common carotid(29%), internal carotid(18%), iliac(18%), renal(12%), vertebral(6%), axillary(6%), femoral(6%), inferior mesenteric(6%), brachiocephalic trunk(12%). Supra- and infra-diaphragmatic vessels involvement was present in 3 patients(18%), while the remaining(82%) had exclusive supradiaphragmatic involvement. In 5 patients(29%), vascular disease was limited to the branches originating from the aortic arch. Inflammatory coronary artery disease was present in 7 patients(41%) and it was isolated in 6. Ten patients(59%) had concomitant aortitis, mostly affecting the ascending aorta.

In 11 patients, vascular inflammation was diagnosed by means of CA. Three of them underwent also CTA, and 1 both CTA and CT/PET. In 2 patients the imaging technique was MRA, in 2 patients CTA, in 1 patient US. In 1 patient vascular involvement was documented *post-mortem*.

All patients were treated with steroids as first-line therapy. In 10 patients(59%) a conventional synthetic disease-modifying antirheumatic drug(csDMARD) was added(cyclophosphamide, 5; azathioprine, 4; methotrexate, 4; cyclosporine, 2; mycophenolate-mofetil, dapsone and chlorambucil, 1). A biological DMARD(bDMARD) was used in 4 patients(24%). In all cases, infliximab was the initial bDMARD and in one case it was switched to rituximab. In 7 patients(41%), a vascular interventional procedure was required(coronary artery bypass graft, 3; aortic aneurysm repair, 2; aortofemoral bypass and percutaneous transluminal coronary angioplasty, 1). Three patients(18%) died due to RP-related cardiovascular complications.

DISCUSSION

In our review we showed that RP patients can develop LVV involvement of the aorta and its branches and we reported the disease features of this subgroup of RP patients.

LVV diagnosis was subsequent or simultaneous to RP onset, suggesting that the RP-related systemic inflammation might also affect extra-aortic large vessels. Nonetheless, as RP itself can be associated with many autoimmune diseases, it is really hard to say whether LVV involvement represents a different disease complicating the course of RP or a manifestation included in the clinical spectrum of RP.

Downloaded on April 18, 2024 from www.jrheum.org

This accepted article is protected by copyright. All rights reserved.

Accepted Article

Since the presence of LVV involvement in RP patients is usually not actively investigated, in the majority of cases the diagnosis was made once vascular inflammation became clinically overt. Moreover, once patients are diagnosed with RP, steroid therapy is usually started with benefits also for underlying vascular inflammation. This might explain why LVV diagnosis is usually made either concomitantly with RP onset(when a full assessment is performed), or with a significant diagnostic delay(when steroid therapy has been tapered).

In this subgroup of RP patients, we observed a high frequency of auricular and nasal involvement and a low frequency of laryngotracheal manifestations. The majority of patients(81%) had involvement of other extra-chondral sites, chiefly ocular inflammation and arthritis, indicating a higher burden of inflammation and a more severe disease phenotype. Moreover, similarly to other LVVs, but dissimilarly to previous reports, a slight female preponderance seems associated with extra-aortic LVV.

Heterogeneity of studies and clinical phenotypes preclude clear conclusions on the best therapeutic approach. Both csDMARDs and bDMARDs were used as steroid-sparing agents in refractory cases. Mixed results were obtained with cyclophosphamide, azathioprine and methotrexate. In one-third of patients, bDMARDs were started upon csDMARDs failure. The experience with bDMARDs was mainly restricted to 3 different mechanisms of action(anti-IL1, anti-TNF-alpha, anti-IL-6r), with tocilizumab and infliximab showing the best results.

Vascular involvement can be extremely severe in RP patients, as documented by the significant percentage of patients undergoing vascular surgery.

In conclusion, we suggest that LVV involvement should be clinically investigated and eventually confirmed in RP patients both at diagnosis and during follow-up visits. In these patients, treatment choice should be focused both on RP and LVV manifestations, as LVV involvement can be insidious and impact on patients' survival. Recent progresses in imaging modalities together with emerging treatment options might open a new scenario for this orphan disease.

This accepted article is protected by copyright. All rights reserved.

Downloaded on April 18, 2024 from www.jrheum.org

Accepted Article

REFERENCES

1. Kingdon J, Roscamp J, Sangle S, D'Cruz D. Relapsing polychondritis: A clinical review for rheumatologists. Rheumatology. 2018;57:1525–32.
2. Del Rosso A, Petix NR, Pratesi M, Bini A. Cardiovascular involvement in relapsing polychondritis. Semin Arthritis Rheum. 1997;26:840–4.
3. Le Besnerais M, Arnaud L, Boutémy J, Bienvenu B, Lévesque H, Amoura Z, et al. Aortic involvement in relapsing polychondritis. Joint Bone Spine. 2018;85:345–51.
4. Bowness P, Hawley IC, Morris T, Dearden A, Walport MJ. Complete heart block and severe aortic incompetence in relapsing polychondritis: Clinicopathologic findings. Arthritis Rheum. 1991;34:97–100.
5. Rabuzzi DD. Relapsing polychondritis. Arch Otolaryngol. 1970;91:188–94.
6. Esdaile J, Hawkins D, Gold P, Freedman SO, Duguid WP. Vascular involvement in relapsing polychondritis. Can Med Assoc J. 1977;116:1019–22.
7. Sohi GS, Desai AM, Ward WW, Flowers NC. Aortic cusp involvement causing severe aortic regurgitation in a case of relapsing polychondritis. Cathet Cardiovasc Diagn. 1981;7:79–86.
8. Giordano M, Valentini G, Sodano A. Relapsing polychondritis with aortic arch aneurysm and aortic arch syndrome. Rheumatol Int. 1984;4:191–3.
9. Yamazaki K, Suga T, Hirata K. Large vessel arteritis in relapsing polychondritis. J Laryngol Otol. 2001;115:836–8.
10. Barretto SN, Oliveira GH, Michet CJ, Nyman MA, Edwards WD, Kullo IJ. Multiple cardiovascular complications in a patient with relapsing polychondritis. Mayo Clin Proc. 2002;77:971–4.
11. Sasirekha D, Meenakshi NA, Thomas JM, Jagannath BR, Nayar S, Cherian KM. Multiple cardiovascular involvement in a case of relapsing polychondritis. J Assoc Physicians India. 2006;54:817–9.
12. Vaidyanathan RK, Byalal JR, Sundaramoorthi T, Sankar NM, Thomas JM, Meenakshi NA, et al. Rapidly progressive coronary ostial stenosis after aortic valve replacement in relapsing polychondritis. J Thorac Cardiovasc Surg. 2006;131:1395–6.
13. Butterton JR, Collier DS, Romero JM, Zembowicz A. Case records of the Massachusetts General Hospital. Case 14-2007. A 59-year-old man with fever and pain and swelling of both eyes and the right ear. N Engl J Med. 2007;356:1980–8.
14. Ghosn S, Malek J, Shbaklo Z, Matta M, Uthman I. Takayasu disease presenting as malignant pyoderma gangrenosum in a child with relapsing polychondritis. J Am Acad Dermatol. 2008;59:S84-7.
15. Stein JD, Lee P, Kuriya B, Tenenbaum J, Daniel LB, Butany J, et al. Critical coronary artery stenosis and aortitis in a patient with relapsing polychondritis. J Rheumatol. 2008;35:1898–900.
16. McCarthy EM, Cunnane G. Treatment of relapsing polychondritis in the era of biological agents. Rheumatol Int. 2010;30:827–8.
17. Sugrue G, Durcan L, Bell L, Bolster F, Donnelly S, Kavanagh E. Unsuspected cardiovascular involvement in relapsing polychondritis: A case of aortitis with critical coronary artery stenosis secondary to relapsing polychondritis. Circ Cardiovasc Imaging. 2014;7:409–11.

Downloaded on April 18, 2024 from www.jrheum.org

This accepted article is protected by copyright. All rights reserved.

18. Malik TG, Khalil M, Ijaz AU, Bhatti MM. Ocular ischemic syndrome and ischemic optic neuropathy in Takayasu arteritis. J Coll Physicians Surg Pak. 2015;25:S47-9.
19. Karakaya AD, Karaman A, Alper F. Multisystem Imaging Findings of a Case with Relapsing Polichondritis. Acta Medica Anatolia. 2016;4:88–90.
20. Subhadarshani S, Gupta V, Chahal A, Verma KK. Saddle-nose and bilateral cauliflower ear deformities with pyoderma gangrenosum-like ulcers, cavitary pulmonary lesions, digital gangrene and pulselessness in a young female. BMJ Case Rep. 2017

Accepted Article

This accepted article is protected by copyright. All rights reserved.

Downloaded on April 18, 2024 from www.jrheum.org

Accepted Article

LEGENDS

Figure 1. Flow diagram of the study selection process**.**

Figure 2. Balanced turbo field-echo sequence magnetic-resonance angiography showing infrarenal abdominal aorta dilation in patient 1 (**panel A**). High-resolution 3D volumetric contrast-enhanced magnetic-resonance angiography showing wall thickening of brachiocephalic trunk and aortic arch in patient 2 (**panel B**). ^{18}Fluorodeoxyglucose positron emission tomography showing radiotracer uptake in ascending aorta and arch of aorta in patient 4 (**panel C**)

Table 1. Summary of the cases of relapsing polychondritis with extra-aortic large-vessel vasculitis in our cohort and reported in the literature. AA, axillary artery; BCT, brachiocephalic trunk; CA, coronary artery; CCA, common carotid artery; CT, celiac trunk; FA, femoral artery; IA, iliac artery; ICA, internal carotid artery; IMA, inferior mesenteric artery; RA, renal artery; SA, subclavian artery; VA, vertebral artery

This accepted article is protected by copyright. All rights reserved.

Downloaded on April 18, 2024 from www.jrheum.org

Accepted Article

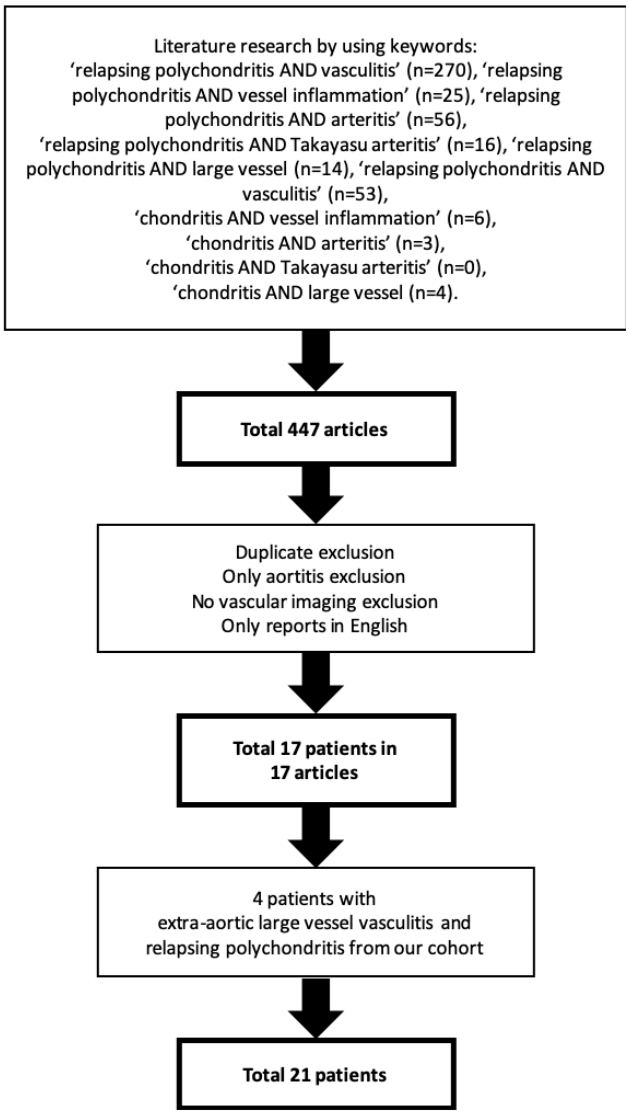

Figure 1. Flow diagram of the study selection process.

This accepted article is protected by copyright. All rights reserved.

Downloaded on April 18, 2024 from www.jrheum.org

Accepted Article

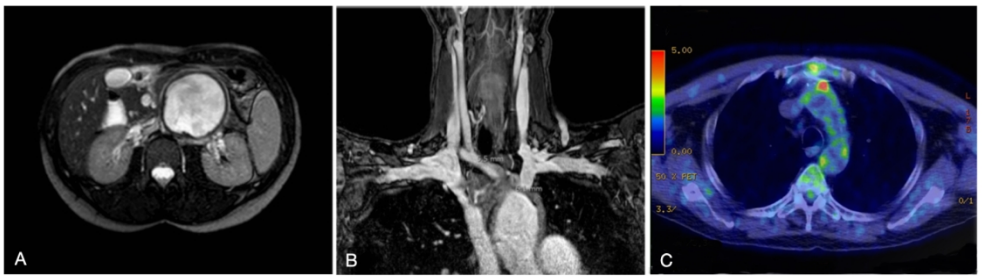

Figure 2. Balanced turbo field-echo sequence magnetic-resonance angiography showing infrarenal abdominal aorta dilation in patient 1 (panel A). High-resolution 3D volumetric contrast-enhanced magnetic-resonance angiography showing wall thickening of brachiocephalic trunk and aortic arch in patient 2 (panel B). 18Fluorodeoxyglucose positron emission tomography showing radiotracer uptake in ascending aorta and arch of aorta in patient 4 (panel C).

468x140mm (100 x 100 DPI)

This accepted article is protected by copyright. All rights reserved.

Downloaded on April 18, 2024 from www.jrheum.org

Study		Age at RP onset Sex	Sites of chondritis	Other clinical features	Vasculitis diagnosis	Temporal delay (months)	First vascular sign/symptom	Imaging for vasculitis diagnosis	Aortitis	Coronary involvement	Large arteries vasculitis	Vascular intervention	csDMARDs	bDMARDs
Rabuzzi *et al.* (1970)	1	25 years Female	Nose	Arthritis, episcleritis	Concomitant	-	Headache, ischemic stroke	Angiography	-	-	Right CCA	-	-	-
Esdaile *et al.* (1977)	2	46 years Male	Ear, costo-sternal	Episcleritis, iritis, orbital pseudotumor	Subsequent	36	Angina abdominis	Angiography	Ascending, abdominal	-	Bilateral RA and IA; IMA	-	AZA, CYC	-
Sohi *et al.* (1981)	3	19 years Female	Nose, trachea	Keratitis	Subsequent	252	Heart failure	Angiography	Ascending, abdominal	-	Bilateral IA	Aortic aneurysm repair	-	-
Giordano *et al.* (1984)	4	28 years Female	Nose, ear, trachea	Arthritis, episcleritis	Subsequent	204	Vascular bruits	Angiography	Arch	-	BCT; left CCA; left SA	-	-	-
Bowness *et al.* (1991)	5	33 years Male	Ear, nose, larynx	Arthritis	Subsequent	5	Heart failure	*Post-mortem examination*	-	Right and left CA	-	-	CYC	-
Yamazaki *et al.* (2001)	6	59 years Female	Ear, nose	-	Subsequent	11	Headache	MRA	-	-	Bilateral ICA	-	AZA	-
Barretto *et al.* (2002)	7	42 years Male	Ear	Sensorineural deafness	Subsequent	72	Lower limb ischemia	CTA, angiography	Entire aorta	Left and circumflex CA	Bilateral IA, FA and SA; left RA	Aortofemoral bypass	CSA, CYC, chlorambucil	-
Sasirekha *et al.* (2006)	8	24 years Female	Ear, nose	Arthritis	Subsequent	12	Angina pectoris	Angiography	Ascending	Right and left CA	-	CABG	Dapsone	-
Vaidyanathan *et al.* (2006)	9	24 years Female	Ear, nose	-	Subsequent	24	Heart failure	Angiography	Ascending	Right and left CA	-	-	-	-
Butterton *et al.* (2007)	10	59 years Male	Ear, nose	Periorbital inflammation	Concomitant	-	Carotidynia	CTA	-	-	Left ICA and VA	-	MMF	-

Accepted Article

This accepted article is protected by copyright. All rights reserved.

Downloaded on April 18, 2024 from www.jrheum.org

Ghosn *et al.* (2008)	11	7 years Female	Ear, nose	Pyoderma gangrenosum	Concomitant	-	-	CTA, angiography	Ascending	-	Right CCA and AA; bilateral SA	Aortic aneurysm repair	-	IFX
Stein *et al.* (2008)	12	30 years Male	Ear, nose	Uveitis	Subsequent	60	Angina pectoris, heart failure	CTA, angiography	Ascending	Right and left CA	-	CABG	MTX, CYC	IFX
McCarthy *et al.* (2009)	13	29 years Male	Ear, nose	Arthritis, sensorineural deafness	Subsequent	192	Angina pectoris, heart failure	Angiography	-	Right and left CA	-	CABG	MTX, AZA, CSA	IFX, RTX
Sugrue *et al.* (2014)	14	51 years Male	Ear	Arthritis Oral ulcers	Subsequent	12	Heart failure	CTA, PET, angiography	Ascending	Left CA	-	PTCA	MTX	IFX
Malik *et al.* (2015)	15	35 years Female	Ear, nose	Arthritis, ischemic optic neuropathy	Concomitant	-	Ocular ischemic syndrome	Doppler US	-	-	Bilateral CCA, VA, SA	-	-	-
Karakaya *et al.* (2016)	16	26 years Female	Ear, Trachea	-	Concomitant	-	Upper limb numbness	MRA	-	-	Bilateral ICA; left VA; right SA	-	-	-
Subhadarshani *et al.* (2017)	17	14 years Female	Ear, nose	Pyoderma gangrenosum	Subsequent	96	Lower limb ischemia	CTA	Arch	-	Bilateral SA; left CCA; BCT	-	CYC, AZA	-
Our cohort	18	25 years, Female	Ear, nose	Oral ulcers	Subsequent	50	Lower limbs claudication	MRA, PET	Abdominal	-	SMA; CT; bilateral IA	Aneurysm repair + aortofemoral bypass	AZA, MTX	GOL, TCZ
	19	37 years, Female	Ear, nose	-	Subsequent	36	Ischemic stroke	MRA	Ascending, arch	-	Left CCA and SA; BCT; CT	-	AZA	-
	20	20 years, Female	Ear, nose	Erythema nodosum	Subsequent	108	-	Angiography, MRA	Ascending, abdominal	Left CA	Bilateral CCA; left IA	Aortic aneurysm repair; coronary PTA	CSA, MTX, CYC	ANK, TCZ
	21	Male 20 years	Ear, nose	Arthritis, episcleritis, pyoderma gangrenosum	Subsequent	204	Arterial hypertension, angina pectoris	Angiography, US	-	Right and left CA	Bilateral RA; CT; SMA	CABG, Renal PTA	AZA, MMF, MTX	ETN, IFX, ADA, TCZ, ANK

Accepted Article

This accepted article is protected by copyright. All rights reserved.

Downloaded on April 18, 2024 from www.jrheum.org