

A Review of Cauda Equina Syndrome in Ankylosing Spondylitis:
Challenges in Diagnosis, Management, and Pathogenesis
Chen Tang MD, Franklin G Moser MD, John Reveille MD, Jane Bruckel, Michael H.
Weisman MD. Cedars-Sinai Medical Center, Departments of Rheumatology and
Neuroradiology.

Chen Tang: MD
Cedars-Sinai Medical Center: No Financial disclosures
chentang00@gmail.com
2334 West View Street, Los Angeles, CA 90016
6033597249

Franklin G Moser: MBA, MD
Cedars-Sinai Medical Center: No Financial disclosures
Franklin.Moser@cshs.org
8700 Beverly Blvd, Los Angeles, CA 90048
3104232468

John Reveille: MD
University of Texas Health Science Center at Houston: No Financial disclosures
John.D.Reveille@uth.tmc.edu
6431 Fannin St, Houston, TX 77030
7135006900

Jane Bruckel: BSN, RN
Spondylitis Association of America: No Financial disclosures
jbruckel@sbcglobal.net
3985 Witzel Drive Sherman Oaks, CA. 91423
8189866918

Michael H Weisman: MD
Cedars-Sinai Medical Center: No Financial disclosures
Michael.Weisman@cshs.org
8700 Beverly Blvd, West Hollywood, CA 90048
3104233277

Competing interests – none

Contributorship

1. Chen Tang MD:
Conception or design of the work
Data collection
Data analysis and interpretation
Drafting the article

Critical revision of the article
Final approval of the version to be published

2. Franklin G Moser MD
Data analysis and interpretation
Critical revision of the article
Final approval of the version to be published

3. John Reveille MD
Data collection
Final approval of the version to be published

4. Jane Bruckel
Conception or design of the work
Data collection
Critical revision of the article
Final approval of the version to be published

5. Michael H. Weisman MD.
Conception or design of the work
Data collection
Data analysis and interpretation
Drafting the article
Critical revision of the article
Final approval of the version to be published

Acknowledgements: none

Funding information: not applicable

This paper involved only patient chart and literature review for the purpose of learning about the pathophysiology of cauda equina syndrome in ankylosing spondylitis. There was no financial support from any source to the patients whose charts were reviewed or to the authors who gathered, interpreted and reported the data herein. None of the authors have any financial interests, potential conflict of interest or the appearance of a conflict of interest to disclose with regard to the work.

Summary Bullet points:

- Cauda equina syndrome (CES) is a rare neurologic complication of long-standing AS
- There are no proven or effective therapy reported to date
- Chronic enthesitis may initiate the process of dural sac weakening, a process perpetuated by mechanical force transduction in the spine eventually forming ectasias in the dura mater

Abstract:

Objective: Cauda equina syndrome (CES) is a rare neurologic complication of long-standing Ankylosing spondylitis (AS). It is unclear what causes CES, and no proven or effective therapy has been reported to date. We have encountered six patients with long-standing AS diagnosed with CES. We set about to study their features intensely, review the literature, and generate hypotheses regarding pathophysiology as well as to speculate on the possibilities of early recognition and prevention.

Method: We obtained permission from six patients with longstanding AS and CES to access their medical records and imaging studies for research purposes related to this paper. We collected and reviewed each patient's past medical history, imaging studies, disease duration, past therapies especially those that relate to AS, laboratory data, as well as any treatment they received for CES and follow up results of each case to the present time.

Results: The six cases of CES with AS have remarkable similarity to each other in that several decades of the disease had passed before neurologic symptoms and later signs appeared. All cases have fused spines and facet joints without spinal fractures, spinal stenosis, or disc herniation.

Conclusion: CES is a rare yet debilitating neurologic complication of long-standing AS. The pathophysiology and treatments are far from clear. We postulate that chronic enthesitis of the vertebral column initiates the process that results in dural stiffening and formation of ectasias causing downstream nerve root damage.

Word Count: 234 (Limit: 250)

Introduction:

Ankylosing spondylitis (AS) is characterized radiologically and pathologically in its late stages by fusion of the sacroiliac (SI) joints and ossification of tendons and ligaments at their sites of attachment to bones (1-3). Non-musculoskeletal manifestations include uveitis, pulmonary fibrosis, aortic valvular disease, and amyloidosis (2, 4). Neurologic complications of AS are reported to occur in 2.1% of patients and include atlantoaxial subluxation with spinal cord compression or pathologic fractures of the rigid spine causing neurologic deficits. (2,4).

Cauda equina syndrome (CES) is a rare neurologic complication of long-standing AS; it was initially described by Bowie, Glasgow, and Hauge in 1961 (5, 6). Dural ectasia with or without nerve root adhesion to the enlarged dural sac is the typical finding seen on magnetic resonance imaging (MRI) and the main diagnostic feature associated with this condition (7-9). It is unclear what causes CES, and no proven or effective therapy has been reported to date. It is assumed that dural ectasia with subsequent fibrosis of the dura mater is the result of chronic inflammation, which at one point becomes unrecoverable (10-14). However, it is possible that unique

features related to spinal and dural anatomy and the distribution of mechanical forces in the thoraco-lumbar spine taking place over time in AS patients may have an as yet unrecognized contribution to the etio-pathogenesis of CES.

Challenges related to management of CES are almost overwhelming; case reports of patients treated with tumor necrosis factor inhibitors (TNFi), and lumbo-peritoneal shunting (LPS), have showed some effect, whilst other reports have revealed no improvement (15-20). CES, a rare but nevertheless well-defined neurologic complication of long-standing AS, has an extremely important impact on physical function and patients' quality of life. We have encountered six patients diagnosed with CES all of whom have suffered from long-standing AS. We set about to study their features intensely, review the literature, and generate hypotheses regarding why this event occurs as well as to speculate on the possibilities of early recognition and prevention.

Method:

We obtained permission from six patients with longstanding AS and CES to access their medical records and imaging studies for research purposes related to this case series and review. One of the six patients was deceased and her husband gave permission. All patients gave permission to discuss their cases with them to fill gaps where necessary. The process by which the investigators achieved access to personal health information from these subjects was approved by the Cedars-Sinai Institutional Review Board.

We collected and reviewed each patient's past medical history, imaging studies, disease duration, past therapies especially those that relate to AS, laboratory data, as well as any treatment they received for CES and follow up results of each case to the present time.

Cases:

Patient 1 is a 70-year-old female with almost 40yrs of AS who reported a very slow progression (over 14 years) of pins and needles sensations in the right foot. Symptoms progressed to involve the right leg along with increasing numbness. Eight years after symptom onset, she started experiencing a change in her bowel habits with more frequency and urgency, and then constipation. After six more years, she noticed slight weakness of the right quadriceps. She stopped playing competitive table tennis when the pins and needles sensation intensified, and numbness began to involve the buttock and perineum, and urinary urgency developed. She had been on NSAIDs and etanercept for her AS almost the entire time she had experienced the above neurologic symptoms. MRI of the lumbar spine showed diffuse bony fusion, L1-2 dural ectasia involving the right posterior elements with a posterolateral dural diverticulum. There was associated displacement of the distal conus, filum and nerves of the upper cauda equina to the right suggestive of associated tethering. She received four doses of infliximab but stopped after shingles developed. Laminectomy with untethering was performed. Dural patch placement was performed; however, the patch dehisced weeks after the procedure. She did not

experience relief in her symptoms with medical or surgical treatments. She now has chronic constipation and urinary retention being treated with medications. Physical activity, including prolonged sitting, is difficult for her at the present time.

Patient 2 is a 69-year-old male with a 20-year diagnosis of AS who reported two years of numbness and tingling in bilateral lower extremities that progressed to involve the saddle region. Pain became dominant as well as numbness. Urinary and bowel incontinence began to develop, and he learned to self-catheterize for relief. He could bike up to 50 miles on occasion prior to the diagnosis of CES. He used only NSAIDs for the treatment of his AS. Inflammatory markers were always normal. MRI of the spine disclosed multilevel remodeling and dehiscence of the posterior elements; there were multiple L1-S1 thecal sac sacculations with scalloping of the lamina, and disposition of the cauda equina into those sacculations. He was continued on NSAIDs without improvement of his symptoms and now requires a cane for ambulation.

Patient 3 is a 69-year-old female (now deceased) with over 30 years of AS who presented with 2 years of numbness and pain in the right buttock radiating to the right lower extremity, as well as numbness of the left foot. She had associated weakness of the lower extremities and loss of sensation with urination and bowel movements. These symptoms caused her to use a cane and stop driving. Physical exam showed atrophy of the calve muscles, absent ankle jerk reflexes, and abnormal sensation testing. MRI revealed dural ectasia L2-4 with adhesive arachnoiditis. She received a short 6-week course of adalimumab without improvement. Laminectomy and epidural steroid injections did not help. Subsequently she was diagnosed with metastatic pancreatic cancer and passed away shortly after that diagnosis was made.

Patient 4 is a 65-year-old male with almost 40 years of AS who presented with left foot drop associated with pain, numbness, weakness, and muscle atrophy over 4 years in duration. His symptoms extended proximally and began to involve the right side as well. Physical exam disclosed significant muscle atrophy, weakness, and abnormal sensation from the feet to the buttock. MRI revealed left-sided L1-3 dural ectasia containing several descending nerve roots as well as compressing the L5-S1 nerve roots. He had a bone spur surgical removal due to concern for nerve impingement but without benefit. He received adalimumab with unexpected worsening of symptoms, and this treatment was stopped.

Patient 5 is a 70-year-old male with 40 years of AS who presented with 6 years of numbness and pain in the left foot that gradually ascended to involve the entire leg and groin. He also developed bladder, bowel and sexual dysfunction. Because of the severity of his urinary issues, he suffered from frequent urinary tract infections and nephrolithiasis. He now performs urinary self-catheterization. Physical exam reveals abnormal sensation in the left leg and absent ankle reflexes. MRI disclosed multilevel dural ectasias without tethering of the conus medullaris. He was started

on adalimumab with subjective improvement in pain. Strength and sensation returned partially to the perineum at the time of his last assessment.

Patient 6 is a 69-year-old male with almost 30 years of AS who presented with numbness of the right foot that extended caudally, followed by weakness of the calf, as well as involvement of the left lower extremity and saddle areas. Prior to the diagnosis of CES, he travelled extensively to many national parks and participated in swimming and biking exercise activities. MRI demonstrated extensive L2-5 dural ectasias. He underwent LPS with significant reduction in neuropathic pain, however symptoms returned to previous levels 2 to 3 years following surgery. He now uses a cane to ambulate.

See appendix for list of patient demographics and characteristics as well as imagings.

Discussion:

Cauda equina syndrome (CES) remains today a rare but devastating neurologic complication of long-standing AS (21). Damage to the nerve roots appears to take place at the distal end of the spinal cord resulting in sensory and/or motor deficits of the pelvis and lower limbs including bladder and bowel dysfunction. Symptoms could develop rapidly, but most CES cases associated with AS take years to develop resulting in delay in diagnosis.

There are no specific clinical or imaging criteria for the diagnosis of CES. The diagnosis is supported by symptoms and radiographic findings. MRI is the preferred modality (21). A list of red flag symptoms used to diagnose CES includes: low back pain, weakness, sensory loss or pain; saddle anesthesia, urinary or bowel dysfunction, sexual dysfunction, and reduced reflexes (13).

In patients with CES but without AS the process is most commonly caused by lumbar disc herniation (22) with a pathogenesis understood to be underlying spinal canal narrowing with ligamentum flavum infolding (22). Further injury to the nerves could be perpetuated by reactive inflammation from any process, subsequently leading to nerve root compression (22-24). However, CES in AS patients occurs without obvious spinal canal or foraminal narrowing, or disc herniation presenting the challenge to understand why it takes place.

The six cases of CES with AS described herein have remarkable similarity to each other in that several decades of the disease had passed before neurologic symptoms and later signs appeared. All cases have fused spines and facet joints without spinal fractures, spinal stenosis, or disc herniation. The diagnosis of AS was established in the patients' early 30's but symptoms of back pain likely occurred much earlier. In addition, none of the cases displayed other extra-spinal manifestations. Three of the six patients participated in very active recreational exercises. One case of CES developed while the patient was taking a TNF inhibitor; attempts at treatment of

established signs and symptoms of CES with anti-TNF agents in the other cases did not reveal a pattern of success.

Theories on Pathogenesis:

The pathogenesis of CES in AS is unknown. One proposed theory is that the meninges expand in response to CSF pulse pressure allowing increased absorption of the CSF and subsequent dampening of the transmitted pressure variations (12). Other suggested mechanisms include small vessel angiitis of the vasa vasorum of the nerve roots, increased arterial pulsatile forces, or prior radiation treatments (12). Koboyashi et al. (25) studied cauda equina circulation of patients with neurogenic intermittent claudication in lumbar spinal canal stenosis using dynamic contrast-enhanced magnetic resonance imaging; he and others found abnormal contrast extravasation, delayed arterial uptake, and venous pooling of contrast suggesting disruption of the blood-brain barrier, findings which often occur with chronic inflammation of any cause. It is possible, according to Koboyashi, that edema from vascular compromise occurs secondary to chronic enthesitis in various tissues of the spinal canal in AS subjects, which in turn causes irreversible damage to the spinal nerve roots over time (25).

Recent attempts from clinical and imaging studies and animal model investigations to increase our understanding of the biomechanical basis for enthesitis do provide a unifying concept for enthesitis as a potential mechanism for development of CES in AS subjects (26, 3). The enthesis, a site of a ligament, tendon, or joint capsule attachment on to bone, may be the pathway by which the loading forces of the spine can produce inflammation setting in motion the cascade of events leading to nerve damage in CES patients. Based on these newly evolving concepts of AS pathogenesis, we propose that enthesitis in tissues of the spine is the inciting event that leads to the multiple downstream sequelae resulting in CES in AS patients. Primary AS inflammatory processes may extend to the dura mater from adjacent entheses causing inflammatory changes to the blood-nerve barrier and adhesion of the dura mater to the surrounding structures thereby resulting in reduction of compliance of the dural sac (25, 27). Stiffening of the dural sac would cause it to weaken over time encouraging the development of ectasias (28). The combination of mechanical distribution of the forces in the thoraco-lumbo-sacral spine, increased pressure in the lower vertebral column from a fused spine, associated edema, and reduced dural compliance, all of which could cause the formation of dural ectasias (29). Because more ligaments are found in the lateral-posterior portions of the spinal canal, it is possible that more enthesitis occurs in these regions and weakening of these structures results in the common finding of posterior sacculations on imaging. Displacement, tethering, and vascular damage to the nerve roots overtime could result in CES.

For patients who have been on biologic therapy with quiescent disease for years and then develop CES, one can argue that inflammation may not be the primary initiating event. However, it is likely that weakening of the dural sac would have already occurred prior to initiation of biologic therapy, since in almost all cases CES

develops in AS patients with complete fusion of the spine. This suggests a prolonged latency period from clinically active disease to development of CES following decades of apparent clinical remission.

Anatomy of the Spine and its Relation to CES:

A review of the anatomy of the spine segments involved in AS does provide us with a critical view of where and when CES may take place. There are three major ligaments in the spine: the anterior longitudinal ligament that runs along the front of the vertebral bodies, the posterior longitudinal ligament behind the vertebral bodies, and the ligamentum flavum that covers the dura mater and connects under the facet joints (13). These critical ligaments connect bones or cartilage elements together providing stability to a joint during rest and movement.

The posterior longitudinal ligament is intimately adherent to the fibrocartilages and contiguous margins of the vertebrae and is connected to the most superficial layer of the meninges, the dura mater (13). The dura has two layers: the superficial layer, which serves as the skull's inner periosteum, and a deep meningeal layer (13). When the dura covers the spinal cord, it is known as the dural or thecal sac. The dura also becomes the epineurium at the level of the dorsal root ganglion. The next layer of meninges is the arachnoid mater, which lines the dural sac (13). The third and deepest layer of the meninges is the pia mater, which closely covers the brain, spinal cord, and the nerve roots, and eventually forms the filum terminale, which arises from the conus medullaris and anchors the spinal cord to the coccyx. The cauda equina consists of nerve roots distal to the conus containing afferent dorsal sensory fibers and efferent ventral motor fibers. These nerve roots enter the spinal cord through both sides of the vertebral bodies, with every added cephalad nerve root displacing subsequent distal nerve roots posteriorly maintaining the orientation of motor fibers being anteromedial, and sensory fibers posterolateral (13).

From an appreciation of the complex mechanical anatomy of the spine, we observe that the ligaments of the vertebral column are closely associated with the meninges; therefore, enthesitis of the vertebral column would necessarily affect the nerve roots. Weakening of the ligaments and underlying meninges could occur both from inflammation and erosion as well as from mechanical tension on the spinal connective tissue from rigidity created by ankylosis. Zarzur (28) observed that the posterior lumbar dura mater was easily distensible only in the transverse direction. Therefore, fusion of the spine may limit the ability of the dura to redistribute pressure; this observation, in part, may explain the specific mechanical contributions to the formation of posterior dural sacculations. We could not examine whether ossification or calcification of the posterior longitudinal ligaments occurred in our patient cohort due to insufficient CT imaging data.

The work of Ward et al. (30-32) suggests that syndesmophytes (SM) are non-randomly distributed around the disc margins, and they occurred most often at the postero-lateral rim. We would expect random distribution of SM's if they were

formed solely in response to inflammation. Further, orthopedists and biomechanical engineers cite this area as the middle column of the spine where mechanical stress is concentrated at the base of the pedicles. Therefore these observations suggest that mechanical forces in this area of spine may play an important role in SM's initiation as well as in spinal enthesitis.

Therapeutics:

There has been no demonstrated effective medical or surgical treatment for CES once it occurs in AS (20). Ahn et al. (20) performed a meta-analysis for treatment effects of CES in AS and found that steroids had not been effective. While NSAIDs appeared to improve symptoms, they did not alter neurologic deficits (20). Others reported improvement after treatment with infliximab, but this is not consistent across reports (17). Surgical intervention such as LPS, untethering, and laminectomy also have displayed inconsistent results (15, 16). Some experts have suggested early medical treatment is crucial for making as full a recovery as possible for typical CES, especially in those who have evidence of active inflammation (33). Unfortunately, early diagnosis is difficult to make, and treatments inconsistently succeed. Degree of recovery is limited even in those that have a partial response.

The information presented in this report leads to the conundrum of when should CES be suspected in AS patients. The following questions need to be addressed if we are going to understand how to diagnosis and manage this condition. How and when do we screen, predict progression, and differentiate CES from other causes of pain and neuropathy? Is it too late to intervene when patients display the initial symptoms of neuropathy when chronic inflammation presumably has already taken place? Are physical mechanical forces on the spine a major cause of CES in AS? Future attempts to identify at risk patients early may help us understand more about CES pathogenesis and treatment options.

Conclusion:

CES is a rare yet debilitating neurologic complication of long-standing AS and the pathophysiology and treatments are far from clear. Herein we reported six patients with CES and AS, and reviewed current understanding of the pathogenesis of CES in AS. We postulate that chronic enthesitis of the vertebral column initiates the process that results in dural stiffening and formation of ectasias causing downstream nerve root damage. Mechanical force transduction in the spine may play a pivotal etiologic role.

Word Count: 2992 (Limit: 3000)

References:

1. Dau JD, Lee M, Ward MM, Gensler LS, Brown MA, Learch TJ, et al. Opioid Analgesic Use in Patients with Ankylosing Spondylitis: An Analysis of the Prospective Study of Outcomes in an Ankylosing Spondylitis Cohort. *J Rheumatol* 2018;45:188-194

2. Jamalyaria F, Ward MM, Assassi S, Learch TJ, Lee M, Gensler LS, et al. Ethnicity and disease severity in ankylosing spondylitis a cross-sectional analysis of three ethnic groups. *Clin Rheumatol* 2017;36:2359-2364
3. Watad A, Cuthbert RJ, Amital H & McGonagle D. Enthesitis: Much more than focal insertion point inflammation. *Curr Rheumatol Rep* 2018;20:41
4. Wysham KD, Murray SG, Hills N, Yelin E & Gensler LS. Cervical spinal fracture and other diagnosis associated with mortality in hospitalized ankylosing spondylitis patients. *Arthritis Care Res* 2017;69:271-277.
5. Hassan I. Cauda equina syndrome in ankylosing spondylitis: a report of six cases. *J Neurol Neurosurg Psychiatry* 1976;39:1172-1178
6. Tullous MW, Skerhut HE, Story JL, Brown WE Jr, Eidelberg E, Dadsetan MR, et al. Cauda equina syndrome of long-standing ankylosing spondylitis. *J Neurosurg* 1990;73:441-447
7. Arslanoglu A & Aygun N. Magnetic resonance imaging of cauda equina syndrome in long-standing ankylosing spondylitis. *Australas Radiol* 2007;51, 375-377
8. LanHH, Chen DY, Chen CC, Lan JL & Hsieh CW. Combination of transverse myelitis and arachnoiditis in cauda equina syndrome of long-standing ankylosing spondylitis: MRI features and its role in clinical management. *Clin Rheumatol* 2007;26:1963-1967
9. Levine DS, Forbat SM, & Saifuddin A. MRI of the axial skeletal manifestations of ankylosing spondylitis. *Clin Rad* 2004;59:400-413
10. Tyrrell PNM, Davies AM, & Evans N. Neurological disturbances in ankylosing spondylitis. *Annals of the rheumatic diseases* 1994;53:714-717
11. Van Hoydonck M, de Vlam K, & Lories RJ. Destructive dural ectasia of dorsal and lumbar spine with cauda equina syndrome in a patient with ankylosing spondylitis. *Open Rheumatol J* 2010;4:31-34
12. Ha SW & Son BC. Cauda equina syndrome associated with dural ectasia in chronic ankylosing spondylitis. *J Korean Neurosurg Soc* 2014;56:517-520
13. Gitelman A, Hishmeh S, Morelli BN, Joseph SA Jr, Casden A, Kuflik P, et al. Cauda equina syndrome: A comprehensive review. *Am J Orthop* 2008; 37:556-562

14. Liu CC, Lin YC & Chang TP. Cauda equina syndrome and dural ectasia: rare manifestations in chronic ankylosing spondylitis. *Br J Radiol* 2011;84:123-125
15. Dinichert A, Cornelius JF, Lot G. Lumboperitoneal shunt for treatment of dural ectasia in ankylosing spondylitis. *J Clin Neurosci* 2008;15:1179-1182
16. Ea HK, Lioté F, Lot G & Bardin T. Cauda equina syndrome in ankylosing spondylitis: successful treatment with lumboperitoneal shunting. *Spine* 2010;35:1423-1429
17. Cornec D, Pensec VD, Joulin SJ & Saraux A. Dramatic efficacy of Infliximab in cauda equina syndrome complicating ankylosing spondylitis. *Arthritis Rheum* 2009;60:1657-1660
18. Bele K, Pendharkar HS, Venkat E & Gupta AK. Anterior dural ectasia mimicking a lytic lesion in the posterior vertebral body in ankylosing spondylitis. *J Neurosurg Spine* 2011;15:636-640
19. Kotil K & Yavasca P. Lumbar radiculopathy in ankylosing spondylitis with dural ectasia. *J Clin Neurosci* 2007;14:981-3
20. Ahn NU, Ahn UM, Nallamshetty L, Springer BD, BUchowski JM, Funches L, et al. Cauda equina syndrome in ankylosing spondylitis (the CES-AS syndrome): meta-analysis of outcomes after medical and surgical treatments. *J Spinal Disord* 2001;14:427-33
21. Kiltz U, Baraliakos X, Regel A, Bühring B & Braun J. Causes of pain in patients with axial Spondyloarthritis. *Clin Exp Rheumatol* 2017;35:102-107
22. Korse NS, Kruil MC, Peul WC & Vieggeert-Lankamp CLA. Lumbar spinal canal MRI diameter is smaller in herniated disc cauda equina syndrome patients. *Plos One* 2017;12
23. Oba H, Takahashi J, Futatsugi T, Mogami Y, Shibata S, Ohji Y & Tanikawa H. Study of dural sac cross-sectional area in early and late phases after lumbar decompression surgery. *Spine J* 2013;13:1088-1094
24. Chau AMT, Xu LL, Pelzer NR & Gragnaniello C. Timing of surgical intervention in cauda equina syndrome: A systematic critical review. *World Neurosurg* 2014;81:640-650
25. Kobayashi S, Suzuki Y, Meir A, Al-Khudairi N, Nakane T & Hayakawa K. Circulatory dynamics of the cauda equina in lumbar canal stenosis using dynamic contrast-enhanced magnetic resonance imaging. *Spine J* 2015;15:2132-2141.

26. Kehl AS, Corr M, Weisman MH. New Insights Into Pathogenesis, Diagnostic Modalities, and Treatment. *Arthritis Rheumatol* 2016;68:312-322
27. Maki Y, Takayama M, Hayashi H, Yokoyama Y & Agawa Y. Cauda equina syndrome due to dural sac shift with engorgement of the epidural venous plexus: rare complication after lumbar microdiscectomy. *World Neurosurg* 2017;104:15-18
28. Zarzur E. Mechanical properties of the human lumbar dura mater. *Arq Neuropsychiatr* 1996;54:455-60
29. van Engelen SJPM, Bisshop A, Smit TH, van Royen BJ & van Dieën JH. The effect of neighboring segments on the measurement of segmental stiffness in the intact lumbar spine. *The spine journal* 2015;15:1302-1309
30. Tan S, Yao L & Ward MM. Thoracic syndesmophytes commonly occur in the absence of lumbar syndesmophytes in ankylosing spondylitis: A computed tomography study. *J Rheumatol*, 2017;44:1828-1832
31. Tan S, Yao J, Flynn JA, Yao L & Ward MM. Quantitation of circumferential syndesmophyte height along the vertebral rim in ankylosing spondylitis using computed tomography. *J Rheumatol*, 2015;42:472-478
32. Tan S, Dasgupta A, Yao J, Flynn JA, Yao L & Ward MM. Spatial distribution of syndesmophytes along the vertebral rim in ankylosing spondylitis: preferential involvement of the posterolateral rim. *Ann Rheum Dis* 2016; 75:1951-1957
33. Thakur JD, Storey C, Kalakoti P, Ahmed O, Dossani RH, Menger RP, et al. Early intervention in cauda equina syndrome associated with better outcomes: a myth or reality? Insights from the nationwide inpatient sample database (2005-2011). *Spine J* 2017;17:1435-1448
-

Patient #	Status	Gender	Age	HLAB27	Extraspinal Disease	Family Hx of SpA	Smoker	Physical activity	Spinal Radiation	TNFi before dx of CES	Treatment for AS before CES
1	Alive	F	70	Yes	No	No	No	Competitive table tennis	Yes	Yes	NSAID, etanercept
2	Alive	M	69	Yes	No	Yes	No	Swim, bike (20-50mile)	No	No	NSAIDs
3	Deceased	F	69	Yes	No	No	No	unknown	unknown	No	NSAIDs
4	Alive	M	65	Yes	Iritis	No	Yes	unknown	unknown	No	NSAIDs
5	Alive	M	70	Yes	Iritis, Colitis, Entesitis	Reiter's Syndrome	No	unknown	unknown	No	NSAIDs
6	Alive	M	69	Unknown	iritis, colitis, entesitis, psoriasis	No	Yes	walk, bike, swim	No	No	NSAIDs

Table 1: Demographic summary of six patients with cauda equina syndrome. Sx: symptoms. AS: ankylosing spondylitis. Dx: diagnosis. CES: cauda equine syndrome. NSAIDs: non-steroidal anti-inflammatory drugs. Wks: weeks.

Patient #	Age at First Sx of AS (yrs)	Age at Dx of AS (yrs)	Age at first Sx of CES (yrs)	Age at Dx of CES (yrs)	Duration of Diagnosed AS at time of Diagnosed CES (yrs)	Presenting Sx of CES	Imaging abnormalities (a)	Medical Treatment for CES	Response	Surgery for CES	Response	Mobility after CES dx
1	21	29	51	65	36	Pins and needles of the R foot progressively up to the perineum with episodes of shock-like pain, numbness and weakness, urinary and bowel urgency	Yes	Infliximab (stopped for shingles), duloxetine, gabapentin	No	Yes	No	walks slowly, cannot sit >2hrs
2	27	38	54	58	20	Numbness and tingling in the feet and saddle, urinary and bowel incontinence	Yes	NSAIDs	No	No	No	cane
3	20	30	62	64	34	Saddle and R lower extremity pain, weakness, numbness, tenesmus with bowel movement and urine	Yes	pregabalin, Adalimumab	No	Yes	No	cane
4	20	24	59	63	39	L foot drop, weakness, atrophy, numbness and pain of the feet then to legs	Yes	Adalimumab	No	Yes	No	unknown
5	unknown	28	62	68	40	Numbness and pain of L foot then leg and saddle. Bowel, bladder and sexual dysfunction	Yes	Adalimumab	Yes	No	NA	Cane
6	18	25	47	52	27	Numbness, pain and weakness of the R foot with progression to the butt and left side.	unknown	NSAIDs	No	Yes	Yes	cane

Table 2: Summary of duration of disease at diagnosis, clinical features, treatments and responses in six patients with cauda equina syndrome. Sx: symptoms. AS: ankylosing spondylitis. Dx: diagnosis. CES: cauda equine syndrome. R: right. L: left. NSAIDs: non-steroidal anti-inflammatory drugs. Wks: weeks. CSF: cerebral spinal fluid.

(a): All patients had imaging findings of dural ectasia with displacement of the cauda equina, and ankylosis of the spine. There were no findings of spinal canal stenosis, foraminal narrowing, vertebral fracture, vertebral mass, disc herniation, or arachnoiditis in any of the imaging findings.

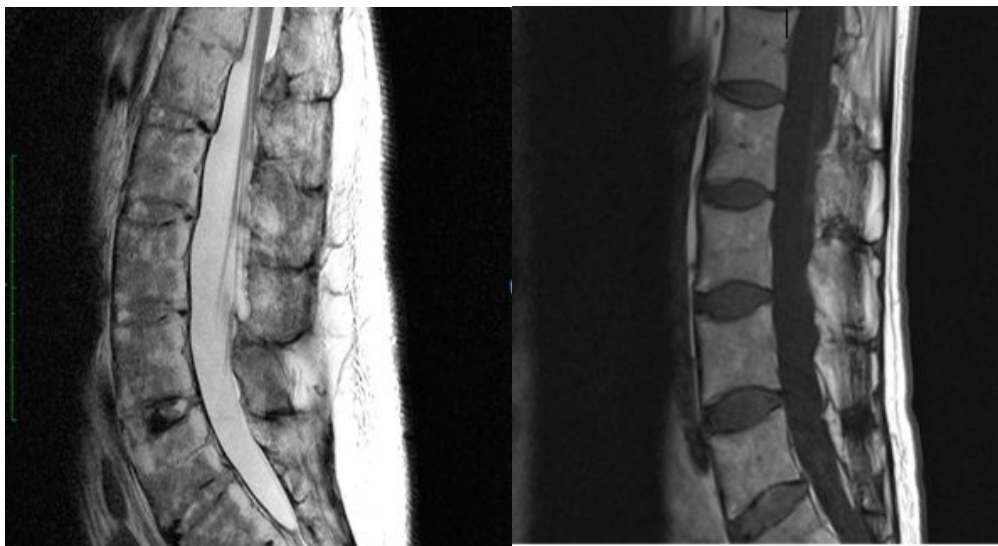


Image 1: left: T-2 weighted sagittal scan of the lumbar spine demonstrating the conus terminating at the L-1 level, Right: T1-weighted non-contrast sagittal scan of the lumbar spine showing a widely patent spinal canal

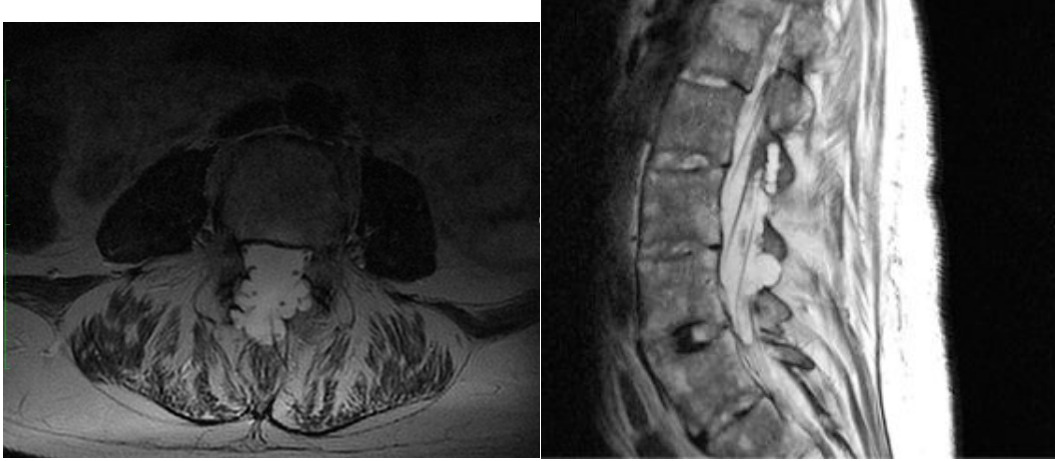

Image 2: Left: T2-Weighted axial scan at the L 4 level in the lumbar spine demonstrating posterior dural ectasia, Right: T-2 weighted sagittal scan of the lumbar spine showing the posterior location of the abnormalities with the normal contour of the anterior spinal canal