

Tongue Atrophy in Sjögren Syndrome Patients with Mucosa-associated Lymphoid Tissue Lymphoma: Autoimmune Epithelitis beyond the Epithelial Cells of Salivary Glands?

Evangelia Zampeli , Eleni-Marina Kalogirou, Evangelia Piperi, Clio P. Mavragani, and Haralampos M. Moutsopoulos

ABSTRACT. Objective. Primary Sjögren syndrome (pSS), an autoimmune epithelitis, bears the risk of evolving to non-Hodgkin lymphoma and most frequently to the mucosa-associated lymphoid tissue (MALT) subtype. Based on the observation that pSS patients with MALT present a more atrophic and more intensely fissured tongue, we aimed to semiquantify severity of tongue atrophy and clinically assess lingual appearance in pSS patients with and without MALT, and investigate whether tongue atrophy and fissured appearance could serve as clinical indicators/signs of MALT.

Methods. A blinded complete oral examination was performed in pSS patients with and without MALT. Tongue atrophy was scored using a semiquantified atrophy score. Clinical and laboratory variables were recorded for all patients.

Results. After excluding pSS patients with oral candidiasis, iron deficiency, and megaloblastic anemia, 19 pSS patients with salivary MALT were matched 1:3 for age, sex, and disease duration with 57 pSS patients without MALT. The pSS-MALT patients had increased prevalence of salivary gland enlargement, lymphadenopathy, monoclonal gammopathy, rheumatoid factor positivity, higher focus and Tarpley scores in the minor salivary gland biopsy, and hyposalivation, compared to the pSS non-MALT patients. A significantly higher prevalence of tongue atrophy (68% vs 30%, $p = 0.006$) and fissured tongue (89% vs 33%, $p < 0.001$) was observed in the former group. Multivariate analysis showed that fissured tongue appearance, hyposalivation, and lymphadenopathy associate independently with salivary MALT in pSS.

Conclusion. These results suggest that pSS patients with lymphoid malignancy exhibit a more atrophic and more fissured tongue. This particular clinical tongue appearance can serve as an additional clinical sign for salivary MALT lymphoma in pSS patients. (J Rheumatol First Release July 15 2018; doi:10.3899/jrheum.180101)

Key Indexing Terms:

SJÖGREN SYNDROME TONGUE ATROPHY RISK FACTORS MALT LYMPHOMA

From the Institute for Systemic Autoimmune and Neurological Diseases; Department of Oral Medicine and Oral Pathology, Faculty of Dentistry, School of Health Sciences, National and Kapodistrian University of Athens; Department of Pathophysiology, and Department of Physiology, Medical School, National and Kapodistrian University of Athens; Academy of Athens, Athens, Greece.

E. Zampeli, MD, Institute for Systemic Autoimmune and Neurological Diseases; E.M. Kalogirou, DDS, Department of Oral Medicine and Oral Pathology, Faculty of Dentistry, School of Health Sciences, National and Kapodistrian University of Athens; E. Piperi, DDS, Department of Oral Medicine and Oral Pathology, Faculty of Dentistry, School of Health Sciences, National and Kapodistrian University of Athens; C.P. Mavragani, MD, Department of Pathophysiology, and Department of Physiology, Medical School, National and Kapodistrian University of Athens; H.M. Moutsopoulos, MD, FACP, FRCP (hc), Master ACR, Institute for Systemic Autoimmune and Neurological Diseases, and Academy of Athens.

Address correspondence to Dr. E. Zampeli, Institute for Systemic Autoimmune and Neurological Diseases, M. Asias 75, 11527, Athens, Greece. E-mail: zampeli@zampeli@gmail.com

Accepted for publication May 16, 2018.

Sjögren syndrome (SS) or autoimmune epithelitis is a chronic, autoimmune systemic disorder. Its clinical spectrum ranges from local manifestations arising from exocrine gland involvement, to extraglandular manifestations resulting either from periepithelial infiltrates or immune complex deposition^{1,2,3}.

The most severe complication of SS is the development of B-cell non-Hodgkin lymphoma (NHL), especially that of mucosa-associated lymphoid tissue (MALT) type, in about 5–10% of patients⁴. Several clinical, serological, histopathological, and genetic factors have been associated with an increased risk for NHL development in the context of SS^{5,6,7}. It has been shown that initial presentation of SS associates to subsequent outcome and that the overall mortality of SS patients compared to the general population is increased only in patients with adverse predictors⁸. Previously, a predictive risk score for NHL development in SS patients was formu-

lated, taking into account clinical manifestations [i.e., salivary gland enlargement (SGE), lymphadenopathy, and Raynaud phenomenon] and serological factors, including presence of anti-Ro/SSA and/or anti-La/SSB autoantibodies, rheumatoid factor (RF) positivity, monoclonal gammopathy, and serum C4 hypocomplementemia⁹.

The salivary and lacrimal glands are among the major exocrine target tissues of the lymphocytic infiltration, the histopathological hallmark of SS, leading to gland destruction and severe functional impairment^{2,10}. As a result of salivary gland involvement, patients with SS experience hyposalivation, accompanied by alterations in the saliva protein composition, that predispose to changes in oral microflora, increased susceptibility to fungal infections, and dental caries^{5,11,12}. Oral discomfort, mucosal soreness when eating or swallowing dry foods, dysgeusia, halitosis, and a burning sensation are frequently reported by patients with SS. Sticky or frothy saliva, or even absence of saliva pooling in the floor of the mouth, food debris on mucosal surfaces or teeth, and recurrent swellings of the major salivary glands are common manifestations of xerostomia^{11,12}.

An oral manifestation frequently encountered in patients with SS is the fissured tongue, where the lingual dorsum exhibits multiple furrows of variable size and depth, which contribute to a cobblestone-like texture of the tongue. This fissured tongue appearance is known to be associated with partial to complete tongue atrophy as a result of hyposalivation and lingual depapillation¹². Data on clinical, serological, and histopathological associations of tongue morphology in the setting of SS are scarce, while a possible association between tongue atrophy, fissured tongue appearance, and NHL among patients with SS has not yet been studied.

Based on the clinical observation that primary SS (pSS) patients who also have MALT present a much more intense lingual atrophy and fissured tongue appearance, we sought to investigate whether tongue atrophy and this particular tongue appearance in the setting of pSS could be independent variables in pSS patients with MALT.

MATERIALS AND METHODS

Study subjects. In the present case-control study, the cohort comprised 19 pSS patients (meeting the American-European Consensus Criteria)¹³ complicated with localized salivary MALT (pSS-MALT) and 57 age-, sex-, and disease duration-matched (1:3) pSS patients without MALT (pSS non-MALT). All patients were followed in 2 different outpatient rheumatology clinics (Department of Pathophysiology, Medical School, National and Kapodistrian University of Athens, and Institute for Autoimmune Systemic and Neurological Diseases, Athens, Greece). Exclusion criteria for all participants included diabetes mellitus, iron deficiency anemia, megaloblastic anemia, presence of periodic acid-Schiff (PAS)-positive results for oral candidiasis, presence of indices or manifestations of extraglandular lymphoma, dystrophy, or neurological diseases, use of psychotropic medication, and prior treatment with cytotoxic chemotherapy, rituximab, or irradiation.

All patients were referred for oral examination. Their demographic,

clinical, biochemical, serological, and histopathological data were retrieved from the patients' records kept in the 2 outpatient rheumatology clinics.

This study was approved by the Ethical/Scientific Committee of the "Laikon" Hospital (12/20-4-2016) and all participants provided informed consent according to the Declaration of Helsinki.

Tongue morphology and atrophy evaluation. A complete oral mucosal examination was performed in all study subjects. Morphological features of the tongue and the tongue atrophy was evaluated and scored independently by 2 oral medicine specialists (EP and EMK). Each examiner was blinded to the patients' clinical and laboratory data, as well as to the results of the other examiner. At the time of oral examination, a digital image of the tongue was recorded by the examiner. The tip of the protruded tongue was held in the left hand of the examiner and photographs of the lingual dorsum were taken with an 8-megapixel digital camera, downloaded and stored in a Microsoft Windows XP computer. A modified semiquantitative atrophy score of tongue papillae was used¹⁴. In brief, the lingual dorsum (area between the tip of the tongue and the circumvallate papillae) was divided into posterior, middle, and anterior parts, and the grade of atrophy of the filiform and fungiform papillae was scored from 0 to 2 for each single part. Score = 0 corresponded to the normal lingual papillae; score = 1 to rounded or flattened-and-fewer or nonkeratinized filiform papillae and to unclear in shape or flattened fungiform papillae with indistinct blood vessels; and score = 2 was adopted in case of diminished papillae. This scoring system resulted in 6 different atrophy values (i.e., 2 values in every tertile, each corresponding to the filiform and the fungiform papillae), with a maximum final tongue atrophy score (filiform and fungiform papillae for the entire tongue) of 12 (Figure 1). Absence of tongue atrophy was defined as having a maximum final tongue atrophy score of ≤ 2 (Figure 2A), while presence of tongue atrophy was defined as having a maximum final tongue atrophy score of ≥ 3 (Figure 2B and 2C).

Cytologic evaluation of Candida presence. Oral examination comprised the evaluation of clinical appearance of the lips, the tongue, the floor of the mouth, the gingiva, the cheeks, and the palate. Of note, none of the patients included in the study was wearing dentures, the fitting surface of which can serve as a niche for yeasts and be a predisposing factor for oral erythematous candidiasis, especially on the hard palate¹⁵. Therefore, in the patients included in the study, at the time of oral examination, smears from the lingual dorsum were collected by gently scraping the tongue using a sterile brush (Kolplast, and Cytobrush, PadtanTeb) to evaluate *Candida albicans* presence. The samples were removed from the brush, applied uniformly on slides and were immediately immersion-fixed in hydrated alcohol for staining with PAS stain. The slides were evaluated for the presence of *Candida hyphae* and spores, and patients with PAS-positive results were not included in the study.

Measurement of whole unstimulated salivary flow. All patients had their whole unstimulated salivary flow (UWSF) measured. Assessment was performed at mid-morning, at least 1 h after the last food or beverage intake. Smoking, chewing gum, and consumption of coffee were also prohibited 1 h preceding the evaluation. The patients were instructed not to masticate, swallow, or speak for a period of 15 min and during that time, they were asked to collect all saliva produced in the oral cavity into a calibrated conical tube by drooling or gentle spitting. The saliva was allowed to settle and then measured in a graduated syringe. The flow was expressed in ml/min and an unstimulated rate of < 1.5 ml/15 min was considered as indicative of hyposalivation^{16,17}.

Statistical analysis. Statistical analysis was performed using SPSS 21.0 (SPSS Inc.) and significance was defined as $p < 0.05$ throughout. Qualitative and quantitative features between pSS patients with and without MALT were compared using the Fisher exact/chi-square test and Mann-Whitney U tests, respectively. For data analysis, univariate and multivariate logistic regression models were implemented. The outcome variable of interest was the presence of MALT lymphoma. We first compared clinical, laboratory/serological features, and oral examination findings in the 2 groups (univariate analysis). Next, 2 separate multivariate

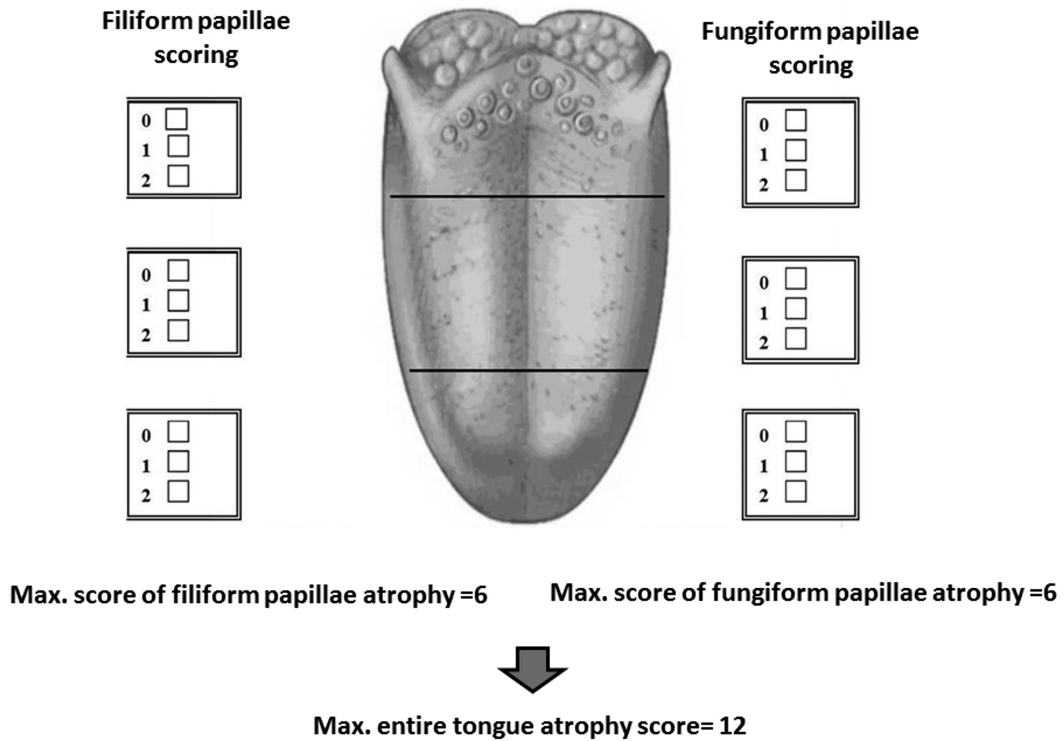


Figure 1. Tongue atrophy scoring. The lingual dorsum is divided into posterior, middle, and anterior parts, and the grade of atrophy of the filiform and fungiform papillae is scored from 0 to 2 for each tertile. This scoring system results in a maximum (max.) final tongue atrophy score (filiform and fungiform papillae for the entire tongue) of 12.

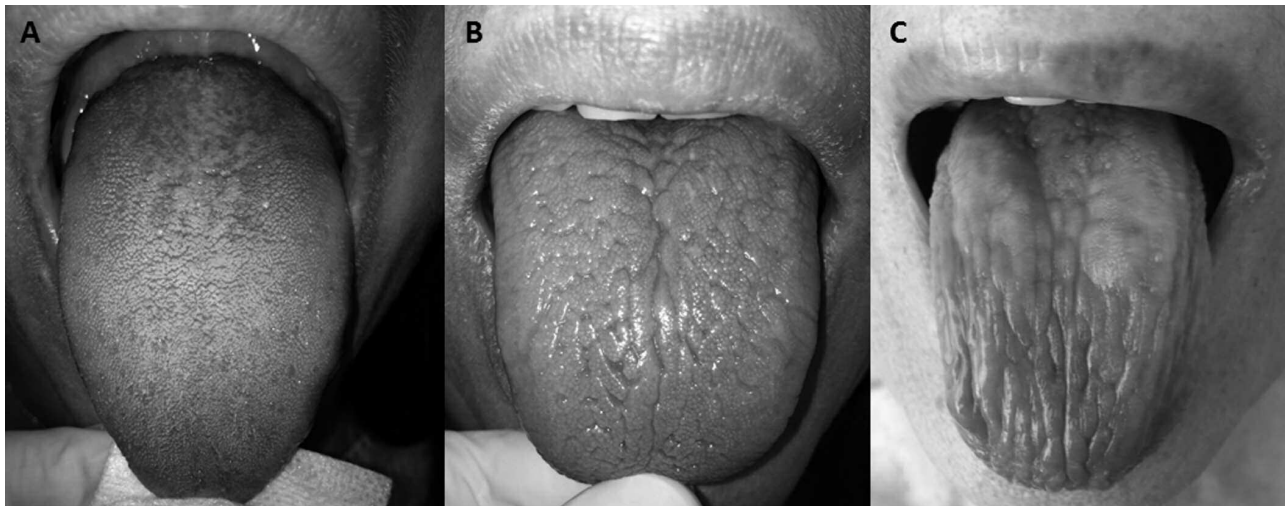


Figure 2. Representative tongue images of pSS patients with (A) normal, nonatrophic lingual papillae and nonfissured tongue (maximum final tongue atrophy score = 0/12); (B) fissured (scrotal) tongue with flattened or rounded filiform papillae and flattened fungiform papillae in all 3 tongue tertiles (maximum final tongue atrophy score = 7/12); (C) dry, lobulated, and shiny atrophic tongue appearance because of loss of filiform and fungiform papillae, especially in the anterior and middle tongue tertiles (maximum final tongue atrophy score = 11/12). pSS: primary Sjögren syndrome.

models were constructed, each of which included only those variables of oral examination and clinical findings found to be significant in the univariate analysis. For fitting the final models, a backward stepwise approach was used. At each step of the process, the least significant variable was eliminated from the model, and the model was rerun with the remaining variables. Further, clinical and laboratory/serological characteristics of pSS-MALT patients with and without tongue atrophy were compared by univariate analysis.

RESULTS

The patients with pSS were all women in both groups. The pSS non-MALT ($n = 57$) and pSS-MALT ($n = 19$) patients were of similar age (mean age 56.4 ± 13.2 and 60.0 ± 11.3 yrs, respectively; $p = 0.287$), and disease duration (7.3 ± 7.4 and 6.9 ± 5.9 yrs, respectively; $p = 0.822$). In both the pSS non-MALT and pSS-MALT groups, patients were treated

with pilocarpine at doses ranging from 10 mg to 15 mg daily (31% and 33%, respectively; $p = 0.852$) and/or hydroxychloroquine 200 mg once a day (23% and 20%, respectively; $p = 0.803$). None of the patients in either group were taking glucocorticoids.

In Table 1, the prevalence of clinical manifestations and laboratory/serological characteristics of pSS patients with and without MALT are presented (univariate analysis). In our cohort, pSS patients having evolved to MALT (pSS-MALT) showed increased prevalence of SGE and lymphadenopathy. From the laboratory, serological, and histological variables, pSS-MALT patients presented significantly higher prevalence of monoclonal gammopathy, RF positivity, and higher focus score as well as Tarpley score in the minor salivary gland (MSG) biopsy compared to the age-, sex-, and disease duration-matched pSS non-MALT patients.

The results from the oral examination of patients with pSS in both groups confirmed the initial observation concerning the lingual atrophy in pSS patients with MALT. Patients with pSS-MALT showed a significantly higher prevalence of tongue atrophy, expressed as a maximum final tongue atrophy score of ≥ 3 (68% vs 30%, $p = 0.006$) compared to the non-MALT pSS patients. The patients with pSS-MALT presented, as expected, significantly higher prevalence of hyposalivation (defined as UWSF < 1.5 ml/15 min) compared to the pSS non-MALT patients (84% vs 25%, $p < 0.001$), with a mean UWSF of 0.5 ± 0.8 versus 2.2 ± 1.1 ml/15 min ($p < 0.001$), respectively (Table 2). Interestingly,

an increased prevalence of fissured (scrotal) tongue was observed in both groups of patients, with a statistically significant difference favoring patients with pSS-MALT (89% vs 33%, $p < 0.001$).

To determine whether tongue atrophy and/or morphology could be independent signs associated with MALT in pSS patients, a multivariate regression analysis (backward stepwise method) was used in 2 steps. In the first step, the oral variables that significantly differed between the 2 groups were analyzed and thereafter, the clinical variables that differed in the 2 groups and are known to confer an increased risk for lymphoma (SGE, lymphadenopathy) were added. In addition to lymphadenopathy, more intense hyposalivation and a more prevalent fissured tongue appearance seem to be independent oral features associated with MALT in patients with pSS (OR 0.071, 95% CI 0.005–1.031; OR 0.169, 95% CI 0.033–0.867; OR 0.070, 95% CI 0.007–0.669, respectively; Table 3). Further, to exclude possible disease manifestations that could affect the more atrophic and fissured tongue appearance in patients with pSS-MALT, a univariate analysis was performed including only those patients. In this subset analysis, patients with pSS-MALT were stratified based on the presence or absence of tongue atrophy. Clinical and laboratory/serological manifestations were not different in pSS-MALT patients having lingual atrophy compared to the pSS-MALT patients not demonstrating lingual atrophy, with the exception of anti-Ro/SSA and/or anti-La/SSB positivity, which was more prevalent in pSS-MALT patients with

Table 1. Clinical manifestations and histopathological/laboratory/serological features in the 2 groups of patients. Values are n (%).

Variables	pSS non-MALT, n = 57	pSS-MALT ^δ , n = 19	p
Clinical manifestations			
Oral dryness (subjective)	46/57 (81)	18/19 (95)	0.274
Ocular dryness (subjective)	43/57 (75)	17/19 (89)	0.330
SGE	13/57 (23)	11/19 (58)	0.009
Raynaud phenomenon	13/57 (23)	7/19 (37)	0.243
Palpable purpura	5/57 (9)	2/19 (10)	1.000
Arthralgias/myalgias	35/55 (64)	14/19 (73)	0.576
Arthritis	10/57 (17)	4/19 (21)	0.740
Lymphadenopathy	3/57 (5)	5/19 (26)	0.020
Histopathological/laboratory/serological features			
MSG biopsy focus score ≥ 1	29/57 (51)	17/19 (89)	0.003
MSG biopsy Tarpley score > 2	17/57 (30)	17/19 (89)	< 0.001
Leukopenia*	6/56 (11)	2/19 (10)	1.000
ANA-positive [†]	36/57 (63)	16/19 (84)	0.153
C4 hypocomplementemia [‡]	27/51 (53)	9/17 (53)	1.000
Anti-Ro/SSA- and/or anti-La/SSB-positive	36/57 (63)	14/19 (74)	0.235
RF-positive	26/57 (46)	16/19 (84)	0.001
Monoclonal gammopathy	0/44 (0)	5/17 (29)	0.001

^δ pSS-MALT: pSS patients with MALT lymphoma, matched 1:3 for age, sex, and disease duration with pSS non-MALT patients. * Defined as white blood cells $< 3000/\text{mm}^3$ on 3 separate occasions. [†] Titers $> 1:160$. [‡] Defined as serum C4 levels < 20 mg/dl on 3 separate occasions. Values in bold face are statistically significant. pSS: primary Sjögren syndrome; MALT: mucosa-associated lymphoid tissue; SGE: salivary gland enlargement; MSG: minor salivary gland; ANA: antinuclear antibodies; RF: rheumatoid factor.

Table 2. Oral examination findings in the 2 groups of patients. Values are n (%).

Oral Examination Findings	pSS non-MALT, n = 57	pSS-MALT ^δ , n = 19	p
UWSF ≤ 1.5 ml/15 min	14/57 (25)	16/19 (84)	< 0.001
Presence of tongue atrophy	17/57 (30)	13/19 (68)	0.006
Fissured tongue	19/57 (33)	17/19 (89)	< 0.001

^δ pSS-MALT: pSS patients with MALT lymphoma, matched 1:3 for age, sex, and disease duration with pSS non-MALT patients. Values in bold face are statistically significant. pSS: primary Sjögren syndrome; MALT: mucosa-associated lymphoid tissue; UWSF: unstimulated whole salivary flow.

Table 3. Multivariate analysis. Independent oral and clinical findings associated with MALT lymphoma in patients with pSS.

Independent Variables	OR (95% CI)	p
Oral findings		
UWSF ≤ 1.5 ml/15 min	0.09 (0.015–0.560)	0.010
Fissured tongue	0.11 (0.017–0.711)	0.020
Presence of tongue atrophy	2.364 (0.401–14.500)	0.352
Oral and clinical findings		
UWSF ≤ 1.5 ml/15 min	0.169 (0.033–0.867)	0.033
Fissured tongue	0.070 (0.007–0.669)	0.021
Lymphadenopathy	0.071 (0.005–1.031)	0.050
SGE	0.249 (0.058–1.079)	0.063

Values in bold face are statistically significant. MALT: mucosa-associated lymphoid tissue; pSS: primary Sjögren syndrome; UWSF: unstimulated whole salivary flow; SGE: salivary gland enlargement.

tongue atrophy (92% vs 40%, p = 0.015; Table 4). Further, the focus score in the MSG biopsy did not correlate with the presence of tongue atrophy in the patients with pSS-MALT (p = 0.217).

DISCUSSION

The results of our study demonstrate that pSS patients with localized salivary MALT present more intense tongue atrophy and an increased prevalence of fissured tongue, as well as more intense hyposalivation.

The oral examination finding of an atrophic tongue can be attributed to several local and systemic conditions. *Candida* infection is considered one of the primary causes of generalized tongue depapillation in the setting of SS^{18,19}. An atrophic tongue can also be attributed, directly or indirectly, to several systemic conditions, including blood dyscrasias

Table 4. Clinical manifestations and histopathological/laboratory/serological features in the pSS-MALT patients with and without tongue atrophy. Values are n (%).

Variables	pSS-MALT without Tongue Atrophy, n = 6	pSS-MALT with Tongue Atrophy, n = 13	p
Clinical manifestations			
Oral dryness (subjective)	6/6 (100)	12/13 (92)	1.000
Ocular dryness (subjective)	6/6 (100)	11/13 (85)	1.000
SGE	4/6 (67)	7/13 (54)	1.000
Raynaud phenomenon	1/6 (17)	6/13 (46)	0.333
Palpable purpura	1/6 (17)	1/13 (7)	1.000
Arthralgias/myalgias	4/6 (67)	10/13 (77)	1.000
Arthritis	2/6 (33)	2/13 (15)	0.557
Lymphadenopathy	0/6 (0)	5/13 (38)	0.128
Histopathological/laboratory/serological features			
MSG biopsy focus score ≥ 1	5/6 (83)	11/13 (85)	1.000
MSG biopsy Tarpley score > 2	6/6 (100)	11/13 (85)	1.000
Leukopenia*	0/6 (0)	2/13 (15)	1.000
ANA-positive [†]	5/6 (83)	11/13 (85)	1.000
C4 hypocomplementemia [◊]	1/5 (20)	8/12 (67)	0.131
Anti-Ro/SSA and/or anti-La/SSB positive	2/5 (40)	12/13 (92)	0.015
RF-positive	4/4 (100)	12/12 (100)	1.000
Monoclonal gammopathy	2/5 (40)	3/12 (25)	0.600

* Defined as white blood cells < 3000/mm³ on 3 separate occasions. [†] Titers > 1:160. [◊] Defined as serum C4 levels < 20 mg/dl on 3 separate occasions. Values in bold face are statistically significant. pSS: primary Sjögren syndrome; MALT: mucosa-associated lymphoid tissue; SGE: salivary gland enlargement; MSG: minor salivary gland; ANA: antinuclear antibody; RF: rheumatoid factor.

(e.g., anemia), nutritional deficiencies, and gastrointestinal disorders such as celiac disease, and metabolic diseases including diabetes mellitus, as well as to the administration of numerous medications, such as psychotropic drugs^{20,21}. Patients with elaborated oral candidiasis, iron deficiency, and/or megaloblastic anemia were therefore not included in the analyses, while evaluation of medical records of all patients included ruled out the possibility of tongue atrophy being a result of any of the aforementioned systemic disorders, nutritional deficiencies, or drugs.

Fissured tongue (plicated or scrotal tongue) is a common anatomic variant of unknown etiology, with varying expressivity, characterized by multiple irregular fissures on the dorsal tongue surface, and accompanied by mild depapillation and edema of the filiform papillae. The entity may be seen in about 2% to 5% of the adult population, but an increase in prevalence with age reaching up to 30% has also been described. Fissured tongue has been suggested to be hereditary, inherited with an autosomal dominant trait, while it may also be encountered in the context of other conditions such as geographic tongue, Melkersson-Rosenthal syndrome, and Down syndrome²². A study in a Greek population has also reported that patients with fissured tongue show an increased frequency of HLA-DRB1*08, HLA-DRB1*14, HLA-DRB1*11, and HLA-DRB1*16 alleles²³. Interestingly, HLA-DRB1 haplotypes have also been shown to relate to an increased susceptibility for SS⁷, suggesting that both conditions may share a common genetic link, which could explain the increased prevalence of fissured tongue appearance in patients with SS. Local irritating factors may also play a role in fissured tongue appearance²²; increased hyposalivation and subsequent tongue atrophy may explain the increased prevalence and more intense appearance of fissured tongue in patients with pSS-MALT compared to the pSS non-MALT group.

Tongue atrophy can also be a manifestation of salivary hypofunction²⁴, yet in head-and-neck irradiated patients, an example of noninflammation-mediated cause of hyposalivation, radiation injury seems to cause loss of saliva-producing acinar cells, while salivary ducts mostly remain intact and tongue depapillation does not occur as an immediate postradiation effect²³. In our study, a reduced unstimulated whole salivary flow was exceedingly more prominent in patients with pSS complicated with MALT in whom intense tongue atrophy and fissured tongue appearance were evident. One could assume that tongue atrophy was more prevalent in the patients with pSS-MALT simply because they had worse salivary hypofunction. However, in our study the grade of tongue findings correlated well with the focus score on MSG biopsy. In pSS patients with increased salivary gland focal lymphocytic infiltrates (high scores), increased risk for MALT development has been described¹. The lymphocytic infiltrates in different organs (salivary glands, kidneys, liver, bronchi) in patients with pSS

are periepithelial². The epithelial cells are activated and retain, even in culture, their activated phenotype. They inappropriately express immunoregulatory molecules, sustain apoptotic cell death, release in the apoptotic blebs Ro and La autoantigens, and are responsible for the initiation and perpetuation of the autoimmune lesion².

Thus, on the basis of the findings of our present study, the atrophic tongue papillae in pSS patients with MALT may be similar to pathology seen in the salivary and conjunctival epithelial cells that are part of the “pan-epithelitis” of pSS. Therefore, the tongue findings can be the result of lingual epithelial cell activation and death, and the severity of the findings seems to parallel with the transition of benign to malignant lymphoproliferation in pSS.

Further studies from tongue biopsies, at the cellular and molecular levels, are needed to portray the status of the lingual epithelia in patients with SS and to elaborate the pathogenetic mechanism underlying lingual atrophy. Until then, however, oral examination and evaluation of lingual atrophy in association with a more prominent fissured tongue appearance should be an integral part of the complete physical examination for every patient with SS, because a pronounced atrophic and fissured tongue appearance could be a clinical indication of lymphomagenesis in SS.

ACKNOWLEDGMENT

The authors thank Michael Miligkos, MD, PhD, for expert statistical advice.

REFERENCES

1. Moutsopoulos HM. Sjogren's syndrome: autoimmune epithelitis. *Clin Immunol Immunopathol* 1994;72:162-5.
2. Moutsopoulos HM. Sjögren's syndrome: a forty-year scientific journey. *J Autoimmun* 2014;51:1-9.
3. Mavragani CP, Moutsopoulos HM. Sjogren syndrome. *CMAJ* 2014;186:E579-86.
4. Voulgarelis M, Dafni UG, Isenberg DA, Moutsopoulos HM. Malignant lymphoma in primary Sjogren's syndrome: a multicenter, retrospective, clinical study by the European Concerted Action on Sjogren's Syndrome. *Arthritis Rheum* 1999;42:1765-72.
5. Kassan SS, Thomas TL, Moutsopoulos HM, Hoover R, Kimberly RP, Budman DR, et al. Increased risk of lymphoma in sicca syndrome. *Ann Intern Med* 1978;89:888-92.
6. Zintzaras E, Voulgarelis M, Moutsopoulos HM. The risk of lymphoma development in autoimmune diseases: a meta-analysis. *Arch Intern Med* 2005;165:2337-44.
7. Nezos A, Mavragani CP. Contribution of genetic factors to Sjögren's syndrome and Sjögren's syndrome related lymphomagenesis. *J Immunol Res* 2015;2015:754825.
8. Skopouli FN, Dafni U, Ioannidis JP, Moutsopoulos HM. Clinical evolution, and morbidity and mortality of primary Sjogren's syndrome. *Semin Arthritis Rheum* 2000;29:296-304.
9. Fragkioudaki S, Mavragani CP, Moutsopoulos HM. Predicting the risk for lymphoma development in Sjogren syndrome: an easy tool for clinical use. *Medicine* 2016;95:e3766.
10. Christodoulou MI, Kapsogeorgou EK, Moutsopoulos HM. Characteristics of the minor salivary gland infiltrates in Sjögren's syndrome. *J Autoimmun* 2010;34:400-7.
11. Gonzalez S, Sung H, Sepulveda D, González M, Molina C. Oral manifestations and their treatment in Sjogren's syndrome. *Oral Dis* 2014;20:153-61.

12. Mays JW, Sarmadi M, Moutsopoulos NM. Oral manifestations of systemic autoimmune and inflammatory diseases: diagnosis and clinical management. *J Evid Based Dent Pract* 2012;12:265-82.
13. Vitali C, Bombardieri S, Jonsson R, Moutsopoulos HM, Alexander EL, Carsons SE, et al; European Study Group on Classification Criteria for Sjögren's Syndrome. Classification criteria for Sjögren's syndrome: a revised version of the European criteria proposed by the American-European Consensus Group. *Ann Rheum Dis* 2002;61:554-8.
14. Yamamoto K, Kurihara M, Matsusue Y, Komatsu Y, Tsuyuki M, Fujimoto T, et al. Atrophic change of tongue papilla in 44 patients with Sjögren syndrome. *Oral Surg Oral Med Oral Pathol Oral Radiol Endod* 2009;107:801-5.
15. Ergun S, Cekici A, Topcuoglu N, Migliari DA, Külekçi G, Tanyeri H, et al. Oral status and Candida colonization in patients with Sjögren's syndrome. *Med Oral Patol Oral Cir Bucal* 2010; 15:e310-5.
16. Skopouli FN, Siouna FH, Ziciadis C, Moutsopoulos HM. Evaluation of unstimulated whole saliva flow rate and stimulated parotid flow as confirmatory tests for xerostomia. *Clin Exp Rheumatol* 1989;7:127-9.
17. Vitali C, Moutsopoulos HM, Bombardieri S. The European Community Study Group on diagnostic criteria for Sjögren's syndrome. Sensitivity and specificity of tests for ocular and oral involvement in Sjögren's syndrome. *Ann Rheum Dis* 1994;53:637-47.
18. Daniels TE, Kapila YL. Comments on atrophic lingual papillae and candidiasis in Sjögren syndrome. *Oral Surg Oral Med Oral Pathol Oral Radiol Endod* 2010;109:4.
19. Hernandez YL, Daniels TE. Oral candidiasis in Sjögren's syndrome: prevalence, clinical correlations, and treatment. *Oral Surg Oral Med Oral Pathol* 1989;68:324-9.
20. Erriu M, Pili FM, Cadoni S, Garau V. Diagnosis of lingual atrophic conditions: associations with local and systemic factors. A descriptive review. *Open Dent J* 2016;10:619-35.
21. Reamy BV, Derby R, Bunt CW. Common tongue conditions in primary care. *Am Fam Physician* 2010;81:627-34.
22. Neville BW, Damm DD, Allen CM, Bouquot JE. Oral and maxillofacial pathology. 3rd ed. St. Louis: Saunders, Elsevier; 2009:13.
23. Kalifatidis A, Albanidou-Farmaki E, Daniilidis M, Markopoulos AK, Karyotis N, Antoniadis DZ. HLA alleles and fissured tongue. *Int J Immunogenet* 2010;37:509-11.
24. Osailan SM, Pramanik R, Shirlaw P, Proctor GB, Challacombe SJ. Clinical assessment of oral dryness: development of a scoring system related to salivary flow and mucosal wetness. *Oral Surg Oral Med Oral Pathol Oral Radiol* 2012;114:597-603.