

# Development and Validation of the OMERACT Rheumatoid Arthritis Magnetic Resonance Tenosynovitis Scoring System in a Multireader Exercise

Daniel Glinatsi, Paul Bird, Frédérique Gandjbakhch, Espen A. Haavardsholm, Charles G. Peterfy, Edward M. Vital, Paul Emery, Philip G. Conaghan, and Mikkel Østergaard

**ABSTRACT. Objective.** To develop and validate a magnetic resonance imaging (MRI) tenosynovitis (TS) score for tendons at the wrist and metacarpophalangeal (MCP) joint levels in patients with rheumatoid arthritis (RA).

**Methods.** Axial T1-weighted precontrast and postcontrast fat-saturated MR image sets of the hands of 43 patients with RA initiating rituximab therapy were obtained at baseline and after 14, 26, 38, or 52 weeks. The MR images were scored twice by 4 readers. Nine tendon compartments of the wrist and 4 flexor tendon compartments at the MCP joints were assessed. Tenosynovitis was scored as follows: 0: No; 1: < 1.5 mm; 2: ≥ 1.5 mm but < 3 mm; 3: ≥ 3 mm peritendinous effusion and/or postcontrast enhancement. Intrareader and interreader intraclass correlation coefficients (ICC), smallest detectable change (SDC), percentage of exact and close agreement (PEA/PCA), and standardized response mean (SRM) were calculated.

**Results.** Intrareader and interreader ICC for status and change scores were very good (≥ 0.80) for total scores for all readers. Intrareader SDC was ≤ 3.0 and interreader SDC was < 2.0. The overall PEA/PCA intrareader and interreader agreements for change scores in all tendons were 73.8%/97.6% and 47.9%/85.0%, respectively. Average SRM was moderate for total scores and 60.5% of the patients had a tenosynovitis change score ≥ SDC.

**Conclusion.** The TS score showed high intrareader and interreader agreement for wrist and finger tendons, with moderate responsiveness, and the majority of the patients showed a change above the SDC. This scoring system may be included as a component of the RAMRIS. (J Rheumatol First Release May 1 2017; doi:10.3899/jrheum.161097)

## Key Indexing Terms:

MAGNETIC RESONANCE IMAGING  
RHEUMATOID ARTHRITIS

TENOSYNOVITIS  
OMERACT

From the Copenhagen Center for Arthritis Research (COPECARE), Center for Rheumatology and Spine Diseases, Rigshospitalet, Glostrup; Department of Clinical Medicine, University of Copenhagen, Copenhagen, Denmark; Leeds Institute of Rheumatic and Musculoskeletal Medicine, University of Leeds; UK National Institute for Health Research (NIHR) Leeds Musculoskeletal Biomedical Research Unit; Leeds Teaching Hospitals National Health Service (NHS) Trust, Leeds, UK; University of New South Wales (NSW), Sydney, Australia; Hôpital Pitié-Salpêtrière, APHP, Université Paris VI, Paris, France; Diakonhjemmet Hospital, Oslo, Norway; Spire Sciences Inc., Boca Raton, Florida, USA.

Supported by the Danish Rheumatism Association. The clinical trial from which these data were acquired was supported by a research grant and study drug from Roche. The research is supported by the NIHR Leeds Musculoskeletal Biomedical Research Unit. The views expressed are those of the author(s) and not necessarily those of the NHS, the NIHR, or the UK Department of Health. Dr. Gandjbakhch has received consultation fees from Pfizer, AbbVie, Roche, and Janssen, and research support and grants from Pfizer and Roche. Dr. Haavardsholm has received consultation fees from Pfizer and MSD, and research support and grants from AbbVie, UCB, MSD, Pfizer, and Roche. Dr. Peterfy is a shareholder in Spire Sciences Inc. E.M. Vital has received research support and grants from Roche and AstraZeneca. P.G. Conaghan has been a consultant or on the speakers' bureau for Abbvie, Lilly, Novartis, Pfizer, and Roche, and has received a research grant from BMS. Dr. Østergaard has received consultation fees from Abbvie, BMS, Boehringer-Ingelheim, Celgene, Eli-Lilly, Centocor, GSK, Hospira, Janssen, Merck, Mundipharma, Novartis, Novo, Orion, Pfizer, Regeneron, Schering-Plough, Roche, Takeda, UCB, and Wyeth, and

has received research support and grants from Abbvie, BMS, Janssen, and Merck.

D. Glinatsi, MD, research fellow, COPECARE, Center for Rheumatology and Spine Diseases; P. Bird, BMed (Hons), FRACP, PhD, Grad Dip MRI, Associate Professor, University of NSW; F. Gandjbakhch, MD, Practicing Rheumatologist, Hôpital Pitié-Salpêtrière, APHP, Université Paris VI; E.A. Haavardsholm, MD, PhD, Postdoctoral Researcher, Department of Rheumatology, Diakonhjemmet Hospital; C.G. Peterfy, MD, PhD, FRCP, Chief Executive Officer, Spire Sciences Inc.; E.M. Vital, MRCP, PhD, Associate Professor and Honorary Consultant, Leeds Institute for Rheumatic and Musculoskeletal Medicine, University of Leeds, and NIHR Leeds Musculoskeletal Biomedical Research Unit; P. Emery, MA, MD, FRCP, ARC Professor in Rheumatology, Leeds Institute for Rheumatic and Musculoskeletal Medicine, University of Leeds, and NIHR Leeds Musculoskeletal Biomedical Research Unit; P.G. Conaghan, MB, BS, PhD, FRACP, FRCP, Professor of Musculoskeletal Medicine, Leeds Institute of Rheumatic and Musculoskeletal Medicine, University of Leeds, and NIHR Leeds Musculoskeletal Biomedical Research Unit; M. Østergaard, MD, PhD, DMSc, Professor, COPECARE, Center for Rheumatology and Spine Diseases, Rigshospitalet, and the Department of Clinical Medicine, University of Copenhagen.

Address correspondence to Dr. D. Glinatsi, Copenhagen Center for Arthritis Research (COPECARE), Center for Rheumatology and Spine Diseases, Rigshospitalet, Nordre Ringvej 57, 5th entrance, 2600 Glostrup, Denmark. E-mail: daniel.glinatsi@gmail.com

Accepted for publication March 23, 2017.

Tenosynovitis (TS) in the hand of patients with rheumatoid arthritis (RA) is a frequent and early occurring inflammatory feature that can cause tendon rupture and may be associated with subsequent bone erosion<sup>1,2,3,4,5</sup>. Magnetic resonance imaging (MRI) provides excellent visualization of bone and soft tissues in the hand, including TS.

The Outcome Measures in Rheumatology (OMERACT) MRI in Arthritis Working Group developed an RA MRI score (RAMRIS) for synovitis, osteitis, bone erosion, and recently, for joint space narrowing<sup>6,7</sup>. Adding TS to the RAMRIS may provide improved power to study and monitor the disease course of RA.

Haavardsholm, *et al* designed a TS score for the wrist that demonstrated good reliability and responsiveness<sup>8,9</sup>. In addition, the Working Group has suggested and validated a TS score for the fingers as part of the psoriatic arthritis MRI score (PsAMRIS)<sup>10,11,12</sup>. However, none of these scores covered the tendons at both wrist and metacarpophalangeal (MCP) joint level.

Our aim was to develop and validate an RA TS score for tendons at wrist and MCP joint levels. Here we present previously unpublished results that demonstrate the reliability of this novel score, enabling it to be included in the internationally renowned RAMRIS.

## MATERIALS AND METHODS

**Development of scoring system.** In accordance with the processes in the OMERACT Handbook for technical tool development, previous MRI TS scores were identified through a thorough review of the literature by a fellow of the Working Group, which included rheumatologists, radiologists, methodologists, and industry representatives from 3 continents. The TS scores suggested by Haavardsholm, *et al* and the PsAMRIS appeared most thoroughly assessed methodologically and were tested in a pilot phase where the 2 TS scores were assessed at wrist and MCP joints by 2 readers at 2 timepoints<sup>8,9</sup>. The methodology by Haavardsholm, *et al* seemed more applicable to the wrist area and was therefore chosen for subsequent intrareader and interreader agreement analyses in a pre-exercise with 80 hands at 2 timepoints (baseline/1-year followup), in which the exact thickness of TS was also measured. The results were presented and discussed at a subsequent meeting of the Working Group, and modifications were implemented based on tendon sheath thickness distributions (Supplementary Figure 1, available with the online version of this article). The group then proceeded to perform the multireader exercise below.

**Image selection.** MR image sets were selected from a study<sup>13</sup> in which patients with active RA (disease activity score > 3.2, rheumatoid factor-and/or anticyclic citrullinated peptide-positive,  $\geq 1$  previous disease-modifying antirheumatic drug) were treated with 2–3 doses of 1000 mg rituximab at baseline. MRI of the dominant hand was performed on a Siemens 1.5 Tesla MRI unit using a dedicated hand coil. Axial T1-weighted fat-saturated precontrast and postcontrast gradient echo MR image sets (slice thickness 0.45 mm, repetition time 30 ms, echo time 6.8 ms, field of view 150 mm) were obtained at baseline (n = 43) and after 14 (n = 5), 26 (n = 8), 38 (n = 15), or 52 (n = 15) weeks.

**Scoring of images.** Four readers (DG, FG, MØ, PB) with previous experience in MRI-assessment of TS participated in the exercise. The readers performed a calibration session the evening before the exercise. Forty-three paired MR image sets were blinded for patient data but not for chronology<sup>14</sup>, and were read twice on identical 23-inch screens over 2 days with reanonymizing and rerandomizing between the 2 reads.

**Reader rules and scoring system.** At the wrist, 6 extensor tendon compartments and 3 flexor tendon compartments were assessed between the radioulnar joint and the hook of hamate. At the level of the second to the fifth MCP joints, flexor tendons were assessed in an area from 1 cm proximal to 1 cm distal to each joint (Figure 1A).

TS was defined as peritendinous effusion and/or postcontrast enhancement of the tendon sheath seen on axial sequences over  $\geq 3$  consecutive slices. The maximum width of the effusion and/or enhancing tendon sheath was measured perpendicularly to the tendon, and the TS score was graded as follows: 0: No; 1: < 1.5 mm; 2:  $\geq 1.5$  mm but < 3 mm; 3:  $\geq 3$  mm peritendinous effusion and/or postcontrast enhancement (Figure 1A). Tendon sheaths of crossing tendons were measured proximally to the crossing point, and tendon bundles within a common tendon sheath were assessed as 1 unit (Figure 1B-C). Supplementary Figure 2 (available with the online version of this article) shows examples of TS.

**Statistical analysis.** Descriptive statistics and the Wilcoxon signed-rank test were used to assess changes in score over time.

Intrareader and interreader agreement were assessed using single and average measure intraclass correlation coefficient (smICC/avmICC), respectively. The smallest detectable change (SDC) was calculated for intrareader and interreader change scores<sup>15</sup> and was also expressed as the percentage of maximum observed change (%MOC). The percentage of exact agreement (PEA, scores equal) and the percentages of close agreement (PCA, scores  $\leq 1$  different) between the 2 reads and the 4 readers were calculated for intrareader and interreader agreement, respectively.

Responsiveness was assessed by the standardized response mean (SRM). Ability to show change was also assessed by the percentage of patients with change score  $\geq$  SDC.

## RESULTS

Baseline and followup characteristics of the patients are presented in Supplementary Table 1 (available with the online version of this article). Median (range) change in total TS score was  $-1.0$  ( $-1.0$  to  $-2.5$ ;  $p < 0.01$ ).

Intrareader smICC for baseline scores were very good for all measures in all readers, except for MCP scores in 1 reader (smICC 0.79). Intrareader smICC for change scores were good to very good for all measures. All readers demonstrated very good intrareader smICC for total scores. Baseline/change interreader avmICC were  $> 0.90$  (i.e., very good) for all measures. Median (range) intrareader SDC was 2.8 (2.1–3.0) for total scores. Interreader SDC for scores averaged over 4 readers were  $< 2.0$  for wrist, MCP ( $< 1.0$ ), and total scores. The percentage of patients with a total change score  $\geq$  SDC was 39.5% to 54.7% for intrareader SDC. For interreader SDC, this percentage was 60.5%. The %MOC was below 20% for intrareader and interreader total scores (Table 1).

*Figure 1.* Scoring sheet for the TS score. At the wrist, 6 extensor tendon compartments and 3 flexor tendon compartments are assessed, and at the level of the second to the fifth metacarpophalangeal (MCP) joints, the flexor tendons are assessed. The range of the scores is 0-27, 0-12, and 0-39 for the tendons at the wrist, MCP joints, and total score, respectively (A). Measuring the common tendon sheath perpendicularly from an individual tendon (B) will result in overestimation of the thickness of the tendon sheath. Therefore, the tendons within a common tendon sheath are assessed as 1 unit (C), illustrated by the dashed lines. The enhancing tendon sheath is measured perpendicularly to the unit at the thickest point. FCR: flexor carpi radialis; FPL: flexor pollicis longus.

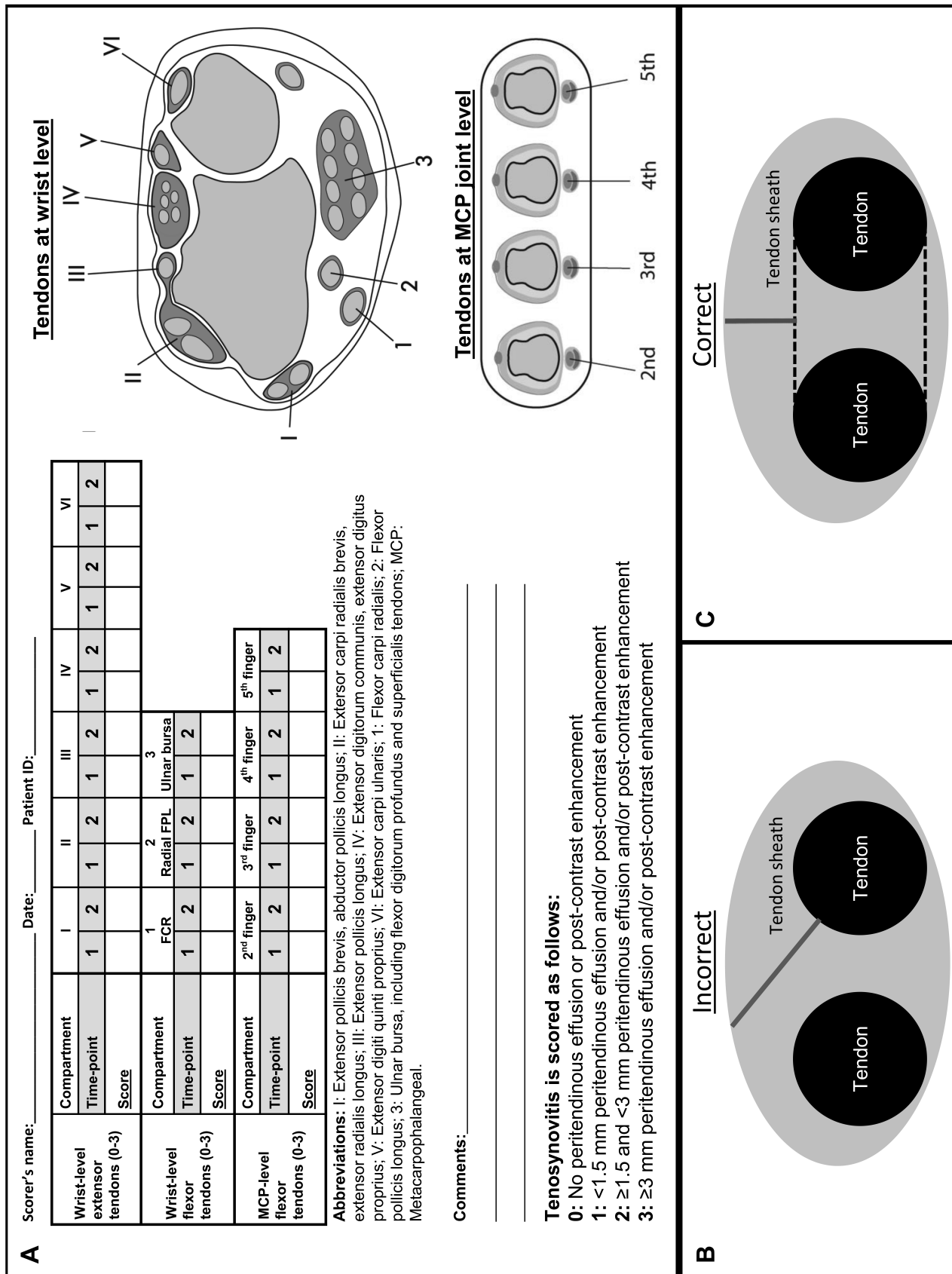


Figure 1.

Table 1. Intrareader and interreader agreement of the TS score.

		Wrist		MCP Flexor Tendons		Total Score	
		Baseline	Change	Baseline	Change	Baseline	Change
Intrareader ICC and SDC, Reader 1	smICC (95% CI)	0.91 (0.82–0.95)	0.82 (0.69–0.90)	0.89 (0.80–0.94)	0.81 (0.68–0.89)	0.90 (0.82–0.95)	0.88 (0.79–0.93)
	SDC (% patients ≥ SDC) [%MOC]		1.8 (54.7) [18.9]		1.1 (22.1) [15.5]		2.1 (39.5) [13.5]
Intrareader ICC and SDC, Reader 2	smICC (95% CI)	0.93 (0.87–0.96)	0.80 (0.67–0.89)	0.88 (0.79–0.93)	0.83 (0.71–0.90)	0.94 (0.90–0.97)	0.83 (0.70–0.90)
	SDC (% patients ≥ SDC) [%MOC]		2.0 (57.0) [18.2]		1.2 (23.3) [10.6]		2.7 (40.7) [13.3]
Intrareader ICC and SDC, Reader 3	smICC (95% CI)	0.84 (0.72–0.91)	0.76 (0.59–0.86)	0.79 (0.65–0.88)	0.68 (0.48–0.81)	0.87 (0.77–0.93)	0.84 (0.73–0.91)
	SDC (% patients ≥ SDC) [%MOC]		2.9 (48.8) [22.8]		1.8 (44.2) [23.8]		3.0 (54.7) [15.8]
Intrareader ICC and SDC, Reader 4	smICC (95% CI)	0.94 (0.89–0.97)	0.64 (0.42–0.79)	0.92 (0.85–0.96)	0.87 (0.78–0.93)	0.95 (0.91–0.97)	0.80 (0.67–0.88)
	SDC (% patients ≥ SDC) [%MOC]		2.3 (37.2) [29.7]		1.1 (44.2) [13.5]		2.7 (50.0) [18.1]
Intrareader PEA and PCA, %, average	PEA	76.7	75.4	73.4	70.3	75.7	73.8
	PCA	98.3	97.4	99.4	98.0	98.6	97.6
Interreader ICC and SDC	avmICC (95% CI)	0.94 (0.87–0.97)	0.91 (0.86–0.95)	0.96 (0.93–0.98)	0.94 (0.91–0.97)	0.96 (0.90–0.98)	0.94 (0.90–0.96)
	SDC (% patients ≥ SDC) [%MOC]		1.7 (49.4) [17.1]		0.9 (50.6) [10.2]		1.8 (60.5) [10.2]
Interreader PEA and PCA, %	PEA	42.5	50.3	41.0	42.4	42.0	47.9
	PCA	81.1	84.0	86.9	87.2	82.9	85.0

An intraclass correlation (ICC)  $\geq 0.50$  was considered good and an ICC  $\geq 0.80$  was considered very good. The smallest detectable change (SDC) was calculated for the change scores and expresses the lowest amount of change that can be considered as true change and not measurement error. The percentage of exact agreement (PEA) was defined as the percentage of individual tendons having an exact agreement between the 2 reads for intrareader agreement and between the 4 readers for interreader agreement. The percentage of close agreement (PCA) was defined as the percentage of tendons with agreement differing  $\leq 1$ . PEA and PCA are presented as the average percentages for total scores. TS: tenosynovitis; MCP: metacarpophalangeal; %MOC: percentage of maximum observed change; smICC: single measure ICC; avmICC: average measure ICC.

The overall PEA/PCA intrareader and interreader agreements for change scores in all tendons were 73.8%/97.6% and 47.9%/85.0%, respectively (Table 1). PEA/PCA for individual tendons are presented in Supplementary Table 2 (available with the online version of this article). The interreader PEA/PCA for pairs of 2 readers were 72.4%/99.6% (baseline) and 73.3%/98.8% (change) for the best matched pair and 64.3%/98.3% (baseline) and 67.5%/97.0% (change) for the average pair when all tendons were considered.

The average SRM for total scores was moderate (Table 2). Overall, there were no differences in ICC, %MOC, PEA/PCA, and SRM between tendon sheaths at wrist versus MCP joint levels.

Table 2. Responsiveness of the TS score.

	Change Wrist	Change MCP	Change Total
Reader 1	0.36	0.44	0.42
Reader 2	0.44	0.42	0.48
Reader 3	0.44	0.54	0.54
Reader 4	0.52	0.47	0.54
Average	0.44	0.47	0.50

Standardized response mean (SRM) for individual readers, expressed as the mean change divided by the SD of the change scores. SRM interpretation: trivial  $< 0.20$ ; small 0.20–0.49; moderate 0.50–0.79; good  $\geq 0.80$ .

## DISCUSSION

This longitudinal multireader exercise of patients with active RA showed that the TS score had high intrareader and interreader agreement and moderate responsiveness. The results were similar at wrist and MCP joint level.

Intrareader and interreader ICC were very good, both for total baseline and change scores, indicating that the TS score is reliable and can monitor change over time.

The average intrareader PEA was high and the PCA was close to 100%. Interreader PEA was acceptable considering the increased difficulty of 4 assessors needing to reach exact agreement, as compared to 2 assessors. Because most clinical trials have 2 assessors, we also analyzed the PEA/PCA for paired readers, and found the average percentages close to the intrareader agreements and the percentages of the best paired assessors in line with the intrareader agreements.

The interreader SDC was  $\leq 2.0$  and the %MOC  $< 11\%$ . Although the average SRM was only 0.50 (moderate),  $> 60\%$  of the patients showed a change  $\geq$  SDC. Variable treatment regimens (related to different timing of infusions) and different timing of followup MRI may have affected the responsiveness but would not be expected to alter the intrareader and interreader agreement. Future studies should assess the responsiveness in early RA cohorts and in placebo-controlled studies, where responsiveness can be compared between groups.



This TS score was developed as a modification from the score by Haavardsholm, *et al* after assessing this and the PsAMRIS TS score in a pilot phase<sup>8,9,10,11</sup>. A key modification of the methodology by Haavardsholm, *et al* was to narrow the intervals of tendon sheath thickness within each increment to potentially increase the ability to detect change. As proven by this exercise, the reliability of the current TS score remained high. The responsiveness was not increased compared to the results reported by Haavardsholm, *et al*<sup>9</sup>, but because therapies in the 2 cohorts were different, the results are not fully comparable. Other advances, compared to the score by Haavardsholm, *et al*, included clarifications on how to score tendon sheaths of crossing tendons and common tendon sheaths of tendon bundles (Figure 1B-C).

Other MRI TS scores have previously been used. Several have not assessed reliability and responsiveness<sup>1,16</sup> or have scored TS qualitatively as absent/present<sup>2,4,17,18,19,20,21,22</sup>. Regarding the monitoring of change, qualitative scores may have less power to detect changes in TS. Semiquantitative TS scores have been suggested by McQueen, *et al*<sup>23</sup> and Schirmer, *et al*<sup>24</sup>, but did not assess the performance in longitudinal settings nor the intrareader and interreader agreement. Lisbona, *et al*<sup>25</sup> suggested a TS score for the hand (based on incomplete and complete halos of enhancing tendon sheath) that showed high intrareader and interreader ICC, but small SRM.

This TS score was developed as a potential addendum to the existing RAMRIS<sup>6,26</sup>. Therefore, we strived to design the score so that it covered the tendons at the joint regions included in the RAMRIS core set. Because TS is scored on the same MRI sequences and projections as synovitis, these pathologies may be scored simultaneously and therefore the addition of TS score will add only a small amount of time to assessing a hand when using the RAMRIS method. Based on this and the reliability and responsiveness data, we conclude that this TS score fulfills the OMERACT filter criteria concerning truth, discrimination, and feasibility<sup>27</sup> and may be included as a component of the RAMRIS for assessing TS of the hand in RA clinical trials.

## ACKNOWLEDGMENT

We thank illustrator Axel Norén for help with Figure 1, and the Danish Rheumatism Association.

## ONLINE SUPPLEMENT

Supplementary material accompanies the online version of this article.

## REFERENCES

- Boutry N, Hachulla E, Flipo RM, Cortet B, Cotten A. MR imaging findings in hands in early rheumatoid arthritis: comparison with those in systemic lupus erythematosus and primary Sjogren syndrome. *Radiology* 2005;236:593-600.
- Eshed I, Feist E, Althoff CE, Backhaus M, Burmester GR, Hamm B, et al. Early rheumatoid arthritis-do we really know what it means? Consistency and distribution of MRI findings according to different definitions for early rheumatoid arthritis. *Clin Rheumatol* 2011;30:551-5.
- Nieuwenhuis WP, Krabben A, Stomp W, Huizinga TW, van der Heijde D, Bloem JL, et al. Evaluation of magnetic resonance imaging-detected tenosynovitis in the hand and wrist in early arthritis. *Arthritis Rheumatol* 2015;67:869-76.
- McQueen F, Beckley V, Crabbe J, Robinson E, Yeoman S, Stewart N. Magnetic resonance imaging evidence of tendinopathy in early rheumatoid arthritis predicts tendon rupture at six years. *Arthritis Rheum* 2005;52:744-51.
- Lillegraven S, Boyesen P, Hammer HB, Ostergaard M, Uhlig T, Sesseng S, et al. Tenosynovitis of the extensor carpi ulnaris tendon predicts erosive progression in early rheumatoid arthritis. *Ann Rheum Dis* 2011;70:2049-50.
- Ostergaard M, Peterfy C, Conaghan P, McQueen F, Bird P, Ejbjerg B, et al. OMERACT Rheumatoid Arthritis Magnetic Resonance Imaging Studies. Core set of MRI acquisitions, joint pathology definitions, and the OMERACT RA-MRI scoring system. *J Rheumatol* 2003;30:1385-6.
- Glinatsi D, Lillegraven S, Haavardsholm EA, Eshed I, Conaghan PG, Peterfy C, et al. Validation of the OMERACT magnetic resonance imaging joint space narrowing score for the wrist in a multireader longitudinal trial. *J Rheumatol* 2015;42:2480-5.
- Haavardsholm EA, Ostergaard M, Ejbjerg BJ, Kvan NP, Kvien TK. Introduction of a novel magnetic resonance imaging tenosynovitis score for rheumatoid arthritis: reliability in a multireader longitudinal study. *Ann Rheum Dis* 2007;66:1216-20.
- Haavardsholm EA, Ostergaard M, Hammer HB, Boyesen P, Boonen A, van der Heijde D, et al. Monitoring anti-TNFalpha treatment in rheumatoid arthritis: responsiveness of magnetic resonance imaging and ultrasonography of the dominant wrist joint compared with conventional measures of disease activity and structural damage. *Ann Rheum Dis* 2009;68:1572-9.
- Boyesen P, McQueen FM, Gandjbakhch F, Lillegraven S, Coates L, Wiell C, et al. The OMERACT Psoriatic Arthritis Magnetic Resonance Imaging Score (PsAMRIS) is reliable and sensitive to change: results from an OMERACT workshop. *J Rheumatol* 2011;38:2034-8.
- Glinatsi D, Bird P, Gandjbakhch F, Mease PJ, Boyesen P, Peterfy CG, et al. Validation of the OMERACT Psoriatic Arthritis Magnetic Resonance Imaging Score (PsAMRIS) for the hand and foot in a randomized placebo-controlled trial. *J Rheumatol* 2015;42:2473-9.
- Ostergaard M, McQueen F, Wiell C, Bird P, Boyesen P, Ejbjerg B, et al. The OMERACT psoriatic arthritis magnetic resonance imaging scoring system (PsAMRIS): definitions of key pathologies, suggested MRI sequences, and preliminary scoring system for PsA Hands. *J Rheumatol* 2009;36:1816-24.
- Vital EM, Dass S, Buch MH, Rawstron AC, Emery P. An extra dose of rituximab improves clinical response in rheumatoid arthritis patients with initial incomplete B cell depletion: a randomised controlled trial. *Ann Rheum Dis* 2015;74:1195-201.
- van Tuyl LH, van der Heijde D, Knol DL, Boers M. Chronological reading of radiographs in rheumatoid arthritis increases efficiency and does not lead to bias. *Ann Rheum Dis* 2014;73:391-5.
- Bruynsteyn K, Boers M, Kostense P, van der Linden S, van der Heijde D. Deciding on progression of joint damage in paired films of individual patients: smallest detectable difference or change. *Ann Rheum Dis* 2005;64:179-82.
- Matsumoto T, Tsurumoto T, Shindo H, Uetani M. Comparative study of fat-suppressed Gd-enhanced MRI of hands in the early stage of rheumatoid arthritis (RA) and non-RA. *Mod Rheumatol* 2001;11:56-60.
- Eshed I, Feist E, Althoff CE, Hamm B, Konen E, Burmester GR, et al. Tenosynovitis of the flexor tendons of the hand detected by MRI: an early indicator of rheumatoid arthritis. *Rheumatology* 2009;48:887-91.

18. Klarlund M, Ostergaard M, Jensen KE, Madsen JL, Skjodt H, Lorenzen I. Magnetic resonance imaging, radiography, and scintigraphy of the finger joints: one year follow up of patients with early arthritis. The TIRA Group. *Ann Rheum Dis* 2000;59:521-8.
19. Krabben A, Stomp W, Huizinga TW, van der Heijde D, Bloem JL, Reijnders M, et al. Concordance between inflammation at physical examination and on MRI in patients with early arthritis. *Ann Rheum Dis* 2015;74:506-12.
20. Lindegaard HM, Vallo J, Horslev-Petersen K, Junker P, Ostergaard M. Low-cost, low-field dedicated extremity magnetic resonance imaging in early rheumatoid arthritis: a 1-year follow-up study. *Ann Rheum Dis* 2006;65:1208-12.
21. Narvaez J, Narvaez JA, de Albert M, Gomez-Vaquero C, Nolla JM. Can magnetic resonance imaging of the hand and wrist differentiate between rheumatoid arthritis and psoriatic arthritis in the early stages of the disease? *Semin Arthritis Rheum* 2012;42:234-45.
22. Wakefield RJ, O'Connor PJ, Conaghan PG, McGonagle D, Hensor EM, Gibbon WW, et al. Finger tendon disease in untreated early rheumatoid arthritis: a comparison of ultrasound and magnetic resonance imaging. *Arthritis Rheum* 2007;57:1158-64.
23. McQueen FM, Stewart N, Crabbe J, Robinson E, Yeoman S, Tan PL, et al. Magnetic resonance imaging of the wrist in early rheumatoid arthritis reveals a high prevalence of erosions at four months after symptom onset. *Ann Rheum Dis* 1998;57:350-6.
24. Schirmer C, Scheel AK, Althoff CE, Schink T, Eshed I, Lembecke A, et al. Diagnostic quality and scoring of synovitis, tenosynovitis and erosions in low-field MRI of patients with rheumatoid arthritis: a comparison with conventional MRI. *Ann Rheum Dis* 2007;66:522-9.
25. Lisbona MP, Maymo J, Perich J, Almirall M, Carbonell J. Rapid reduction in tenosynovitis of the wrist and fingers evaluated by MRI in patients with rheumatoid arthritis after treatment with etanercept. *Ann Rheum Dis* 2010;69:1117-22.
26. Ostergaard M, Boyesen P, Eshed I, Gandjbakhch F, Lillegraven S, Bird P, et al. Development and preliminary validation of a magnetic resonance imaging joint space narrowing score for use in rheumatoid arthritis: potential adjunct to the OMERACT RA MRI scoring system. *J Rheumatol* 2011;38:2045-50.
27. Boers M, Kirwan JR, Gossec L, Conaghan PG, D'Agostino MA, Bingham CO, et al. How to choose core outcome measurement sets for clinical trials: OMERACT 11 approves filter 2.0. *J Rheumatol* 2014;41:1025-30.