

Isotretinoin-induced Spondyloarthritis-related Symptoms: A Prospective Study

Samet Alkan, Nuriye Kayiran, Orhan Zengin, Ali Kalem, Gezmis Kimyon, Emine Ozkul Kilinc, Yavuz Pehlivan, Necmettin Kirtak, Ahmet Mesut Onat, and Bunyamin Kisacik

ABSTRACT. Objective. Acne vulgaris is a chronic inflammatory disease involving the pilosebaceous unit of the skin. Isotretinoin is a systemic retinoid that is often used as an effective treatment option for severe and treatment-resistant acne. Isotretinoin may also cause rheumatologic symptoms. The aim of this prospective observational study was to present followup results regarding the rheumatologic symptoms of patients who received systemic therapy for the treatment of acne (isotretinoin and tetracycline).

Methods. For inclusion in the study, all consecutive patients with acne who were aged > 18 years were evaluated by the same dermatologist. The first 42 consecutive patients were included in the isotretinoin group, and after matching for age and sex, 32 consecutive patients were included in the tetracycline group. Isotretinoin treatment was planned as an average dose of 30 mg daily and a total dose of 120–150 mg/kg for 4–6 months. The patients were administered a dose of 1 g/day of tetracycline as 2 equal doses for 3 months.

Results. Forty-two patients diagnosed with acne vulgaris were treated with isotretinoin 20.6 ± 4.4 (male/female: 17/22), and 32 patients were treated with tetracycline 20.6 ± 2.7 (male/female: 8/24). There was no significant difference between the 2 groups with respect to age and sex. Unilateral Achilles enthesopathy developed in 3 patients, whereas both Achilles enthesopathy and unilateral sacroiliitis developed in 1 patient. Inflammatory back pain developed in 6 patients in the isotretinoin group.

Conclusion. To our knowledge, this was the first prospective observational study that assessed the rheumatologic symptoms of isotretinoin treatment. The spondyloarthritis findings were identified in 23.1% of the patients who used isotretinoin. (J Rheumatol First Release October 15 2015; doi:10.3899/jrheum.150013)

Key Indexing Terms:

ISOTRETINOIN
ENTHESITIS

SPONDYLOARTHROPATHY
INFLAMMATORY LOW BACK PAIN

From the Department of Internal Medicine, and Department of Dermatology, and Department of Internal Medicine, Division of Rheumatology, Faculty of Medicine, Gaziantep University, Gaziantep; Department of Internal Medicine, Division of Rheumatology, Faculty of Medicine, Uludağ University, Bursa, Turkey.

S. Alkan, MD, Research Assistant, Department of Internal Medicine, Gaziantep University Faculty of Medicine; N. Kayiran, MD, Dermatology Specialist, Department of Dermatology, Gaziantep University Faculty of Medicine; O. Zengin, MD, Rheumatology Specialist, Department of Internal Medicine, Division of Rheumatology, Faculty of Medicine, Gaziantep University; A. Kalem, MD, Research Assistant, Department of Internal Medicine, Gaziantep University Faculty of Medicine; G. Kimyon, MD, Rheumatology Specialist, Department of Internal Medicine, Division of Rheumatology, Faculty of Medicine, Gaziantep University; E.O. Kilinc, MD, Dermatology Specialist, Department of Dermatology, Gaziantep University Faculty of Medicine; Y. Pehlivan, MD, Associate Professor, Department of Internal Medicine, Division of Rheumatology, Faculty of Medicine, Uludağ University; N. Kirtak, MD, Professor, Department of Dermatology, Gaziantep University Faculty of Medicine; A.M. Onat, MD, Professor, Department of Internal Medicine, Division of Rheumatology, Faculty of Medicine, Gaziantep University; B. Kisacik, MD, Associate Professor, Department of Internal Medicine, Division of Rheumatology, Faculty of Medicine, Gaziantep University.

Address correspondence to Dr. S. Alkan, Gaziantep University, Faculty of Medicine, Internal Medicine, Şahinbey, Gaziantep, 27100, Turkey.
E-mail: smtalkan@hotmail.com

Accepted for publication July 15, 2015.

Acne vulgaris is a chronic inflammatory disease involving the pilosebaceous unit of the skin and has a multifactorial etiology. The disease affects both sexes and all races at a similar rate and usually begins at puberty¹. Systemic treatment is preferred for moderate and severe cases of acne or when topical therapy is not effective or causes irritation. Usually, the first step in systemic treatment is a course of antibiotics^{2,3}. Isotretinoin is a systemic retinoid that is often used as an effective treatment option for severe and treatment-resistant acne⁴. However, isotretinoin has a broad spectrum of side effects that may involve the reproductive, skin, ocular, neurological, hepatic, and musculoskeletal systems⁵. Isotretinoin may also cause sacroiliitis and other inflammatory rheumatologic symptoms such as back pain. Nonetheless, only a few case reports in the literature have evaluated these problems^{6–16,17}.

The aim of our prospective observational study was to present followup results regarding the rheumatologic symptoms of patients who received systemic therapy for the treatment of acne (isotretinoin and tetracycline).

MATERIALS AND METHODS

Patients. All consecutive patients with acne aged > 18 years were evaluated by the same dermatologist for their inclusion in our present study. The following patients were excluded from the study: (1) those who received previous systemic therapy for acne treatment, (2) those with a history of rheumatologic disease, (3) those with doubtful physical examination findings regarding rheumatologic disease, (4) those who were pregnant or planning to become pregnant during the treatment course, (5) those who were consuming another medication for any reason, and (6) those with systemic diseases such as renal failure, hepatic failure, and diabetes mellitus.

The first 42 consecutive patients were included in the isotretinoin group, and after matching for age and sex, 32 consecutive patients were included in the tetracycline group. In total, 74 patients were included in our present study from the outpatient dermatology clinic of the Faculty of Medicine, Gaziantep University, in 2011. Our study was approved by the local ethics committee, and all subjects were informed regarding the principles of our study. All patients provided written informed consent.

Procedures. Isotretinoin treatment was planned as an average daily dose of 30 mg and a total dose of 120–150 mg/kg for 4–6 months. The patients were administered a dose of 1 g/day of tetracycline as 2 equal doses for 3 months.

Clinical and laboratory investigations. We evaluated the patients for rheumatologic symptoms and performed a rheumatological examination, as well as completed the Bath Ankylosing Spondylitis Disease Activity Index (BASDAI) scoring before treatment, at the time of acute symptoms, and at the third and sixth month after treatment. The patients also underwent laboratory examinations to assess the erythrocyte sedimentation rate and C-reactive protein level. A standardized evaluation form was used. The same dermatologist and rheumatologist examined the patients during every followup visit, and the clinical data were properly recorded. All symptomatic cases were evaluated in detail by radiography and HLA-B27 tests. In addition, the patients with heel pain were assessed by ultrasonography (US), and patients with inflammatory back pain (IBP) were assessed by sacroiliac magnetic resonance imaging (MRI). The patients were diagnosed with IBP according to the Berlin criteria¹⁸.

Statistical analysis. The Statistical Package for Social Sciences, version 11 (SPSS Inc.) was used for data analysis. The parametric Student t test was used to compare the groups. Pearson correlation analysis was used to investigate the correlations among different variables. A p value of < 0.05 was considered to be statistically significant.

RESULTS

Forty-two patients diagnosed with acne vulgaris were treated with isotretinoin 20.6 ± 4.4 (male/female: 17/22), and 32 patients were treated with tetracycline 20.6 ± 2.7 (male/female: 8/24). There was no significant difference between the 2 groups with respect to age and sex ($p > 0.05$ each). Therefore, a total of 74 patients were included in our study, although 3 patients from the isotretinoin group were subsequently excluded. Two of these patients wanted to stop the consumption of the medication, and treatment was discontinued for the third patient because of a high bilirubin level during the second month of treatment. All patients in the tetracycline group had completed 3 months of treatment.

Unilateral Achilles enthesopathy developed in 3 patients (all women), whereas both Achilles enthesopathy and unilateral sacroiliitis developed in 1 patient during the course of the study (a female patient). Enthesopathy developed during the first 2 months of treatment. IBP developed in 6 patients in the isotretinoin group, with these patients being symptomatic during their first month of treatment.

We did not observe the development of inflammatory lower back pain in the tetracycline group, and there was a significant difference between the 2 groups ($p = 0.003$). In addition, the mean BASDAI scores at the third month of treatment were 1.76 ± 2.2 and 0.5 ± 0.7 in the isotretinoin and tetracycline groups, respectively, and these data showed a significant difference between the groups ($p = 0.005$).

There was no significant difference between the acute-phase tests that were performed before treatment and those that were completed during the third month of treatment. The demographic and laboratory characteristics of the study group are shown in Table 1.

The diagnoses of Achilles enthesopathy and sacroiliitis were made at the clinic using imaging studies such as MRI and US (Figure 1 and Figure 2). Positive HLA-B27 was not found in any of the patients who had inflammatory lower back pain. Patients who developed rheumatologic symptoms during the treatment course were followed up and treated with nonsteroidal antiinflammatory drugs (NSAID) alone. We observed that the complaints of the patients had decreased a month after the discontinuation of the medication and completely disappeared by the third month during the followup; all patients were asymptomatic by the sixth month of their followup visit.

DISCUSSION

To our knowledge, ours was the first prospective observational study that assessed the rheumatologic symptoms of isotretinoin treatment. The spondyloarthropathy (SpA) findings were identified in 23.1% of the patients who received isotretinoin. The most common SpA symptoms were inflammatory lower back pain (6 patients), Achilles enthesopathy (3 patients), and both Achilles enthesopathy and unilateral sacroiliitis (1 patient).

Isotretinoin is often preferred as a systemic medication for the treatment of acne vulgaris, although it can cause adverse effects in multiple organ systems of the body and may also cause rheumatologic symptoms.

Rheumatologic symptoms that have been reported as occurring with this medication are bilateral and unilateral

Table 1. Demographic and laboratory features of study groups. Values are mean \pm SD unless otherwise specified.

Characteristics	Isotretinoin, n = 39	Tetracycline, n = 32	p
Age, yrs	20.6 ± 4.4	20.6 ± 2.7	0.997
Male/female, n	17/22	8/24	0.175
Baseline CRP	3.1 ± 0.4	2.9 ± 0.5	0.095
Baseline ESR	8.9 ± 6.3	6.9 ± 5.4	0.177
Baseline BASDAI	0.6 ± 1	0.7 ± 1	0.793
3-mo CRP	2.9 ± 0.9	2.8 ± 0.3	0.782
3-mo ESR	12.3 ± 10	6.1 ± 4.7	0.127
3-mo BASDAI	1.76 ± 2.2	0.5 ± 0.7	0.005

CRP: C-reactive protein; ESR: erythrocyte sedimentation rate; BASDAI: Bath Ankylosing Spondylitis Disease Activity Index.

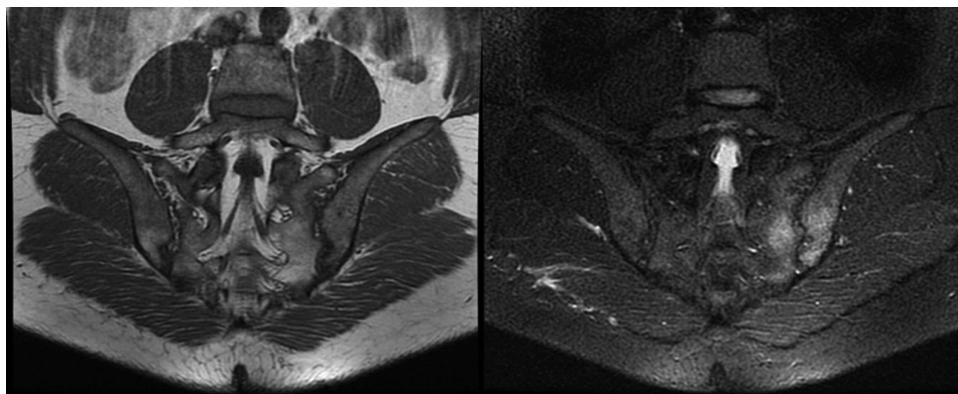


Figure 1. Sacroiliitis on magnetic resonance imaging (MRI) in a patient with acne treated with isotretinoin. Left panel shows SIJ paracoronaral T1-weighted image, and right panel shows STIR MRI. STIR sequences revealed hyperintense lesions compatible with bone marrow edema in both iliac and sacral bones in the left SIJ. SIJ: sacroiliac joint; STIR: short tau-inversion recovery.

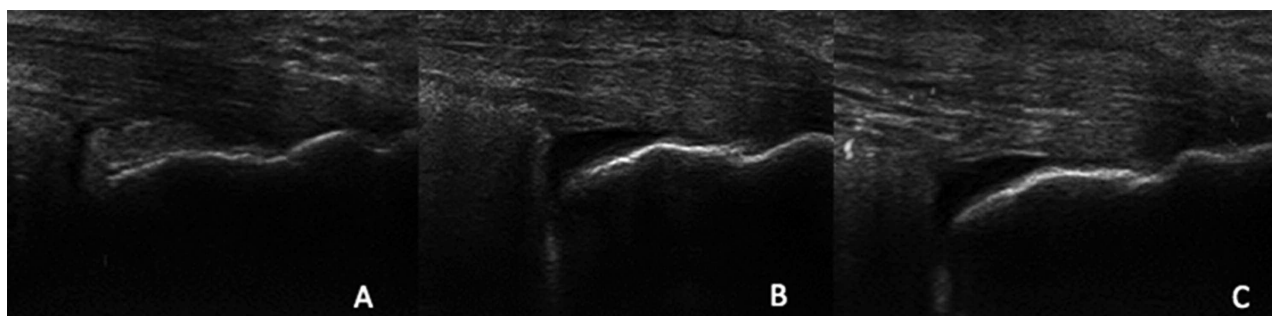


Figure 2. Ultrasonographic evaluation of Achilles tendon enthesopathy of a patient treated with isotretinoin. A. A grayscale, longitudinal scan of the right Achilles tendon showing normal findings. However, in the grayscale images of the left Achilles enthesopathy, (B) an enlargement of the retrocalcaneal bursa and (C) grade 1 power Doppler signal indicative of Achilles tendinopathy were observed.

sacroiliitis, acute arthritis, enthesopathy, inflammatory lower back pain, polyneuropathy, and myopathy. Pehlivan, *et al* have reported 4 isotretinoin-related inflammatory lower back pain cases. All of those patients had negative HLA-B27 tests and normal MRI results; NSAID were considered an adequate treatment for them. In addition, the patients' symptoms completely disappeared after the discontinuation of the medication and never recurred⁸. Barbareschi, *et al* presented a case of unilateral sacroiliitis that was associated with isotretinoin use. The patient's symptoms disappeared after the discontinuation of isotretinoin and never recurred⁹. Similarly, Dincer, *et al* reported 2 cases with bilateral sacroiliitis and 1 case with unilateral sacroiliitis after isotretinoin use. They demonstrated the development of sacroiliitis in these patients using MRI and scintigraphy¹⁷. Fiallo and Tagliapietra described 2 severe acute myopathy cases that were associated with isotretinoin use. The patients completely recovered without any sequelae after the discontinuation of the medication¹⁶. In our study, patients who developed rheumatologic symptoms recovered after the discontinuation of isotretinoin treatment.

It is known that isotretinoin can cause rheumatologic symptoms. The association of isotretinoin therapy and sacroiliitis is not novel, but much rarer. Information indicating that retinoids cause immune dysfunction, thereby leading to arthritis and vasculitis, is present in the literature. However, the mechanism by which isotretinoin leads to arthritis or sacroiliitis is poorly understood. Retinoids have beneficial effects in several mouse models and foster the outgrowth and suppressive properties of some subsets of regulatory T cells. The discrepancy between these mouse models and the worsening or induction of SpA-like features in some humans could lead to a new hypothesis regarding the pathogenesis of SpA because this is another example of "paradoxical" reactions often noticed when treating patients with SpA. However, it has been shown that isotretinoin reduces the formation of cytokines, such as tumor necrosis factor (TNF), which is involved in the inflammatory mechanism of rheumatologic diseases. One study showed that interleukin-1 α , interleukin-1 β , and TNF- α levels decreased in patients who received isotretinoin¹⁹. Therefore, one may expect that retinoids have fewer deleterious effects

and even beneficial effects when administered at lower doses in SpA. In fact, Bidad, *et al* revealed that all-transretinoic acid may decrease the TNF- α secretion of ankylosing spondylitis (AS) cases compared with controls, as demonstrated by the culture supernatants of AS cases²⁰.

Our study has some limitations. First, the cytokine measurement in our study group may help us to reveal the possible etiology. Second, our study has an open and nonrandomized design and may be susceptible to bias. It may be necessary to confirm our results by conducting randomized studies in the future with a larger sample size. Third, we also could not exclude the effects of family history of SpA on our results because we did not screen our patients regarding family history. Another limitation was the study design. Because patients were informed regarding the aim of our study, this may have been sufficient to account for most of the observed differences between groups, at least for subjective features such as IBP. However, we also used objective methods, such as MRI, to eliminate this effect. As a result, the duration of isotretinoin use and the age of onset of SpA diseases are very similar. Isotretinoin caused the development of SPA symptoms in up to 23.1% of the patients; however, symptoms completely resolved after the discontinuation of the medication. Clinicians should question the use of isotretinoin in patients who develop SpA symptoms or have a medical history of its usage.

REFERENCES

1. Niemann C, Horsley V. Development and homeostasis of the sebaceous gland. *Semin Cell Dev Biol* 2012;23:928-36.
2. Bhambri S, Del Rosso JQ, Bhambri A. Pathogenesis of acne vulgaris: recent advances. *J Drugs Dermatol* 2009;8:615-8.
3. Sagransky M, Yentzer BA, Feldman SR. Benzoyl peroxide: a review of its current use in the treatment of acne vulgaris. *Expert Opin Pharmacother* 2009;10:2555-62.
4. Leyden JJ. The role of isotretinoin in the treatment of acne: personal observations. *J Am Acad Dermatol* 1998;39:S45-8.
5. Brelsford M, Beute TC. Preventing and managing the side effects of isotretinoin. *Semin Cutan Med Surg* 2008;27:197-206.
6. Elías LM, Gómez MI, Torrelo A, Boixeda JP, Ledo A. Acne fulminans and bilateral seronegative sacroiliitis triggered by isotretinoin. *J Dermatol* 1991;18:366-7.
7. Bachmeyer C, Charoud A, Turc Y, Callot V, Blum L, Aractingi S. Isotretinoin-induced bilateral sacroiliitis. *Dermatology* 2003;206:285-6.
8. Pehlivan Y, Kisacik B, Sayiner ZA, Onat AM. Inflammatory back pain in patients treated with isotretinoin. *J Rheumatol* 2011;38:2690.
9. Barbareschi M, Paresce E, Chiaratti A, Ferla Lodigiani A, Clerici G, Greppi F. Unilateral sacroiliitis associated with systemic isotretinoin treatment. *Int J Dermatol* 2010;49:331-3.
10. Geller AS, Alagia RF. Sacroiliitis after use of oral isotretinoin—association with acne fulminans or adverse effect? *An Bras Dermatol* 2013;88 Suppl 1:193-6.
11. Rozin AP, Kagna O, Shiller Y. Sacroiliitis and severe disability due to isotretinoin therapy. *Rheumatol Int* 2010;30:985-6.
12. Eksioğlu E, Öztekin F, Unlu E, Cakci A, Keyik B, Karadavut IK. Sacroiliitis and polyneuropathy during isotretinoin treatment. *Clin Exp Dermatol* 2008;33:122-4.
13. Hughes RA. Arthritis precipitated by isotretinoin treatment for acne vulgaris. *J Rheumatol* 1993;20:1241-2.
14. Levinson M, Gibson A, Stephenson G. Sacroiliitis secondary to isotretinoin. *Australas J Dermatol* 2012;53:298-300.
15. Dubourg G, Koeger AC, Huchet B, Rozenberg S, Bourgeois P. Acute monoarthritis in a patient under isotretinoin. *Rev Rhum Engl Ed* 1996;63:228-9.
16. Fiallo P, Tagliapietra AG. Severe acute myopathy induced by isotretinoin. *Arch Dermatol* 1996;132:1521-2.
17. Dinçer Ü, Çakar E, Kırılalp MZ, Dursun H. Can isotretinoin induce sacroiliitis: three cases. *Romatizma/Rheumatism* 2008;23:157-9.
18. Rudwaleit M, Metter A, Listing J, Sieper J, Braun J. Inflammatory back pain in ankylosing spondylitis: a reassessment of the clinical history for application as classification and diagnostic criteria. *Arthritis Rheum* 2006;54:569-78.
19. Bergler-Czop B, Brzezińska-Wcisło L. Pro-inflammatory cytokines in patients with various kinds of acne treated with isotretinoin. *Postepy Dermatol Alergol* 2014;31:21-8.
20. Bidad K, Salehi E, Jamshidi A, Saboor-Yaraghi AA, Oraei M, Meysamie A, et al. Effect of all-transretinoic acid on Th17 and T regulatory cell subsets in patients with ankylosing spondylitis. *J Rheumatol* 2013;40:476-83.