

Salivary Gland Ultrasonography as a Diagnostic Tool for Secondary Sjögren Syndrome in Rheumatoid Arthritis

Sunil Das, DoQuyen Huynh, Hong Yang, Arnoldas Ceponis, and Arthur Kavanaugh

ABSTRACT. Objective. To assess salivary gland ultrasonography (US) as a diagnostic tool for secondary Sjögren syndrome (sSS) in patients with rheumatoid arthritis (RA).

Methods. Salivary gland US images from 30 patients with RA were graded using a validated semiquantitative scoring system. Sicca symptoms, oral health, and RA disease activity were assessed.

Results. US changes consistent with SS were found in 40% of patients. Patients with higher US scores had more sicca symptoms as well as higher RA activity and poorer oral health.

Conclusion. Salivary gland US may aid the diagnosis of sSS in patients with RA. (J Rheumatol First Release May 1 2015; doi:10.3899/jrheum.141149)

Key Indexing Terms:

ULTRASOUND SJÖGREN SYNDROME RHEUMATOID ARTHRITIS DIAGNOSIS

Sjögren syndrome (SS) is a chronic autoimmune disease characterized by lymphocytic infiltration of the lacrimal and salivary glands resulting in clinical symptoms of keratoconjunctivitis sicca and xerostomia. It may be primary (pSS) or secondary (sSS), and may occur in other rheumatic diseases such as rheumatoid arthritis (RA)¹. The reported prevalence of sSS in patients with RA has varied from < 4% to > 40%^{1,2,3,4}; with variation probably related to patient populations, diagnostic criteria, and testing used. In RA, sSS has been associated with more severe disease, higher risk for lymphoma, and worse outcomes^{5,6,7}.

Diagnosing SS can be challenging. The 2002 American European Consensus Group (AECG) classification criteria⁸ and the 2012 American College of Rheumatology (ACR) classification criteria⁹ include as diagnostic tests minor salivary gland biopsy, Schirmer's test/ocular staining, sialography, salivary flow, and scintigraphy. These modalities can be invasive, expensive, painful, and hard to access. The diagnostic utility of serologies [e.g., rheumatoid factor (RF), Ro/SSA, and La/SSB antibodies] is limited in isolation. There has been increasing interest in using salivary gland US to aid SS diagnosis^{10,11,12,13}, and studies have shown good correlation with other imaging modalities¹⁴ and minor salivary gland pathology¹⁵. Salivary gland US has been suggested to

increase the performance of the AECG and ACR criteria^{10,16}. While many studies have focused on pSS, we examined salivary gland US in patients with RA.

MATERIALS AND METHODS

Design. Our study was a cross-sectional observational study in a university-based, rheumatology specialty clinic.

Study population. The subjects were a convenience sample of patients diagnosed with RA according to the 1987 ACR criteria. Exclusion criteria included head and neck malignancies and previous irradiation. The study was approved by the University of California San Diego Human Research Protection Program; all patients provided written informed consent prior to procedures.

Measurements. Standard demographic information was obtained. Functional status was quantified with the multidimensional Health Assessment Questionnaire (HAQ) and RA disease activity by the Routine Assessment of Patient Index Data (RAPID3) score¹⁷. Ocular and oral dryness were assessed using a sicca syndrome questionnaire based on questions proposed by the AECG 2002 criteria for SS⁸. Oral health-related quality of life was measured using the validated Oral Health Impact Profile (OHIP-14)¹⁸.

Imaging of the salivary glands was performed using a Sono-Site M-turbo US scanner with an 8–13 MHz (small parts) linear transducer. Thyroid gland US was used as an individual reference. The parotid and submandibular glands were scanned bilaterally in longitudinal and transverse planes and assigned a score based on the system validated by Hočevár, *et al*^{11,12}. Briefly, 5 variables were semiquantitatively assessed for each gland: parenchymal echogenicity relative to the thyroid gland, homogeneity, presence of hypoechoic areas, presence of hyperechoic foci, and glandular borders (Figure 1). Grades for all 4 glands in each of the 5 variables were summed (maximum score of 48). US images were obtained and scored by 3 observers (SD, DH, and HY). To assess interrater reliability, random sets of ultrasonographic images were scored. With individual scores treated as continuous data, the correlation among raters was high: Pearson correlation coefficient 0.912, $p < 0.001$. When data were transformed into binary variables (scores < 17 or ≥ 17), correlation using Cohen's κ was 0.625 ($p = 0.03$).

Analysis. Standard descriptive statistics were used for demographic and RA characteristics. The population was divided into 2 groups based on their US scores. A cutoff of ≥ 17 , validated by Hočevár, *et al*^{11,12}, classified patients as having ultrasonographic changes consistent with SS. The independent

From the Division of Rheumatology, Allergy, and Immunology, University of California San Diego, La Jolla, California, USA.

S. Das, MD; D. Huynh, MD; H. Yang, MD, PhD; A. Ceponis, MD, PhD; A. Kavanaugh, MD.

Address correspondence to Dr. A. Kavanaugh, Professor of Medicine, Division of Rheumatology, Allergy, and Immunology, University of California, San Diego, 9500 Gilman Drive, La Jolla, California 92093-0943, USA. E-mail: akavanaugh@ucsd.edu, Rheum.doc101@gmail.com

Accepted for publication March 4, 2015.

Personal non-commercial use only. The Journal of Rheumatology Copyright © 2015. All rights reserved.

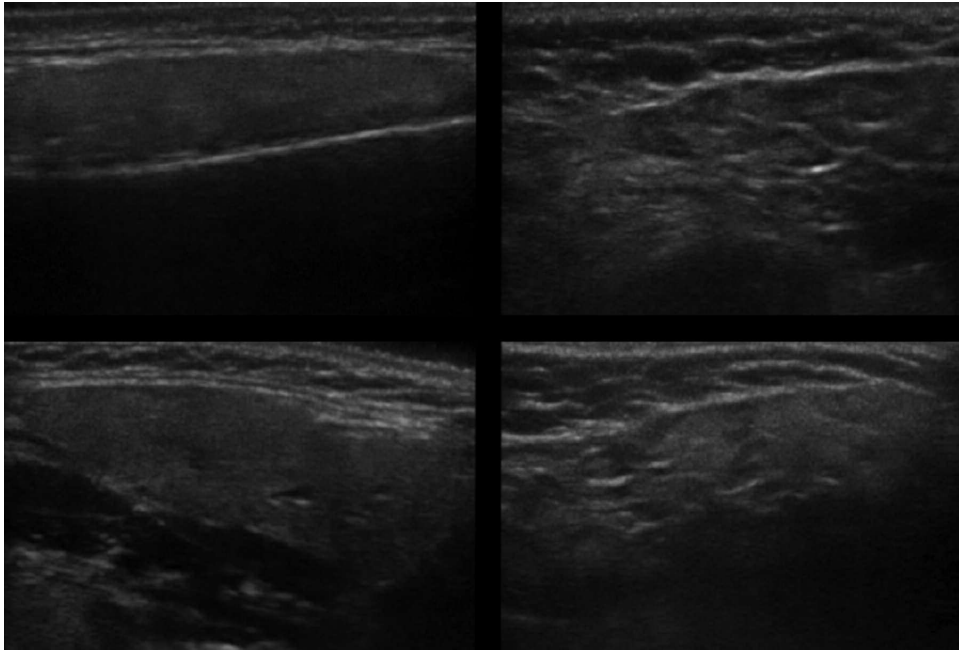


Figure 1. Ultrasound images of parotid and submandibular glands. Normal parotid (upper left) and submandibular gland (bottom left), compared to abnormal parotid (upper right) and submandibular gland (bottom right) with structural changes consistent with Sjögren syndrome. The images on the right show gland inhomogeneity, hypoechoic areas, hyperechoic stranding, and poorly defined borders.

samples t test was used to compare the number of sicca symptoms between those with and without ultrasonographic changes. ANOVA was used to compare the distribution of US scores based on the number of sicca symptoms. Independent samples t-test was applied to compare different measures of RA severity between those with and without ultrasonographic changes. For all statistical tests, α level was set at 0.05. All statistical analyses were performed using SPSS 20 software (IBM Corporation).

RESULTS

Thirty patients with RA were enrolled. Ninety percent ($n = 27$) of the participants were women with RA with a mean age (\pm SD) of 57 ± 13 years. Most were nonsmokers (67%, $n = 20$) or former smokers (27%, $n = 8$); only 2 (7%) currently smoked. Of 29 patients with available results, 69% were RF-positive; 82% of 28 had antibodies to citrullinated proteins; and 65% of 17 were antinuclear antibody-positive. Results for antibodies to SSA and SSB were only available for 13 and 14 participants; none were positive.

Twelve of 30 participants (40%) had US scores ≥ 17 ; higher scores indicate more structural changes and scores ≥ 17 are consistent with SS (Figure 1). Those with scores ≥ 17 answered positively to more questions on the sicca syndrome questionnaire (3.3 vs 1.3, $p = 0.009$). Further, when divided into groups based on the number of sicca questions answered positively, higher numbers of positive responses corresponded with higher US scores (ANOVA, $F = 3.13$, $p = 0.026$; Figure 2). Those with US scores ≥ 17 also had significantly worse periodontal health (higher OHIP questionnaire scores; mean scores 14.8 vs 3.2, $p = 0.007$).

When divided by US scores, patients with scores ≥ 17 had significantly higher disease activity (RAPID3 scores). HAQ scores, erythrocyte sedimentation rate, and C-reactive protein were not significantly different between those with and without substantial ultrasonographic changes (Table 1).

DISCUSSION

SS results in structural changes in the salivary glands such as hypoechoic regions and hyperechoic stranding, which are readily detected with US. Several studies have assessed salivary gland US for the diagnosis of pSS^{10,11,12,13}. Our goal was to assess the utility of US in diagnosing sSS among patients with RA. We found that 40% of patients with RA, recruited without knowledge of sicca symptoms, had sonographic salivary gland changes consistent with SS.

Previous studies have reported prevalences of sSS in RA ranging from 4% to 40%^{2,3,4}. Our study, using a sonographic scoring system, found a prevalence of 40%. De Vita, *et al* assessed salivary gland US in both pSS and sSS and found sonography less sensitive in sSS (53.8% against asymptomatic controls; 46.2% against symptomatic controls) compared to pSS (sensitivity 81.5%), although specificity was still $\sim 90\%$ ¹⁹. Notably, their scoring system assessed only 1 variable (gland homogeneity) and validated the diagnosis using older SS criteria. We used a scoring system and cutoff score approach incorporating 5 different US variables, developed by Hočevár, *et al* and validated against the 2002 AECG criteria¹¹. Subsequently, that group demonstrated

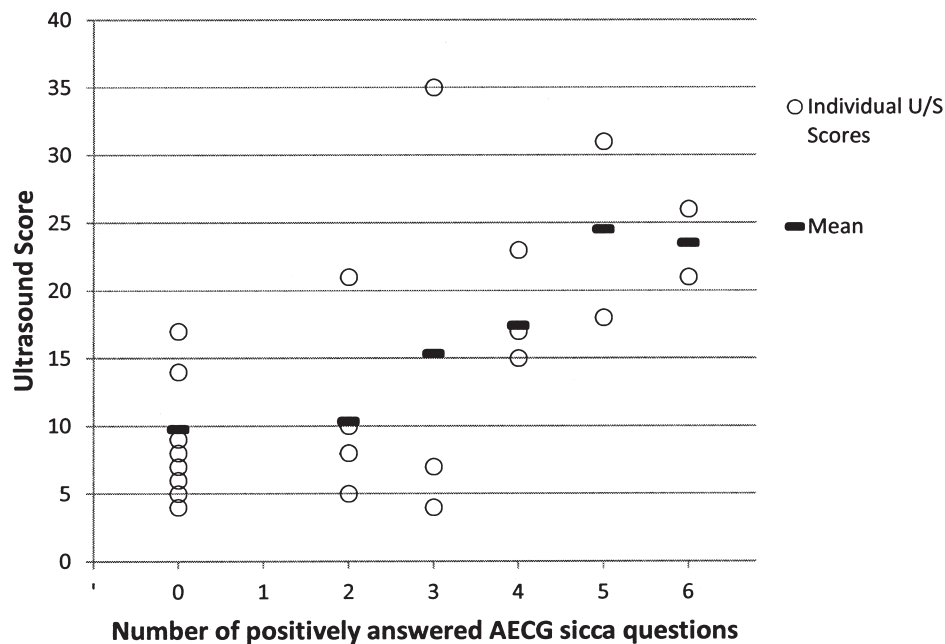


Figure 2. Mean ultrasound (U/S) score grouped by number of positively answered American European Consensus Group (AECG) sicca questions.

Table 1. Comparison of those with and without changes on ultrasonography. T test of means used for all statistical tests, except where denoted by *, where Fisher's exact test was used.

Mean	US Score < 17, n = 18	U/S Score ≥ 17, n = 12	p
Total sicca score	1.33	3.25	0.009
% former or current smokers	27.8	41.7	0.461*
OHIP score	3.17	14.75	0.007
HAQ score	0.82	1.15	0.138
RAPID3 score	10.22	15.58	0.013
ESR	33.44	21.58	0.099
CRP	1.43	0.63	0.079

Significant data are given in bold face. US: ultrasound; OHIP: Oral Health Inventory Profile-14; HAQ: Health Assessment Questionnaire; RAPID3: Routine Assessment of Patient Index Data 3; ESR: erythrocyte sedimentation rate; CRP: C-reactive protein.

reproducibility as well as high specificity (98.7%), with higher sensitivity (58.8%)¹².

Cornec, *et al* demonstrated that using salivary gland US in addition to standard testing used in the 2002 AECG criteria improved sensitivity in diagnosing SS from 77.9% to 85.7%. Because no gold standard exists for SS diagnosis, Cornec, *et al* used 3 experts as the reference standard. They suggested salivary gland US be used initially to avoid salivary gland biopsy¹⁰. It has been proposed that new criteria for SS might incorporate US instead of more invasive modalities¹³. Our findings further support the potential utility of US in sSS.

Our study demonstrates that not only the severity of reported sicca symptoms correlated significantly with sonographic changes seen on US, but also that patients with changes on salivary gland US had significantly worse oral health-related quality of life. This is an important practical observation because those with SS are known to be more prone to dental caries, oral candidiasis, and periodontal disease¹. Periodontal disease has been suggested to correlate with or even contribute to the pathogenesis of RA²⁰. Thus, sonographic diagnosis of sSS in patients with RA may potentially help to identify the patients who need routine assessment and management of their oral health.

In our study, patients with changes on salivary gland US had higher RAPID3 scores than those without changes, indicating more active RA. This contrasts with the findings of Haga, *et al* and Antero, *et al* that RA patients with sSS did not have more active disease (using the Disease Activity Score)^{2,3}. It is possible that the RAPID3, consisting of 3 patient-reported outcomes, may better identify this aspect of extraarticular disease.

Although the US changes corresponded well to sicca symptoms, a limitation of our study is that it did not include the more established objective measures of lacrimal and salivary gland structure and function, including salivary gland biopsy, sialography, salivary flow, and scintigraphy. Therefore, this study was not able to make a comparison to currently accepted classification criteria of SS, and it was limited to determining which participants had ultrasonographic changes consistent with the disease. While interrater

reliability between 2 of the observers was high, intrarater reliability was not assessed in our study.

Our data support salivary gland US as a potential non-invasive imaging tool for diagnosing sSS in patients with RA.

REFERENCES

1. Fox RI. Sjogren's syndrome. *Lancet* 2005;366:321-31.
2. Haga HJ, Naderi Y, Moreno AM, Peen E. A study of the prevalence of sicca symptoms and secondary Sjogren's syndrome in patients with rheumatoid arthritis, and its association to disease activity and treatment profile. *Int J Rheum Dis* 2012;15:284-8.
3. Antero DC, Parra AG, Miyazaki FH, Gehlen M, Skare TL. Secondary Sjogren's syndrome and disease activity of rheumatoid arthritis. *Rev Assoc Med Bras* 2011;57:319-22.
4. Drosos AA, Lanchbury JS, Panayi GS, Moutsopoulos HM. Rheumatoid arthritis in Greek and British patients. A comparative clinical, radiologic, and serologic study. *Arthritis Rheum* 1992;35:745-8.
5. Young A, Koduri G. Extra-articular manifestations and complications of rheumatoid arthritis. *Best Pract Res Clin Rheumatol* 2007;21:907-27.
6. Martens PB, Pillemer SR, Jacobsson LT, O'Fallon WM, Matteson EL. Survivorship in a population based cohort of patients with Sjogren's syndrome, 1976-1992. *J Rheumatol* 1999;26:1296-300.
7. Kauppi M, Pukkala E, Isomaki H. Elevated incidence of hematologic malignancies in patients with Sjogren's syndrome compared with patients with rheumatoid arthritis (Finland). *Cancer Causes Control* 1997;8:201-4.
8. Vitali C, Bombardieri S, Jonsson R, Moutsopoulos HM, Alexander EL, Carsons SE, et al. Classification criteria for Sjogren's syndrome: a revised version of the European criteria proposed by the American-European Consensus Group. *Ann Rheum Dis* 2002;61:554-8.
9. Shiboski SC, Shiboski CH, Criswell L, Baer A, Challacombe S, Lanfranchi H, et al. American College of Rheumatology classification criteria for Sjogren's syndrome: a data-driven, expert consensus approach in the Sjogren's International Collaborative Clinical Alliance cohort. *Arthritis Care Res* 2012;64:475-87.
10. Cornec D, Jousse-Joulin S, Pers JO, Marhadour T, Cochener B, Boissrame-Gastrin S, et al. Contribution of salivary gland ultrasonography to the diagnosis of Sjogren's syndrome: toward new diagnostic criteria? *Arthritis Rheum* 2013;65:216-25.
11. Hočevnar A, Ambrozic A, Rozman B, Kveder T, Tomsic M. Ultrasonographic changes of major salivary glands in primary Sjogren's syndrome. Diagnostic value of a novel scoring system. *Rheumatology* 2005;44:768-72.
12. Hočevnar A, Rainer S, Rozman B, Zor P, Tomsic M. Ultrasonographic changes of major salivary glands in primary Sjogren's syndrome. Evaluation of a novel scoring system. *Eur J Radiol* 2007;63:379-83.
13. Vitali C, Carotti M, Salaffi F. Is it the time to adopt salivary gland ultrasonography as an alternative diagnostic tool for the classification of patients with Sjogren's syndrome? Comment on the article by Cornec et al. *Arthritis Rheum* 2013;65:1950.
14. Niemela RK, Takalo R, Paakko E, Suramo I, Paivansalo M, Salo T, et al. Ultrasonography of salivary glands in primary Sjogren's syndrome. A comparison with magnetic resonance imaging and magnetic resonance sialography of parotid glands. *Rheumatology* 2004;43:875-9.
15. Salaffi F, Argalia G, Carotti M, Giannini FB, Palombi C. Salivary gland ultrasonography in the evaluation of primary Sjogren's syndrome. Comparison with minor salivary gland biopsy. *J Rheumatol* 2000;27:1229-36.
16. Cornec D, Jousse-Joulin S, Marhadour T, Pers JO, Boissrame-Gastrin S, Renaudineau Y, et al. Salivary gland ultrasonography improves the diagnostic performance of the 2012 American College of Rheumatology classification criteria for Sjogren's syndrome. *Rheumatology* 2014;53:1604-7.
17. Pincus T, Swearingen CJ, Bergman MJ, Colglazier CL, Kaell AT, Kunath AM, et al. RAPID3 (Routine Assessment of Patient Index Data) on an MDHAQ (Multidimensional Health Assessment Questionnaire): agreement with DAS28 (Disease Activity Score) and CDAI (Clinical Disease Activity Index) activity categories, scored in five versus more than ninety seconds. *Arthritis Care Res* 2010;62:181-9.
18. Brennan DS, Spencer AJ. Dimensions of oral health related quality of life measured by EQ-5D+ and OHIP-14. *Health Qual Life Outcomes* 2004;2:35.
19. De Vita S, Lorenzon G, Rossi G, Sabella M, Fossaluzza V. Salivary gland echography in primary and secondary Sjogren's syndrome. *Clin Exp Rheumatol* 1992;10:351-6.
20. Scher JU, Bretz WA, Abramson SB. Periodontal disease and subgingival microbiota as contributors for rheumatoid arthritis pathogenesis: modifiable risk factors? *Curr Opin Rheumatol* 2014;26:424-9.