

Distinguishing Gouty Arthritis from Calcium Pyrophosphate Disease and Other Arthritides

Christian Löffler, Horst Sattler, Lena Peters, Uta Löffler, Michael Uppenkamp, and Raoul Bergner

ABSTRACT. Objective. Differentiating gout, calcium pyrophosphate deposition disease (CPPD), and non-crystal-related inflammatory arthropathies (non-CRA) is essential but often clinically impossible. The sonographic double contour (DC) sign may have good specificity for gout in highly specialized centers, but it can be challenging to use it to distinguish gout from cartilage hyperenhancements in CPPD. We evaluated the diagnostic value of the DC sign alone and in combination with Doppler signals and uric acid (UA) levels in patients with acute arthritis.

Methods. We retrospectively investigated 225 acutely inflamed joints and documented the presence of DC, Doppler hypervascularization, and serum UA (SUA) levels. All patients underwent synovial fluid (SF) analysis. Sensitivity, specificity, and positive predictive values were calculated, and correlation analyses and a binary regression model were used to investigate their diagnostic values.

Results. The sensitivity of DC sign for crystalline arthritides was 85% and specificity 80%. Its specificity for gout was 64%, for CPPD 52%. In contrast to non-CRA hypervascularization, degree 2 and 3 Doppler signals were highly associated with gout and less with CPPD ($p < 0.01$). The combination of DC sign with hypervascularization and elevated UA levels increased specificity for gout to more than 90% and resulted in a 7-fold increase of the likelihood of diagnosis of gout ($p < 0.01$), but with a loss of sensitivity (42%).

Conclusion. The DC sign alone is suitable for predicting crystal-related arthropathies, but it cannot reliably distinguish gout from CPPD in everyday clinical routine. Combining hypervascularization and SUA levels increases the diagnostic value, leading us to propose a diagnostic algorithm. (J Rheumatol First Release Nov 15 2014; doi:10.3899/jrheum.140634)

Key Indexing Terms:

GOUT

DOUBLE CONTOUR

CPPD

HYPERVASCULARIZATION

SONOGRAPHY

DOPPLER

Both gout and calcium pyrophosphate deposition disease (CPPD) are crystal-related joint diseases that often present with acute monoarthritis or oligoarthritis and are caused by synovial deposition of monosodium urate (MSU) or calcium pyrophosphate (CPP) crystals, respectively. The process of crystal precipitation induces an inflammatory cascade resulting in joint effusion, extensive pain, and swelling¹.

The inflammation is decisively maintained by macrophages and neutrophils and by upregulation of interleukin 1 β and cryopyrin pathways^{2,3}. Gouty arthritis can be triggered by consumption of alcohol and purine-rich foods and occurs more often in male patients with hyperuricemia⁴. CPPD arthritis is the third most common inflammatory arthritis, with risk factors being aging, osteoarthritis, various metabolic disorders, and past trauma⁵.

Joint ultrasound (US) is a key diagnostic tool in establishing the diagnosis. It can compete with computed tomography and magnetic resonance imaging in diagnostic sensitivity and specificity^{6,7}. Crystal-related arthropathies (CRA) can be identified sonographically by a hyperechoic enhancement of the articular cartilage. In the case of gout, it has been suggested that thickening of the superficial synovial margin — called the double contour (DC) sign — was highly specific^{8,9,10,11,12}, whereas CPPD arthritis was characterized by hyperechoic spots within the cartilage layer^{8,13}. Recently, however, doubts have arisen as to the unequivocal interpretation of the DC sign and its seemingly high specificity for gout. Especially in the presence of joint effusion not compressible with the transducer head, the definite allocation of the hyperechoic enhancement to either

From the Department of Rheumatology, Nephrology, and Oncology, Klinikum Ludwigshafen, Ludwigshafen; Department of Nephrology, Hypertensiology, Rheumatology, University Hospital Mannheim, Mannheim; Center of Psychological Psychotherapy, University of Heidelberg, Heidelberg, Germany.

C. Löffler, MD, Department of Rheumatology, Nephrology, and Oncology, Klinikum Ludwigshafen, University Hospital Mannheim, University of Heidelberg; H. Sattler, MD; L. Peters, MD, Department of Rheumatology, Nephrology, Oncology, Klinikum Ludwigshafen; U. Löffler, Dipl Psych, Center of Psychological Psychotherapy, University of Heidelberg; M. Uppenkamp, MD, PhD, Department of Rheumatology, Nephrology, Oncology, Klinikum Ludwigshafen; R. Bergner, MD, Department of Rheumatology, Nephrology, and Oncology, Klinikum Ludwigshafen, University Hospital Mannheim, University of Heidelberg.

Address correspondence Dr. C. Löffler, Klinikum Ludwigshafen, Bremsenstr. 79, D-67067 Ludwigshafen, Germany.

E-mail: christianloeffler@gmx.de

Accepted for publication October 1, 2014.

Personal non-commercial use only. The Journal of Rheumatology Copyright © 2014. All rights reserved.

the superficial margin or the intracartilage area proves difficult^{14,15}. Moreover, intracartilage hyperechoic enhancement in CPPD can also appear as a hyperechoic band parallel to the articular surface¹⁶, making the distinction of the DC sign in gout even more tenuous (Figure 1).

Only a few studies have dealt with gout and CPPD arthritis in direct comparison^{9,10,11,12}. Others limit their focus to a single joint^{9,10}.

In our present study we retrospectively analyzed 225 joints of patients who presented to our rheumatology department with clinical signs of acute monoarthritis or oligoarthritis. We aimed at investigating the predictive value of hyperechoic cartilage enhancements in combination with hypervascularization in color Doppler studies and serum uric acid (SUA) levels. Definite diagnosis was established by SF analysis.

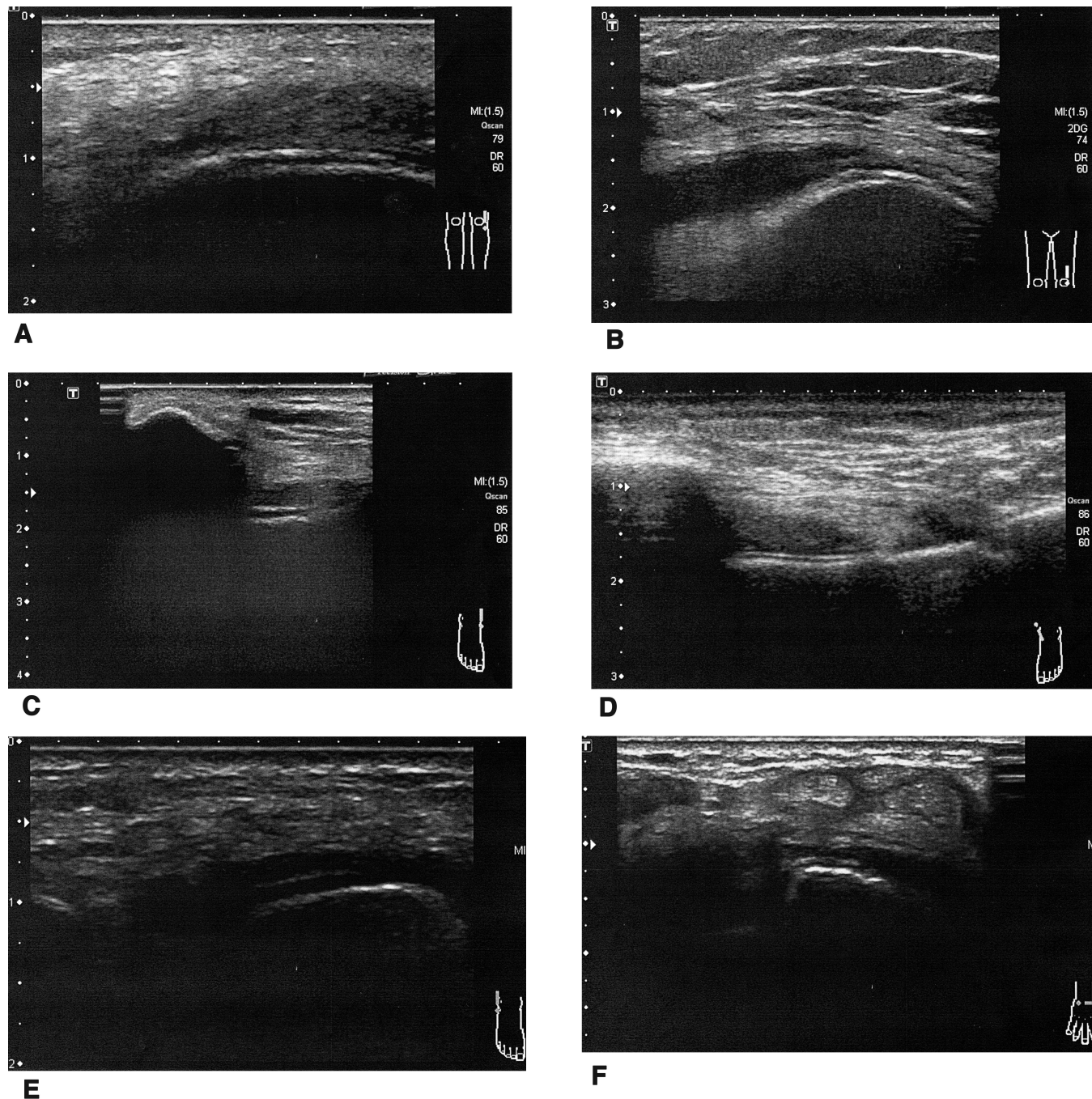


Figure 1. A. Knee joint with DC sign in gout. B. Knee joint with DC sign in CPPD. C. Ankles with DC sign in gout. D. Ankles with DC sign in CPPD. E and F: DC sign in gout presenting as seemingly intracartilage hyperechoic enhancements in the presence of joint effusion. DC: double contour; CPPD: calcium pyrophosphate deposition disease.

MATERIALS AND METHODS

All patients included in this retrospective study presented with acute monoarthritis or oligoarthritis within the daily hospital routine. We investigated 225 joints in total. We included every type and size of joint. All patients received an US of the affected joint, done by physicians with at least 2 years experience in joint sonography. All sonographers were specially trained in joint sonography and certified by the standards of the German Society of Ultrasound in Medicine (DEGUM). Two of them were DEGUM level 2 and 3 sonographers (3 being the highest DEGUM certification, i.e., US trained). We used an Aplio 400 (Toshiba) and a Xario XG (Toshiba) US device, each equipped with a high-frequency (7–14 MHz) linear transducer head. The devices are contained in the list of recommended US machines for high-quality sonography meeting DEGUM level 3 standards (see www.degum.de).

Cartilage enhancements presenting as a line parallel to the bony articular surface were characterized as DC sign. The DC's relation to the cartilage (superficial margin vs intracartilage) and hypervascularization in Doppler/Duplex studies in power color mode were documented. The degree of hypervascularization was semiquantitatively classified as 0 degrees (none), degree 1 (≤ 3 isolated Doppler signals), degree 2 (> 3 distinct Doppler signals), and degree 3 (large converging Doppler signals). After US, all patients underwent SF analysis by needle aspiration of the affected joint. SF specimens were analyzed by a consultant in pathology using polarizing microscopy. The presence of phagocytized MSU crystals was diagnostic for gout, that of CPP crystals for CPPD. In cases where both crystal entities were detected, the diagnosis of combined gout/ CPPD was made. In the absence of crystalline structures, the pathologist distinguished inflammatory from noninflammatory SF by the number of leukocytes present (semiquantitatively). At the time of the US, the results of the SF analysis were unknown to the sonographer. SUA levels were documented when available. Elevated UA levels were defined as > 7.5 mg/dl (446 $\mu\text{mol/l}$), according to the margin of reference provided by our laboratory.

Statistical analyses were performed with SPSS v11.5. We calculated sensitivities, specificities, positive/negative likelihood ratios (LR), and positive/negative predictive values by chi-square confusion matrices. Correlation analyses (Pearson and Spearman coefficient) and a binary logistic regression model were used to evaluate the predictive value of the DC sign, degree of hypervascularization, and SUA levels for the underlying

diagnosis. The comparison of mean UA levels between diagnosis groups was done with a unifactorial ANOVA. Statistical significance was defined as a 2-tailed $p < 0.05$.

RESULTS

Epidemiological data. The cases analyzed in our study had a male:female ratio of 1.7:1. In gout, 82% of the patients were male, in CPPD, 63%. The mean age was 64 ± 16 years (range 18–93); that of the gout group was 69 ± 12 years and that of the CPPD group, 73 ± 11 years. There were no statistically significant differences in age distribution over the different diagnosis groups ($p = 0.57$). We investigated 225 joints with clinical signs of arthritis, most of which were knees (58%) and ankles (17%). A list of all investigated joints is in Figure 2. We diagnosed 74 cases of gout (33%), 38 cases of CPPD (17%), and 9 cases of combined gout and CPPD with presence of both MSU and CPP crystals in SF analysis (4%). There were 80 cases (36%) of non-crystal-related inflammatory joint disease (non-CRA) such as rheumatoid arthritis, psoriatic arthritis, septic arthritis, and others. Because the focus of this work was crystal-related arthropathies, we did not divide this group into its sub-entities. The remaining 24 joints (11%) were attributed to noninflammatory joint diseases such as osteoarthritis, hemarthros, or reactive joint effusion after overexertion (Figure 3).

Evaluation of the DC sign. Cartilage enhancements presenting as a hyperechoic line parallel to the articular surface were classified as DC sign. In only 5 cases could we definitely classify these enhancements as being located within the cartilage layer. All these cases were CPPD. If not definitely of intracartilage localization, the DC sign was

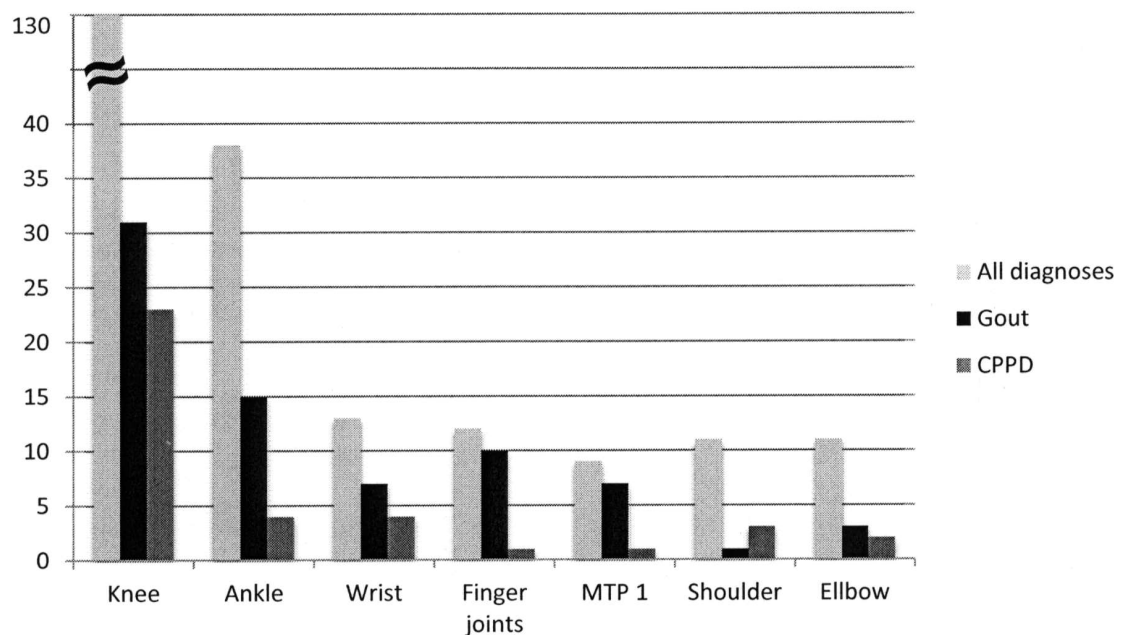


Figure 2. Numbers of investigated joints. MTP: metatarsophalangeal joint; CPPD: calcium pyrophosphate deposition disease.

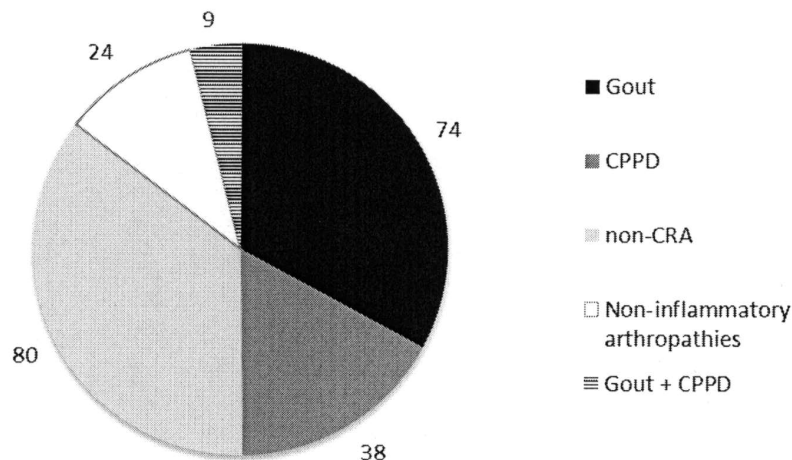


Figure 3. Quantitative distribution of diagnoses. Total = 225 investigated joints. CPPD: calcium pyrophosphate deposition disease; non-CRA: non-crystal-related inflammatory arthropathies.

highly correlated with CRA ($r = 0.628$, $p < 0.001$), but was not able to distinguish between gout and CPPD. The sensitivity of the DC sign for crystalline arthritides was 84.8%, with a specificity of 79.8% and a positive predictive value (PPV) of 81.9% (Table 1). However, the specificities for gout and CPPD were only 64.1% and 51.7%, respectively. In binary regression analysis (gout vs CPPD), the DC sign did not reach levels of significance (OR 2.49, $p = 0.556$, 95% CI 0.84–7.41).

In our study the DC sign alone was able to predict a crystal-related joint disease but it could not distinguish between the types of crystals present.

Evaluation of UA levels in serum. The mean UA level in patients with gout in our study was 9.4 ± 3.7 mg/dl, significantly higher than in any other diagnosis group, as depicted in Figure 4: CPPD 6.4 ± 3.2 mg/dl, non-CRA 5.4 ± 1.9 mg/dl, non-inflammatory arthropathies 6.7 ± 3.5 mg/dl ($p < 0.001$). In both correlation and regression analyses, this relationship remained highly significant (OR 10.1, $p < 0.001$, 95% CI 3.54–28.83).

Evaluation of hypervascularization. Fifty-seven out of 74 gouty joints showed hypervascularization of degree 2 or higher (77%), in contrast to only 25 out of 34 (66%) in CPPD and 37 out of 80 (46%) in non-CRA. Of all joints showing hypervascularization degree 3, 55% turned out to be gout, and 20% and 21.5% were diagnosed as CPPD and non-CRA, respectively (Figure 5). These relationships were highly statistically significant ($p < 0.001$). The regression model confirmed these results: the degree of hypervascularization was significantly linked to the diagnosis of gout (OR 1.93, $p < 0.01$, 95% CI 1.16–3.20).

The likelihood of gout significantly increased the more intensively the affected joints were vascularized in Doppler/Duplex examination.

Combining DC sign, hypervascularization, and UA levels. If a DC sign coincided with hypervascularization, correlation analyses were still significant for both forms of CRA, yet the correlation was weaker for CPPD than for gout (gout: $r = 0.421$, $p < 0.001$; CPPD: $r = 0.178$, $p < 0.01$). Specificity for gout increased to 75.4% (Table 1), while the PPV for

Table 1. Summary of statistical data regarding sensitivity, specificity, positive and negative predictive value (PPV, NPV) and positive and negative likelihood ratios (LR).

Diagnosis	Applied Diagnostics	Sensitivity (%)	Specificity (%)	PPV (%)	NPV (%)	LR+	LR-
CRA in total	DC	84.8	79.8	81.9	83.0	4.2	0.2
	DC/Do	63.4	86.5	83.5	68.7	4.7	0.4
	DC/Do/SUA	31.3	93.3	83.3	55.7	4.7	0.7
Gout	DC	87.8	64.1	56.0	91.0	2.4	0.2
	DC/Do	67.6	75.4	58.8	81.7	2.8	0.4
	DC/Do/SUA	42.0	92.3	88.6	72.8	5.3	0.6
CPPD	DC	78.9	51.7	25.6	92.0	1.6	0.4
	DC/Do	55.3	64.0	24.7	87.0	1.5	0.7
	DC/Do/SUA	14.9	78.7	15.6	77.8	0.7	1.1

DC: double contour; Do: Doppler with hypervascularization ≥ 2 ; SUA: serum uric acid; CRA: crystal-related arthropathy; CPPD: calcium pyrophosphate deposition disease.

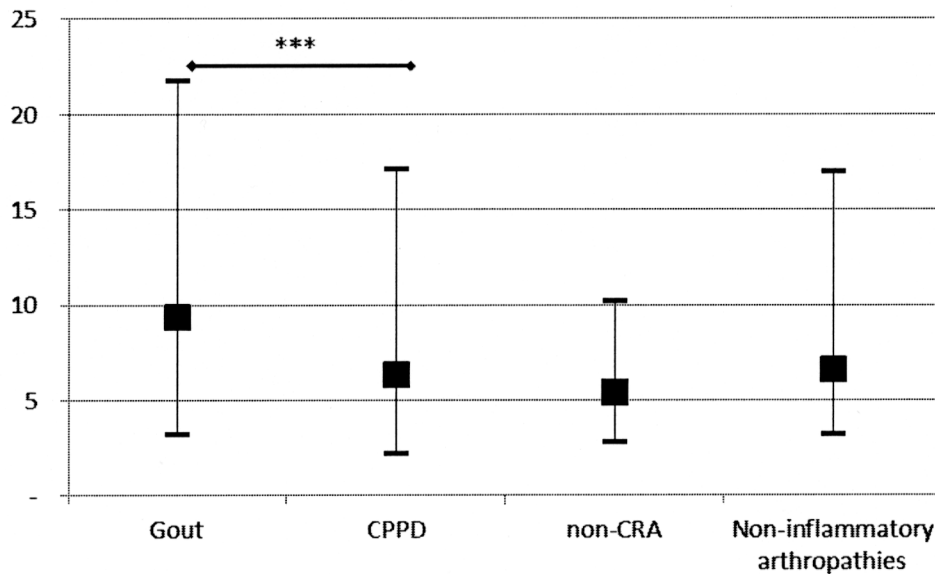


Figure 4. Mean serum uric acid levels with variance. *** $p < 0.001$. CPPD: calcium pyrophosphate deposition disease; non-CRA: non-crystal-related inflammatory arthropathies.

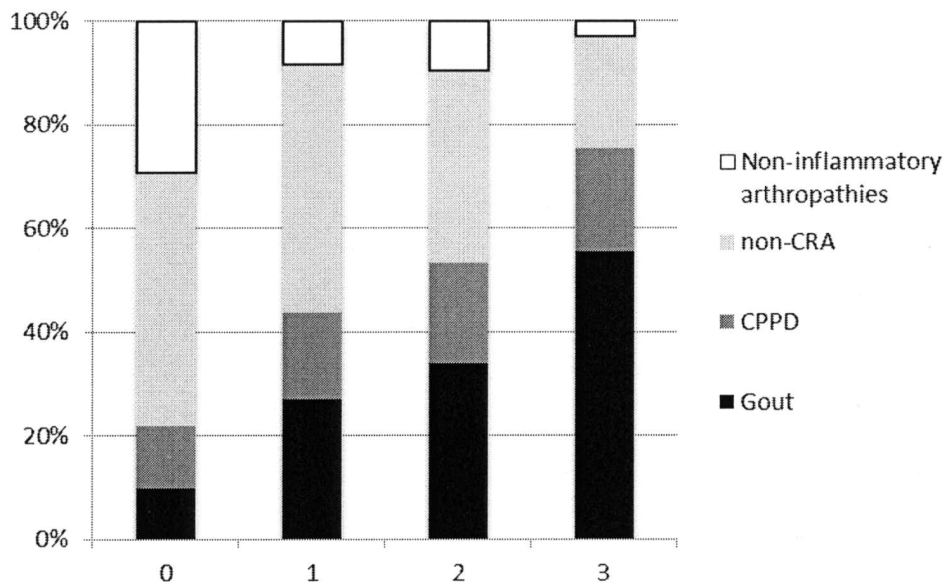


Figure 5. Percentage of each diagnosis group over the 4 different degrees of vascularization in Doppler/Duplex. CPPD: calcium pyrophosphate deposition disease; non-CRA: non-crystal-related inflammatory arthropathies.

gout was virtually identical to that of the DC sign alone. In regression analysis, the combination of DC sign and hypervascularization could not predict gout.

Combining a positive DC sign with hypervascularization and elevated UA levels, however, resulted in a significant positive correlation for gout in contrast to CPPD or any other diagnosis (gout: $r = 0.401$, $p < 0.001$; CPPD: $r = -0.66$,

$p = 0.33$). Specificity for gout was now 92.3%, but at the expense of sensitivity, which decreased to 42%. The PPV for gouty arthritis increased to 88.6% compared to 58.8% (DC sign with hypervascularization) and 56% (DC sign alone). The positive log LR was 5.3, indicating a strong pretest probability for gout. In the regression model the triple combination was able to predict gout with high statis-

tical significance and increased the likelihood of the diagnosis of gout by a factor of 7 (OR 7.40, $p < 0.01$, 95% CI 2.07–26.47). Table 1 lists the statistical characteristics of the investigated diagnostic combinations.

Special case: simultaneous gout and CPPD. In 9 cases (4%), the pathologist found both MSU and CPP crystals in the same SF specimen. These cases were excluded from the above-mentioned analyses because they naturally cannot contribute to distinguishing the 2 forms of CRA. DC sign was seen in 7 joints (77.8%) and hypervascularization was degree 2 or higher in 8 out of 9 cases (88.9%). Mean UA levels in this subgroup were 7.9 ± 2.2 mg/dl. Interestingly, only 3 cases showed UA levels > 7.5 mg/dl (33.3%).

DISCUSSION

In our retrospective study of 225 acutely affected joints we evaluated the utility of the DC sign, joint hypervascularization in Doppler power color mode, and SUA levels and their combinations in diagnosing CRA (as well as their capability to differentiate gout from CPPD and other arthropathies). The gold standard of diagnosis was SF analysis according to the European League Against Rheumatism recommendations¹⁷.

In the literature the DC sign is attributed to a high specificity for gout^{8,9,10,11,12}. However, various studies have no or very low numbers of cases with CPPD in their control groups^{9,10,11,12,18}, or they limit their investigations to metatarsophalangeal and/or knee joints^{9,10,19}. If hyperechoic depositions in CPPD are densely accumulated, they can appear as continuous lines running parallel to the articular surface, making it very challenging if not impossible to distinguish them from the classic DC (Figure 1 A-D). Other authors have come to similar conclusions^{14,15}. It is our clinical experience that in acute arthritis with joint effusion, the definite allocation of sonographic hyperechoic cartilage enhancements to either the superficial margin as in gout or to the intracartilage area as in CPPD is rarely possible, even for experienced joint sonographers (Figure 1 E-F). In our investigation the DC sign was highly associated with CRA with good sensitivity and specificity and a high positive LR, but it could not differentiate the 2 crystal-related diseases. In the 5 cases in which hyperechoic enhancements were undoubtedly of intracartilage localization, the diagnosis CPPD was made in 100% of the cases. Notably, in 21 of 116 cases (18.1%) with positive DC sign, we found a non-CRA. Given its pathophysiology, a DC in the absence of crystalline disease seems like a paradox. One explanation could be the anatomy and shape of certain bones, which in some patients might lead to the false detection of a DC sign. Further, a DC is present not only during acute flares of CRA but also beyond that point^{20,21,22}. Some of our patients might have presented with an acute flare of a non-CRA while having asymptomatic hyperuricemia or even a history of CRA that was not present at the time of investigation but

might have led to the formation of crystalline joint deposits in the past.

We have limited our investigation to the acutely affected joint at disease flare. Others have extended their US studies to more joints; however, they included patients not presenting with an acute clinical exacerbation of arthritis and with an exclusive history of gout^{20,21}. These authors detected US findings in clinically unaffected joints attributable to gout. Perhaps in acute arthritis it is possible to improve the diagnostic value of the US if clinically healthy joints are included into the examination, as Lamers-Karnebeek and colleagues have recently suggested²².

Very few studies included Doppler signals in their evaluation^{19,21}. Doppler/Duplex is often used to successfully detect even subclinical synovitis, but most studies have dealt with non-crystal-related joint diseases^{23,24,25}. In our study, higher degrees of hypervascularization (\geq degree 2) in power color mode were associated with gout and made that diagnosis more likely than CPPD or non-CRA (Figure 4). In combination with the DC sign, specificity for gout increased. This could be explained by the high inflammatory potential inherent to CRA, involving not only the immune system's cellular components but also the joint's vasculature³. Whether CPPD has a lesser inflammatory momentum than gout is purely speculative and clinically doubtful. Further studies including Doppler/Duplex examinations in the field of CRA are warranted.

It is well accepted that gouty arthritis occurs more frequently in hyperuricemic patients^{4,17}; however, it is likewise accepted that SUA levels can be normal in acute gouty arthritis while individuals with elevated UA might never be symptomatic¹⁷. Although mean UA levels in patients with gout were significantly higher than in any other disease group in our study (Figure 5), one can neither establish the diagnosis of gout nor rule out any other joint disease when relying solely on SUA. However, our data suggest that the concomitance of DC, hypervascularization, and elevated UA makes a diagnosis of gout 7 times more likely than one of CPPD or non-CRA. Moreover, in this case the PPV for gout is almost 89% and the specificity for gout rises to 92%. We propose a diagnostic algorithm (Figure 6) that can guide the clinician. The low sensitivity of 42% for gout, however, must be kept in mind, and means that a DC sign in the absence of either elevated UA or hypervascularization or both makes gout and CPPD equally likely (55.2% vs 44.8%). Hence, SF analysis is still required to confirm the diagnosis.

Interestingly, we detected 9 cases of simultaneous gout and CPPD. To our knowledge there are no reports of the kind published so far. The great majority of these cases had a positive DC sign and was strongly vascularized. A profound statistical statement, however, cannot be made.

Our work has some limitations that should be addressed. This study is retrospective in design. The cases were

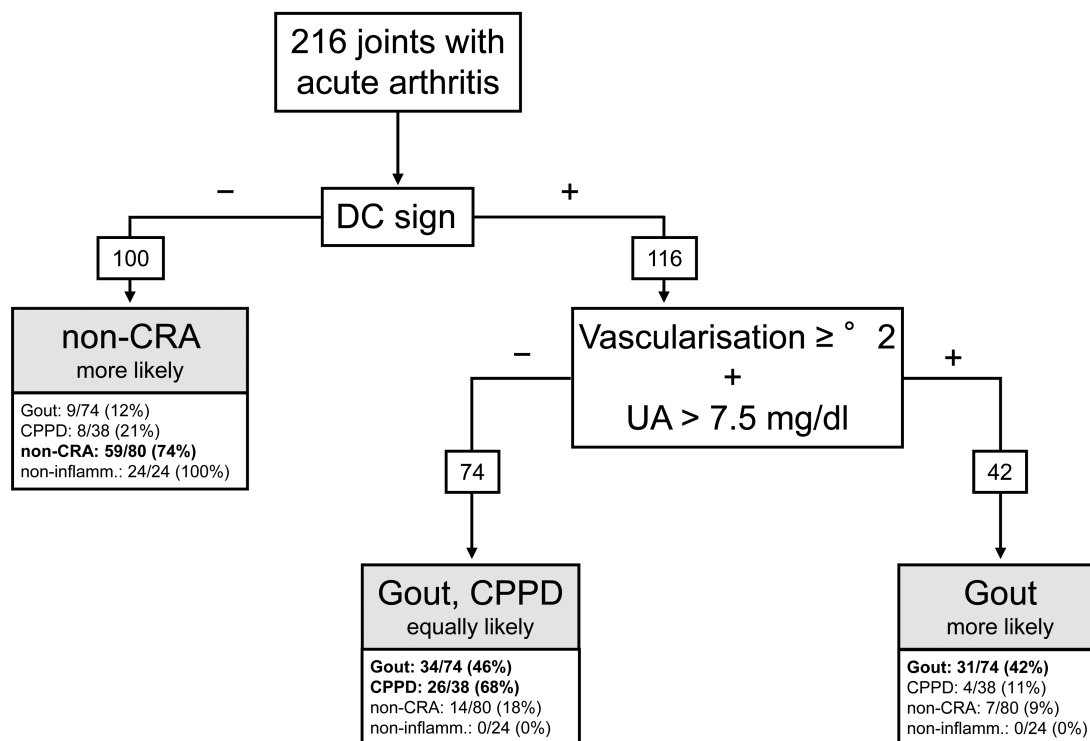


Figure 6. Possible diagnostic algorithm to differentiate gout, CPPD, and non-CRA. Of the 225 total cases, the missing ones are the 9 cases with coincidence of gout + CPPD. Below each branch, the absolute numbers in relation to total assurance of the diagnosis are given. Non-inflamm.: noninflammatory joint disease; CPPD: calcium pyrophosphate deposition disease; non-CRA: non-crystal-related inflammatory arthropathies; DC: double contour; UA: uric acid.

recruited from our clinical routine and therefore a total of 6 physicians performed the US. All sonographers were trained in joint sonography by DEGUM standards. However, the level of experience varied. In difficult or uncertain cases, a less experienced examiner consulted more experienced colleagues to verify findings. This procedure, however, was not standardized and could affect the sonographic results. The US findings were not routinely confirmed by a second sonographer blinded to the first results. Our US examinations focused on cartilage enhancements and Doppler flow. Other signs such as erosions, tophi, or tendon pathologies were not taken into consideration^{11,26}. The types of joints in our study were predominantly knees and ankles because these are common sites for CRA and other inflammatory joint diseases. For a separate evaluation for each joint, the study cohort lacked the appropriate case numbers.

Our data suggest that in daily clinical routine outside highly specialized joint sonography centers (like those of Filippucci^{12,19}, Grassi^{8,26}, and colleagues, for instance) the sonographic DC sign is highly specific for CRA but not for gout in particular. However, this specificity can be decisively increased by easy and commonly available instruments such as the Doppler-based evaluation of hyper-vascularization and determination of SUA levels. Further studies are required to facilitate and ensure the diagnosis in

patients with acute monoarthritis and oligoarthritis with noninvasive techniques, especially for patients in whom joint puncture is contraindicated.

REFERENCES

1. Fang ZH, Waizy H. Current concepts in the treatment of gouty arthritis. *Orthop Surg* 2013;5:6-12.
2. Terkeltaub R, Sundry JS, Schumacher HR, Murphy F, Bookbinder S, Biedermann S, et al. The interleukin 1 inhibitor riloncept in treatment of chronic gouty arthritis: results of a placebo-controlled, monosequence crossover, non-randomised, single-blind pilot study. *Ann Rheum Dis* 2009;68:1613-7.
3. Cronstein BN, Sunkureddi P. Mechanistic aspects of inflammation and clinical management of inflammation in acute gouty arthritis. *J Clin Rheumatol* 2013;19:19-29.
4. Duskin-Bitan H, Cohen E, Goldberg E, Shochat T, Levi A, Garty M, et al. The degree of asymptomatic hyperuricemia and the risk of gout. A retrospective analysis of a large cohort. *Clin Rheumatol* 2014;33:549-53.
5. Zhang W, Doherty M, Bardin T, Barskova V, Guerne PA, Jansen TL, et al. European League Against Rheumatism recommendations for calcium pyrophosphate deposition. Part I: terminology and diagnosis. *Ann Rheum Dis* 2011;70:563-70.
6. Gruber M, Bodner G, Rath E, Supp G, Weber M, Schueller-Weidekamm C. Dual-energy computed tomography compared with ultrasound in the diagnosis of gout. *Rheumatology* 2014;53:173-9.
7. Thiele RG. Role of ultrasound and other advanced imaging in the diagnosis and management of gout. *Curr Rheumatol Rep*

- 2011;13:146-53.
8. Grassi W, Meenagh G, Pascual E, Filippucci E. "Crystal clear" — sonographic assessment of gout and calcium pyrophosphate deposition disease. *Semin Arthritis Rheum* 2006;36:197-202.
 9. Ottaviani S, Richette P, Allard A, Ora J, Bardin T. Ultrasonography in gout: a case-control study. *Clin Exp Rheumatol* 2012;30:499-504.
 10. Wright SA, Filippucci E, McVeigh C, Grey A, McCarron M, Grassi W, et al. High-resolution ultrasonography of the first metatarsal phalangeal joint in gout: a controlled study. *Ann Rheum Dis* 2007;66:859-64.
 11. Thiele RG, Schlesinger N. Diagnosis of gout by ultrasound. *Rheumatology* 2007;46:1116-21.
 12. Filippucci E, Riveros MG, Georgescu D, Salaffi F, Grassi W. Hyaline cartilage involvement in patients with gout and calcium pyrophosphate deposition disease. An ultrasound study. *Osteoarthritis Cartilage* 2009;17:178-81.
 13. Filippou G, Frediani B, Gallo A, Menza L, Falsetti P, Baldi F, et al. A "new" technique for the diagnosis of chondrocalcinosis of the knee: sensitivity and specificity of high-frequency ultrasonography. *Ann Rheum Dis* 2007;66:1126-8.
 14. Adinolfi A, Picerno V, Di Sabatino V, Bertoldi I, Galeazzi M, Frediani B, et al. Inquiry is fatal to certainty-is the ultrasonography double contour sign specific for uric acid-induced arthritis? *Arthritis Rheum* 2013;65:1952.
 15. Russell E, Checa A. Potential pitfalls in the diagnosis of crystal-induced arthritis and in the sonographic measurement of hyaline cartilage due to the presence of joint effusion. *J Clin Rheumatol* 2013;19:98-100.
 16. Frediani B, Filippou G, Falsetti P, Lorenzini S, Baldi F, Acciai C, et al. Diagnosis of calcium pyrophosphate dihydrate crystal deposition disease: ultrasonographic criteria proposed. *Ann Rheum Dis* 2005;64:638-40.
 17. Zhang W, Doherty M, Leeb BF, Alekseeva L, Arden NK, Bijlsma JW, et al. EULAR evidence based recommendations for the diagnosis of hand osteoarthritis - report of a task force of the EULAR Standing Committee for International Clinical Studies Including Therapeutics (ESCSIT). *Ann Rheum Dis* 2009;68:8-17.
 18. Howard RG, Pillinger MH, Gyftopoulos S, Thiele RG, Swearingen CJ, Samuels J. Reproducibility of musculoskeletal ultrasound for determining monosodium urate deposition: concordance between readers. *Arthritis Care Res* 2011;63:1456-62.
 19. Filippucci E, Scirè CA, Delle Sedie A, Iagnocco A, Riente L, Meenagh G, et al. Ultrasound imaging for the rheumatologist. XXV. Sonographic assessment of the knee in patients with gout and calcium pyrophosphate deposition disease. *Clin Exp Rheumatol* 2010;28:2-5.
 20. Roddy E, Menon A, Hall A, Datta P, Packham J. Polyarticular sonographic assessment of gout: a hospital-based cross-sectional study. *Joint Bone Spine* 2013;80:295-300.
 21. Peiteado D, De Miguel E, Villalba A, Ordóñez MC, Castillo C, Martín-Mola E. Value of a short four-joint ultrasound test for gout diagnosis: a pilot study. *Clin Exp Rheumatol* 2012;30:830-7.
 22. Lamers-Karnebeek FB, Van Riel PL, Jansen TL. Additive value for ultrasonographic signal in a screening algorithm for patients presenting with acute mono-/oligoarthritis in whom gout is suspected. *Clin Rheumatol* 2014;33:555-9.
 23. Scirè CA, Iagnocco A, Meenagh G, Riente L, Filippucci E, Delle Sedie A, et al. Ultrasound imaging for the rheumatologist XXXIII. Sonographic assessment of the foot in early arthritis patients. *Clin Exp Rheumatol* 2011;29:465-9.
 24. Andersen M, Ellegaard K, Hebsgaard JB, Christensen R, Torp-Pedersen S, Kvist PH, et al. Ultrasound colour Doppler is associated with synovial pathology in biopsies from hand joints in rheumatoid arthritis patients: a cross-sectional study. *Ann Rheum Dis* 2014;73:678-83.
 25. Kawashiri SY, Suzuki T, Nakashima Y, Horai Y, Okada A, Nishino A, et al. Synovial inflammation assessed by ultrasonography correlates with MRI-proven osteitis in patients with rheumatoid arthritis. *Rheumatology* 2014;53:1452-6.
 26. Grassi W, Filippucci E, Farina A, Salaffi F, Cervini C. Ultrasonography in the evaluation of bone erosions. *Ann Rheum Dis* 2001;60:98-103.