

# Percutaneous Transluminal Angioplasty for Symptomatic Pulmonary Stenosis in Takayasu Arteritis

Hui Dong, Xiongjing Jiang, Meng Peng, Yubao Zou, Ting Guan, Huimin Zhang, Lei Song, Haiying Wu, Yuejin Yang, and Runlin Gao

**ABSTRACT. Objective.** The aim of this study was to evaluate the safety and efficacy of percutaneous transluminal angioplasty (PTA) for symptomatic pulmonary stenosis in Takayasu arteritis (TA).

**Methods.** From January 2009 to December 2012, clinical data of 14 patients [mean age  $33.9 \pm 9.3$  yrs; 11 patients female (78.6%)] with symptomatic pulmonary stenosis in TA underwent PTA and were analyzed prospectively.

**Results.** PTA was successfully performed in 22 lesions of 14 patients. Among those lesions, 18 were treated by PTA alone while the others were treated with stent implantation. Three patients (21.4%) had reperfusion pulmonary injury; 2 patients recovered completely while the other died of respiratory failure 3 days after the procedure. Mean pulmonary arterial pressure (PAP) decreased from  $53.4 \pm 15.8$  mmHg to  $38.4 \pm 12.7$  mmHg immediately after intervention ( $p < 0.001$ ). After an average of 29 months of followup, the New York Heart Association functional class and 6-min walking distances improved while mean PAP measured by echocardiography decreased significantly (compared with baseline, all  $p < 0.01$ ). One patient died of severe pulmonary infection and cardiac shock at 28 months after the procedure.

**Conclusion.** The study showed that PTA improved subjective symptoms and objective variables of the patients with symptomatic pulmonary stenosis in TA, with an acceptable mortality. PTA may be a promising therapeutic strategy for symptomatic pulmonary stenosis in TA. (J Rheumatol First Release Aug 15 2014; doi:10.3899/jrheum.131007)

*Key Indexing Terms:*

PERCUTANEOUS TRANSLUMINAL ANGIOPLASTY  
PULMONARY STENOSIS  
TAKAYASU ARTERITIS

Takayasu arteritis (TA) is a chronic, nonspecific inflammatory disease that mainly produces stenosis and aneurysmal dilation of the aorta and its branches<sup>1,2</sup>. The pulmonary arteries could also be involved, with a prevalence of 44–86%<sup>3,4</sup>. Delayed diagnosis was usually made for the absence of typical symptoms of pulmonary artery involvement. However, when progressive dyspnea, fatigue, and/or bilateral leg edema occurred as a late clinical manifestation of pulmonary artery hypertension and/or right heart failure, medical therapy alone was not effective. In this phase, pulmonary revascularization is essential to restore blood flow of pulmonary arteries, decrease pulmonary

artery pressure, improve right ventricular function, and relieve clinical symptoms.

Surgical procedures have been reported in a few cases, but the characteristics of multiple vessel involvement and frequent progression and serious complications including anastomotic site aneurysms, graft occlusion, and death, have precluded the widespread use of reconstructive surgery<sup>5,6</sup>. Currently, some case reports indicated the feasibility of percutaneous transluminal angioplasty (PTA) for symptomatic pulmonary stenosis due to TA<sup>5,7,8,9</sup>. However, the data are quite limited and the clinical outcomes of this interventional strategy have not been investigated systematically in relatively large series. Therefore, we examined the safety and clinical efficacy of PTA for treatment of symptomatic pulmonary stenosis due to TA.

## MATERIALS AND METHODS

**Patient population.** Between January 2009 and December 2012, 194 patients were diagnosed with TA in our institution, of whom 88 patients (45.4%) had pulmonary artery involvement and 18 (9.3%) patients had isolated pulmonary artery involvement. From these, 14 consecutive patients with symptomatic pulmonary stenosis in TA scheduled to undergo PTA were enrolled. TA was usually diagnosed according to the American College of Rheumatology 1990 criteria<sup>1</sup>. With regard to isolated pulmonary artery involvement, the diagnosis was made according to the following points: (1) onset age was young, especially  $\leq 40$  years; (2) inflammatory

---

*From the Department of Cardiology, State Key Laboratory of Cardiovascular Disease, Fuwai Hospital, National Center for Cardiovascular Disease, Chinese Academy of Medical Sciences and Peking Union Medical College, Beijing, People's Republic of China.*

*H. Dong, MS; X. Jiang, MD; M. Peng, MS; Y. Zou, MD, PhD; T. Guan, BS; H. Zhang, MD; L. Song, MD, PhD; H. Wu, MD; Y. Yang, MD, FACC; R. Gao, MD, FACC.*

*Drs. Dong and Jiang contributed equally to this study.*

*Address correspondence to Dr. X. Jiang, Department of Cardiology, State Key Laboratory of Cardiovascular Disease, Fuwai Hospital, National Center for Cardiovascular Disease, Chinese Academy of Medical Sciences and Peking Union Medical College, 167 Beilishilu, Xicheng District, Beijing 100037, People's Republic of China. E-mail: jxj103@hotmail.com*  
*Accepted for publication April 17, 2014.*

---

Personal non-commercial use only. The Journal of Rheumatology Copyright © 2014. All rights reserved.

markers such as erythrocyte sedimentation rate (ESR) and C-reactive protein (CRP) were abnormal, while serological tests of connective disease were all negative; (3) pulmonary angiographic findings were consistent with TA, which presented with wall thickness and multiple narrowing, occlusion or dilation of the affected vessel lumen; and (4) other etiologies resulting in pulmonary stenosis were excluded. Indication for PTA was defined as pulmonary artery diameter reduction of > 70%, accompanied by severe pulmonary hypertension (systolic pulmonary artery pressure > 70 mmHg) and/or right ventricular dysfunction. Exclusion criteria included (1) intolerance to heparin and antiplatelet drugs; (2) allergy to contrast medium; (3) severe comorbidity, making patients unable to tolerate interventional therapy; (4) any other illness that impeded their ability to provide informed consent; and (5) life expectancy < 2 years. The study protocol was approved by the institutional review boards of Fuwai Hospital. Written informed consent was provided by each patient before the procedure.

**Interventional procedure and medical protocol.** All patients received aspirin (100 mg/day) and clopidogrel (75 mg/day) for at least 2 days before the procedure. The interventional procedures were all performed under local anesthesia through femoral vein access. Using the Seldinger technique, an 8F introducer sheath was positioned, and heparin (1 mg/kg) was administered. A 5F pigtail diagnostic catheter was introduced into the main pulmonary artery coming from the iliac vein, inferior vena cava, right atrium, and right ventricle in sequence, over a 0.035-inch HiWire angled hydrophilic guidewire (Cook Medical). Pulmonary lesions and hemodynamics were obtained first to determine treatment strategy. Then the pigtail catheter was dropped out while the hydrophilic guidewire was maintained in the pulmonary artery. A guiding catheter 8F MPA1 (Cordis) was inserted into the pulmonary artery over the hydrophilic guidewire. The lesion was predilated by graded undersized balloons with the maximal size  $\leq$  90% of the original size of the vessel diameter. The procedural success of PTA was defined as < 50% residual stenosis. When dissection and/or  $\geq$  50% residual stenosis occurred, the self-expandable stents were implanted, including Maris (Invatec) and Protégé (Ev3). If needed, the lesion was postdilated to achieve a residual stenosis < 30% after stent implantation. Other target lesions were all treated according to this protocol.

Reperfusion pulmonary injury was defined as chest radiographic opacity in intervention-related pulmonary segments and worsening of hypoxemia, with or without hemoptysis. If hemoptysis related to reperfusion pulmonary injury occurred, the patients were given nucleoprotamine to neutralize heparin and elevated concentrations of oxygen administered through an oxygen mask. The related arteries were compressed by balloon with low pressure for 3–5 min repeatedly until hemoptysis stopped.

Pulmonary arterial pressure (PAP) was measured again by the pigtail catheter immediately after intervention. Then all patients were transferred to the intensive care unit for careful hemodynamic monitoring and vigilant observation of clinical symptoms for 24 h or more. After the procedure, aspirin and clopidogrel were continued for 1 month for those who underwent PTA alone, and for 3–6 months for those with a stent. Glucocorticoids and immunosuppressive agents were administered during the perioperative period and at followup.

**Followup.** Telephone or clinic interviews were conducted every 6 months after the procedure by a dedicated research coordinator. Echocardiography, arterial blood gas analysis, New York Heart Association (NYHA) functional class, 6-min walk distance (6MWD), and inflammatory factors were examined. All patients were required to undergo computerized tomographic (CT) pulmonary angiography at 6 months after the procedure. Repeat CT pulmonary angiography was advised if any patient had recurrent clinical symptoms after 6 months.

**Statistical analysis.** Continuous variables were the mean  $\pm$  SD, while categorical data were given as counts and percentages. Differences between variables measured before and immediately after the procedure were tested by the paired t test. The NYHA functional class is expressed as the median and number of patients in each class, and changes in NYHA functional class were evaluated using the Wilcoxon signed-rank test. For assessing the

differences among before, after, and followup data, variables were analyzed by linear mixed modeling. All analyses were performed using the software SPSS 17.0 (SPSS Inc.). All probability values were 2-sided, and a p value < 0.05 was considered to indicate statistical significance.

## RESULTS

**Baseline patient characteristics.** The patients were 17–48 (33.9  $\pm$  9.3) years old; 11 patients (78.6%) were female. Disease duration (time between onset of symptoms to interventional therapy) was 47.1  $\pm$  36.8 months. In 8 patients, symptoms were accompanied by involvement of the aorta and its branches, while the remaining patients had only isolated pulmonary stenosis. Exertional dyspnea appeared in all 14 patients, and bilateral leg edema in 8 patients (57.1%). A classification of NYHA functional class III was found in 8 patients (57.1%), and class IV in the other 6 (42.9%; Table 1). All patients had increased ESR and CRP in the course of TA. Because of the proper administration of antiinflammatory agents in other institutions, 7 patients had normal inflammatory markers when they first came to our institution. The other 7 patients with increased ESR and/or CRP were administered glucocorticoids for at least 2 months to normalize inflammatory markers. All 14 patients had normal ESR and CRP when procedures were performed.

**Procedural characteristics.** PTA was successfully performed in 22 lesions of 14 patients, with the reduction of angiographic stenosis from 83.4  $\pm$  6.8% to 11.1  $\pm$  5.7%; and the increase of lesion diameter from 2.6  $\pm$  1.0 mm to 7.4  $\pm$  2.6 (both p < 0.001). Among these, 18 lesions were treated by PTA alone; and the maximal diameters of angioplasty balloons in 22 lesions were 5–10 mm (7.5 mm  $\pm$  1.6). The

*Table 1.* Baseline patient characteristics. Continuous variables are expressed as mean  $\pm$  SD, and categorical data are given as counts and percentages.

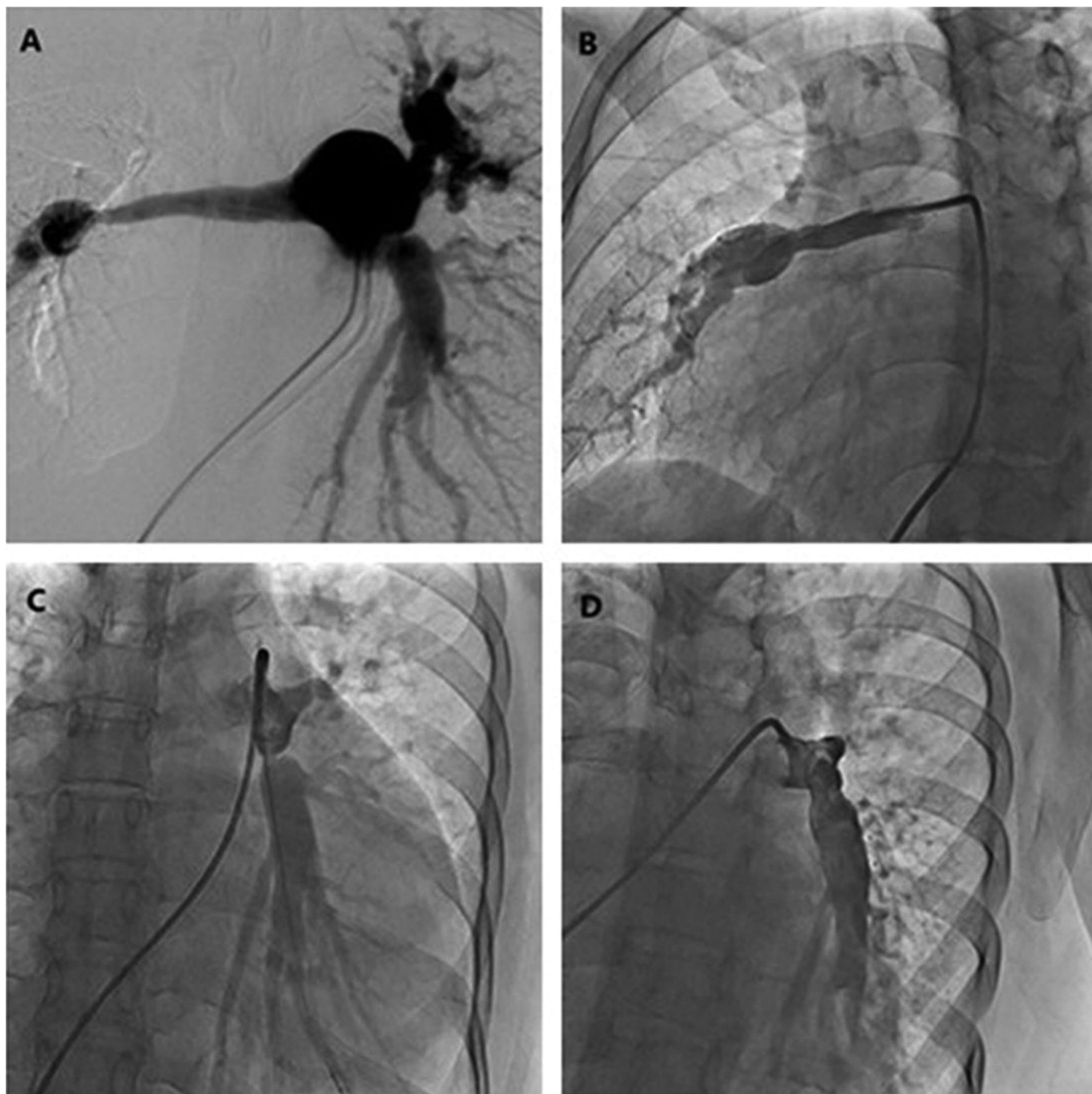
Characteristics	Results
Age, yrs	33.9 $\pm$ 9.3
Female, n (%)	11 (78.6)
Exertional dyspnea, n (%)	14 (100.0)
Bilateral leg edema, n (%)	8 (57.1)
The history of tuberculosis infection, n (%)	3 (21.4)
The history of hemoptysis, n (%)	4 (28.6)
NYHA functional class, n (%)	
III	8 (57.1)
IV	6 (42.9)
ESR, mm/h	5.5 $\pm$ 4.8
CRP, mg/l	5.7 $\pm$ 4.7
hsCRP, mg/l	5.1 $\pm$ 4.4
Serum creatine, $\mu$ mol/l	73.7 $\pm$ 22.4
NT-proBNP, fmol/ml	2402.9 $\pm$ 2010.6
Big-ET, fmol/ml	1.0 $\pm$ 0.5
D-dimer, $\mu$ g/ml	0.4 $\pm$ 0.3

NYHA: New York Heart Association; ESR: erythrocyte sedimentation rate; CRP: C-reactive protein; hsCRP: high-sensitivity C-reactive protein; NT-proBNP: N-terminal pro-brain natriuretic peptide; Big-ET: big endothelin.

other 4 lesions were treated with self-expandable stent implantation; stent type included Maris 12.0 × 60 mm, Protégé 12.0 × 60 mm, Protégé 10.0 × 30 mm, and Protégé 12.0 × 30 mm (Figure 1). Compared with preintervention, systolic and mean arterial pressure were significantly improved immediately after intervention (systolic PAP, 74.7 ± 14.1 vs 103.9 ± 15.9 mm Hg; mean PAP, 38.4 ± 12.7 vs 53.4 ± 15.8 mm Hg, respectively; both  $p < 0.01$ ). Three patients (21.4%) had reperfusion pulmonary injury during the perioperative period. Hemoptysis related to reperfusion pulmonary injury occurred in 2 patients during the procedure and the 2 patients recovered completely after active treatment. The other patient died of severe reper-

fusion pulmonary injury and type I respiratory failure on the third day after the procedure. No other adverse events occurred in the perioperative period.

*Followup.* After an average of 29 months of followup (range, 3 to 50 mos), NYHA functional class, 6MWD, arterial oxygen saturation, and arterial partial pressure of oxygen improved while systolic and mean PAP measured by echocardiography decreased (compared with preintervention, all  $p < 0.01$ , compared with postintervention, all  $p > 0.05$ ; Figure 2 and Table 2). Moreover, left ventricular diastolic diameter was slightly increased and right ventricular diameter was slightly decreased compared with baseline values, but the differences were not statistically



*Figure 1.* Representative angiography of percutaneous transluminal angioplasty (PTA). (A) Right pulmonary angiogram before PTA; (B) Right pulmonary angiogram after PTA; (C) Left pulmonary angiogram before stent implantation; (D) Left pulmonary angiogram after stent implantation. After the procedure, the systolic pulmonary artery pressure was decreased from 123 mmHg to 89 mmHg, and mean pulmonary artery pressure from 60 mmHg to 42 mmHg.

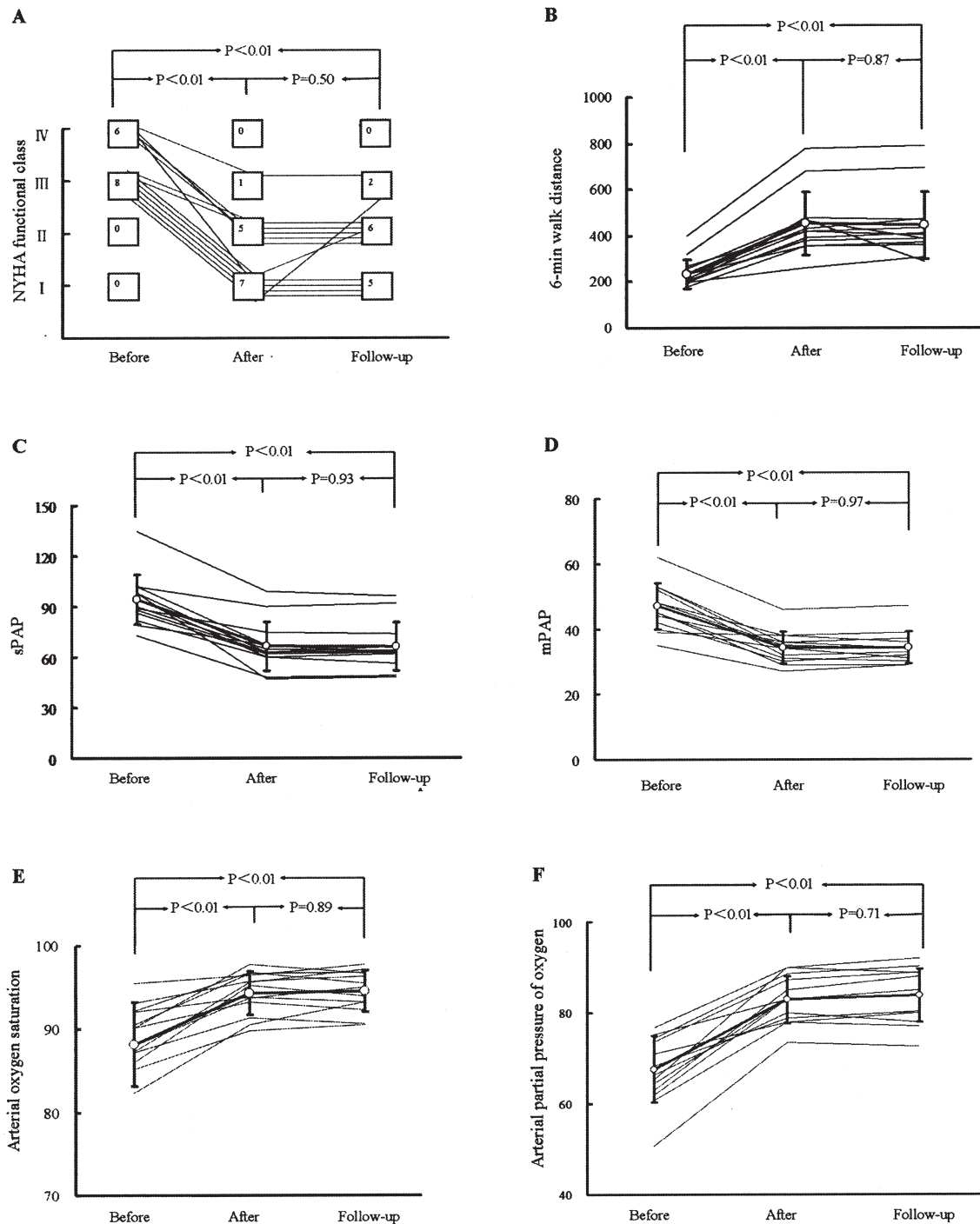


Figure 2. Change in variables after percutaneous transluminal angioplasty. Variables before the procedure (before; n = 14), after the procedure (after; n = 13), and at followup (followup; n = 13) were compared. These measures were significantly improved immediately after the procedure: A. New York Heart Association (NYHA) functional class; B. 6-min walk distance; C. systolic pulmonary arterial pressure (sPAP) measured by echocardiography; D. mean pulmonary arterial pressure (mPAP) measured by echocardiography; E. arterial oxygen saturation; and F. arterial partial pressure of oxygen. Improvements were maintained at followup.

significant (both  $p > 0.05$ ; Table 2). At 6 months after the procedure, 11 patients underwent CT pulmonary angiography, and there were no findings of restenosis in

PTA-related pulmonary arteries and no new lesions in other pulmonary arteries (Figure 3). One patient had a recurrence of dyspnea and NYHA functional class III at 16 months. She

Table 2. Subjective symptoms and objective variables of preintervention, postintervention, and followup. Values other than NYHA functional class are expressed as mean  $\pm$  SD. NYHA functional class is presented as the median and number of patients in each class.

	Preintervention, n = 14	Postintervention, n = 13	Followup, n = 13
NYHA functional class (I/II/III/IV)	3 (0/8/6)	1 (7/5/1/0)*	2 (5/6/2/0)†
6-min walk distance, m	232.3 $\pm$ 63.4	452.9 $\pm$ 137.7*	445.0 $\pm$ 143.7†
Echocardiography			
LVDD, mm	37.9 $\pm$ 4.0	39.3 $\pm$ 5.1	41.7 $\pm$ 6.0
LVEF, %	63.7 $\pm$ 7.7	62.4 $\pm$ 5.3	64.5 $\pm$ 8.9
sPAP, mmHg	94.2 $\pm$ 14.8	66.6 $\pm$ 14.5*	66.1 $\pm$ 14.2†
mPAP, mmHg	47.0 $\pm$ 7.1	34.3 $\pm$ 4.9*	34.2 $\pm$ 4.9†
RVD, mm	37.9 $\pm$ 5.5	34.8 $\pm$ 5.2	34.6 $\pm$ 5.2
Arterial blood gas analysis			
Arterial oxygen saturation, %	88.2 $\pm$ 5.0	94.3 $\pm$ 2.6*	94.5 $\pm$ 2.5†
Arterial partial pressure of oxygen, mmHg	67.6 $\pm$ 7.3	82.9 $\pm$ 5.1*	83.8 $\pm$ 5.9†
Arterial partial pressure of carbon dioxide, mmHg	35.7 $\pm$ 3.4	37.5 $\pm$ 3.2	36.9 $\pm$ 3.5

\*Compared with preintervention,  $p < 0.01$ ; †Compared with preintervention,  $p < 0.01$  and compared with postintervention,  $p > 0.05$ . NYHA: New York Heart Association; LVDD: left ventricular end diastolic diameter; LVEF: left ventricular ejection fraction; sPAP: systolic pulmonary arterial pressure measured by echocardiography; mPAP: mean pulmonary arterial pressure measured by echocardiography; RVD: right ventricular diameter.

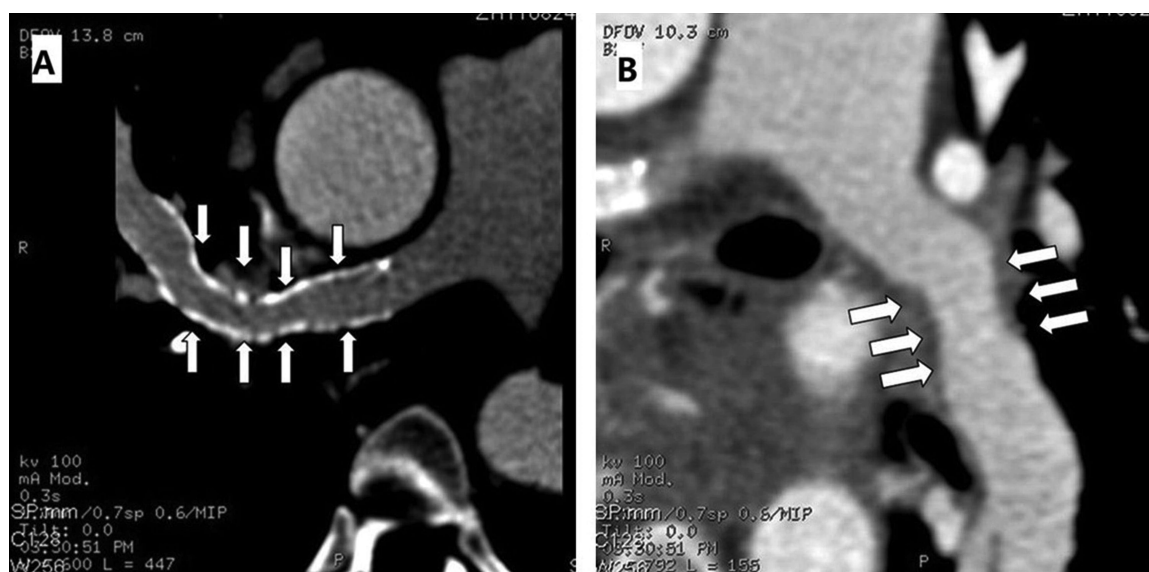


Figure 3. Representative computerized tomographic pulmonary angiography. (A) and (B) indicate no obvious restenosis at 6 months' followup after percutaneous transluminal angioplasty (arrow).

refused to undergo CT angiography and declined to receive antiinflammatory therapy because of her persistent concern about the side effects of antiinflammatory agents. She died of severe pulmonary infection and cardiac shock at 28 months postintervention and 1 year after discontinuing anti-inflammatory therapy. There was no other adverse event reported at followup.

## DISCUSSION

With recent advances in percutaneous interventions, PTA for stenotic lesions of the aorta and its branches in TA have been reported to show excellent procedural and longterm results compared with surgical procedures<sup>10</sup>. However, this form of therapy has been reported in few cases with pulmonary artery involvement. Li, *et al* reported a patient with sympto-

matic isolated pulmonary stenosis due to TA<sup>8</sup>. Two self-expanding nickel-titanium stents and a rapamycin-eluting stent were implanted into 2 pulmonary lesions, respectively. The exercise tolerance and clinical symptoms were relieved markedly. In our previous 4 cases<sup>7</sup>, 3 underwent stent implantation and the other received PTA alone. The NYHA functional class and PAP were improved significantly after the procedure. However, until now, there were only 8 reported cases describing in detail PTA for patients with pulmonary stenosis in TA, including 4 performed in our institution<sup>5,7,8,9,11</sup>. To the best of our knowledge, the present study represents the largest consecutive series and longest followup of patients with symptomatic pulmonary stenosis due to TA undergoing PTA. Our results showed that angiographic stenosis and pulmonary artery pressure decreased immediately after intervention. After an average of 29 months' followup, subjective symptoms and pulmonary hemodynamics both improved significantly. Thus, our results corroborate findings from our own previous cases<sup>7</sup>, as well as those reported from others<sup>5,8,9,11</sup> and indicate that PTA is a safe and effective treatment strategy for patients with symptomatic pulmonary stenosis owing to TA.

Additionally, given the uniqueness of pulmonary hemodynamics and the distinct mechanism of restenosis between TA and atherosclerosis, these 3 points are crucial to prevent reperfusion pulmonary injury and to decrease related adverse events: (1) broadening of the criteria for procedural success. TA is an inflammatory disease and the affected vessels are rigid and fragile. Excessive balloon dilation could result in dissection, even rupture of pulmonary arteries and reperfusion injury of the affected pulmonary segments. Indeed, the incidence of reperfusion pulmonary injury in our series was lower than that reported in other studies with strict demands for procedural success (mean PAP < 30 mmHg)<sup>12,13</sup>; (2) selecting the proper stent. Considering certain characteristics of self-expandable stents (including good flexibility, high-vessel wall surface coverage, and persistent expansion), which can be introduced into the lesions easily, continue to expand the lumen after the procedure, and maintain longterm vessel patency, we selected the self-expandable stent in all 4 lesions with stent implantation<sup>14</sup>; and (3) finally and most importantly, vigilant inflammatory control in perioperative and longterm followup. The mechanism of restenosis after PTA in TA is mainly attributed to vessel inflammation rather than the inflammatory reaction that was the leading cause or atherosclerosis. Thus, despite the use of drug-eluting stents, the incidence of restenosis was high if the vessel inflammation was not effectively controlled<sup>8</sup>. Some previous studies also indicated that the restenosis rate was lower when PTA was performed for stenotic lesions of the aorta and its branches caused by TA at the stable stage and followed by anti-inflammatory therapy<sup>10,15</sup>. In our study, all patients were

required to receive antiinflammatory agents to control the vessel inflammation perioperatively and during followup. Unfortunately, 1 patient discontinued antiinflammatory therapy and died of severe pulmonary infection and cardiac shock. Thus, we suggest that vigilant antiinflammatory therapy is mandatory to prevent restenosis and reduce related adverse events.

There are several limitations to this study. Like the majority of previous studies about isolated pulmonary artery involvement in TA<sup>8,16</sup>, isolated pulmonary TA was recognized mainly according to clinical features, laboratory data, and angiographic findings. Thus, we cannot exclude other origins of pulmonary stenosis because of the lack of histological examinations in our 6 cases with isolated pulmonary artery involvement. The variables of pulmonary hemodynamics during the procedure included only systolic and mean PAP; other characteristics including right atrial pressure, cardiac output, and pulmonary capillary wedge pressure were not measured. Moreover, hemodynamic variables were evaluated by echocardiography rather than right heart catheterization at followup. Although pulmonary artery pressure measured by echocardiography provides comparable information to that measured by right heart catheterization<sup>17,18</sup>, right heart catheterization is the "gold standard." Therefore, right heart catheterization with more hemodynamic variables would demonstrate the clinical efficacy of PTA for treatment of pulmonary stenosis in TA.

PTA improved subjective symptoms and objective variables immediately after the intervention and improvement was maintained for 29 months of followup in patients with symptomatic pulmonary stenosis in TA, with an acceptable mortality. PTA may be a promising therapeutic strategy for pulmonary stenosis in TA.

## REFERENCES

1. Arend WP, Michel BA, Bloch DA, Hunder GG, Calabrese LH, Edworthy SM, et al. The American College of Rheumatology 1990 criteria for the classification of Takayasu arteritis. *Arthritis Rheum* 1990;33:1129-32.
2. Mukhtyar C, Guillevin L, Cid MC, Dasgupta B, de Groot K, Gross W, et al. EULAR recommendations for the management of large vessel vasculitis. *Ann Rheum Dis* 2009;68:318-23.
3. Castellani M, Vanoli M, Cali G, Bacchiani G, Origgi L, Reschini E, et al. Ventilation-perfusion lung scan for the detection of pulmonary involvement in Takayasu's arteritis. *Eur J Nucl Med* 2001; 28:1801-5.
4. Lupi HE, Sanchez TG, Horwitz S, Gutierrez E. Pulmonary artery involvement in Takayasu's arteritis. *Chest* 1975;67:69-74.
5. Tyagi S, Mehta V, Kashyap R, Kaul UA. Endovascular stent implantation for severe pulmonary artery stenosis in aortoarteritis (Takayasu's arteritis). *Catheter Cardiovasc Interv* 2004;61:281-5.
6. Nakajima N, Masuda M, Imamaki M, Ishida A, Tanabe N, Kuriyama T. A case of pulmonary artery bypass surgery for a patient with isolated Takayasu pulmonary arteritis and a review of the literature. *Ann Thorac Cardiovasc Surg* 2007;13:267-71.
7. Luo Q, Zhang HL, Liu ZH, Xiong CM, Ni XH. Percutaneous transluminal angioplasty and stenting for pulmonary stenosis due to Takayasu's arteritis: clinical outcome and four-year follow-up. *Clin*

- Cardiol 2009;32:639-43.
8. Li D, Ma S, Li G, Chen J, Tang B, Zhang X, et al. Endovascular stent implantation for isolated pulmonary arterial stenosis caused by Takayasu's arteritis. *Clin Res Cardiol* 2010;99:573-5.
  9. Garcia-Olivé I, Prats Bardají MS, Calvo Pascual S, Sánchez Berenguer D, Valverde Forcada E, Ruiz-Manzano J. [Severe pulmonary hypertension and Takayasu arteritis.] [Article in Spanish] *Arch Bronconeumol* 2008;44:170-2.
  10. Saadoun D, Lambert M, Mirault T, Resche-Rigon M, Koskas F, Cluzel P, et al. Retrospective analysis of surgery versus endovascular intervention in Takayasu arteritis: a multicenter experience. *Circulation* 2012;125:813-9.
  11. Tooru S, Jun N, Sosuke M, Haruo M, Atsuko S, Motohiro O. A case of Takayasu's arteritis treated by percutaneous transluminal angioplasty for the pulmonary artery stenosis. *Cardioangiology* 1999;45:77-81.
  12. Mizoguchi H, Ogawa A, Munemasa M, Mikouchi H, Ito H, Matsubara H. Refined balloon pulmonary angioplasty for inoperable patients with chronic thromboembolic pulmonary hypertension. *Circ Cardiovasc Interv* 2012;5:748-55.
  13. Sugimura K, Fukumoto Y, Satoh K, Nochioka K, Miura Y, Aoki T, et al. Percutaneous transluminal pulmonary angioplasty markedly improves pulmonary hemodynamics and long-term prognosis in patients with chronic thromboembolic pulmonary hypertension. *Circ J* 2012;76:485-8.
  14. Stoeckel D, Pelton A, Duering T. Self-expanding nitinol stents: material and design considerations. *Eur Radiol* 2004;14:292-301.
  15. Park MC, Lee SW, Park YB, Lee SK, Choi D, Shim WH. Post-interventional immunosuppressive treatment and vascular restenosis in Takayasu's arteritis. *Rheumatology* 2006;45:600-5.
  16. Fukuda Y, Shirai K, Takamiya Y, Nathan M, Mito T, Yamagi D, et al. Isolated pulmonary arterial stenosis caused by Takayasu's arteritis in an elderly male. *J Cardiol* 2008;51:196-200.
  17. Denton CP, Cailles JB, Phillips GD, Wells AU, Black CM, Bois RM. Comparison of Doppler echocardiography and right heart catheterization to assess pulmonary hypertension in systemic sclerosis. *Br J Rheumatol* 1997;36:239-43.
  18. Pyxaras SA, Pinamonti B, Barbati G, Santangelo S, Valentincic M, Cettolo F, et al. Echocardiographic evaluation of systolic and mean pulmonary artery pressure in the follow-up of patients with pulmonary hypertension. *Eur J Echocardiogr* 2011;12:696-701.