

Comparison of Labial Minor Salivary Gland Biopsies from Childhood Sjögren Syndrome and Age-matched Controls

Naoto Yokogawa, Scott M. Lieberman, Faizan Alawi, Sharon Bout-Tabaku, Marta Guttenberg, David D. Sherry, and Frederick B. Vivino

ABSTRACT. *Objective.* To determine an appropriate focus score cutoff for childhood Sjögren syndrome (SS). *Methods.* Labial salivary gland tissue from specimens from children with SS and age-matched controls was retrospectively identified and reviewed by a blinded oral pathologist. *Results.* The presence of any focal sialadenitis (focus score > 0 foci/4 mm²) was common among childhood SS samples but present in only 1 of 8 control samples. *Conclusion.* The presence of any focal lymphocytic sialadenitis in minor labial salivary gland tissue is suggestive of childhood SS and should be included in future childhood SS-specific diagnostic or classification criteria. (J Rheumatol First Release May 1 2014; doi:10.3899/jrheum.131511)

Key Indexing Terms:

SJÖGREN SYNDROME
MINOR SALIVARY GLANDS

PEDIATRICS

DIAGNOSIS
PATHOLOGY

Sjögren syndrome (SS) is a multiorgan autoimmune disease that causes progressive secretory dysfunction with subsequent ocular and oral complications along with potential for extraglandular organ damage. While the peak onset of SS is in the fifth decade of life, SS may occur in children^{1,2,3,4,5,6,7,8,9,10,11,12}. Given the lack of sensitive child-specific diagnostic criteria^{1,6}, the prevalence, prognosis, and optimal management of childhood SS are not currently known. A hallmark of SS diagnosis in adults is the focus score, based on histopathological evaluation of

inflammation within labial minor salivary gland (LSG) biopsy specimens^{13,14}. Histopathological evidence of typical focal lymphocytic sialadenitis (FLS) is also considered the gold standard in the diagnosis of childhood SS by some pediatric rheumatologists. In adults, a focus score ≥ 1 focus/4 mm² tissue is considered positive for SS. This cutoff is required to maintain specificity for SS based on the relatively high incidence of FLS (i.e., focus score > 0 foci/4 mm²) in non-SS LSG specimens¹⁵. Whether this cutoff is appropriate for use in children has not been evaluated to our knowledge, and studies of LSG samples from children without SS are lacking. Here we evaluate LSG biopsy specimens from children with childhood SS and non-SS controls to evaluate focus scoring that may indicate childhood SS and to propose a child-specific positive focus score for use in future diagnostic and classification criteria.

From the Department of Rheumatic Diseases, Tokyo Metropolitan Tama Medical Center, Tokyo, Japan; Stead Family Department of Pediatrics, Division of Rheumatology, Carver College of Medicine, University of Iowa, Iowa City, Iowa; Department of Dermatology, Division of Dermatopathology, and Division of Rheumatology, University of Pennsylvania, Philadelphia, Pennsylvania; Division of Rheumatology, Nationwide Children's Hospital and Department of Pediatrics, Ohio State University College of Medicine, Columbus, Ohio; Division of Anatomic Pathology, and the Division of Rheumatology, The Children's Hospital of Philadelphia, Philadelphia, Pennsylvania, USA.

N. Yokogawa, MD, Department of Rheumatic Diseases, Tokyo Metropolitan Tama Medical Center; S.M. Lieberman, MD, PhD, Stead Family Department of Pediatrics, Division of Rheumatology, Carver College of Medicine, University of Iowa; F. Alawi, DDS, Department of Dermatology, Division of Dermatopathology, University of Pennsylvania; S. Bout-Tabaku, MD, MSc, Division of Rheumatology, Nationwide Children's Hospital and Department of Pediatrics, Ohio State University College of Medicine; M. Guttenberg, MD, Division of Anatomic Pathology; D.D. Sherry, MD, Division of Rheumatology, The Children's Hospital of Philadelphia; F.B. Vivino, MD, MS, Division of Rheumatology, University of Pennsylvania.

Dr. Yokogawa and Dr. Lieberman contributed equally to this study.

Address correspondence to Dr. S.M. Lieberman, Stead Family Department of Pediatrics, Carver College of Medicine, University of Iowa, 500 Newton Road, 2191A ML, Iowa City, Iowa 52242, USA.

E-mail: scott-lieberman@uiowa.edu

Accepted for publication February 28, 2014.

MATERIALS AND METHODS

Patient selection. Medical records between 1998 and 2008 at The Children's Hospital of Philadelphia were retrospectively reviewed for children < 18 years old with a suspected diagnosis of SS (International Classification of Diseases, 9th ed. 710.2) for whom LSG tissue was available. Clinical presentation, serologies, objective tests for sicca, and histopathology were reviewed. Patients were included in the SS group if diagnosed with SS by a pediatric rheumatologist, followed for a minimum of 1 year with no subsequent alternate diagnosis to explain presenting symptoms, and positive for autoantibodies [anti-SSA, anti-SSB, and/or antinuclear antibody (ANA)]. Patients with other autoimmune diseases were included. Control subjects included children ages 4 to 18 years who had LSG tissue (collected between 1998 and 2009 at The Children's Hospital of Philadelphia) available for analysis and for whom diagnosis of SS was unlikely. These specimens were obtained either as part of the diagnostic examination for children initially suspected to have SS or as part of routine surgical procedures in children with orofacial anomalies. The study was in compliance with the Declaration of Helsinki and was

Personal non-commercial use only. The Journal of Rheumatology Copyright © 2014. All rights reserved.

approved by the Institutional Review Board at The Children's Hospital of Philadelphia.

LSG histopathological analysis. All available slides of LSG biopsies were de-identified and labeled with a numerical code. An oral pathologist reviewed all slides in a blinded fashion and documented the LSG histopathological findings, including (1) number of lobules, (2) total tissue surface area, (3) number of lymphocytic foci (aggregates \geq 50 mononuclear cells), and (4) number of nonfocus lymphocytic aggregates (aggregates $<$ 50 mononuclear cells).

Statistical analysis. Statistical analyses were performed with Prism version 6.02 (GraphPad Software). Fisher's exact test was used for contingency table analyses to compare categorical variables. The Mann-Whitney U test was used to compare continuous variables.

RESULTS

Patients and controls. LSG tissue was available from 17 children $<$ 18 years old with suspected SS. Two presented with parotitis but were later diagnosed with human immunodeficiency virus (HIV) and sarcoidosis. Another presented with sicca symptoms but was later diagnosed with immune dysregulation polyendocrinopathy enteropathy X-linked (IPEX) syndrome. These 3 children were included as non-SS controls. One child had $<$ 1 year followup and was excluded. Of the remaining 13 children with suspected SS, 11 had positive anti-SSA/B, 1 had positive ANA with negative anti-SSA/B, and 1 was negative for anti-SSA/B and ANA. The latter child was excluded from analysis because of lack of evidence of serologic autoimmunity, but was still suspected of having SS. Thus, 12 children were included in our childhood SS group (Table 1A). Of these 12 children, 5 presented with parotitis and positive anti-SSA \pm anti-SSB (SS1, SS4, SS5, SS7, SS11), which is the most common presentation of childhood SS^{1,2,4,5,6}. Two presented with neuromyelitis optica and positive anti-SSA \pm anti-SSB (SS10, SS12). Association of neuromyelitis optica

and SS has been described^{9,16,17} including the case of SS10⁹. One presented with meningoencephalitis and was noted to have parotid gland changes on magnetic resonance imaging, prompting the SS investigation (SS9). Two children presented with renal tubular acidosis (SS2, SS8), which has been described in childhood SS^{3,10}. Specifically, SS2 presented with periodic paralysis and positive anti-SSA/B, while SS8 had a complicated course with longstanding juvenile arthritis, uveitis, optic neuritis, and multiple dental caries before developing hypokalemic acidosis leading to subsequent investigations for SS¹⁰. One child was referred for investigation of microscopic hematuria and positive ANA and was found to have sicca symptoms and positive anti-SSA along with class II lupus nephritis (SS3). One child presented with arthralgias and was found to have sicca symptoms and positive anti-SSA/B (SS6). Two children had an additional autoimmune disease: SS3 was diagnosed with systemic lupus erythematosus and SS concomitantly; SS8 had longstanding juvenile arthritis prior to diagnosis of SS (Table 1A). Thus, these children represent true childhood SS cases.

Non-SS controls (Table 1B) included the 3 children initially suspected of having SS because of parotitis (nonSS1, nonSS2) or sicca symptoms (nonSS3), but who were later diagnosed with HIV, sarcoidosis, and IPEX, respectively, along with 5 children with lip anomalies prompting surgical intervention with subsequent tissue samples containing LSG tissue. Ages of patients with SS and non-SS controls were similar, with medians (ranges) of 12.6 years (4.2–16.2 yrs) and 12.9 years (4–17.2 yrs), respectively ($p = 0.9250$).

Histopathological analysis. H&E-stained sections of LSG tissue from patients with SS and age-matched non-SS controls were analyzed by bright field microscopy. Foci (\geq

Table 1A. Characteristics of patients with childhood Sjögren syndrome (SS).

Subject	Sex	Age, yrs		SSA/SSB	ANA Titer	Decreased Salivary Flow	Parotitis	Dry Mouth	Dry Eyes	Abnormal Schirmer Test	Extraglandular (whole course)*	Followup, yrs	Focus Score (no. / 4 mm ²)
		At Dx	At Biopsy										
SS1	F	14.5	14.9	SSA/SSB	1280	ND	Y	Y	Y	N	J	2	2.7
SS2	F	15.8	16.2	SSA/SSB	Pos	ND	N	Y	Y	ND	J, L, R	2	2.3
SS3 [§]	F	9.5	9.6	SSA	320	ND	N	N	Y	N	R	1	2.2
SS4	F	8.8	4.2	SSA	1280	ND	Y	Y	Y	Y	F, L, N, S	3	2
SS5	F	10.6	11.1	SSA/SSB	1280	ND	Y	N	N	ND		1	1.2
SS6	F	14.8	15.1	SSA/SSB	1280	ND	N	Y	N	N	H, J, L	1	1.2
SS7	F	13.4	13.5	SSA/SSB	1280	ND	Y	N	N	N	J, L	5	1.1
SS8 [§]	F	11	11.1	Neg	1280	Y	N	Y	Y	ND	J, N, R, S	7	1
SS9	F	11.9	12.1	SSA	1280	ND	Y	N(\rightarrow Y) [†]	N	ND	F, L, N, S	2	0.9
SS10	F	11.3	11.4	SSA/SSB	160	ND	N	N	N	ND	N, R	5	0.8
SS11	M	14.5	15.4	SSA/SSB	160	Y	Y	Y	N	N		3	0.5
SS12	F	12.8	13	SSA/SSB	1280	ND	N	N	N	N	J, N	2	0.4

[†] N(\rightarrow Y), developed after diagnosis. [§] Additional autoimmune disease diagnosis: systemic lupus erythematosus (SS3), juvenile idiopathic arthritis (SS8). Dx: diagnosis; ANA: antinuclear antibody; N: no/absent; ND: not done; Neg: negative; Pos: positive; Y: yes/present. * F: fever; H: hematological; J: arthritis/arthralgias; L: lymphadenopathy; N: neurological; R: nephrological; S: rash.

Table 1B. Characteristics of non-childhood Sjögren syndrome controls.

Subject	Sex	Age, yrs		Diagnosis	Focus Score (no. / 4 mm ²)
		At Diagnosis	At Biopsy		
NonSS1	M	Control	17.2	Parotitis, suspected SS later diagnosed with HIV	0
NonSS2	M	Control	12.2	Parotitis, suspected SS later diagnosed with sarcoidosis	0
NonSS3	F	Control	6.3	Dry mouth, suspected SS later diagnosed with IPEX	0
NonSS4	F	Control	15.9	Excision of lip pits	0.7
NonSS5	F	Control	16.2	Hemifacial microsomia, excision of malformation	0
NonSS6	F	Control	13.6	Cleft palate syndrome, excision of residual mucosa	0
NonSS7	M	Control	4	Excision of lip pits	0
NonSS8	F	Control	4.1	Excision of lip pits	0

IPEX: immune dysregulation polyendocrinopathy enteropathy; X-linked syndrome N: no/absent; ND: not done; Neg: negative; HIV: human immunodeficiency virus.

50 mononuclear cells with lymphocyte predominance) present in SS samples were in the typical periductal and perivascular distribution as described in adult and pediatric LSG tissue samples (Figure 1). Foci were counted and focus scores calculated (no. foci per 4 mm² tissue; Table 1). Not surprisingly, focus scores were higher in the SS group compared to non-SS controls; however, only 8 of 12 SS samples contained focus scores ≥ 1 focus/4 mm², the standard cutoff for SS in adults (Table 2). This cutoff is required in part because of the relatively high incidence of foci within LSG samples from adults without SS¹⁵. In contrast, only 1 of our LSG samples from non-SS control children had any foci present, and this sample had only 1 focus (focus score of 0.7 foci/4 mm²). All 12 of our SS samples had at least 1 focus present (i.e., focus scores > 0 foci/4 mm²). All SS samples and 6 of 8 non-SS control samples contained nonfocus lymphocytic aggregates (aggregates of < 50 mononuclear cells).

In contrast to adult SS¹⁸, the phenotypic and serological features of childhood SS did not differ between the childhood SS patients with focus score ≥ 1 focus/4 mm² and those with focus score < 1 focus/4 mm² (Table 1, and not shown).

DISCUSSION

The LSG biopsy has been a pivotal diagnostic component of SS for over 50 years. In SS, the typical histopathological findings consist of foci of mononuclear cells, with lymphocyte predominance, in a periductal and/or periacinar distribution. In adult SS, a focus score of ≥ 1 focus/4 mm² was strongly associated with the main phenotypic features of SS, including positive anti-SSA/SSB and rheumatoid factor (RF), high ANA titers and IgG concentration, presence of keratoconjunctivitis sicca, and decreased unstimulated whole salivary flow, but not with the symptoms of dry mouth and dry eyes¹⁸. Whether this cutoff is similarly appropriate for use in diagnosing childhood SS has not previously been evaluated, to our knowledge. FLS is not uncommon in adults, and FLS with a focus score > 1 focus/4 mm² may occur in up to 15% of otherwise healthy adults¹⁵;

however, only 1 of our non-SS control LSG samples had a focus. Thus, FLS is not as common in children as it is in adults without SS. In contrast, all of our childhood SS LSG samples exhibited FLS. These data are consistent with other studies of childhood SS LSG biopsies, including 1 study⁸ in which all 8 specimens had lymphocytic infiltrates whereas only 5 of 8 had focus scores ≥ 1 focus/4 mm². Similarly, another study¹¹ reported 20 of 21 children showed at least 1 pathological feature of SS on LSG biopsy, but only 11 (55%) had focus scores > 1 focus/4 mm². Whether the pathological lymphocytic infiltrates in the specimens with focus scores < 1 focus/4 mm² in these studies were foci or nonfocus lymphocytic aggregates, however, was not stated. Another childhood SS study suggested an important role for parotid biopsies in suspected childhood SS, given that only 2 of 6 LSG samples were “consistent with SS”⁷. They did not, however, note whether the lack of consistency was due to focus score < 1 focus/4 mm² or rather, lack of any foci. The remaining 4 children had parotid biopsies consistent with SS⁷. Thus, in some children, parotid biopsies may be warranted.

SS is one of the most common autoimmune rheumatic diseases in adults. Prevalence of childhood SS, however, is not well defined, partly because of inadequate classification criteria^{1,6}. Regardless, childhood SS can cause significant organ damage and complications^{1,3,9,10,12}. Earlier diagnosis could therefore facilitate more meaningful interventions and potentially prevent a lifetime of SS-related morbidities. Whether the increased risk for malignancy is similar in childhood SS as in adult SS cannot be assessed without first defining childhood SS. In our cohort, only 4 of the 12 patients (33.3%) with childhood SS met the American-European Consensus Group (AECG) criteria¹³ even when modified to include parotitis, the most common presenting symptom in childhood SS^{1,2,4,5,6}. Seven of the 12 (58.3%) met the American College of Rheumatology (ACR) criteria for SS¹⁴ based on positive serologies and positive histopathology (i.e., focus score ≥ 1 focus/4 mm²). Ocular staining scores included in the ACR criteria were not reported for any of these patients and are not routinely reported for children in general, so full determination of

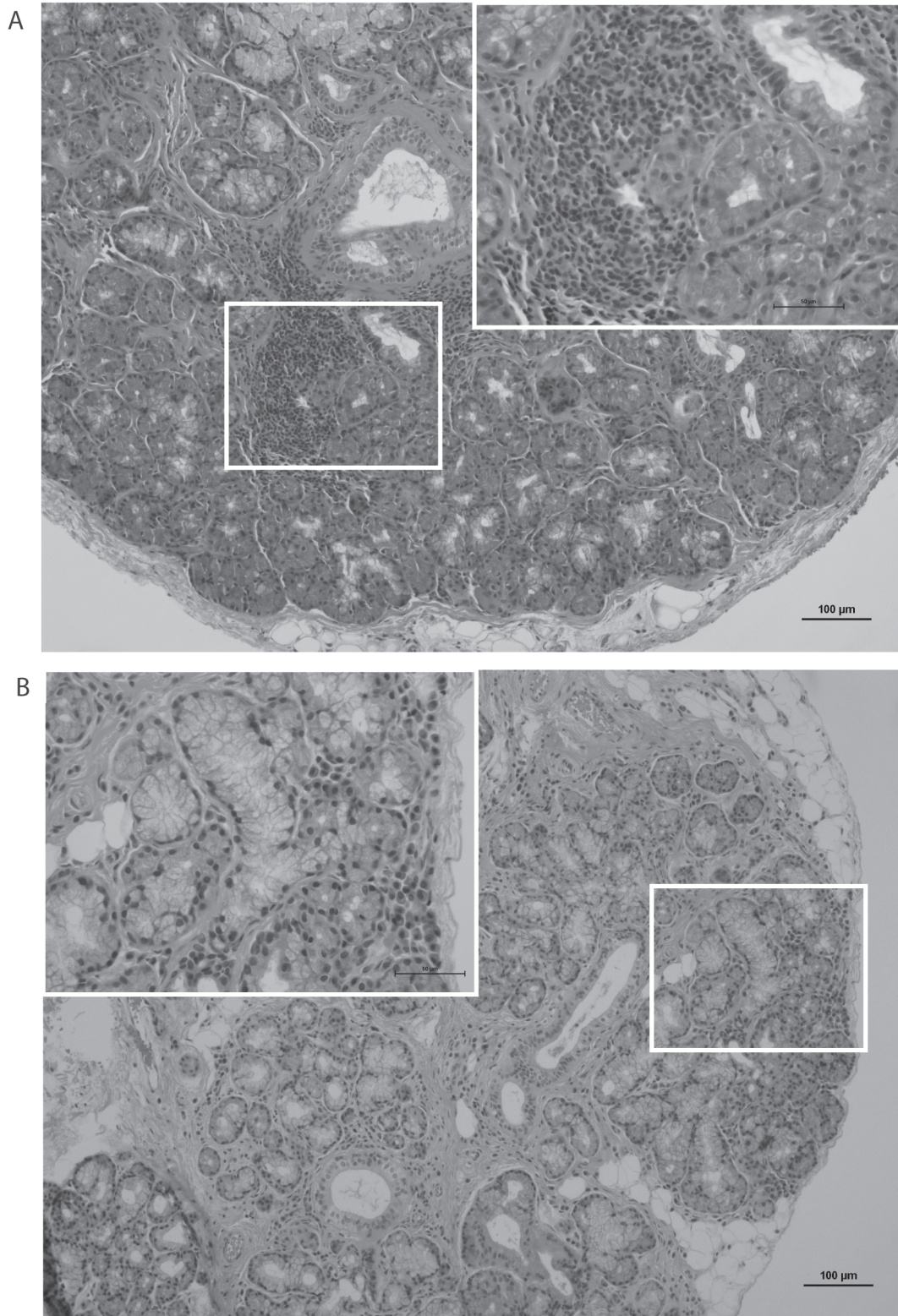


Figure 1. Characteristic labial minor salivary gland (LSG) histopathology in childhood Sjögren syndrome (SS) and age-matched non-SS controls. Representative H&E-stained sections of LSG from (A) an 11.4-year-old female with SS (SS10 in Table 1) demonstrating mononuclear focus in typical periductal and perivascular distribution with normal surrounding acinar tissue, and (B) a 13.6-year-old child with cleft palate (nonSS6) demonstrating normal tissue. Original magnification 10 × (inset, 40 ×). Bars are 100 μm (inset, 50 μm).

Table 2. Histopathological characteristics of the LSG biopsy in childhood SS and age-matched controls.

Characteristics	SS, n = 12	non-SS, n = 8	p
FS (n/4 mm ²), median (range)	1.15 (0.4–2.7)	0 (0–0.7)	< 0.0001 [†]
NFLAS (n/4 mm ²), median (range)	0.47 (0.22–13.71)	0.84 (0–4)	0.955 [†]
FS ≥ 1 focus/4 mm ² , n (%)	8 (66.7)	0 (0)	0.005 [‡]
FS > 0 foci/4 mm ² , n (%)	12 (100)	1 (12.5)	0.0001 [‡]
NFLA present, n (%)	12 (100)	6 (75)	0.147 [‡]

[†] Mann-Whitney U test. [‡] Fisher's exact test. FS: focus score; LSG: labial salivary gland; NFLA: nonfocus lymphocytic aggregates; NFLAS: NFLA score; SS: Sjögren syndrome.

validity of the ACR criteria in our cohort could not be performed. Of note, if our proposed child-specific positive focus score definition (i.e., focus score > 0 foci/4 mm²) were used in each criteria, the child-modified ACR criteria would be met by 11 of 12 (91.6%) of our cohort, whereas only 5 of 12 would meet the child-modified AECG criteria. The only child (SS8) who would not meet child-modified ACR criteria was ANA-positive but RF-negative and SSA/B-negative, although she had documented decreased salivary flow.

Caveats to our study include the relatively small size of the patient and control samples and the retrospective nature of subject identification. A larger prospective study including control groups with other inflammatory diseases would be ideal but may not be ethically appropriate without clinical basis for obtaining an LSG biopsy. Additional childhood SS and control cases should be analyzed to determine whether focus score > 0 foci/4 mm² is both adequate and optimal. Ultimately, to advance our ability to diagnose and study childhood SS, an international childhood SS working group should be established.

FLS is uncommon in the LSG of children without SS, and any FLS (focus score > 0 foci/4 mm²) should support a diagnosis of childhood SS in the right clinical setting. Both increasing awareness of childhood SS and establishing more sensitive criteria will facilitate earlier diagnosis, allowing for more optimal management. This will also allow for future studies to assess prevalence of childhood SS along with longterm outcomes such as the incidence of SS-associated lymphoma.

ACKNOWLEDGMENT

We thank Juan P. Palazzo, MD (Thomas Jefferson University), and Lytia Fischer for assistance with collection of clinical data, and Frank Pessler, MD, PhD, for initiating our childhood SS studies.

REFERENCES

- Bartunkova J, Sediva A, Vencovsky J, Tesar V. Primary Sjogren's syndrome in children and adolescents: proposal for diagnostic criteria. *Clin Exp Rheumatol* 1999;17:381-6.
- Baszis K, Toib D, Cooper M, French A, White A. Recurrent parotitis as a presentation of primary pediatric Sjogren syndrome. *Pediatrics* 2012;129:e179-82.
- Bogdanovic R, Basta-Jovanovic G, Putnik J, Stajic N, Paripovic A. Renal involvement in primary Sjogren syndrome of childhood: case report and literature review. *Mod Rheumatol* 2013;23:182-9.
- Cimaz R, Casadei A, Rose C, Bartunkova J, Sediva A, Falcini F, et al. Primary Sjogren syndrome in the paediatric age: a multicentre survey. *Eur J Pediatr* 2003;162:661-5.
- Civilibal M, Canpolat N, Yurt A, Kurugoglu S, Erdamar S, Bagci O, et al. A child with primary Sjogren syndrome and a review of the literature. *Clin Pediatr* 2007;46:738-42.
- Houghton K, Malleson P, Cabral D, Petty R, Tucker L. Primary Sjogren's syndrome in children and adolescents: are proposed diagnostic criteria applicable? *J Rheumatol* 2005;32:2225-32.
- McGuirt WF Jr, Whang C, Moreland W. The role of parotid biopsy in the diagnosis of pediatric Sjogren syndrome. *Arch Otolaryngol Head Neck Surg* 2002;128:1279-81.
- Saad Magalhaes C, de Souza Medeiros PB, Oliveira-Sato J, Custodio-Domingues MA. Clinical presentation and salivary gland histopathology of paediatric primary Sjogren's syndrome. *Clin Exp Rheumatol* 2011;29:589-93.
- Arabshahi B, Pollock AN, Sherry DD, Albert DA, Kreiger PA, Pessler F. Devic disease in a child with primary Sjogren syndrome. *J Child Neurol* 2006;21:285-6.
- Pessler F, Emery H, Dai L, Wu YM, Monash B, Cron RQ, et al. The spectrum of renal tubular acidosis in paediatric Sjogren syndrome. *Rheumatology* 2006;45:85-91.
- Stillier M, Golder W, Doring E, Biedermann T. Primary and secondary Sjogren's syndrome in children—a comparative study. *Clin Oral Investig* 2000;4:176-82.
- Singer NG, Tomanova-Soltys I, Lowe R. Sjogren's syndrome in childhood. *Curr Rheumatol Rep* 2008;10:147-55.
- Vitali C, Bombardieri S, Jonsson R, Moutsopoulos HM, Alexander EL, Carsons SE, et al. Classification criteria for Sjogren's syndrome: a revised version of the European criteria proposed by the American-European Consensus Group. *Ann Rheum Dis* 2002;61:554-8.
- Shiboski SC, Shiboski CH, Criswell LA, Baer AN, Challacombe S, Lanfranchi H, et al. American College of Rheumatology classification criteria for Sjogren's syndrome: a data-driven, expert consensus approach in the Sjogren's International Collaborative Clinical Alliance Cohort. *Arthritis Care Res* 2012;64:475-87.
- Radfar L, Kleiner DE, Fox PC, Pillemer SR. Prevalence and clinical significance of lymphocytic foci in minor salivary glands of healthy volunteers. *Arthritis Rheum* 2002;47:520-4.
- Kahlenberg JM. Neuromyelitis optica spectrum disorder as an initial presentation of primary Sjogren's syndrome. *Semin Arthritis Rheum* 2011;40:343-8.
- Nagaishi A, Takagi M, Umemura A, Tanaka M, Kitagawa Y, Matsui M, et al. Clinical features of neuromyelitis optica in a large Japanese cohort: comparison between phenotypes. *J Neurol Neurosurg Psychiatry* 2011;82:1360-4.
- Daniels TE, Cox D, Shiboski CH, Schiodt M, Wu A, Lanfranchi H, et al. Associations between salivary gland histopathologic diagnoses and phenotypic features of Sjogren's syndrome among 1,726 registry participants. *Arthritis Rheum* 2011;63:2021-30.