

Ultrasound of Synovitis in Rheumatoid Arthritis: Advantages of the Dorsal over the Palmar Approach to Finger Joints

Matthias N. Witt, Felix Mueller, Peter Weinert, Axel P. Nigg, Christiane S. Reindl, Fabian Proft, Hendrik Schulze-Koops, and Mathias Grunke

ABSTRACT. Objective. To compare the dorsal and palmar ultrasound (US) examination of finger joints in early rheumatoid arthritis (RA) with regard to the concurrence of greyscale (GSUS) and power Doppler (PDUS) positivity, and to correlate both approaches with clinical variables.

Methods. Patients with newly diagnosed RA were assessed by clinical examination and US. GSUS and PDUS of metacarpophalangeal (MCP) and proximal interphalangeal (PIP) joints were performed using the dorsal and palmar approach. Findings of synovitis in GSUS and PDUS were graded semiquantitatively from 0 to 3. Clinical and sonographic reevaluation was performed after 6 months.

Results. With 44.6% versus 32.2% positive findings, palmar GSUS identified significantly more joints with synovitis than did dorsal GSUS. With 22.1% versus 8.9%, PDUS abnormalities were detected significantly more often from the dorsal side. With 71.2% versus 21.8% for the MCP and 57.5% versus 17.4% for the PIP joints, significantly more GSUS and PDUS double-positive joints were found with the dorsal as opposed to the palmar approach. These differences remained significant at Month 6. Both palmar and dorsal GSUS and PDUS correlated with comparable strength with clinical variables such as the Disease Activity Score 28, Clinical Disease Activity Index, and Simple Disease Activity Index.

Conclusion. Although the dorsal approach detected fewer GSUS findings than the palmar approach, PDUS signals were significantly more frequently detected by dorsal US. In addition, the prevalence of double-positive joints with concurrent GSUS and PDUS findings was significantly higher with the dorsal approach. These data argue in favor of the dorsal US approach to finger joints in RA. (J Rheumatol First Release Feb 1 2014; doi:10.3899/jrheum.131027)

Key Indexing Terms:

EARLY RHEUMATOID ARTHRITIS

SYNOVITIS

ULTRASOUND

High-resolution ultrasonography (US) of the joints has become an essential tool for diagnosis of inflammatory rheumatic diseases but also for monitoring and assessment of remission. This technique is more sensitive and reliable

than clinical joint examination alone and is less expensive and more easily available than magnetic resonance imaging (MRI)^{1,2}. Yet there is still no consensus on which joints should be examined in the clinical setting and how the quantification of abnormal findings should be done and no agreement concerning the optimal approach to the finger joints. Concerning quantification, most authors consider the standard approach a semiquantitative grading system for greyscale ultrasound (GSUS) and power Doppler ultrasound (PDUS) findings^{3,4}. Exactly which joints should be monitored is still under debate. A comprehensive examination of all accessible joints is hardly feasible in clinical trials and almost impossible in daily clinical practice. However, “subclinical joints,” i.e., joints that are not tender or swollen by clinical examination but show sonographic activity, seem to be at risk for relapse and therefore constitute important information for the targeted goal of disease remission^{5,6}. Several scoring systems have been developed with the inclusion of different numbers and types of joints, which have all shown some correlation with clinical variables or MRI evaluation^{7,8,9,10}. At the moment,

From the Division of Rheumatology, Medizinische Klinik und Poliklinik IV, University of Munich, Munich; Leibniz-Rechenzentrum, Bavarian Academy of Sciences and Humanities, Garching, Germany.

Supported by the German Federal Ministry of Education and Research (BMBF) as part of the ArthroMark project (grant 01EC1009A).

M. Witt, MD; F. Mueller, Division of Rheumatology, Medizinische Klinik und Poliklinik IV, University of Munich; P. Weinert, MD, Leibniz-Rechenzentrum, Bavarian Academy of Sciences and Humanities; A. Nigg, MD; C. Reindl, MD, Division of Rheumatology, F. Proft, MD; H. Schulze-Koops, MD, Division of Rheumatology, Medizinische Klinik und Poliklinik IV, University of Munich; M. Grunke, MD, Division of Rheumatology, Medizinische Klinik und Poliklinik IV, University of Munich.

Drs. Witt and Mueller contributed equally to this work and should be considered co-first authors.

Address correspondence to Dr. Witt, Division of Rheumatology, Pettenkoferstr. 8a, 80336 Munich, Germany.

E-mail: matthias.witt@med.uni-muenchen.de

Accepted for publication November 28, 2013.

Personal non-commercial use only. The Journal of Rheumatology Copyright © 2014. All rights reserved.

there is no clear preference for one of these evaluation tools. These scores differ not only in the choice of evaluated joints, but also in the approach of the US probe to some of the joints, especially the metacarpophalangeal (MCP) and proximal interphalangeal (PIP) joints of the hands. Because a harmonization of the different evaluation tools is desirable and organizations such as Outcome Measures in Rheumatology are working on this goal¹¹, it seems of great importance to reach an agreement on which sides of the finger joints should be preferably examined.

Some authors prefer the dorsal approach to the finger joints for GSUS and PDUS^{2,4,12}: PDUS signals seem to be better detectable from the dorsal side¹² while greyscale findings are more frequent on the palmar side^{13,14,15}. The German “US7” score therefore examines MCP and PIP joints of the second and third digit from the dorsal side for PDUS signals and from the palmar side for GSUS and PDUS³. A more recent publication dealing with the differences between dorsal and palmar finger joint US underlined the better sensitivity of GSUS but also PDUS findings by the palmar approach and found a better correlation with clinical variables¹⁴. In a recent publication we showed that the better sensitivity for GSUS findings from the palmar side may be due to an overproportional number of “grade 1” findings, i.e., capsule distension of mild degree¹³. These borderline alterations seem to be of questionable relevance, as they can be found in healthy individuals as well, do not correlate with clinical variables, and show significantly less sensitivity to change over time upon treatment versus GSUS findings of higher grades. Moreover, the palmar GSUS findings were rarely accompanied by PDUS signals, which seem to be the most important variable for significant synovitis^{6,16,17}. Hence, the better approach to a joint may not be just the more sensitive one, but the one with the better concurrence between GSUS and PDUS abnormalities.

To clarify the role of dorsal versus palmar US of the finger joints, we compared the concurrence of GSUS and PDUS findings using both joint aspects. Additionally, we correlated dorsal and palmar findings with clinical examination and disease activity variables and evaluated the changes seen upon treatment.

MATERIALS AND METHODS

A total of 70 patients with newly diagnosed rheumatoid arthritis (RA) were recruited into our study. Diagnosis of RA was based on the modified American College of Rheumatology (ACR) criteria of 1987 or the 2010 ACR/European League Against Rheumatism (EULAR) criteria^{18,19}. Newly diagnosed RA was defined as disease duration of less than 2 years and no pretreatment with disease-modifying antirheumatic drugs (DMARD). Patients with inflammatory rheumatic diseases other than RA or with osteoarthritis were excluded. Grossly deformed joints and fused or replaced joints were not included in the analysis.

All individuals were clinically assessed by a 28-joint count according to the EULAR technique performed by 2 rheumatologists (MW or MG), who are experienced trainers in standardized clinical joint assessment in RA^{20,21}. Results were recorded as 28-tender joint count (TJC-28) and

28-swollen joint count (SJC-28). On the same day, after clinical examination, all individuals were independently assessed by US examination of the MCP and PIP joints from the palmar and dorsal side by 3 trained US assessors (MG, MW, and FM). Investigators performing the clinical examination were excluded from performing the US assessment to guarantee blinding. Standard longitudinal scanning planes were performed for both the palmar and the dorsal aspects of the finger joints, supplemented by a perpendicular second plane if an erosion was suspected. GSUS and PDUS were used in all joints examined and findings of synovitis in each modality were graded semiquantitatively as reported^{3,4}. GSUS grading was defined as follows: grade 1, a small anechoic line beneath the joint capsule; grade 2, capsule distension parallel to the joint area; grade 3, pronounced convex distension of the joint capsule. PDUS grading was defined as follows: grade 1, detection of up to 3 single color signs; grade 2, more than 1 confluent color sign; grade 3, color signs that fill more than 50% of the synovial area. To ensure discrimination of Doppler signals of origins other than synovitis-related hyperperfusion (e.g., superficial veins), the position of the Doppler box included the superficial parts of the US image. US assessments were performed on a high-resolution system (MyLab70, Esaote) with an 8–18 MHz probe. PD was uniformly performed with a pulse repetition frequency of 750 MHz. Six months after the baseline evaluation, a followup clinical and US examination was performed in 50 out of the initial 70 patients. In addition to clinical and US examinations, epidemiologic variables, the Health Assessment Questionnaire (HAQ), and patient and physician global assessments on visual analog scales (VAS) were obtained for all patients included in the study. Composite scores to assess disease activity were the Disease Activity Score (DAS28)²², the Clinical Disease Activity Index (CDAI)²³, and the Simplified Disease Activity Index (SDAI)²⁴.

Interobserver and intraobserver reliability assessments for the US examinations were calculated and based on described methods^{10,25}. For interobserver reliability, intraclass correlations (ICC) using an unadjusted, 2-way, mixed ICC model for single measures were calculated to enable nondichotomous reliability assessments. The following cutoff values were defined for interobserver reliability: $-1.00-0.0 =$ none; $0-0.20 =$ poor; $0.21-0.40 =$ modest; $0.41-0.60 =$ fair; $0.61-0.80 =$ good; $0.81-1.00 =$ excellent. Intraobserver agreements were calculated as percentage of an observer’s agreement between the scoring of the same randomly displayed set of US images at 2 timepoints. The results of intraobserver reliability were categorized in groups as described for interobserver assessment. For the description of the sensitivity to change of the palmar versus the dorsal GSUS and PDUS, the standardized response means (SRM) of the GSUS and PDUS positive joints were calculated. The effect sizes of the SRM were estimated as follows: $< 0.20 =$ trivial; $0.21-0.50 =$ small; $0.51-0.80 =$ moderate; $> 0.80 =$ large effect.

ICC were calculated using SPSS software, version 20.0 (IBM); all other statistical analysis was performed with Prism 5 software, version 5.2 (Prism). Significant changes were calculated by Fisher’s exact test or chi-square test. Quantitative variables are given as mean values (\pm SD), as absolute numbers, or as percentages. P values < 0.05 were considered statistically significant.

Our study was part of the ArthroMark project, which has ethical approval from the Charité Universitaetsmedizin Berlin. All patients gave their written informed consent for participation in the trial.

RESULTS

Patient characteristics. We evaluated 70 RA patients with disease duration < 2 years and no pretreatment with DMARD at baseline, corresponding to 1400 examined MCP and PIP joints. The cohort’s mean age was 55.6 years with a female-to-male ratio of 2.3. Rheumatoid factor and anti-citrullinated protein antibodies-positive findings in patients were 71.4% and 58.6%, respectively. Means for DAS28,

CDAI, and SDAI composite scores for disease activity were 4.7, 24.0, and 26.1, respectively. An overview of the baseline characteristics is given in Table 1. All patients subsequently received treatment according to national guidelines, with tight control and the goal of disease remission. The majority of patients received methotrexate as initial DMARD. Followup data after 6 months of treatment were available in 50 patients.

Interrater and intrarater reliability of US assessments. Data from 20 patients with RA were included in the interrater and intrarater reliability assessments, relating to a total of 440 US examinations of MCP, PIP, and wrist joints. Interrater agreement, as determined by ICC, was 0.84 for GSUS and 0.93 for PDUS. Intrarater reliability findings for GSUS and PDUS were 90.4% and 88.0%, 84.3% and 86.0%, and 85.7% and 87.4% for MW, MG, and FM, respectively.

Palmar versus dorsal GSUS and PDUS findings at baseline and Month 6. At baseline, palmar GSUS detected positive findings in 44.6%, while dorsal GSUS detected positive findings in 32.2% of all MCP and PIP joints examined ($p < 0.0001$). Palmar GSUS followup evaluation at Month 6 found positive findings in 29.4%, compared to 13.2% of positive findings found with dorsal GSUS ($p < 0.0001$). Concerning PDUS, the palmar examination of MCP and PIP joints at baseline detected positive findings in 8.9% of all joints examined, while dorsal PDUS was positive in 22.1% ($p < 0.0001$). Followup evaluation with PDUS at Month 6 detected positive findings in 2.2% with the palmar approach and in 5.5% with the dorsal approach ($p < 0.0001$, Figure 1). The prevalence of palmar and dorsal GSUS and PDUS findings differed significantly between baseline and followup at Month 6. In addition, with SRM > 0.80 for palmar and dorsal GSUS and PDUS, both approaches detected substantial treatment effects. In detail, SRM were 1.61 and 1.71 for dorsal GSUS and PDUS, respectively, and 1.22 and 1.57 for palmar GSUS and PDUS, respectively.

Table 1. Baseline characteristics of the study population.

No. of patients (n)	70
Age, yrs*	55.6 ± 15.2
Female:male	2:3
Mean disease duration, mo*	8.4 ± 7.8
RF-positive, %	71.4
ACPA-positive, %	58.6
Tender joints*, n	6.7 ± 4.8
Swollen joints*, n	6.3 ± 4.2
C-reactive peptide*, mg/dl	2.1 ± 2.6
ESR*, mm/h	22.4 ± 20.9
DAS28*	4.7 ± 1.2
CDAI*	24.0 ± 10.1
SDAI*	26.1 ± 11.4

* Mean ± SD; RF: rheumatoid factor; ACPA: anticitrullinated peptide antibodies; DAS28: 28-joint Disease Activity Score; CDAI: Clinical Disease Activity Index; SDAI: Simplified Disease Activity Index.

Palmar versus dorsal GSUS/PDUS concurrence at baseline and Month 6. The data at baseline and Month 6 were analyzed for the presence of double-positive joints, i.e., joints with concurrent localization of both GSUS and PDUS findings. At baseline, the prevalence of double-positive joints in MCP and PIP joints was 21.8% and 17.4% for the palmar approach and 71.2% and 57.5% for the dorsal approach, respectively ($p < 0.0001$ palmar vs dorsal for MCP and PIP). At followup at Month 6, the prevalence of double-positive joints in MCP and PIP joints decreased to 9.1% and 4.5% for the palmar approach compared to 46.2% and 21.5% for the dorsal approach, respectively ($p < 0.0001$ palmar vs dorsal for MCP and PIP, Figure 2).

Grading of palmar vs dorsal GSUS and PDUS findings at baseline. Palmar and dorsal GSUS and PDUS findings at baseline were stratified depending on the grade of positivity. The palmar approach detected grade 1, grade 2, and grade 3 GSUS findings in 24.7%, 14.9%, and 5.2% of all joints examined, respectively, while the dorsal approach detected grade 1, grade 2, and grade 3 GSUS findings in 15.9%, 11.7%, and 4.7%, respectively. Concerning PDUS, the palmar approach found grade 1, grade 2, and grade 3 findings in 6.1%, 2.0%, and 0.6% of all examinations, respectively, while the dorsal approach found grade 1, grade 2, and grade 3 findings in 7.6%, 11.2%, and 3.3%, respectively.

With GSUS and PDUS grade 0–3 in each modality, 15 GSUS/PDUS combinations of positive findings were possible, consisting of either single-positive, i.e., either GSUS or PDUS positivity, or double-positive, i.e., GSUS and PDUS positivity, findings in a given joint (Figure 3). Concerning any positive findings, the combination GSUS grade 1 with PDUS grade 0 was most prevalent from both sides, with significantly higher frequencies from the palmar side ($p < 0.0001$). Concerning double-positive findings only, marked differences between the palmar and the dorsal approach were noted. In general, double-positive findings were more prevalent with the dorsal approach.

Correlation of palmar versus dorsal GSUS and PDUS findings with clinical variables. Baseline palmar and dorsal GSUS and PDUS findings were correlated with HAQ, VAS pain, VAS activity, VAS physician, TJC-28, SJC-28, and the composite disease activity scores DAS28, CDAI, and SDAI. Significant correlations were found for palmar GSUS and PDUS with VAS physician, TJC-28, SJC-28, DAS28, CDAI, and SDAI. For dorsal GSUS and PDUS, significant correlations were found with VAS physician, SJC-28, and DAS28. The strength of correlation ranged from modest to fair, depending on the variable assessed. Palmar and dorsal correlations of GSUS and PDUS with clinical variables did not differ significantly. Correlations with HAQ, VAS pain, and VAS activity did not reach significance for both palmar and dorsal GSUS and PDUS (Table 2 and Figure 4).

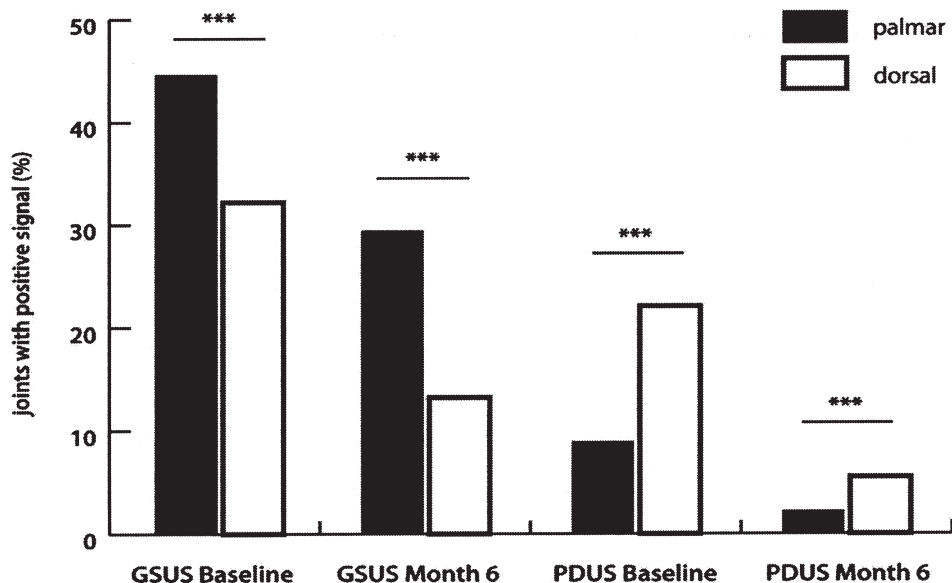


Figure 1. Prevalence of palmar versus dorsal greyscale ultrasound (GSUS) and power Doppler ultrasound (PDUS) findings at baseline and at Month 6 in percent of all joints examined. Dorsal PDUS detects significantly more findings. GSUS findings are more frequently detected on the palmar side. Findings detected by both approaches improve significantly with therapy. *** $p < 0.0001$.

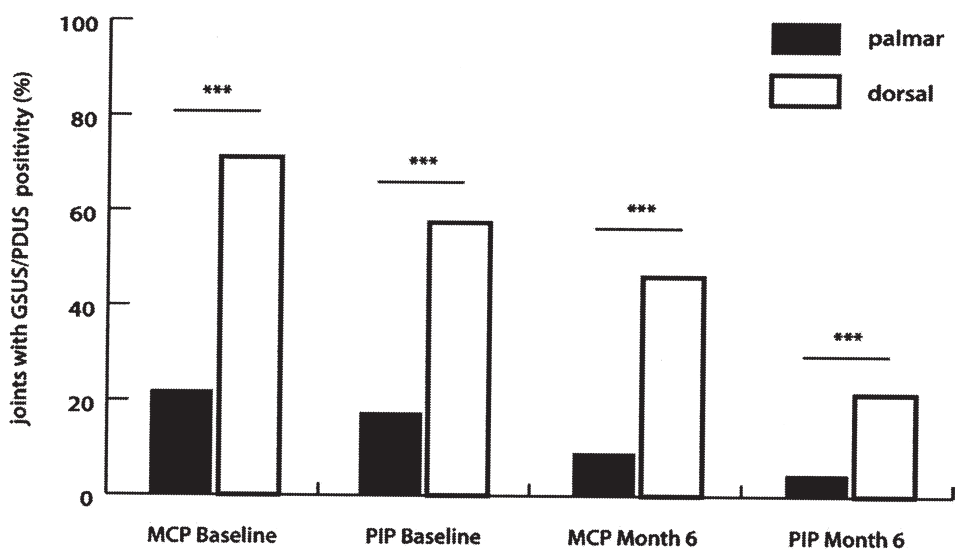


Figure 2. Prevalence of greyscale ultrasound (GSUS) and power Doppler ultrasound (PDUS) double-positive palmar versus dorsal on the metacarpophalangeal (MCP) and proximal interphalangeal (PIP) joints at baseline and at Month 6, in percentage of all positive GSUS and PDUS findings. Double positivity is detected significantly more often by the dorsal approach. *** $p < 0.0001$.

DISCUSSION

The purpose of our work was to compare the palmar and dorsal US approaches to the finger joints in early RA. With this regard, several aspects were analyzed for each approach, namely the ability to detect synovitis, the sensitivity to change upon treatment, the respective prevalence of GSUS and PDUS double-positive joints and the correlations with important clinical variables. So far, a thorough

comparison of the various US approaches using either the palmar and/or the dorsal approach to the finger joints has not been performed. However, detailed information about the respective advantages and limitations of either approach is of importance for the development of a practical composite US score, which could be used in clinical practice as well as in clinical trials.

The patients in our cohort represent a typical early RA

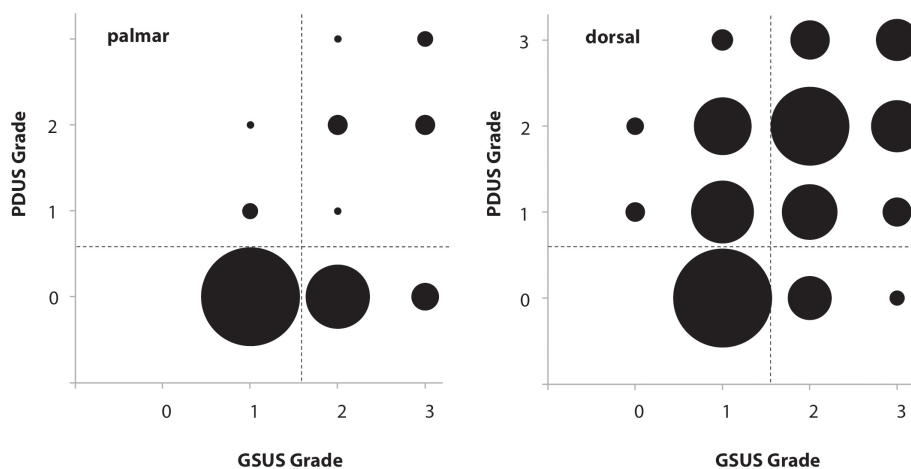


Figure 3. Overview of the semiquantitative grading pattern for palmar (left) and dorsal (right) greyscale ultrasound (GSUS) and power Doppler ultrasound (PDUS) positive joints. Circles in the upper right quadrants indicate that double-positive joints with higher grades were more frequently detected with the dorsal approach.

Table 2. Overview of correlations of palmar and dorsal GSUS and PDUS with clinical criteria. Correlations in bold face are shown in Figure 4.

	Physician VAS	TJC-28	SJC-28	DAS28	CDAI	SDAI
Palmar						
GSUS	0.521***	0.411**	0.692***	0.527***	0.619***	0.639***
PDUS	0.393**	0.357**	0.430**	0.443***	0.497***	0.500***
GSUS + PDUS	0.523***	0.429**	0.663***	0.545***	0.632***	0.648***
Dorsal						
GSUS	0.535***	0.192	0.715***	0.435**	0.528***	0.571***
PDUS	0.593***	0.242*	0.615***	0.514***	0.550***	0.595***
GSUS + PDUS	0.576***	0.212	0.696***	0.484***	0.551***	0.599***

*** p < 0.0001; ** p < 0.01; * p < 0.05. Physician VAS: physician global assessments on visual analog scale; TJC-28: 28-joint tender joint count; SJC-28: 28-joint swollen joint count; GSUS: greyscale ultrasound; PDUS: power Doppler ultrasound; DAS28: 28-joint Disease Activity Score; CDAI: Clinical Disease Activity Index; SDAI: Simplified Disease Activity Index.

population, which is suitable for analyzing the above-named aspects for several reasons. Most importantly, in this early phase of the disease one can expect a clear picture of synovitis status in US without the bony and soft tissue alterations. These can develop over years of arthritis and may bias the interpretation of GSUS and PDUS findings from either side. In our cohort, there was only a small percentage of joints with sonographic findings consistent with erosive changes (< 5% of joints examined). Further, these patients have a high probability of response to their initial treatment and are therefore very suitable for the sonographic evaluation of changes over time. With 70 and 50 patients analyzed at baseline and at Month 6, palmar, and dorsal US data of 1400 and 1000 examined MCP and PIP joints were available for analysis, respectively, resulting in strong statistical numbers.

Comparing palmar to dorsal GSUS at baseline and Month 6, we could confirm our data and that of others^{3,14} showing that the palmar approach generally seems to pick up more findings consistent with synovitis than the dorsal approach. However, detailed analysis of palmar GSUS findings has shown that up to 50% would be classified as grade 1 findings, which commonly lack PDUS positivity and are also frequently found in healthy individuals. Hence their clinical relevance may be questioned, putting the higher overall prevalence of findings of synovitis with palmar GSUS into perspective^{6,16,17}. With regard to changes in response to treatment, palmar GSUS and PDUS performed comparable to dorsal GSUS and PDUS, because both approaches detected significant improvements from baseline to Month 6. In addition, closer evaluation of treatment effects by reporting SRM demonstrates better

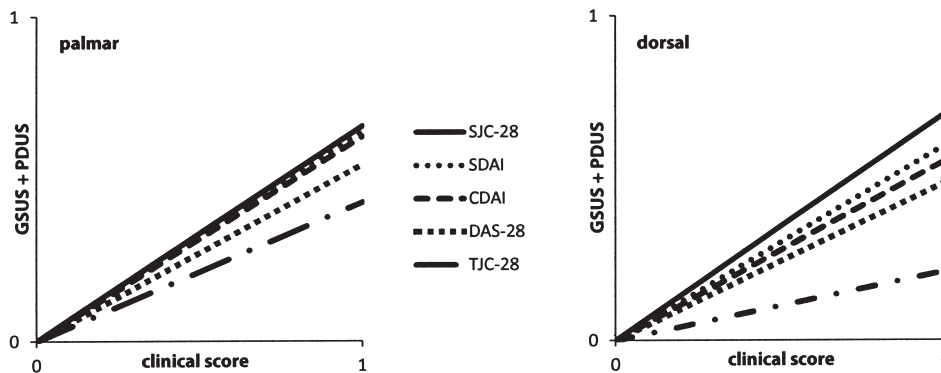


Figure 4. Palmar and dorsal correlations of greyscale ultrasound (GSUS) and power Doppler ultrasound (PDUS) findings with clinical variables. SJC-28: 28-swollen joint count; CDAI: Clinical Disease Activity Index; SDAI: Simplified Disease Activity Index; DAS28: 28-joint Disease Activity Score; TJC-28: 28-joint tender joint count.

performance of GSUS and PDUS with the dorsal approach (Figure 1).

Given the general importance of PDUS for the sonographic assessment of synovitis^{26,27}, we considered the prevalence of concurrent GSUS and PDUS findings in the same joint, i.e., “double-positive joints,” to be a good marker for the evaluation of both examination methods. While joints with GSUS-only findings are quite common (particularly on the palmar side as mentioned), joints that are positive only in PDUS examination are extremely rare. Assuming that double-positive joints more likely represent relevant sonographic synovitis, the dorsal approach performs significantly better than the palmar one, because it identifies more double-positive joints at baseline and Month 6 than the palmar approach, thereby yielding a better consistency of GSUS findings with PDUS positivity. The closer analysis of both the GSUS and PDUS component of double-positive joints shows that this is mainly due to the significantly higher prevalence of PDUS findings from the dorsal side as opposed to the palmar side. This most probably results from a better sensitivity of the dorsal PDUS for the detection of hypervascularization in the more superficial synovitic blood vessels on the dorsal side of the finger joints (Figures 2 and 3). Other reasons for the apparent different sensitivities of the volar versus the dorsal PDUS may include factors such as differences in the capsule laxity, different tissue compositions of the dorsal plate versus the palmar slip, and finally, different thicknesses of the flexor versus the extensor tendons.

The correlation of US scores with clinical variables is usually not very pronounced. This is especially the case for the TJC, patient assessments of pain, global disease activity, and functional impairment as measured by the HAQ. In this respect, our results are in line with published data^{3,14}. In our study, the best correlations between US and clinical variables have been found for the SJC and disease activity as measured by DAS28, CDAI, and SDAI. For all these

assessed variables, the strength of correlation did not differ significantly between the palmar or dorsal approach (Figure 4 and Table 2).

Taken together for the US evaluation of finger joints in early RA, our data point out important differences between the palmar and the dorsal approach. While there are similarities with regard to the correlation with clinical variables, the dorsal GSUS and PDUS approach better demonstrates changes upon treatment and yields significantly better consistency of GSUS findings with PDUS positivity. For these reasons, and as a comprehensive US examination with inclusion of both approaches in all MCP and PIP joints may not be feasible for reasons of practicability, the dorsal approach seems to be preferable to the palmar approach.

REFERENCES

1. Scheel AK, Hermann KG, Ohrndorf S, Werner C, Schirmer C, Detert J, et al. Prospective 7 year follow up imaging study comparing radiography, ultrasonography, and magnetic resonance imaging in rheumatoid arthritis finger joints. *Ann Rheum Dis* 2006;65:595-600.
2. Naredo E, Bonilla G, Gamero F, Uson J, Carmona L, Laffon A. Assessment of inflammatory activity in rheumatoid arthritis: a comparative study of clinical evaluation with grey scale and power Doppler ultrasonography. *Ann Rheum Dis* 2005;64:375-81.
3. Backhaus M, Ohrndorf S, Kellner H, Strunk J, Backhaus TM, Hartung W, et al. Evaluation of a novel 7-joint ultrasound score in daily rheumatologic practice: a pilot project. *Arthritis Rheum* 2009;61:1194-201.
4. Dougados M, Devauchelle-Pensec V, Ferlet JF, Jousse-Joulin S, D'Agostino MA, Backhaus M, et al. The ability of synovitis to predict structural damage in rheumatoid arthritis: a comparative study between clinical examination and ultrasound. *Ann Rheum Dis* 2013;72:665-71.
5. Saleem B, Walsh CA, Emery P. Remission in inflammatory arthritis: a new immunological target. *Immunotherapy* 2011; 3:459-63.
6. Scire CA, Montecucco C, Codullo V, Epis O, Todoerti M, Caporali R. Ultrasonographic evaluation of joint involvement in early rheumatoid arthritis in clinical remission: power Doppler signal predicts short-term relapse. *Rheumatology* 2009;48:1092-7.

7. Dougados M, Jousse-Joulin S, Mistretta F, d'Agostino MA, Backhaus M, Bentin J, et al. Evaluation of several ultrasonography scoring systems for synovitis and comparison to clinical examination: results from a prospective multicentre study of rheumatoid arthritis. *Ann Rheum Dis* 2010;69:828-33.
8. Naredo E, Rodriguez M, Campos C, Rodriguez-Heredia JM, Medina JA, Giner E, et al. Validity, reproducibility, and responsiveness of a twelve-joint simplified power doppler ultrasonographic assessment of joint inflammation in rheumatoid arthritis. *Arthritis Rheum* 2008;59:515-22.
9. Hameed B, Pilcher J, Heron C, Kiely PD. The relation between composite ultrasound measures and the DAS28 score, its components and acute phase markers in adult RA. *Rheumatology* 2008;47:476-80.
10. Ohrndorf S, Fischer IU, Kellner H, Strunk J, Hartung W, Reiche B, et al. Reliability of the novel 7-joint ultrasound score: results from an inter- and intraobserver study performed by rheumatologists. *Arthritis Care Res* 2012;64:1238-43.
11. Naredo E, Wakefield RJ, Iagnocco A, Terslev L, Filippucci E, Gandjbakhch F, et al. The OMERACT ultrasound task force—status and perspectives. *J Rheumatol* 2011;38:2063-7.
12. Seymour MW, Kelly S, Beals CR, Malice MP, Bolognese JA, Dardzinski BJ, et al. Ultrasound of metacarpophalangeal joints is a sensitive and reliable endpoint for drug therapies in rheumatoid arthritis: results of a randomized, two-center placebo-controlled study. *Arthritis Res Ther* 2012;14:R198.
13. Witt M, Mueller F, Nigg A, Reindl C, Leipe J, Proft F, et al. Relevance of grade 1 gray-scale ultrasound findings in wrists and small joints to the assessment of subclinical synovitis in rheumatoid arthritis. *Arthritis Rheum* 2013;65:1694-701.
14. Vlad V, Berghea F, Libianu S, Balanescu A, Bojinca V, Constantinescu C, et al. Ultrasound in rheumatoid arthritis: volar versus dorsal synovitis evaluation and scoring. *BMC Musculoskeletal Disord* 2011;12:124.
15. Scheel AK, Hermann KG, Kahler E, Pasewaldt D, Fritz J, Hamm B, et al. A novel ultrasonographic synovitis scoring system suitable for analyzing finger joint inflammation in rheumatoid arthritis. *Arthritis Rheum* 2005;52:733-43.
16. Szkudlarek M, Court-Payen M, Strandberg C, Klarlund M, Klausen T, Ostergaard M. Power Doppler ultrasonography for assessment of synovitis in the metacarpophalangeal joints of patients with rheumatoid arthritis: a comparison with dynamic magnetic resonance imaging. *Arthritis Rheum* 2001;44:2018-23.
17. Foltz V, Gandjbakhch F, Etchepare F, Rosenberg C, Tanguy ML, Rozenberg S, et al. Power Doppler ultrasound, but not low-field magnetic resonance imaging, predicts relapse and radiographic disease progression in rheumatoid arthritis patients with low levels of disease activity. *Arthritis Rheum* 2012;64:67-76.
18. Aletaha D, Neogi T, Silman AJ, Funovits J, Felson DT, Bingham CO 3rd, et al. 2010 rheumatoid arthritis classification criteria: an American College of Rheumatology/European League Against Rheumatism collaborative initiative. *Arthritis Rheum* 2010;62:2569-81.
19. Arnett FC, Edworthy SM, Bloch DA, McShane DJ, Fries JF, Cooper NS, et al. The American Rheumatism Association 1987 revised criteria for the classification of rheumatoid arthritis. *Arthritis Rheum* 1988;31:315-24.
20. Grunke M, Antoni CE, Kavanaugh A, Hildebrand V, Dechant C, Schett G, et al. Standardization of joint examination technique leads to a significant decrease in variability among different examiners. *J Rheumatol* 2010;37:860-4.
21. Grunke M, Witt MN, Ronneberger M, Schnez A, Laubender RP, Engelbrecht M, et al. Use of the 28-joint count yields significantly higher concordance between different examiners than the 66/68-joint count. *J Rheumatol* 2012;39:1334-40.
22. van der Heijde DM, van't Hof MA, van Riel PL, van Leeuwen MA, van Rijswijk MH, van de Putte LB. Validity of single variables and composite indices for measuring disease activity in rheumatoid arthritis. *Ann Rheum Dis* 1992;51:177-81.
23. Aletaha D, Nell VP, Stamm T, Uffmann M, Pflugbeil S, Machold K, et al. Acute phase reactants add little to composite disease activity indices for rheumatoid arthritis: validation of a clinical activity score. *Arthritis Res Ther* 2005;7:R796-806.
24. Smolen JS, Breedveld FC, Schiff MH, Kalden JR, Emery P, Eberl G, et al. A simplified disease activity index for rheumatoid arthritis for use in clinical practice. *Rheumatology* 2003;42:244-57.
25. Chavez-Lopez MA, Hernandez-Diaz C, Moya C, Pineda C, Ventura-Rios L, Moller I, et al. Inter- and intra-observer agreement of high-resolution ultrasonography and power Doppler in assessment of joint inflammation and bone erosions in patients with rheumatoid arthritis. *Rheumatol Int* 2013;33:173-7.
26. Ohrndorf S, Backhaus M. Musculoskeletal ultrasonography in patients with rheumatoid arthritis. *Nat Rev Rheumatol* 2013;9:433-7.
27. Ohrndorf S, Backhaus M. Advances in sonographic scoring of rheumatoid arthritis. *Ann Rheum Dis* 2013;72 Suppl 2:ii69-75.