

Hidradenitis Suppurativa Associated with Spondyloarthritis — Results from a Multicenter National Prospective Study

Pascal Richette, Anna Molto, Manuel Viguier, Karen Dawidowicz, Gilles Hayem, Aude Nassif, Daniel Wendling, François Aubin, Frédéric Lioté, and Hervé Bachelez

ABSTRACT. Objective. To determine the prevalence and characterize the inflammatory musculoskeletal symptoms of hidradenitis suppurativa (HS), a chronic inflammatory disease of skin appendages.

Methods. Patients with HS referred to 3 dermatology university hospital centers were systematically screened for peripheral arthritis, dactylitis, inflammatory back pain, or enthesitis. After careful clinical examination, patients were further classified according to clinical and imaging criteria for spondyloarthritis (SpA) using the Amor, European Spondyloarthropathy Study Group (ESSG), and ASsessment in ankylosing spondylitis (ASAS).

Results. We screened 640 patients with HS; 184 had musculoskeletal symptoms. In all, 43 (mean age 39.4 yrs, \pm 8.3; 80% women) had arthritis, inflammatory back pain, or enthesitis and were investigated further. Signs of HS preceded the onset of articular symptoms in 39 patients (90%), at a mean interval of 3.6 years. A total of 18 (41%), 24 (55%), and 15 (34%) patients fulfilled the Amor, ESSG, and ASAS criteria, respectively, while synovitis, acne, pustolosis, hyperostosis, and osteitis (SAPHO) syndrome was established in 4 patients. The crude prevalence of SpA in all 640 patients with HS was 3.7% by the ESSG criteria.

Conclusion. SpA may occur in patients with HS, with the prevalence in this group exceeding that in the general population. The very short time between skin and joint symptom onset in some cases suggests common pathogenic mechanisms underlying HS and SpA. (J Rheumatol First Release Jan 15 2014; doi:10.3899/jrheum.130977)

Key Indexing Terms:

HIDRADENITIS SUPPURATIVA
ARTHRITIS

SPONDYLOARTHRITIS
ENTHESITIS

SAPHO SYNDROME
DACTYLITIS

Hidradenitis suppurativa (HS), also called acne inversa, is a chronic, frequently debilitating inflammatory disease involving skin appendages located mainly in axillary and inguinoperineal areas^{1,2,3}. HS may be associated with 1 or several other inflammatory skin diseases, such as severe acne conglobata or neutrophilic dermatoses^{2,4,5,6}, or with extracu-

taneous diseases, such as inflammatory bowel disease (IBD)⁷. Interestingly, all of these conditions share dysregulation of the innate immune system, as supported by the enhanced presence or expression in tissue lesions of neutrophils and macrophages as well as cytokines, such as tumor necrosis factor- α (TNF- α), interleukin 1 β (IL-1 β), and IL-6⁸.

From the Assistance Publique-Hôpitaux de Paris (AP-HP), Hôpital Lariboisière, Pôle appareil locomoteur, Fédération de Rhumatologie; University Paris Diderot, Sorbonne Paris Cité, Paris, France; Universitat Autònoma de Barcelona, Departament de Medicina, Barcelona, Spain; AP-HP, Hôpital Saint-Louis, Service de Dermatologie, Immunité anti virale, Biothérapie et Vaccins; Institut Pasteur, Sorbonne Paris Cité, Université Paris Diderot; AP-HP, Hôpital Bichat, Service de Rhumatologie; Université Paris Diderot, Sorbonne Paris Cité; Institut Pasteur, Centre médical, Paris; Service de Rhumatologie, Service de Dermatologie, Université de Franche-Comté, Besançon-Inserm, UMR S606, Centre Viggo Petersen, Hôpital Lariboisière; AP-HP, Hôpital Saint-Louis, Service de Dermatologie, INSERM U781, Hôpital Necker Enfants-Malades, Sorbonne Paris Cité Université, Paris Diderot, Paris, France.

Supported by the Association Rhumatisme et Travail, Hôpital Lariboisière, Paris, France.

P. Richette, MD, PhD, AP-HP, Hôpital Lariboisière, Pôle appareil locomoteur, Fédération de Rhumatologie; A. Molto, MD, AP-HP, Hôpital Lariboisière, Pôle appareil locomoteur, Fédération de Rhumatologie, and Universitat Autònoma de Barcelona, Departament de Medicina;

M. Viguier, MD, PhD, AP-HP, Hôpital Saint-Louis, Service de Dermatologie, Immunité anti virale, Biothérapie et Vaccins and Institut Pasteur, Sorbonne Paris Cité Université; K. Dawidowicz, MD, PhD, AP-HP, Hôpital Lariboisière, Pôle appareil locomoteur, Fédération de Rhumatologie; G. Hayem, MD, PhD, AP-HP, Hôpital Bichat, Service de Rhumatologie, and University Paris Diderot; A. Nassif, MD, PhD, Institut Pasteur, Centre Medical; D. Wendling, MD, PhD, Service de Rhumatologie, CHRU de Besançon, Université de Franche-Comté; F. Aubin, MD, PhD, Service de Dermatologie, CHRU de Besançon, Université de Franche-Comté; F. Lioté, MD, PhD, AP-HP, Hôpital Lariboisière, Pôle appareil locomoteur, Fédération de Rhumatologie and Inserm, UMR S606, Centre Viggo Petersen, Hôpital Lariboisière; H. Bachelez, MD, PhD, AP-HP, Hôpital Saint-Louis, Service de Dermatologie, INSERM U781, Hôpital Necker Enfants-Malades, Sorbonne Paris Cité.

Address correspondence to Dr. P. Richette, Fédération de Rhumatologie, Hôpital Lariboisière, 2 Rue Ambroise Paré, 75475 Paris cedex 10, France; and Hervé Bachelez, Service de Dermatologie, Hôpital Saint-Louis, 75010 Paris, France. E-mail: pascal.richette@lrh.aphp.fr
Accepted for publication October 30, 2013.

Personal non-commercial use only. The Journal of Rheumatology Copyright © 2014. All rights reserved.

The association of HS and musculoskeletal symptoms has rarely been reported, except as single cases^{4,9,10,11,12} or as limited retrospective case series more than 2 decades ago^{13,14,15}. In most cases, the associated arthropathy suggested spondyloarthritis (SpA), with prominent asymmetrical peripheral arthritis and axial involvement. However, the reported cases of patients with HS and inflammatory arthritis were not extensively investigated with validated classification criteria for SpA and imaging, such as magnetic resonance imaging (MRI).

Evidence that common inflammatory pathways, such as IL-1 and TNF- α , might be dysregulated in both HS⁸ and SpA^{16,17}, provides additional support for studies investigating inflammatory rheumatological disorders in patients with HS.

We investigated the overall prevalence of inflammatory arthritis in a large series of patients with HS and characterized the associated rheumatological involvement using several sets of classification criteria for SpA.

MATERIALS AND METHODS

This was a prospective, multicenter, observational study that involved 3 dermatology and rheumatology departments from tertiary care hospitals in France. The first and last patients were recruited in September 2010 and April 2013, respectively.

To be included, patients had to have a diagnosis of HS assessed by a dermatologist and at least 1 of the following: arthritis, enthesitis, or inflammatory back pain. We chose these criteria to avoid including patients with HS and frequent degenerative conditions, such as osteoarthritis, tendinitis, or chronic low back pain.

The Institutional Review Board (No. IRB000064771) of Paris North Hospitals approved the study (no. 10-073).

Diagnosis of HS. Diagnosis of HS was based on criteria adopted by the second congress organized by the Hidradenitis Suppurativa Foundation, in March 2009. The following 3 criteria must be met to establish the diagnosis: (1) typical lesions, specifically deep-seated painful nodules: "blind boils" in early lesions; abscesses, draining sinus, bridged scars, and "tombstone" open comedones in secondary lesions; (2) typical topography, specifically, axillae; groin; perineal; and perianal region, buttocks, infra-, and inter-mammary folds; and (3) chronicity and recurrences³.

For each patient with HS, the following data were recorded: age at onset, the presence or personal history of inflammatory skin diseases other than HS (acne conglobata, psoriasis, palmo-plantar pustulosis, neutrophilic dermatosis), and family history of HS, uveitis, IBD, and smoking.

At the time of inclusion, the severity of HS was graded by the Hurley classification (grade I: abscess formation, single or multiple without sinus tracts and scarring; grade II: recurrent abscesses with tract formation and scarring and single or multiple lesions with areas of uninvolved skin between lesions; grade III: diffuse or near-diffuse involvement or multiple interconnected tracts and abscesses across the entire area without any normal skin between lesions)³.

Characterization of musculoskeletal features. All patients with HS and who had articular complaints were referred to an academic rheumatologist. After careful clinical examination, patients were included in the study provided they had arthritis and/or enthesitis and/or inflammatory back pain according to the Calin or Berlin criteria^{18,19}. The Calin criteria require the presence of 4 of the following 5 items: age at disease onset < 40 years, duration of back pain > 3 months, insidious onset, morning stiffness > 30 min, and pain improvement with exercise. The Berlin criteria require the presence of 2 of the following items: morning stiffness > 30 min,

improvement in back pain with exercise but not rest, nocturnal awakening (second half of the night only), and alternating buttock pain.

We recorded the localization of clinical musculoskeletal symptoms, as well as age at onset, presence or history of dactylitis, family history of SpA, rapid improvement of back pain after nonsteroidal antiinflammatory (NSAID) therapy, anterior chest wall pain, and positivity for HLA-B27.

Patients underwent radiography and MRI of the spine and sacroiliac joints according to their symptoms and usual clinical practice. Search for presence of sacroiliitis and other imaging features of SpA was performed as described²⁰. Briefly, sacroiliac joint radiographs were graded as 0, normal; 1, doubtful sacroiliitis; 2, minimal abnormality; 3, unequivocal abnormality; 4, severe abnormality-fusion. MRI images were classified as having definite, doubtful, or absent inflammatory and/or structural lesions at the spinal and sacroiliac joint levels.

Finally, we used the following classification criteria for the diagnosis of SpA and subtypes: European Spondylarthropathy Study Group (ESSG), Amor, and ASsessment in ankylosing spondylitis (ASAS) classification criteria¹⁶.

RESULTS

Demographic characteristics of patients. We screened 184 patients with musculoskeletal complaints and a diagnosis of HS from September 2010 to April 2013 (Figure 1); 43 fulfilled the inclusion criteria. The mean age was 39.4 years (\pm 8.3), 80% were women, 70% were current smokers, and the mean body mass index was 29.4 (\pm 6.7 kg/m²; Table 1).

Hidradenitis suppurativa. HS was the unique skin finding in 27 patients (62%) and was associated with acne conglobata, psoriasis, or palmar and/or plantar pustulosis in 8 (18%), 4 (9%), and 5 patients (11%), respectively (Table 1). According to the Hurley classification, most cases of HS were grades 3 and 2 (n = 19/43, 44%; and n = 17/43, 39%, respectively); only 7 (16%) were grade 1 (Table 1). Two patients showed an association of neutrophilic aseptic dermatosis, consisting of pyoderma gangrenosum in 1 case and diffuse cutaneous aseptic abscesses in the other (Table 1). In both patients, neutrophilic lesions followed a parallel course with HS and inflammatory rheumatological disease, and despite increased serum level of C-reactive protein (CRP), both were negative for IBD.

About half of the patients (n = 20) had a family history of skin conditions: HS (n = 11), psoriasis (n = 6), and acne conglobata (n = 3; Table 1). In addition, 4 patients had Crohn's disease and 2 a history of anterior uveitis. One patient presented a complex syndrome combining HS, severe nodulocystic acne, and chronic diffuse cutaneous aseptic abscesses, without evidence of aseptic multifocal osteomyelitis or IBD (Table 1).

At the time of enrollment, 23 patients (53.5%) were taking antibiotics for HS and 22 were taking NSAID; 6 received TNF- α inhibitors.

Axial and peripheral involvement in patients with HS. For 39/43 patients (90%), signs of HS preceded the onset of symptoms of inflammatory rheumatologic disease, with a mean delay of 3.6 years and occurred after or concomitantly with rheumatologic symptoms in 4/43 cases. Table 2

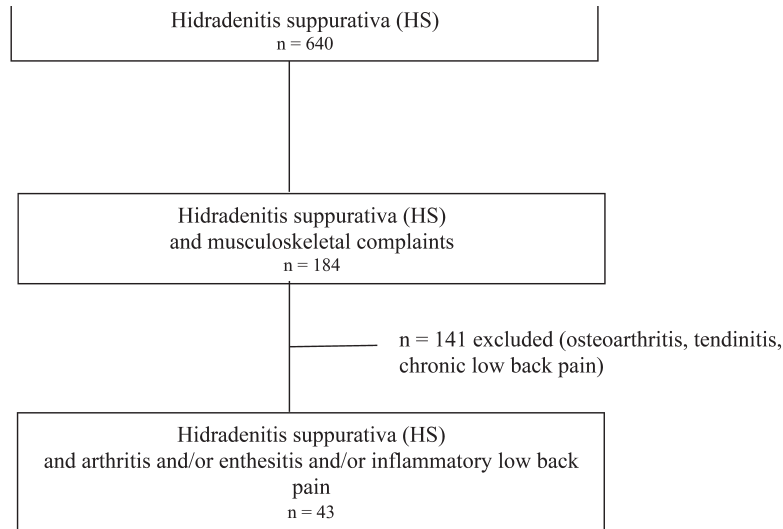


Figure 1. Flow chart of the study participants.

Table 1. Demographic characteristics of 43 patients with hidradenitis suppurativa (HS). Data are n (%) unless otherwise indicated.

Characteristics	
Age, yrs, mean \pm SD	39.4 \pm 8.3
Sex ratio, female/male	34/9
Body mass index, kg/m ² , mean \pm SD	29.4 \pm 6.7
Current smokers	30 (70)
Hurley classification	
Grade 1	7 (16)
Grade 2	17 (39)
Grade 3	19 (44)
Other dermatological conditions	
HS + acne conglobata	8 (18)
HS + palmo plantar pustulosis	5 (11)
HS + plaque psoriasis	4 (9)
HS + pyoderma gangrenosum	1 (2)
Diffuse cutaneous aseptic abscesses	1 (2)
Family history of skin involvement	20 (46)
HS	11 (25)
Psoriasis	6 (13)
Acne conglobata	3 (6)
Associated extra-articular diseases	
Uveitis	2 (4)
Inflammatory bowel disease	4 (9)
HLA-B27 positive	7/16 (43)

describes the prevalence of axial and/or peripheral involvement. The mean duration of rheumatological symptoms was 3.0 years (\pm 3.8). About half of the patients had enthesitis, and 81% (n = 35) had axial involvement. Dactylitis, peripheral arthritis, and anterior chest wall pain were present in 9% (n = 4), 25% (n = 11), and 34% (n = 15) of patients, respectively. Peripheral arthritis predominantly involved the lower limbs, and enthesitis of the Achilles tendon was diagnosed in half of the patients. Four patients showed evidence of aseptic osteitis. The prevalence of

Table 2. Clinical and imaging feature in patients with hidradenitis suppurativa (HS).

Features	n (%)
Clinical	
IBP	35 (81)
Cervical spine	18 (41)
Thoracic spine	17 (39)
Lumbar spine	27 (62)
Buttock	20 (46)
Peripheral arthritis	11 (25)
Dactylitis	4 (9)
Enthesitis	20 (46)
Anterior chest wall pain	15 (34)
Aseptic osteitis	4 (9)
Imaging	
Radiography, n = 31	
SI involvement	10 (32)
Spine involvement	4 (12)
MRI, n = 15	
Inflammatory lesions (SI joint)	3 (20)
Chronic lesions (SI joint)	3 (20)
Inflammatory lesions (spine)	3 (20)

IBP: inflammatory back pain; SI: sacroiliac; MRI: magnetic resonance imaging.

HLA-B27 positivity, as assessed in 16 patients, was 43% (n = 7; Table 1).

Imaging features in patients with HS. Radiographs of both the pelvis and the spine were available for 31 patients. Sacroiliitis was seen in 10 patients and syndesmophytes were seen in 4 (Table 2). In all, 15 patients underwent MRI of the sacroiliac joints and spine; active inflammatory lesions were seen in the spine in 3 patients and in the sacroiliac joints in 3/10 patients. Three patients showed structural lesions of the sacroiliac joints.

Fulfillment of SpA criteria. We assessed the prevalence of SpA in patients with HS by different SpA criteria. A total of 18 (41%), 24 (55%), and 15 (34%) patients fulfilled the Amor, ESSG, and ASAS criteria, respectively. Finally, 4 patients showed synovitis, acne, pustulosis, hyperostosis, and osteitis (SAPHO) syndrome. None of the patients had rheumatoid arthritis or another chronic inflammatory rheumatism. In considering the number of HS patients (n = 640) referred to the 3 dermatology centers during the study period, the crude prevalence of SpA in patients with HS diagnosed by ESSG criteria was 3.7%.

DISCUSSION

To our knowledge, this is the first prospective study involving a systematic screening of a large sample of patients with HS for presence of inflammatory rheumatological disease. Our study involved an established dermatology-rheumatology transdisciplinary network, as well as using well-established classification criteria for both conditions, to limit estimation bias. We provide strong evidence for a non-fortuitous association of SpA and HS, at least with severe forms of the disease. Indeed, the estimated prevalence of SpA of 3.7% in this cohort of patients with HS far exceeds that estimated for the French population, 0.3%^{21,22}.

Our results are strengthened by the use of widely accepted, stringent classification and imaging criteria for the diagnosis of SpA, which were not used in previous studies of HS and rheumatological disorders^{13,14,15}. Several biases may result from the design of our study, such as the predominant recruitment of moderate to severe cases of HS in tertiary care centers, as shown by the overrepresentation of patients with Hurley stages 2 and 3 HS. However, these epidemiological results, as well as the short time interval between the respective onset of HS and SpA in some cases, suggest an association between the 2 diseases. This latter hypothesis is reinforced by common inflammatory mechanisms such as TNF, IL-1, and IL-12/23 pathways operating in both diseases⁸.

Four patients showed an association of HS and SAPHO syndrome, another disease entity in which dysregulated innate immunity has been advocated²³. As well, the parallel courses of HS, neutrophilic dermatosis, and SpA in 2 other patients, who showed increased levels of inflammatory biomarkers such as CRP, also provide additional support for this latter hypothesis.

SpA encompasses a group of inflammatory conditions that share an association with HLA-B27 positivity; the same pattern of peripheral joint involvement with asymmetrical arthritis, predominantly of the lower limbs; and the possible occurrence of sacroiliitis, spondylitis, enthesitis, and uveitis. The exact etiology and pathogenesis of SpA remains unclear, but evidence supports the role of genetic background together with environmental factors, among

which smoking appears to be important^{24,25,26}. Likewise, the mechanisms underlying the preferential association of HS and SpA remain unclear. We lack evidence of linkage disequilibrium between any candidate gene identified in SpA and identified mutations of the gamma-secretase complex in familial cases of HS²⁷.

Regarding environmental factors, our cohort of patients with HS featured a high proportion of obesity and smoking. This finding is not unexpected, because cigarette smoking is a recognized risk factor for both the development of HS and its severe course, and obesity has also been identified as a risk factor^{2,3}. Interestingly, studies have shown that smoking is a risk factor for the onset and severity of SpA, psoriatic arthritis (PsA)^{28,29,30}, and Crohn disease^{31,32}, which highlights the complex interaction between environmental factors and genetic predisposition for these conditions. Unfortunately, we did not record sufficient data in the whole group of patients with HS (n = 640) to search for risk factors of SpA.

The role of other environmental triggers, such as microbial products, is also hypothetical. Bacterial colonization of HS skin lesions generates significant amounts of bacterial fragments, which may behave as antigenic stimuli leading to exaggerated innate immune responses in genetically susceptible individuals³³. Our findings might provide additional support for SpA resulting from interactions between susceptibility genes, bacteria, and the immune system³⁴. This hypothesis is further supported by our observation of SAPHO syndrome in 4 patients with HS, which was previously reported⁹. Indeed, SAPHO syndrome is considered by some to represent a form of reactive osteitis to bacterial agents, such as *Propionibacterium acnes* and coagulase-negative staphylococci, sometimes found in the bone lesions³⁵.

The onset of HS preceded that of joint symptoms in most cases, which is seen in other diseases, such as psoriasis, as recently emphasized in a large cohort of patients with psoriasis and recent inflammatory back pain²⁰. This predominant scenario supports the need for early detection of SpA in patients with HS, a procedure that ideally relies on awareness by clinicians of the association and on transdisciplinary dermatology-rheumatology networks that have also been stressed in other settings, such as PsA³⁶.

We found that prevalence of inflammatory arthritis in patients with HS is likely increased in patients with severe HS and that SpA was the predominant feature in these patients. Although mechanisms underlying this preferential association are likely complex, the shared pathophysiologic features of dysregulated innate immune response and the role of microbial triggers suggests further prospective population-based studies in patients with HS to address the true prevalence of SpA in HS, as well as genetic and mechanistic investigations to better understand its physiopathological bases.

ACKNOWLEDGMENT

The authors thank the patients for their participation in this study.

REFERENCES

1. Kurzen H, Kurokawa I, Jemec GB, Emtestam L, Sellheyer K, Giamarellos-Bourboulis EJ, et al. What causes hidradenitis suppurativa? *Exp Dermatol* 2008;17:455-6; discussion 457-72.
2. Jemec GB. Clinical practice. Hidradenitis suppurativa. *N Engl J Med* 2012;366:158-64.
3. Revuz J. Hidradenitis suppurativa. *J Eur Acad Dermatol Venereol* 2009;23:985-98.
4. Marzano AV, Trevisan V, Gattorno M, Ceccherini I, De Simone C, Crosti C. Pyogenic arthritis, pyoderma gangrenosum, acne, and hidradenitis suppurativa (PAPASH): a new autoinflammatory syndrome associated with a novel mutation of the PSTPIP1 gene. *JAMA Dermatol* 2013;149:762-4.
5. Braun-Falco M, Kovnerystyy O, Lohse P, Ruzicka T. Pyoderma gangrenosum, acne, and suppurative hidradenitis (PASH)—a new autoinflammatory syndrome distinct from PAPA syndrome. *J Am Acad Dermatol* 2012;66:409-15.
6. Marzano AV, Menicanti C, Crosti C, Trevisan V. Neutrophilic dermatoses and inflammatory bowel diseases. *G Ital Dermatol Venereol* 2013;148:185-96.
7. van der Zee HH, van der Woude CJ, Florencia EF, Prens EP. Hidradenitis suppurativa and inflammatory bowel disease: are they associated? Results of a pilot study. *Br J Dermatol* 2010;162:195-7.
8. van der Zee HH, de Ruiter L, van den Broecke DG, Dik WA, Laman JD, Prens EP. Elevated levels of tumour necrosis factor (TNF)- α , interleukin (IL)-1 β and IL-10 in hidradenitis suppurativa skin: a rationale for targeting TNF- α and IL-1 β . *Br J Dermatol* 2011;164:1292-8.
9. De Souza A, Solomon GE, Strober BE. SAPHO syndrome associated with hidradenitis suppurativa successfully treated with infliximab and methotrexate. *Bull NYU Hosp Jt Dis* 2011;69:185-7.
10. Leybishkis B, Fasseas P, Ryan KF, Roy R. Hidradenitis suppurativa and acne conglobata associated with spondyloarthropathy. *Am J Med Sci* 2001;321:195-7.
11. Marquardt AL, Hackshaw KV. Reactive arthritis associated with hidradenitis suppurativa. *J Natl Med Assoc* 2009;101:367-9.
12. Fioravanti A, Laurafflori M, Guidelli GM, Giordano N. Dactylitis as a first manifestation of arthritis associated with hidradenitis suppurativa. *Indian J Dermatol Venereol Leprol* 2011;77:74-6.
13. Rosner IA, Richter DE, Huettner TL, Kuffner GH, Wisniewski JJ, Burg CG. Spondyloarthropathy associated with hidradenitis suppurative and acne conglobata. *Ann Intern Med* 1982;97:520-5.
14. Rosner IA, Burg CG, Wisniewski JJ, Schacter BZ, Richter DE. The clinical spectrum of the arthropathy associated with hidradenitis suppurativa and acne conglobata. *J Rheumatol* 1993;20:684-7.
15. Bhalla R, Sequeira W. Arthritis associated with hidradenitis suppurativa. *Ann Rheum Dis* 1994;53:64-6.
16. Dougados M, Baeten D. Spondyloarthritis. *Lancet* 2011; 377:2127-37.
17. Monnet D, Kadi A, Izac B, Lebrun N, Letourneur F, Zinovieva E, et al. Association between the IL-1 family gene cluster and spondyloarthritis. *Ann Rheum Dis* 2012;71:885-90.
18. Calin A, Porta J, Fries JF, Schurman DJ. Clinical history as a screening test for ankylosing spondylitis. *JAMA* 1977;237:2613-4.
19. Rudwaleit M, Metter A, Listing J, Sieper J, Braun J. Inflammatory back pain in ankylosing spondylitis: a reassessment of the clinical history for application as classification and diagnostic criteria. *Arthritis Rheum* 2006;54:569-78.
20. Richette P, Tubach F, Breban M, Viguier M, Bachelez H, Bardin T, et al. Psoriasis and phenotype of patients with early inflammatory back pain. *Ann Rheum Dis* 2013;72:566-71.
21. Saraux A, Guillemin F, Guggenbuhl P, Roux CH, Fardellone P, Le Bihan E, et al. Prevalence of spondyloarthropathies in France: 2001. *Ann Rheum Dis* 2005;64:1431-5.
22. Roux CH, Saraux A, Le Bihan E, Fardellone P, Guggenbuhl P, Fautrel B, et al. Rheumatoid arthritis and spondyloarthropathies: geographical variations in prevalence in France. *J Rheumatol* 2007;34:117-22.
23. Carneiro S, Sampaio-Barros PD. SAPHO Syndrome. *Rheum Dis Clin North Am* 2013;39:401-18.
24. Sieper J, Rudwaleit M, Khan MA, Braun J. Concepts and epidemiology of spondyloarthritis. *Best Pract Res Clin Rheumatol* 2006;20:401-17.
25. Braun J, Sieper J, Zink A. The risks of smoking in patients with spondyloarthritis. *Ann Rheum Dis* 2012;71:791-2.
26. Braem K, Lories RJ. Insights into the pathophysiology of ankylosing spondylitis: contributions from animal models. *Joint Bone Spine* 2012;79:243-8.
27. Pink AE, Simpson MA, Desai N, Trembath RC, Barker JN. γ -Secretase mutations in hidradenitis suppurativa: new insights into disease pathogenesis. *J Invest Dermatol* 2013;133:601-7.
28. Chung HY, Machado P, van der Heijde D, D'Agostino MA, Dougados M. Smokers in early axial spondyloarthritis have earlier disease onset, more disease activity, inflammation and damage, and poorer function and health-related quality of life: results from the DESIR cohort. *Ann Rheum Dis* 2012;71:809-16.
29. Li W, Han J, Qureshi AA. Smoking and risk of incident psoriatic arthritis in US women. *Ann Rheum Dis* 2012;71:804-8.
30. Lories RJ, de Vlam K. Is psoriatic arthritis a result of abnormalities in acquired or innate immunity? *Curr Rheumatol Rep* 2012; 14:375-82.
31. Birrenbach T, Bocker U. Inflammatory bowel disease and smoking: a review of epidemiology, pathophysiology, and therapeutic implications. *Inflamm Bowel Dis* 2004;10:848-59.
32. Higuchi LM, Khalili H, Chan AT, Richter JM, Bousvaros A, Fuchs CS. A prospective study of cigarette smoking and the risk of inflammatory bowel disease in women. *Am J Gastroenterol* 2012;107:1399-406.
33. Roussomoustakaki M, Dimoulios P, Chatzicostas C, Kritikos HD, Romanos J, Panayiotides JG, et al. Hidradenitis suppurativa associated with Crohn's disease and spondyloarthropathy: response to anti-TNF therapy. *J Gastroenterol* 2003;38:1000-4.
34. Gaston H. Mechanisms of disease: the immunopathogenesis of spondyloarthropathies. *Nat Clin Pract Rheumatol* 2006;2:383-92.
35. Assmann G, Simon P. The SAPHO syndrome—are microbes involved? *Best Pract Res Clin Rheumatol* 2011;25:423-34.
36. Tinazzi I, Adami S, Zanolini EM, Caimmi C, Confente S, Girolomoni G, et al. The early psoriatic arthritis screening questionnaire: a simple and fast method for the identification of arthritis in patients with psoriasis. *Rheumatology* 2012;51:2058-63.