

# The Microanatomic Basis of Finger Clubbing — A High-resolution Magnetic Resonance Imaging Study

Junichi Nakamura, Nicola Ann Halliday, Eiji Fukuba, Aleksandra Radjenovic, Steven F. Tanner, Paul Emery, Dennis McGonagle, and Ai Lyn Tan

**ABSTRACT. Objective.** Hypervascularization in finger clubbing is recognized, but its microanatomical basis remains unclear. This pilot descriptive study used magnetic resonance imaging (MRI) to explore this further.

**Methods.** High-resolution MRI acquired with contrast agent was carried out in 4 patients with finger clubbing and 4 healthy volunteers. The anatomy of the nail bed, capsular structures, and bony changes were described.

**Results.** Marked nail bed thickening and contrast enhancement was noted in all clubbed fingers, with bone edema in 3 of the 4 patients. None of the healthy subjects had similar abnormalities.

**Conclusion.** This confirms that hypervascularization of the nail bed observed in the microanatomy on high-resolution MRI is associated with clubbed appearances of the nails. (J Rheumatol First Release Jan 15 2014; doi:10.3899/jrheum.130823)

## Key Indexing Terms:

FINGER CLUBBING  
LUNG

MAGNETIC RESONANCE IMAGING  
RESPIRATORY

NAIL  
CANCER

Finger clubbing is recognized as the oldest clinical sign in medicine<sup>1</sup>. The presence of finger clubbing is associated with a variety of diseases, including respiratory disease, cyanotic congenital heart disease, and malignant disease. Despite the well-known prevalence of finger clubbing, its

microanatomic basis, specifically in relation to respiratory diseases, remains incompletely understood.

High-resolution magnetic resonance imaging (MRI) has been used to study small joint arthritis involving the hands<sup>2,3,4</sup>. The importance of peripheral hypervascularization in finger clubbing is widely recognized<sup>5</sup>. Our small pilot study used high-resolution MRI to compare patients with finger clubbing against healthy subjects to gain better insights into the microanatomic basis for finger clubbing.

From the UK National Institute for Health Research (NIHR) Leeds Musculoskeletal Biomedical Research Unit, Chapel Allerton Hospital; Leeds Institute of Rheumatic and Musculoskeletal Medicine, University of Leeds, Leeds, UK; Department of Orthopaedic Surgery, Graduate School of Medicine, Chiba University, Chiba, Japan; Department of Radiology, Faculty of Medicine, Shimane University, Shimane, Japan; Medical Physics and Engineering, Leeds Teaching Hospitals UK National Health Service (NHS) Trust, Leeds, UK.

Funded by the Medical Research Council and the Arthritis Research UK.

J. Nakamura, MD, Assistant Professor, NIHR Leeds Musculoskeletal Biomedical Research Unit, Chapel Allerton Hospital, Leeds Institute of Rheumatic and Musculoskeletal Medicine, University of Leeds, and Department of Orthopaedic Surgery, Graduate School of Medicine, Chiba University; N.A. Halliday, PhD, Research Assistant, NIHR Leeds Musculoskeletal Biomedical Research Unit, Chapel Allerton Hospital; E. Fukuba, MD, Assistant Professor, NIHR Leeds Musculoskeletal Biomedical Research Unit, Chapel Allerton Hospital, Leeds Institute of Rheumatic and Musculoskeletal Medicine, University of Leeds, and Department of Radiology, Faculty of Medicine, Shimane University; A. Radjenovic, PhD, Senior Translational Research Fellow, NIHR Leeds Musculoskeletal Biomedical Research Unit, Chapel Allerton Hospital; S.F. Tanner, PhD, Medical Physicist, Medical Physics and Engineering, Leeds Teaching Hospitals NHS Trust; P. Emery, MA, MD, FRCP, Professor of Rheumatology; D. McGonagle, PhD, FRCP, Professor in Regenerative Medicine; A.L. Tan, MD, MRCP, Associate Professor and Consultant in Rheumatology, NIHR Clinician Scientist, NIHR Leeds Musculoskeletal Biomedical Research Unit, Chapel Allerton Hospital and Leeds Institute of Rheumatic and Musculoskeletal Medicine, University of Leeds.

Address correspondence to Dr. A.L. Tan, Leeds Institute of Rheumatic and Musculoskeletal Medicine, Chapel Allerton Hospital, Chapeltown Road, Leeds LS7 4SA, UK. E-mail: a.l.tan@leeds.ac.uk

Accepted for publication November 8, 2013.

## MATERIALS AND METHODS

**Study subjects.** Eight subjects participated in the study: 4 with finger clubbing (2 males, 2 females; mean age 43 yrs, range: 23–63 yrs) and 4 healthy volunteers (2 males, 2 females; mean age 38 yrs, range: 32–47 yrs). The study was approved by the local ethics committee and all subjects gave their informed consent. Patients with finger clubbing (clinically bulbous enlargement of the terminal phalanx, increased fluctuation of the nail bed, and loss of the angle between the nail and the basal tissues) were referred from the respiratory clinics (n = 2 with cystic fibrosis, n = 2 with fibrosing alveolitis; mean disease duration 9 yrs). The healthy volunteers were members of staff from the rheumatology department who responded to posters about the study, with no nail disease or illness. The groups were not matched by age or sex.

**High-resolution MRI.** The finger that appeared most clubbed in each patient and the index finger of the dominant hand of the healthy volunteers were selected for imaging. One finger of each subject was imaged by high-resolution MRI using a 1.5T Gyroscan ACS-NT scanner (Philips Medical Systems). Subjects were placed in the prone position with the hand extended in front of the body. A 23-mm diameter microscopy MRI surface coil was placed on a distal interphalangeal joint including the nail, as described<sup>2</sup>. The protocol included T1-weighted sagittal and axial spin-echo, T2-weighted fat-suppressed spin-echo, coronal proton density-weighted 2-dimensional (2-D) spin-echo, 3-D gradient-echo sagittal images acquired using a water-selective radiofrequency excitation pulse, and axial and sagittal T1-weighted fat-suppressed spin-echo images after intravenous injection of 10 ml of the contrast agent gadolinium diethylene-triaminepen-

taacetic acid. The imaging sequences were as published<sup>2</sup>. The measured slices were 1 mm thick, and therefore the acquired in-plane pixel dimension was between 160–200 mm, with a displayed pixel dimension of 80–100 mm.

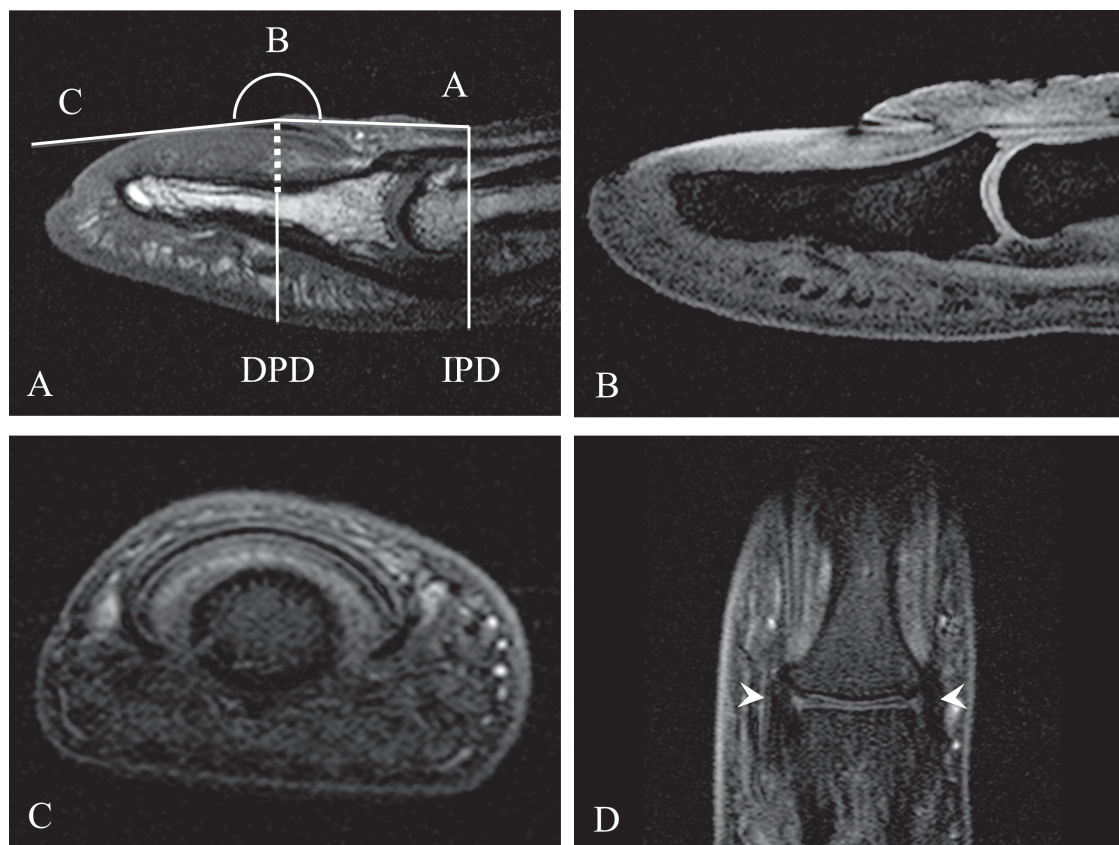
**Analysis of MR images.** MR images were analyzed using a commercially available image analysis software package Analyze (Mayo Clinic, BIR). The observers were blinded to the clinical status of the study subjects. The following structures were evaluated by consensus by a radiologist (EF) and a rheumatologist (JN): nail bed, nail root, collateral ligaments, extensor tendons, bone edema, erosions, and enthesophytes, as described<sup>3</sup>. The nail bed was defined as soft tissue between the nail plate and the distal phalanx, and nail root was defined as the base or origin of the nail underneath the skin. The results were recorded in a dichotomous manner (present/absent). The profile angle<sup>6</sup>, phalangeal depth ratio<sup>7</sup>, and thickness of nail bed were measured using the line profile tool in Analyze by a rheumatologist (JN) and a musculoskeletal research assistant (NAH) by consensus about the site of measurement (Figure 1A). Profile angle (ABC) was constructed by a line AB drawn from the distal digital skin crease to the cuticle and a line BC from the cuticle through a point C of contact with the nail bed. Phalangeal depth ratio (DPD/IPD ratio) was calculated by measuring the distal interphalangeal depth (IPD) at the distal digital skin crease and the distal phalangeal depth (DPD) at the proximal regions of the nail plate just before the cuticle disappears. The thickness of nail bed measured at the point where the nail meets the skin forms part of the DPD.

**Statistical analysis.** Because ours was a descriptive pilot study with a small sample size, the results of significance tests are presented as a guideline only. Results are presented as medians and ranges, and pairwise analyses were performed using the Mann-Whitney test. No correction for multiple testing was performed. No intraobserver or interobserver reliabilities were performed because the scoring was agreed by consensus between 2 readers for each component.

## RESULTS

The fingers scanned in the clubbed cohort included 2 right index, 1 right middle, and 1 left index fingers. The patients with finger clubbing did not have any history of joint pain, and therefore, did not have hypertrophic osteoarthropathy. The healthy volunteers included 3 right index and 1 left index fingers.

**Measurements of finger clubbing.** The measurements were obtained from the MR images. The profile angle, phalangeal depth ratio, and thickness of nail bed were greater in patients with finger clubbing than in healthy subjects. The median profile angle was 186° (range: 179–188°) in finger clubbing and 176° (range: 154–179°) in healthy subjects ( $p = 0.029$ ).



**Figure 1.** Magnetic resonance imaging (MRI)-based measurement and features of normal fingers. (A) MRI of a midsagittal image of a clubbed finger of a 62-year-old female demonstrating the various measurements made. Profile angle (ABC) is formed by lines AB and BC. Phalangeal depth ratio is calculated by distal interphalangeal depth (IPD) and distal phalangeal depth (DPD) (DPD/IPD). Thickness of nail bed is represented by the dotted line. (B) MRI of a water-selective excitation sagittal image of a healthy finger of a 47-year-old female. (C) MRI of a T1-weighted fat-suppressed post-gadolinium axial image of a healthy finger of a 32-year-old male. (D) MRI of a T1-weighted fat-suppressed post-gadolinium coronal image of the same finger demonstrates the collateral ligaments (arrowheads).

Median phalangeal depth ratio was 1.04 (range: 1.02–1.10) in finger clubbing and 0.82 (range: 0.76–0.88) in healthy subjects ( $p = 0.029$ ). The median thickness of nail bed was 3.4 mm (range: 3.2–3.8 mm) in finger clubbing and 1.8 mm (range: 1.1–1.9 mm) in healthy subjects ( $p = 0.029$ ).

**Nail bed and the nail root changes.** Nail bed changes were common in all clubbed fingers (Figure 2A-D). The soft tissue edema and hypertrophy with contrast enhancement was extensive and completely involved the nail bed in clubbing. The nail roots adjacent to the extensor tendon entheses were involved in 3 of the 4 clubbed nails (Figure 2B). None of the 4 healthy subjects had such gross edema or hypertrophy (Figure 1B-D), except 1 showing slight enhancement at the nail bed, but the nail bed was not thickened (Figure 1C).

**Bone changes.** Bone edema was observed in 3 of 4 patients with finger clubbing. One had diffuse bone edema involving the whole of the distal phalanx (Figure 2D) and 2 (age 56 and 62 yrs old) had focal bone edema around enthesophytes at the extensor tendon insertion and at the collateral ligament insertion (with an associated erosion at the origin

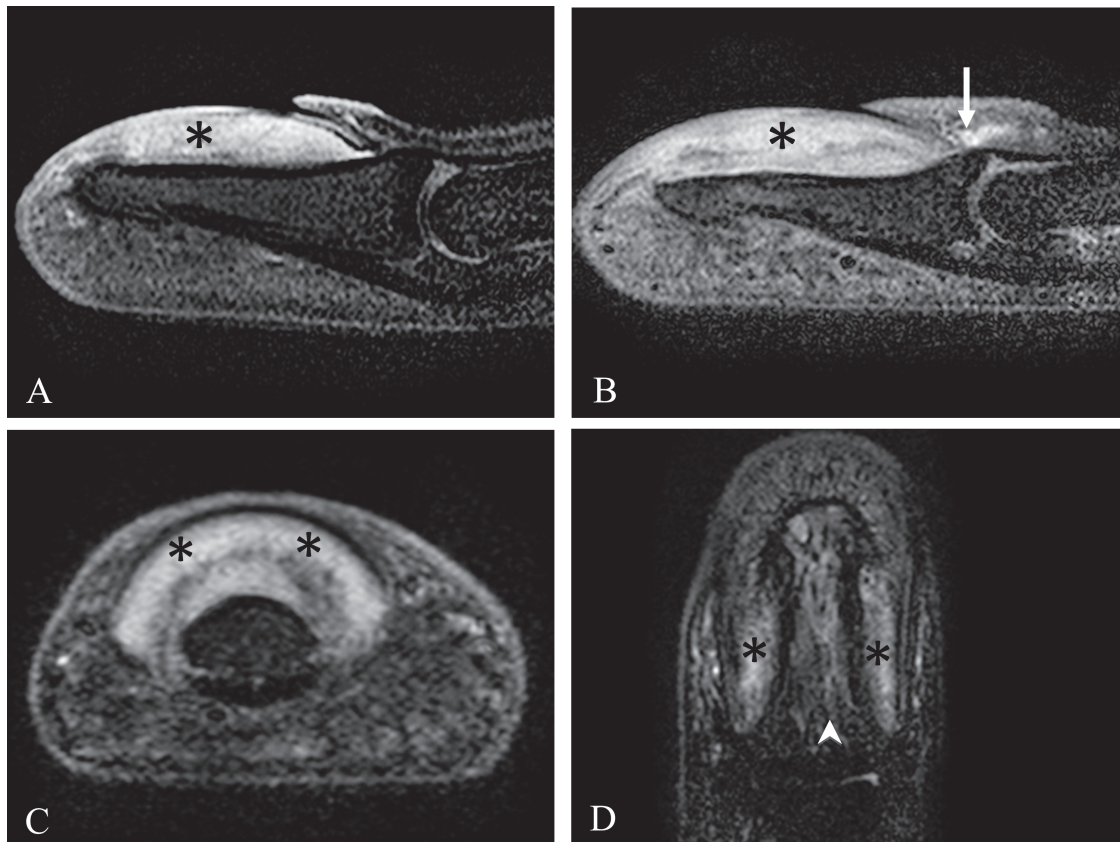
of the ligament). None of the 4 healthy subjects had any bone changes.

**Enthesal changes.** The collateral ligaments were thickened but without contrast enhancement in 1 clubbed finger. None of the 4 healthy subjects had enthesal abnormalities, except 1 female (42 yrs old) showing slight change at 1 side of the collateral ligaments.

## DISCUSSION

To our knowledge, this is the first study using high-resolution MRI to investigate the microanatomic basis for finger clubbing. Ultrasound has been used to evaluate finger clubbing, but there have not been any comprehensive MRI studies for evaluating finger clubbing, except for 1 case report using contrast-enhanced 3-D MR angiography describing hypervascularization in the terminal digits in clubbing<sup>5,8</sup>.

Reports using various methods to study finger clubbing including scintigraphy, thermography, plethysmography, and capillaroscopy have suggested increased blood flow in the finger<sup>9</sup>. The etiology of finger clubbing has been linked



**Figure 2.** Magnetic resonance imaging (MRI) feature of finger clubbing. T1-weighted fat-suppressed post-gadolinium images of finger clubbing in (A) a 57-year-old female (sagittal) and (B) and (C) a 29-year-old female (sagittal and axial), demonstrating thickened tissue under the nail bed with diffuse contrast enhancement (asterisks). (B) The nail root was thickened with contrast enhancement (arrow). (D) MRI of a 23-year-old male with finger clubbing. T1-weighted fat-suppressed post-gadolinium coronal image of the finger demonstrates a diffuse distal phalanx bone edema (arrow head) in addition to nail bed enhancement (asterisks) when compared to a healthy finger, such as in Figure 1D.

to systemic shunting of platelets and their products, including vascular endothelial growth factor (VEGF), with subsequent hypervascularization<sup>10,11,12</sup>. This is supported by our study where diffuse edema with contrast enhancement at the nail bed was striking on high-resolution MRI<sup>11</sup>, providing an anatomic link between possible peripheral hypervascularization and finger clubbing. Finger clubbing is associated with increased glucose metabolism in the nail bed<sup>13</sup>, and has been known to resolve when the underlying causative illness is treated<sup>14,15</sup>, likely reflecting the corresponding reduction in the level of VEGF driving the hypervascularization or inflammation<sup>16</sup>.

Angiography has shown the increase in the number and size of the vessels at the distal end of clubbed fingers<sup>17</sup>, and nail fold capillaroscopy has also shown tortuous abnormal capillaries in the nail bed of clubbed fingers<sup>18</sup>. Therefore, as a result of tissue growth factors that cause hypervascularization and tissue hypertrophy, the thickened nail bed appears to push the growing nail upward with secondary curving of the nail in finger clubbing (Figure 3).

Clubbing is associated with an arthropathy called hypertrophic osteoarthropathy syndrome<sup>19</sup>. Although none of our cases had hypertrophic osteoarthropathy, they exhibited similar features, including enthesal new bone formation and bone edema, which is known to be linked to periostitis<sup>20</sup>. The bone edema changes reported likely represent an early MRI manifestation of the vascular related pathology. However, 2 of the patients with bone edema and enthesophytes were over the age of 40 years and these features may be related to signs of osteoarthritis (OA)<sup>2</sup>, although both still had thickening of the nail bed with contrast enhancement, which is not seen with OA.

None of the healthy subjects showed the features

observed in the clubbed fingers. One healthy subject who was 42 years old showed slight thickening of 1 collateral ligament, which was previously reported in those over the age of 40 years, and may be an early sign of OA<sup>2</sup>.

The main limitation of our study was the small number of subjects who had MRI scans of their fingers. Nevertheless, the high-resolution nature of the MRI allowed detailed depiction of changes in small regions of interest in the fingers, and consistent differences between finger clubbing and a healthy finger and nail were discernible.

Plain radiography was not part of our study because it was considered inadequate for the purpose of the current objective, in terms of its lack of multiplanar imaging capability and inability to study inflammatory processes in the soft tissues or bone.

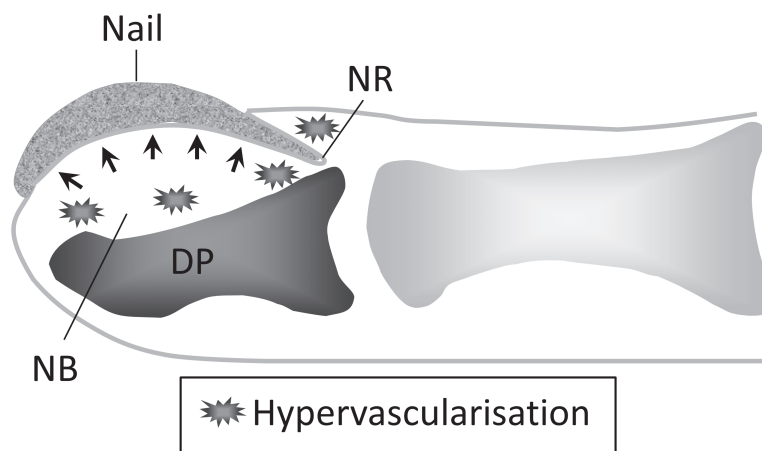
Our small study used high-resolution MRI in patients with finger clubbing to better define its microanatomic basis. The findings suggest the possible role of increased blood flow in the nail bed with tissue hypertrophy and secondary curvature of the nail in clubbing. Further studies, in particular longitudinal studies involving therapy for the underlying systemic illness associated with finger clubbing, are required to improve understanding of the oldest sign in medicine.

#### ACKNOWLEDGMENTS

The authors thank Drs. Daniel Peckham and Michael Henry for referring patients for the study, and all who volunteered for the study.

#### REFERENCES

1. Myers KA, Farquhar DR. The rational clinical examination. Does this patient have clubbing? *JAMA* 2001;286:341-7.
2. Tan AL, Grainger AJ, Tanner SF, Shelley DM, Pease C, Emery P, et al. High-resolution magnetic resonance imaging for the assessment



*Figure 3.* Mechanism of finger clubbing. Areas of hypervascularization, as demonstrated by MRI-determined edema within the bone, and soft tissue in the nail bed (NB) and the nail root (NR) associated with increased pro-angiogenic factors, including vascular endothelial growth factor. The subsequent tissue hypertrophy at the nail bed pushes the growth of the nail dorsally (arrows), resulting in the characteristic curvature of nail clubbing. DP: distal phalanx.

- of hand osteoarthritis. *Arthritis Rheum* 2005;52:2355-65.
3. Tan AL, Grainger AJ, Tanner SF, Emery P, McGonagle D. A high-resolution magnetic resonance imaging study of distal interphalangeal joint arthropathy in psoriatic arthritis and osteoarthritis: are they the same? *Arthritis Rheum* 2006;54:1328-33.
  4. McGonagle D, Ash ZR, Hodgson RJ, Emery P, Radjenovic A. MRI for the assessment and monitoring of RA—what can it tell us? *Nat Rev Rheumatol* 2011;7:185-9.
  5. Wiesmann F, Beer M, Krause U, Pabst T, Kenn W, Hahn D, et al. Clubbing due to peripheral hypervascularization: recognition by contrast-enhanced, three-dimensional magnetic resonance angiography. *Circulation* 2001;104:2503.
  6. Lovibond JL. Diagnosis of clubbed fingers. *Lancet* 1938;231:363-4.
  7. Baughman RP, Gunther KL, Buchsbaum JA, Lower EE. Prevalence of digital clubbing in bronchogenic carcinoma by a new digital index. *Clin Exp Rheumatol* 1998;16:21-6.
  8. Roy HS, Wang Z, Ran H, Song W, Zheng Y. Diagnosis of digital clubbing by high-frequency ultrasound imaging. *Int J Dermatol* 2013;52:1-5.
  9. Fam AG, Chin-Sang H, Ramsay CA. Pachydermoperiostosis: scintigraphic, thermographic, plethysmographic, and capillaroscopic observations. *Ann Rheum Dis* 1983;42:98-102.
  10. Dickinson CJ, Martin JF. Megakaryocytes and platelet clumps as the cause of finger clubbing. *Lancet* 1987;2:1434-5.
  11. Fox SB, Day CA, Gatter KC. Association between platelet microthrombi and finger clubbing. *Lancet* 1991;338:313-4.
  12. Martinez-Lavin M. Exploring the cause of the most ancient clinical sign of medicine: finger clubbing. *Semin Arthritis Rheum* 2007;36:380-5.
  13. Ward RW, Chin R Jr, Keyes JW Jr, Haponik EF. Digital clubbing. Demonstration with positron emission tomography. *Chest* 1995;107:1172-3.
  14. Faller BA, Atkinson JP. Images in clinical medicine. New-onset clubbing associated with lung cancer. *N Engl J Med* 2008;359:e15.
  15. Ishikawa M, Okada J, Kondo H. Takayasu's arteritis with transient clubbed finger. *Clin Exp Rheumatol* 1999;17:629-30.
  16. Olan F, Portela M, Navarro C, Gaxiola M, Silveira LH, Ruiz V, et al. Circulating vascular endothelial growth factor concentrations in a case of pulmonary hypertrophic osteoarthropathy. Correlation with disease activity. *J Rheumatol* 2004;31:614-6.
  17. Takaro T, Hines EA Jr. Digital arteriography in occlusive arterial disease and clubbing of the fingers. *Circulation* 1967;35:682-9.
  18. Jajic Z, Jajic I, Nemcic T. Primary hypertrophic osteoarthropathy: clinical, radiologic, and scintigraphic characteristics. *Arch Med Res* 2001;32:136-42.
  19. Martinez-Lavin M, Matucci-Cerinic M, Jajic I, Pineda C. Hypertrophic osteoarthropathy: consensus on its definition, classification, assessment and diagnostic criteria. *J Rheumatol* 1993;20:1386-7.
  20. Loredó R, Pathria MN, Salonen D, Resnick D. Magnetic resonance imaging in pachydermoperiostosis. *Clin Imaging* 1996;20:212-8.