

Persistent or New Onset Microscopic Hematuria in Patients with Small Vessel Vasculitis in Remission: Findings on Renal Biopsy

DUVURU GEETHA, PHILIP SEO, CARLA ELLIS, MICHAEL KUPERMAN, and STUART M. LEVINE

ABSTRACT. *Objective.* Hematuria is considered a sign of active renal disease in patients with small-vessel vasculitis. In patients who are in apparent clinical remission, presence of persistent or new-onset microscopic hematuria may reflect active vasculitis, damage, or other glomerular pathology.

Methods. We identified 74 patients from the Johns Hopkins Renal Pathology database between 1995 and 2009 with the diagnosis of pauciimmune glomerulonephritis (GN). Among them we identified 9 who were in clinical remission and underwent a renal biopsy for evaluation of persistent or new-onset hematuria.

Results. Nine patients with small-vessel vasculitis, 8 antineutrophil cytoplasmic antibody (ANCA)-positive and 1 ANCA-negative, underwent a renal biopsy at variable time periods after remission of vasculitis (6 to 164 months) for persistent microscopic hematuria (n = 6) or new-onset microscopic hematuria (n = 3). All patients were in apparent clinical remission at the time of renal biopsy. Of the 3 patients presenting with new-onset hematuria, 2 had crescentic IgA nephropathy and 1 had healed crescentic pauciimmune GN. Of the 6 patients with persistent hematuria, 2 had arteriosclerosis, 2 had focal segmental glomerulosclerosis, and 2 had global and segmental glomerulosclerosis and healed crescentic GN, and none had active vasculitis.

Conclusion. Microscopic hematuria in patients with renal vasculitis otherwise in remission could represent chronic glomerular injury from prior episode of vasculitis or may represent new glomerular pathology. Renal biopsy should be considered in these patients to guide therapy. (J Rheumatol First Release June 1 2012; doi:10.3899/jrheum.111608)

Key Indexing Terms:
HEMATURIA

VASCULITIS

RENAL BIOPSY

The small-vessel vasculitides make up a heterogeneous group of uncommon disorders that are prone to cycles of remission and relapse. An important subset of these diseases is strongly associated with the presence of antineutrophil cytoplasmic autoantibodies (ANCA). These vasculitides include granulomatosis with polyangiitis (GPA), microscopic polyangiitis (MPA), and Churg-Strauss syndrome. The prevalence of ANCA-associated vasculitis (AAV) has increased in recent years, an observation that is due in part to increased recognition of these complex diseases. AAV have an incidence of only 20 per million population per year¹; however, it remains the most common cause of rapidly progressive glomerulonephritis (GN)-induced endstage renal disease (ESRD)². Although the treatment and outcome of AAV has improved

considerably, over 20% of patients with pauciimmune renal vasculitis develop ESRD³.

Renal involvement in systemic vasculitis often manifests as microscopic hematuria, with red blood cell casts, and proteinuria with or without elevation in serum creatinine. The typical histopathology is a focal and necrotizing crescentic GN with a minimal amount of immunoglobulin deposition in vessel walls. Treatment response is evaluated clinically and by measurement of serum creatinine and inflammatory and urinary markers, but the time course for resolution of these markers has not been described.

In clinical practice, remission of renal vasculitis is defined as stabilization or improvement in serum creatinine and resolution of hematuria. In clinical trials of vasculitis, tapering of corticosteroids begins in the first month after the disease is stable. However, this practice of tapering corticosteroids in the presence of hematuria is not accepted uniformly in clinical practice, and patients either continue the same immunosuppressive regimen or there is escalation in immunosuppression (personal observation). In a similar fashion, new-onset hematuria in patients with vasculitis is often felt to represent a renal flare once urologic causes are excluded. The best approach to resolve the controversy of whether hematuria in these settings reflects disease activity or damage or a different disease process is to perform repeat renal biopsy in patients

From the Division of Nephrology, Division of Rheumatology, and Department of Pathology, Johns Hopkins University School of Medicine, Baltimore, Maryland, USA.

D. Geetha, MD, FASN, MRCP UK, Division of Nephrology; P. Seo, MD, MHS, Division of Rheumatology; C. Ellis, MD; M. Kuperman, MD, Department of Pathology; S.M. Levine, MD, Division of Rheumatology, Johns Hopkins University School of Medicine.

Address correspondence to Dr. D. Geetha, Johns Hopkins Bayview Medical Center, 301 Mason Lord Drive, Room 2509, Baltimore, MD 21224, USA. E-mail: gduvura@jhmi.edu

Accepted for publication March 15, 2012.

Personal non-commercial use only. The Journal of Rheumatology Copyright © 2012. All rights reserved.

who have persistent hematuria or new-onset hematuria but are otherwise in remission. Because of a lack of such studies, clinical decision making has relied on circumstantial data. Magrey, *et al* reported persistent hematuria for periods ranging from 6 months to over 5 years in 10 out of 25 patients with GPA and renal vasculitis⁴. They concluded that persistent hematuria in these 10 patients could be due to damage based on circumstantial evidence that supported achievement of clinical remission in these patients. However, only 2 of these patients were confirmed to have inactive disease by renal biopsy. We report from our cohort of 74 patients with pauci-immune GN findings on renal biopsy in 9 patients who had either persistent hematuria or new-onset hematuria while their vasculitis was otherwise in remission.

MATERIALS AND METHODS

Study population. The study population included all adult patients with biopsy-proven pauciimmune crescentic GN from 1995 to 2009 entered in the Johns Hopkins Renal Pathology database. "Pauciimmune" was defined as "the intensity of glomerular immunoglobulin staining by direct immunofluorescence assay in renal sections [was] negative to 1+, from a staining scale of 0 to 4+." We used the clinical records and biopsy database to identify patients who underwent repeat renal biopsy for persistent hematuria or new-onset hematuria and who were in remission of their vasculitis by all other criteria. The study protocol was approved by the Institutional Review Board.

Data acquisition. Data regarding patient demographics at the time of diagnosis, organ involvement, Birmingham Vasculitis Assessment Score/Wegener's granulomatosis (BVAS/WG)⁵ at the time of diagnosis calculated by review of the history and physical examination at the time of presentation, peak serum creatinine when the disease was active, serum creatinine during sustained remission, urinalysis at the time of remission and during sustained remission, time to remission, serum creatinine, inflammatory markers, ANCA status, findings on second biopsy, occurrence of disease relapse, and serum creatinine and proteinuria at last followup were collected. Remission was defined as the first medical record entry where the patient had a BVAS/WG score of 0, without symptoms for the last 30 days. Renal remission was defined as stabilization or improvement in serum creatinine and resolution of hematuria. Hematuria was defined as > 5 red blood cells in urine per high-power field. Relapse was defined by BVAS/WG score > 1.

Statistical analysis. We summarized descriptive data as median and range.

RESULTS

We identified 302 patients from the Johns Hopkins Renal Pathology Database between 1995 and 2009 with the diagnosis of pauciimmune GN. Seventy-four patients who had followup clinical and laboratory data were included in our study. Among these 74 patients, 58 achieved remission with a BVAS/WG score of zero and 7 did not achieve remission due to progressive disease resulting in ESRD (n = 5) or death (n = 2). The remaining 9 patients were in apparent clinical remission and were included in our study. Eight of them had a BVAS/WG score of 1 due to persistent or new-onset microscopic hematuria; 1 patient who had new-onset hematuria had a BVAS/WG score of 4. These 9 patients, 1 with a diagnosis of GPA and 8 with a diagnosis of MPA, underwent a renal biopsy for evaluation of either persistent (n = 6) or new-onset microscopic hematuria (n = 3). The red cells in urine were monomorphic in 8 patients and 1 patient had dysmorphic red

blood cells; no patient had red blood cell casts in the urine. Their demographic and clinical characteristics are described in Table 1. All patients, 6 men and 3 women, were white. One patient was ANCA-negative and the rest were ANCA-positive by both immunofluorescence and ELISA (1 cytoplasmic ANCA and PR3 ELISA-positive and 7 perinuclear ANCA and myeloperoxidase ELISA-positive). The median peak serum creatinine was 2.1 mg/dl (range 1.1–13.2 mg/dl). The median serum creatinine during sustained remission was 1.2 mg/dl (range 1.0–2.6 mg/dl). The median time to remission was 4 months (range 1–8 mo).

Six patients underwent repeat renal biopsy for evaluation of persistent hematuria at a median of 24 months from the first biopsy (range 6–51 mo) and 3 patients underwent renal biopsy for new-onset hematuria (2 repeat and 1 first biopsy). The median serum creatinine at the time of the second renal biopsy was 1.4 mg/dl (range 1–2.5 mg/dl). Erythrocyte sedimentation rate was normal in 5 patients at the time of the second biopsy and slightly elevated in the rest. Four patients were persistently positive for ANCA and the rest were ANCA-negative. One patient was receiving azathioprine and prednisone, 2 were receiving prednisone only, and the remaining 6 patients were receiving no immunosuppressive therapy at the time of the second biopsy.

Findings on the second renal biopsy are summarized in Table 2. The median number of glomeruli in these 9 biopsy specimens was 25 (range 7–72). Of the 6 patients with persistent hematuria, 2 had arteriosclerosis with no evidence of active vasculitis, 2 had chronic crescentic GN with fibrous crescents (Figure 1; with secondary focal and segmental glomerulosclerosis in 1 of them), 1 had secondary focal and segmental glomerulosclerosis and hypertensive renal disease, and 1 had global and segmental glomerulosclerosis. The most likely cause of the secondary focal and segmental sclerosis seen in 3 patients was their prior episode of renal vasculitis. Of the 3 patients presenting with new-onset hematuria, 2 had crescentic IgA nephropathy and 1 had healed crescentic pauci-immune GN with fibrous crescents. Among the 2 patients with crescentic IgA nephropathy, 1 had cellular crescents without necrotizing lesions in 3 of 24 glomeruli examined and the other had segmental necrosis and cellular crescents in 5 of 23 glomeruli; both had 3+ IgA mesangial staining on immunofluorescence. Electron microscopy was performed in 5 patients and in all, the glomerular basement membrane had a normal trilaminar structure, with normal thickness in 4 patients and variable thickness in 1 patient. In all 5 patients, the podocyte had focal foot process effacement. In 2 patients, the specimen for electron microscopy had no glomeruli and in the remaining 2 patients electron microscopy was not done. After the results of the second biopsy, the prednisone dose was reduced in the 2 patients taking prednisone at the time of the second biopsy, and the immunosuppression was left unchanged in 1 patient taking azathioprine and prednisone at the time of second biopsy. Of the remaining 6 patients not

Table 1. Patients' demographic and clinical characteristics.

Patient	Age at Diagnosis, yrs	Sex	ANCA Type	Disease	Organs Involved	BVAS/WG Score	Time to Remission, mo	Peak Serum Creatinine, mg/dl	Serum Creatinine During Sustained Remission, mg/dl
1	50	F	p-ANCA	MPA	PN, K	4	3.5	1.1	1.1
2	59	M	c-ANCA	GPA	EA, K, L, J	7	4	2.3	1.6
3	67	M	p-ANCA	MPA	K, J	6	3	3.6	1.9
4	49	M	p-ANCA	MPA	K	6	6	1.9	1.7
5	78	M	p-ANCA	MPA	K, J	6	3	2.8	2.6
6	63	M	p-ANCA	MPA	S, K	4	8	1.2	1.2
7	76	F	p-ANCA	MPA	EA, K, J	1	1	1.0	1.0
8	34	M	Negative	MPA	K, L	7	6	13.2	1.2
9	23	F	p-ANCA	MPA	K, L	11	6	1.5	1.0

p-ANCA: perinuclear antineutrophil cytoplasmic antibody; c-ANCA: cytoplasmic antineutrophil cytoplasmic antibody; GPA: granulomatosis with polyangiitis; MPA: microscopic polyangiitis; PN: peripheral nerve; K: kidney; EA: ear; L: lung; J: joint; S: skin; BVAS/WG: Birmingham Vasculitis Activity Score/Wegener's granulomatosis.

Table 2. Findings on the second renal biopsy.

Patient	Reason for Biopsy	Serum Creatinine at Time of Biopsy, (mg/dl)	BVAS/WG at Time of Biopsy	ESR at Time of Biopsy	ANCA at Time of Biopsy	Renal Biopsy Findings	Followup from First Biopsy, (mo)	Serum Creatinine (mg/dl) at Last Followup	Proteinuria (mg) at Last Followup
1	Persistent hematuria	1.1	1	17	Negative	Normal glomeruli, moderate arteriosclerosis	76	1.4	200
2	Persistent hematuria	1.4	1	43	Persistent positive	Moderate arteriosclerosis	78	1.5	593
3	Persistent hematuria	1.9	1	19	Persistent positive	Secondary FSGS, hypertensive renal disease	NA	ESRD	NA
4	Persistent hematuria	2.0	1	36	Persistent positive	Chronic global and segmental glomerulosclerosis	48	3.1	2400
5	Persistent hematuria	2.5	1	36	Persistent positive	Chronic crescentic GN, secondary FSGS	28	2.6	NA
6	Persistent hematuria	1.2	1	NA	Negative	Chronic crescentic GN	71	1.2	NA
7	New onset hematuria	1.0	1	29	Negative	Chronic crescentic GN	56	1.8	1200
8	New onset hematuria	1.3	1	12	Negative	Crescentic IgA	180	1.3	700
9	New onset hematuria	1.5	4	23	Negative	Crescentic IgA	194	1.1	115

ESR: erythrocyte sedimentation rate; ANCA: antineutrophil cytoplasmic antibody; FSGS: focal segmental glomerulosclerosis; GN: glomerulonephritis; BVAS/WG: Birmingham Vasculitis Activity Score/Wegener's granulomatosis; NA: not applicable; ESRD: endstage renal disease.

undergoing immunosuppression at the time of second biopsy, the 2 that had crescentic IgA nephropathy were treated, 1 with cyclophosphamide and the other with rituximab.

Among the 6 patients with persistent hematuria, 3 experienced renal relapse, at 36, 59, and 19 months after the second biopsy. All 3 patients presented with elevation in inflammatory markers, elevation in serum creatinine, and proteinuria and hematuria at the time of relapse. Two of the 3 patients also had lung involvement at the time of relapse. Among the 3 patients with new-onset hematuria, 2 experienced renal relapse, at 56

and 120 months after the second biopsy. Both these patients had elevation in serum creatinine, proteinuria, and hematuria at the time of relapse. In addition, 1 patient had lung involvement and the other had a vasculitic rash. One patient reached ESRD. The median serum creatinine at last followup was 1.4 mg/dl at a median followup of 73 months from the time of first biopsy.

DISCUSSION

We describe findings in renal biopsy of 9 patients with sys-

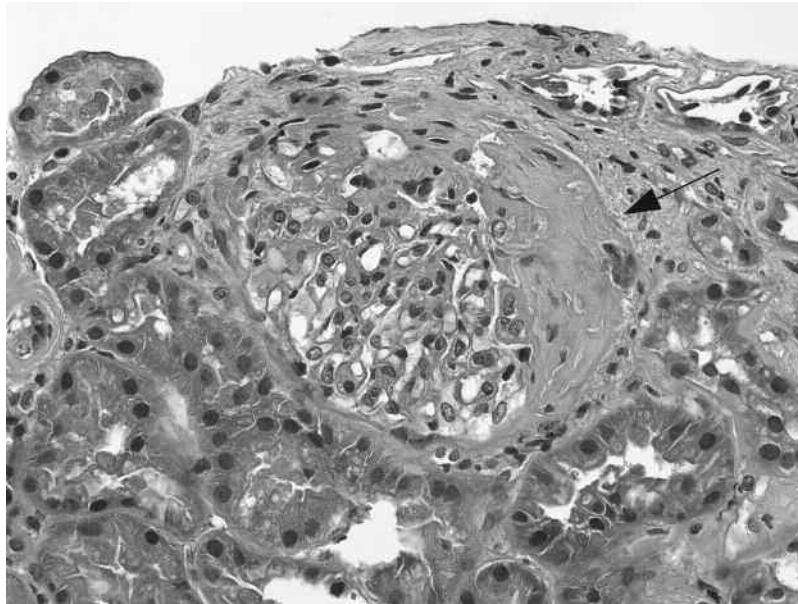


Figure 1. A fibrous glomerular crescent that at an earlier stage was composed of proliferating parietal epithelial cells, inflammatory cells, and fibrin. It now consists primarily of collagenous fibrous tissue (H&E stain; original magnification 160×).

temic small-vessel vasculitis who underwent repeat renal biopsy for persistent or new-onset hematuria, who otherwise met criteria for remission. No patient with persistent hematuria had active vasculitis on renal biopsy and 2 of the 3 patients with new-onset hematuria had evidence of crescentic IgA nephropathy. The renal biopsy findings suggest that persistent hematuria could represent damage and new-onset hematuria could be due to a different disease process. The notion that hematuria in patients with vasculitis reflects active disease requiring continuation or escalation of immunosuppressive therapy may have adverse consequences. This can be avoided if histologic evidence of disease activity is sought with a repeat renal biopsy.

Remission in systemic small-vessel vasculitis is defined as complete absence of disease activity attributable to active vasculitis and stabilization or improvement of injury in the affected organs. The absence of disease activity should be checked systematically according to a validated disease activity score list⁶. The observations used to define vasculitis activity in clinical trials include hematuria, red blood cell casts, and elevation in serum creatinine as markers of active renal vasculitis⁵, whereas those used to define damage from vasculitis include estimated glomerular filtration rate and proteinuria as markers reflecting damage from renal involvement by vasculitic process⁷. In clinical trials of systemic vasculitis, most patients improve within weeks of induction therapy and steroid tapering begins in the first 4 weeks. However, most patients with renal vasculitis continue to have hematuria and proteinuria at 4 weeks. Steroid tapering continues as long as the serum creatinine remains stable and all other measures of

active vasculitis are absent. In AAV — patients in apparent remission — the persistence of hematuria raises the possibility of active disease that might benefit from increased immunosuppressive therapy, and it is unclear whether this practice of tapering steroids in the presence of hematuria in a clinical trial setting is accepted in clinical practice. In a similar fashion, new-onset hematuria in patients with vasculitis is often felt to represent a renal flare once urologic causes are excluded. The controversy of whether persistent hematuria reflects disease activity or damage persists, and has resulted in either continuation or escalation of immunosuppression, with its associated risks of increased infection and longterm malignancy. There have been very few studies on followup renal biopsies in patients with vasculitis. Hauer, *et al* report an analysis of 31 patients with AAV who had followup biopsy for a suspected flare. In that analysis, 13% of biopsies did not have active glomerular lesions⁸. The report by Magrey, *et al* on 10 patients with chronic hematuria also supports that chronic hematuria could be a sign of damage⁴.

Among the 3 patients that underwent renal biopsy for evaluation of new-onset hematuria, 2 had crescentic IgA nephropathy. It is important to recognize that AAV can overlap with other types of vasculitis⁹. In addition, ANCA-associated necrotizing GN has been frequently reported to occur superimposed upon other glomerular disease processes, including IgA nephropathy¹⁰, membranous nephropathy¹¹, acute postinfectious GN¹², lupus nephritis¹³, and even diabetic glomerulosclerosis¹⁴.

Three patients with persistent hematuria and 2 with new-onset hematuria experienced a renal relapse. It could be

argued that the active vasculitis lesions were overlooked by sampling error. All the 9 biopsies had adequate renal tissue and the long time interval between the second biopsy and the subsequent flare indicate that these were not due to sampling error.

This report is subject to the limitations inherent to a retrospective study and small sample size. Despite this, all our cases of persistent hematuria had biopsy-proven chronic disease.

We conclude that microscopic hematuria in patients with renal vasculitis otherwise in remission could represent chronic glomerular injury from prior episode of vasculitis or may represent new glomerular pathology, and repeat renal biopsy should be considered to guide immunosuppressive therapy.

REFERENCES

1. Ntatsaki E, Watts RA, Scott DG. Epidemiology of ANCA-associated vasculitis. *Rheum Dis Clin North Am* 2012;36:447-61.
2. Jayne DR, Marshall PD, Jones SJ, Lockwood CM. Autoantibodies to GBM and neutrophil cytoplasm in rapidly progressive glomerulonephritis. *Kidney Int* 1990;37:965-70.
3. Allen A, Pusey C, Gaskin G. Outcome of renal replacement therapy in antineutrophil cytoplasmic antibody-associated systemic vasculitis. *J Am Soc Nephrol* 1998;9:1258-63.
4. Magrey MN, Villa-Forte A, Koenig CL, Myles JL, Hoffman GS. Persistent hematuria after induction of remission in Wegener granulomatosis: A therapeutic dilemma. *Medicine* 2009;88:315-21.
5. Stone JH, Hoffman GS, Merkel PA, Min YI, Uhlfelder ML, Hellmann DB, et al. A disease-specific activity index for Wegener's granulomatosis: Modification of the Birmingham Vasculitis Activity Score. International Network for the Study of the Systemic Vasculitides (INSSYS). *Arthritis Rheum* 2001;44:912-20.
6. Hellmich B, Flossmann O, Gross WL, Bacon P, Cohen-Tervaert JW, Guillevin L, et al. EULAR recommendations for conducting clinical studies and/or clinical trials in systemic vasculitis: Focus on anti-neutrophil cytoplasm antibody-associated vasculitis. *Ann Rheum Dis* 2007;66:605-17.
7. Exley AR, Bacon PA, Luqmani RA, Kitis GD, Gordon C, Savage CO, et al. Development and initial validation of the Vasculitis Damage Index for the standardized clinical assessment of damage in the systemic vasculitides. *Arthritis Rheum* 1997;40:371-80.
8. Hauer HA, Bajema IM, Hagen EC, Noel LH, Ferrario F, Waldherr R, et al. Long-term renal injury in ANCA-associated vasculitis: An analysis of 31 patients with follow-up biopsies. *Nephrol Dial Transplant* 2002;17:587-96.
9. Havill JP, Levine SM, Kuperman M, Hellmann DB, Geetha D. Falling through the cracks of vasculitis classification — A report of three patients. *NDT Plus* 2011;4:327-30.
10. Haas M, Jafri J, Bartosh SM, Karp SL, Adler SG, Meehan SM. ANCA-associated crescentic glomerulonephritis with mesangial IgA deposits. *Am J Kidney Dis* 2000;36:709-18.
11. Nasr SH, Said SM, Valeri AM, Stokes MB, Masani NN, D'Agati VD, et al. Membranous glomerulonephritis with ANCA-associated necrotizing and crescentic glomerulonephritis. *Clin J Am Soc Nephrol* 2009;4:299-308.
12. Haas M. Incidental healed postinfectious glomerulonephritis: A study of 1012 renal biopsy specimens examined by electron microscopy. *Hum Pathol* 2003;34:3-10.
13. Nasr SH, D'Agati VD, Park HR, Sterman PL, Goyzueta JD, Dressler RM, et al. Necrotizing and crescentic lupus nephritis with antineutrophil cytoplasmic antibody seropositivity. *Clin J Am Soc Nephrol* 2008;3:682-90.
14. Nasr SH, D'Agati VD, Said SM, Stokes MB, Appel GB, Valeri AM, et al. Pauci-immune crescentic glomerulonephritis superimposed on diabetic glomerulosclerosis. *Clin J Am Soc Nephrol* 2008;3:1282-8.