

Propylthiouracil-induced Antineutrophil Cytoplasmic Antibody (ANCA)-associated Renal Vasculitis Versus Primary ANCA-associated Renal Vasculitis: A Comparative Study

YONG-XI CHEN, WEN ZHANG, XIAO-NONG CHEN, HAI-JIN YU, LI-YAN NI, JING XU, XIAO-XIA PAN, HONG REN, and NAN CHEN

ABSTRACT. *Objective.* Renal involvement is frequently present in primary antineutrophil cytoplasmic antibody-associated small-vessel vasculitis (AAV) as well as propylthiouracil (PTU)-induced AAV. We analyzed the characteristics of patients with PTU-induced AAV with renal involvement and investigated the differences of the 2 diseases.

Methods. Thirty-six patients with PTU-induced AAV, diagnosed from 1997 to 2010, were enrolled for study. Their data were compared with those of 174 patients with primary AAV diagnosed at the same time. Renal involvement was present in all patients.

Results. There was a prominent proportion of young women with PTU-induced AAV ($p < 0.01$). They had lower levels of proteinuria and serum creatinine and higher estimated glomerular filtration rate ($p < 0.01$, $p < 0.01$, and $p < 0.01$, respectively). Clinical immunological abnormalities were less severe in patients with PTU-induced AAV. Patients with PTU-induced AAV had less organ involvement and lower Birmingham Vasculitis Assessment Score than patients with primary AAV ($p < 0.01$). Renal biopsies showed a lower proportion of glomeruli with crescents ($p < 0.01$). Interstitial inflammation was less severe in patients with PTU-induced AAV ($p < 0.05$). Similarly, interstitial fibrosis and tubular atrophy were less severe in patients with PTU-induced AAV ($p < 0.01$, $p < 0.05$, respectively). Renal survival and total survival were better in patients with PTU-associated vasculitis ($p < 0.05$, $p = 0.01$).

Conclusion. Clinical and histopathological abnormalities were less severe in patients with PTU-induced AAV and most of them had a good prognosis. (J Rheumatol First Release Jan 15 2012; doi:10.3899/jrheum.110931)

Key Indexing Terms:

ANTINEUTROPHIL CYTOPLASMIC ANTIBODIES
VASCULITIS

PROPYLTHIOURACIL
RENAL INVOLVEMENT

Antineutrophil cytoplasmic antibody (ANCA)-associated vasculitis (AAV) consists of a group of autoimmune diseases that includes Wegener's granulomatosis (WG), microscopic polyangiitis (MPA), and Churg-Strauss syndrome (CSS) and their localized forms. ANCA is the serological marker of those diseases and is clinically relevant^{1,2}. ANCA could also be

detected in some other forms of vasculitis, including drug-induced vasculitis³.

Propylthiouracil (PTU) is one of the most common drugs that induce AAV. We previously reported that renal involvement was the most common manifestation of patients with PTU-induced AAV⁴. However, the characteristics of patients with PTU-induced AAV with renal involvement have not been fully investigated except for a few case reports. In our study, we investigated clinical and pathological features of those patients, making detailed comparisons with patients with primary AAV.

MATERIALS AND METHODS

Patient selection and criteria. Patients with PTU-induced AAV diagnosed in our department during the period 1997 to 2010 were retrospectively analyzed. Their data were compared with data from patients with primary AAV during the same period. Renal involvement was present in all the patients. Diagnosis of PTU-induced AAV was based on the following criteria as we reported^{4,5}: signs and symptoms of vasculitis were related to taking PTU; ANCA was detected using indirect immunofluorescence (IIF) assay and antigen-specific ELISA; other medical conditions that mimicked vasculitis were excluded, especially infections, malignancies, and other definable type of vasculitis.

From the Department of Nephrology, Shanghai Ruijin Hospital affiliated to Shanghai Jiaotong University, School of Medicine, Shanghai, China.

Supported by grants from the National Natural Science Foundation (No. 81000285), the Leading Academic Discipline Project of Shanghai Health Bureau (No. 05III001), the Shanghai Leading Academic Discipline Project (No. T0201), the Shanghai Scientific Committee (No. 10411965900, No. 08dz1900502), and a grant from Ruijin Hospital for young investigators.

Y-X. Chen, MD; W. Zhang, MD; X-N. Chen, MD; H-J. Yu, MD; L-Y. Ni, MD; J. Xu, MD; X-X. Pan, MD; H. Ren, MD; N. Chen, MD, Department of Nephrology, Shanghai Ruijin Hospital.

Address correspondence to Prof. N. Chen, Department of Nephrology, Ruijin Hospital affiliated to Shanghai Jiaotong University, School of Medicine, No. 197, Ruijin Er Road, Shanghai 200025, PR China.

E-mail: chen-nan@medmail.com.cn

Accepted for publication October 5, 2011.

Personal non-commercial use only. The Journal of Rheumatology Copyright © 2012. All rights reserved.

Diagnosis of primary AAV was based on the criteria of the Chapel Hill Consensus Conference 1994 and the American College of Rheumatology, which included MPA, WG, CSS, and renal limited vasculitis (RLV)^{6,7,8}. Renal involvement was defined as an elevated creatinine level attributable to the disease (serum creatinine > 115 $\mu\text{mol/l}$) and/or urinary abnormalities (proteinuria with protein > 300 mg/day and microscopic hematuria with > 10 erythrocytes/high-power field on 2 separate occasions in the absence of urinary infection). Patients with antiglomerular basement antibodies, Henoch-Schonlein purpura, cryoglobulinemic vasculitis, and polyarteritis nodosa were excluded.

ANCA analysis. All patients had been tested for the presence of ANCA by IIF (Euroimmun AG, Lubeck, Germany). ELISA was performed to test antimyeloperoxidase (MPO) and antiproteinase 3 (PR3) antibodies in all sera (Euroimmun AG) as reported^{4,9}.

Clinical data. The GFR was calculated using the simplified "modification of diet in renal disease" formula¹⁰, considering the highest serum creatinine at diagnosis. Disease activity at initial clinical presentation was evaluated by the Birmingham Vasculitis Assessment Score (BVAS) 2003¹¹.

Renal biopsies. Renal biopsy specimens were processed for both light microscopy and IIF study. The glomerulus was scored separately for the presence or absence of crescents (cellular, fibrous). The number of glomeruli revealing such lesions was expressed as a percentage of the total number of glomeruli in the biopsy. Tubulointerstitial lesions such as interstitial fibrosis, interstitial inflammation, and tubular atrophy were graded semiquantitatively (scale 0 to 3; score 0 for absent, 1 for 0–20%, 2 for 20%–50%, 3 for > 50%).

Treatment. Treatment of patients with PTU-induced AAV was as described⁴. Briefly, PTU was discontinued in all the patients with PTU-induced AAV. Patients were treated with prednisone or prednisone together with cyclophosphamide depending on the clinical presentation after cessation of PTU only if necessary. However, if patients presented with rapidly progressive glomerulonephritis or active systemic manifestation at diagnosis, prednisone together with cyclophosphamide was administered. Prednisone was given at a dose of 0.5–0.8 mg/kg for the first 1 to 2 months, with a tapering schedule during the following months. Intravenous cyclophosphamide was given at a dose of 0.5 g/1.73 m² and adjusted according to the patient's leukocyte count. The standard treatment protocol of primary AAV was as described⁹.

Statistics. Statistical analysis was performed with SPSS 11.0 for windows (SPSS Inc., Chicago, IL, USA). Data were presented as mean \pm SD, unless otherwise indicated. Differences of qualitative results were compared by chi-square test. Differences of quantitative variables between groups were analyzed by t test (for normally distributed data) or nonparametric test (for non-normally distributed data). Differences of semiquantitative results were analyzed by Mann-Whitney U test. Kaplan-Meier curves were created to analyze patient survival as well as renal survival. A p value < 0.05 was considered statistically significant.

RESULTS

Demographic data. Thirty-six patients with PTU-induced AAV were enrolled. Their data were compared with those of 174 patients with primary AAV (124 MPA, 24 WG, 21 RLV, and 5 CSS) during the same time period. Renal involvement was present in all patients.

Compared with the primary AAV patients, there were more female patients in the PTU-induced AAV group ($p < 0.01$) and they were younger ($p < 0.01$). There were fewer hypertensive patients in the PTU-induced AAV group ($p < 0.01$). Accordingly, systolic and diastolic blood pressure were both lower in the PTU-induced AAV group ($p < 0.01$ and $p < 0.01$, respectively). Details are summarized in Table 1.

Laboratory presentations. Compared with patients with pri-

mary AAV, more patients were positive for perinuclear-ANCA by IIF in the PTU-induced AAV group ($p < 0.05$). By ELISA, dual positivity for MPO-ANCA and PR3-ANCA was found in 4 patients with PTU-associated vasculitis. No patient with primary AAV had dual ANCA positivity. Immunology findings showed that patients with PTU-induced AAV presented with higher percentages of serum immunological abnormalities (Table 2).

Renal involvement. Renal abnormalities are listed in Table 3. Compared with primary AAV patients, patients with PTU-induced AAV presented with lower levels of serum creatinine and proteinuria, as well as higher estimated GFR ($p < 0.01$, $p < 0.01$, $p < 0.01$, respectively). Our results demonstrated that patients with PTU-induced AAV presented with less severe renal involvement in comparison with patients with primary AAV.

Renal histology. Table 4 summarizes the histopathology of patients who underwent renal biopsies. Compared with patients with primary AAV, patients with PTU-induced AAV had lower proportions of glomeruli with crescents ($p < 0.01$) and interstitial inflammation was less severe ($p < 0.01$). Similarly, interstitial fibrosis and tubular atrophy were less severe in patients with PTU-induced AAV ($p < 0.01$, $p < 0.05$, respectively; Figure 1). The data showed that patients with PTU-induced AAV had less severe histopathological lesions.

Extrarenal involvement. Patients with PTU-induced AAV presented with less severe extrarenal involvement at diagnosis in comparison with patients with primary AAV. Lung involvement was the most common organ manifestation in the 2 groups, which included hemoptysis, respiratory failure, or radiographic infiltrations without evidence of infection. However, fewer patients with PTU-induced AAV presented with pulmonary involvement at diagnosis ($p < 0.01$). Further, the proportion of nervous system involvement was lower in patients with PTU-induced AAV ($p < 0.01$). Finally, patients with PTU-induced AAV had lower BVAS at diagnosis than patients with primary AAV ($p < 0.01$; Table 5).

Treatment and outcomes. For treatment of PTU-induced AAV, prednisone was administered in 11 patients, and 17 patients were treated with prednisone together with immunosuppressant. The remaining 8 patients did not receive immunosuppressive therapy. Compared with primary AAV patients, patients with PTU-induced AAV experienced better overall survival ($p = 0.01$; Figure 2) and a better renal survival rate ($p < 0.05$; Figure 3). Thus, the results suggested that patients with PTU-induced AAV had better prognosis.

DISCUSSION

PTU is a type of antithyroid drug that has been associated with a variety of side effects including potentially life-threatening or even lethal complications. ANCA-associated vasculitis (AAV) is one of the severe side effects induced by PTU³; 4% to 46% of patients treated with PTU could develop vasculi-

Table 1. Comparison of demographic data at diagnosis.

Characteristic	PTU-induced AAV, n = 36	Primary AAV, n = 174	p
Sex: no. female/total (%)	35/36 (97.2)	90/174 (51.7)	< 0.01
Age at presentation, yrs (range)	38.9 ± 15.3 (18–75)	59.8 ± 14.9 (14–88)	< 0.01
Hypertension, n (%)	11 (30.6)	102 (58.6)	< 0.01
Systolic pressure, mm Hg	121.4 ± 21.1	135.3 ± 21.8	< 0.01
Diastolic pressure, mm Hg	74.2 ± 13.0	80.4 ± 11.7	< 0.01

PTU: propylthiouracil; AAV: ANCA-associated vasculitis; ANCA: antineutrophil cytoplasmic antibody.

Table 2. Comparison of laboratory data at diagnosis.

	PTU-induced AAV, n = 36	Primary AAV, n = 174	p
ANCA by immunofluorescence			
p-ANCA, n (%)	34 (94.4)	137 (78.7)	
c-ANCA, n (%)	1 (2.8)	37 (21.3)	< 0.05
Atypical ANCA, n (%)	1 (2.8)	0	
ANCA by ELISA			
MPO-ANCA only, n (%)	31 (86.1)	137 (78.7)	
PR3-ANCA only, n (%)	1 (2.8)	37 (21.3)	NS
PR3-ANCA + MPO-ANCA, n (%)	4 (11.1)	0	
Anemia, n (%)	15 (41.7)	146 (83.9)	< 0.01
Immunology, n (%)			
ANA positivity	12 (33.3)	18 (10.3)	< 0.01
ENA positivity	3 (8.3)	3 (1.7)	NS
IgG increased	8 (22.2)	54 (31.0)	NS
IgA increased	3 (8.3)	34 (19.5)	NS
IgE increased	3 (8.3)	29 (16.7)	NS
IgM increased	7 (19.4)	5 (2.9)	< 0.01
C3 decreased	3 (8.3)	41 (23.6)	NS
C4 decreased	1 (2.8)	21 (12.1)	NS
ESR increased	24 (66.7)	124 (71.3)	NS
CRP increased	13 (36.1)	94 (54.0)	NS

ESR: erythrocyte sedimentation rate; CRP: C-reactive protein; ANA: antinuclear antibodies; ENA: extractable nuclear antigens; ANCA: antineutrophil cytoplasmic antibody; PTU: propylthiouracil; AAV: ANCA-associated vasculitis; MPO: myeloperoxidase; PR3: proteinase 3; NS: nonsignificant.

Table 3. Comparison of renal involvement at diagnosis.

Variables	PTU-induced AAV, n = 36	Primary AAV, n = 174	p
Gross hematuria, n (%)	5 (13.9)	25 (14.4)	NS
Proteinuria, mg/24 h	665.2 ± 696.1	1527.8 ± 1568.7	< 0.01
Serum creatinine, μmol/l	140.0 ± 204.4	363.3 ± 316.9	< 0.01
eGFR, ml/min	86.3 ± 48.6	36.5 ± 36.8	< 0.01

PTU: propylthiouracil; AAV: ANCA-associated vasculitis; eGFR: estimated glomerular filtration rate; NS: non-significant; ANCA: antineutrophil cytoplasmic antibody.

tis^{12,13}. Studies demonstrated that PTU could induce ANCA production and then trigger autoimmunity leading to AAV^{2,3}; however, the dose and duration of PTU therapy might not correlate to onset of the disease⁴. Since the mechanism of PTU-induced AAV is different from that of primary AAV, the clinical course of the 2 diseases might not be the same in some ways. Although several reports have described that the clinical

course of the PTU-induced AAV was satisfactory^{4,14,15,16}, the detailed differences between the 2 diseases remain unclear. In this detailed comparison, we have described clinical characteristics and laboratory aspects of PTU-induced AAV that are unique compared to those of primary AAV.

This study and our previous report⁴ both showed a predominance of young women among patients with

Table 4. Comparison of renal histopathological findings at diagnosis.

	PTU-induced AAV, n = 36	Primary AAV, n = 174	p
No. patients that underwent renal biopsy, n (%)	27 (75.0)	127 (73.0)	NS
Percentage of glomerular lesions, mean \pm SD			
Crescents	18.6 \pm 24.8	34.4 \pm 30.0	< 0.01
Cellular	0.9 \pm 9.8	20.0 \pm 24.5	< 0.01
Fibrotic	10.9 \pm 17.4	11.0 \pm 20.8	NS
Necrosis	2.8 \pm 6.2	7.2 \pm 12.2	NS

PTU: propylthiouracil; AAV: ANCA-associated vasculitis; NS: nonsignificant.

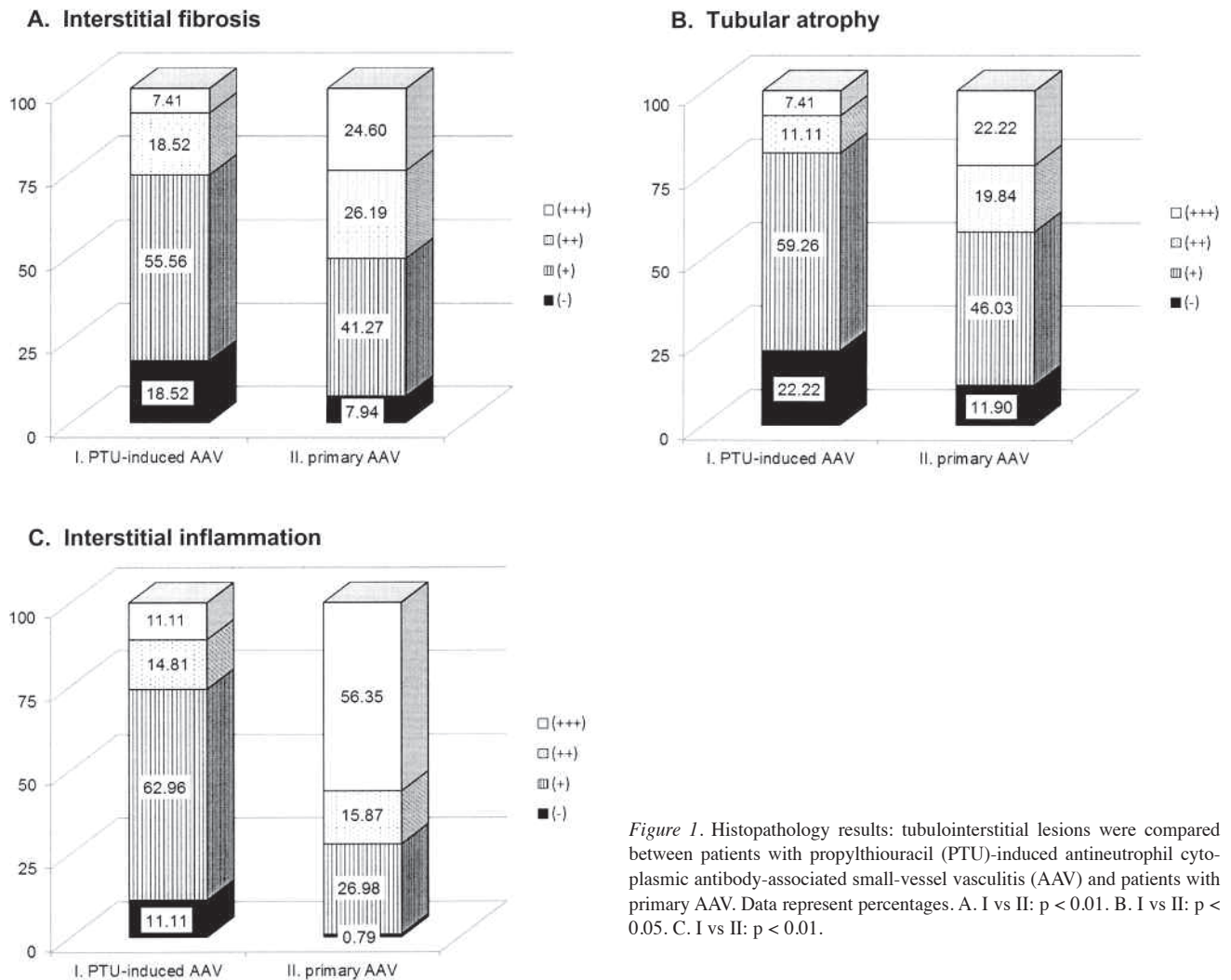


Figure 1. Histopathology results: tubulointerstitial lesions were compared between patients with propylthiouracil (PTU)-induced antineutrophil cytoplasmic antibody-associated small-vessel vasculitis (AAV) and patients with primary AAV. Data represent percentages. A. I vs II: $p < 0.01$. B. I vs II: $p < 0.05$. C. I vs II: $p < 0.01$.

PTU-induced AAV. Similar results were found by other studies in a Chinese population as well as in Japanese pediatric patients^{14,16}. Considering different prevalences of hyperthyroidism in males and females, gender differences might contribute to these results. Further, recent studies pointed out that more and more patients with primary AAV presented at an

elderly age^{17,18}, and the advanced age in primary AAV at disease onset could also contribute to this discrepancy.

As for laboratory findings, our study showed a predominance of p-ANCA found by IIF in the 2 study groups. In patients with PTU-induced AAV, p-ANCA positivity might be related to the pathogenesis of the disease, that is, related to the

Table 5. Comparison of extrarenal involvement and systemic symptoms at diagnosis. Data are n (%) unless otherwise specified.

	PTU-induced AAV, n = 36	Primary AAV, n = 174	p
Lung and lower airway	10 (27.8)	118 (67.8)	< 0.01
Cutaneous	6 (16.7)	20 (11.5)	NS
Ear-nose-throat	13 (36.1)	54 (31.0)	NS
Gastrointestinal tract	0	13 (7.5)	NS
Nervous system	0	31 (17.8)	< 0.01
Cardiovascular	0	5 (2.9)	NS
General			
Fever	16 (44.4)	81 (46.6)	NS
Weight loss	3 (8.3)	34 (19.5)	NS
BVAS, median (range)	13.5 (6–34)	21.0 (4–39)	< 0.01

PTU: propylthiouracil; AAV: ANCA-associated vasculitis; BVAS: Birmingham Vasculitis Assessment Score; NS: nonsignificant; ANCA: antineutrophil cytoplasmic antibody.

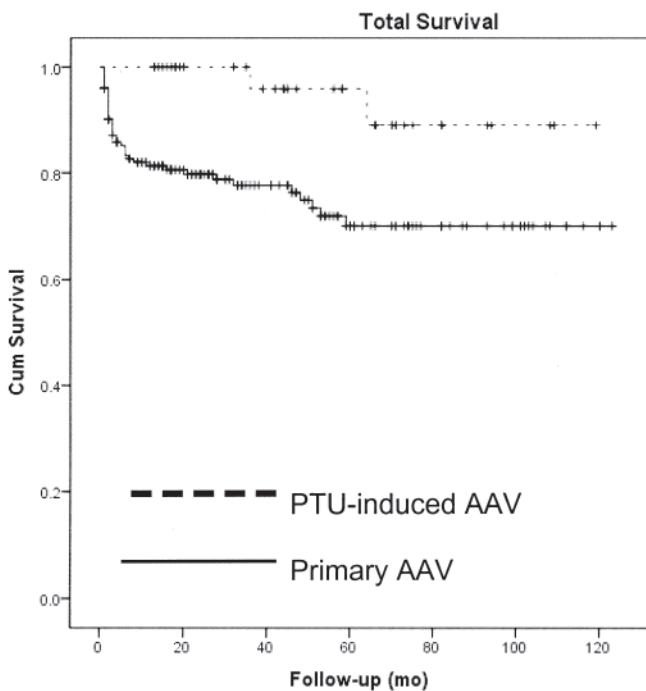


Figure 2. Total survival of patients with PTU-induced AAV and primary AAV.

interaction of PTU and its cytotoxic products and neutrophils^{2,3,19}. By contrast, the predominance of p-ANCA positivity in patients with primary AAV could be a result of the constituent ratio of its clinical subgroups. Most patients with WG presented with cytoplasmic ANCA (c-ANCA)/PR3-ANCA, and p-ANCA/MPO-ANCA was found in more than half the CSS patients with ANCA positivity, while 60% of patients with MPA had p-ANCA/MPO-ANCA and 30% had c-ANCA/PR3-ANCA². Thus, different proportions of WG, CSS, and MPA patients might lead to different percentages of

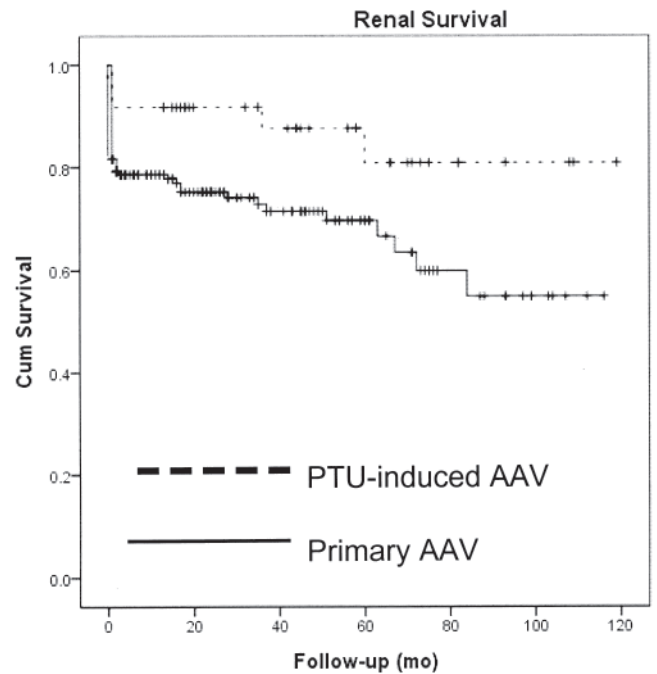


Figure 3. Renal survival of patients with PTU-induced AAV and primary AAV.

p-ANCA/MPO-ANCA and c-ANCA/PR3-ANCA positivity. In our study, patients with MPA, together with CSS and RLV patients, made up the majority of all patients with primary AAV and as a result, a predominance of p-ANCA/MPO-ANCA was found.

Some of our patients with PTU-induced AAV were positive for multiple ANCA; similar results were also found in vasculitis patients who had undergone antithyroid drug therapy^{16,20,21,22,23}. In our study group with primary AAV, no patient presented with multiple ANCA positivity. The mechanism of multiple ANCA positivity in patients with PTU-induced AAV might be related to B cell polyclonal activation. As well as the MPO- and PR3-ANCA, other ANCA antigen targets such as human leukocyte elastase, lactoferrin, bactericidal/permeability-increasing protein, cathepsin G, and azurocidin could also be detected in PTU-treated patients; however, MPO- and/or PR3-ANCA were constantly positive in patients who developed vasculitis during the PTU therapy, and there was a low frequency of MPO- or PR3-ANCA in patients treated with PTU who had no signs of vasculitis^{12,19,24}. Interestingly, the high proportion of multiple ANCA positivity in patients with PTU-induced AAV did not correlate to less severity of the disease. Further studies are needed to investigate the different roles of ANCA in primary and secondary autoimmune diseases.

Regarding the clinical presentations, we found that patients with PTU-induced AAV presented with mild renal involvement. Accordingly, the level of serum creatinine and the GFR were lower and proteinuria was less severe in those patients in comparison with patients with primary AAV. Further, renal

histopathology showed that patients with PTU-induced AAV had less severe glomerular and tubulointerstitial lesions. The lower severity of renal involvement was consistent with the lower percentage of hypertensive patients among those with PTU-induced AAV. It was also shown in our study that patients with PTU-induced AAV had fewer constitutional symptoms and less extrarenal involvement; thus patients had lower BVAS scores than patients with primary AAV. Considering the systemic presentation and renal involvement at diagnosis, most patients with PTU-induced AAV had less severe clinical manifestations than patients with primary AAV; however, some exceptions occurred⁴. In this regard, developing treatment strategies according to the clinical situation is a logical way to treat these patients.

In this study, renal prognosis and survival rates were better in patients with PTU-induced AAV in comparison with primary AAV patients. One possible reason for the good prognosis is that PTU, which triggered the disease onset, was discontinued in all patients with PTU-induced AAV. Second, most patients with PTU-induced AAV presented with mild clinical course and histological lesions. Another possible reason is that our patients were younger, and advanced age was reported to be one of the risk factors of outcomes in patients with vasculitis^{24,25}.

PTU-induced AAV has its characteristic clinical and histological features. Compared with primary AAV, patients with PTU-induced AAV had less severe clinical course and better prognosis. However, severe cases do exist and early recognition and adequate treatment are still necessary to improve outcome in this disease.

REFERENCES

1. Bosch X, Guilbert A, Espinosa G, Mirapeix E. Treatment of antineutrophil cytoplasmic antibody associated vasculitis: A systematic review. *JAMA* 2007;298:655-69.
2. Bosch X, Guilbert A, Font J. Antineutrophil cytoplasmic antibodies. *Lancet* 2006;368:404-18.
3. Nebesio TD, Eugster EA. Antithyroid drugs. *N Engl J Med* 2005;352:2246-7; author reply 7.
4. Chen YX, Yu HJ, Ni LY, Zhang W, Xu YW, Ren H, et al. Propylthiouracil-associated antineutrophil cytoplasmic autoantibody-positive vasculitis: Retrospective study of 19 cases. *J Rheumatol* 2007;34:2451-6.
5. Merkel PA. Drug-induced vasculitis. *Rheum Dis Clin North Am* 2001;27:849-62.
6. Leavitt RY, Fauci AS, Bloch DA, Michel BA, Hunder GG, Arend WP, et al. The American College of Rheumatology 1990 criteria for the classification of Wegener's granulomatosis. *Arthritis Rheum* 1990;33:1101-7.
7. Masi AT, Hunder GG, Lie JT, Michel BA, Bloch DA, Arend WP, et al. The American College of Rheumatology 1990 criteria for the classification of Churg-Strauss syndrome (allergic granulomatosis and angiitis). *Arthritis Rheum* 1990;33:1094-100.
8. Jennette JC, Falk RJ, Andrassy K, Bacon PA, Churg J, Gross WL, et al. Nomenclature of systemic vasculitides. Proposal of an international consensus conference. *Arthritis Rheum* 1994;37:187-92.
9. Chen YX, Yu HJ, Zhang W, Ren H, Chen XN, Shen PY, et al. Analyzing fatal cases of Chinese patients with primary antineutrophil cytoplasmic antibodies-associated renal vasculitis: A 10-year retrospective study. *Kidney Blood Press Res* 2008;31:343-9.
10. K/DOQI clinical practice guidelines for chronic kidney disease: Evaluation, classification, and stratification. *Am J Kidney Dis* 2002;39(2 Suppl 1):S1-266.
11. Flossmann O, Bacon P, de Groot K, Jayne D, Rasmussen N, Seo P, et al. Development of comprehensive disease assessment in systemic vasculitis. *Ann Rheum Dis* 2007;66:283-92.
12. Slot MC, Links TP, Stegeman CA, Tervaert JW. Occurrence of antineutrophil cytoplasmic antibodies and associated vasculitis in patients with hyperthyroidism treated with antithyroid drugs: A long-term followup study. *Arthritis Rheum* 2005;53:108-13.
13. Savige J, Davies D, Falk RJ, Jennette JC, Wiik A. Antineutrophil cytoplasmic antibodies and associated diseases: A review of the clinical and laboratory features. *Kidney Int* 2000;57:846-62.
14. Fujieda M, Hattori M, Kurayama H, Koitabashi Y. Clinical features and outcomes in children with antineutrophil cytoplasmic autoantibody-positive glomerulonephritis associated with propylthiouracil treatment. *J Am Soc Nephrol* 2002;13:437-45.
15. Yu F, Chen M, Gao Y, Wang SX, Zou WZ, Zhao MH, et al. Clinical and pathological features of renal involvement in propylthiouracil-associated ANCA-positive vasculitis. *Am J Kidney Dis* 2007;49:607-14.
16. Gao Y, Chen M, Ye H, Yu F, Guo XH, Zhao MH. Long-term outcomes of patients with propylthiouracil-induced anti-neutrophil cytoplasmic auto-antibody-associated vasculitis. *Rheumatology* 2008;47:1515-20.
17. Booth AD, Almond MK, Burns A, Ellis P, Gaskin G, Neild GH, et al. Outcome of ANCA-associated renal vasculitis: A 5-year retrospective study. *Am J Kidney Dis* 2003;41:776-84.
18. Harper L, Savage CO. ANCA-associated renal vasculitis at the end of the twentieth century — A disease of older patients. *Rheumatology* 2005;44:495-501.
19. Jiang X, Khursigara G, Rubin RL. Transformation of lupus-inducing drugs to cytotoxic products by activated neutrophils. *Science* 1994;266:810-3.
20. Slot MC LT, Stegeman CA, Tervaert JW. Occurrence of antineutrophil cytoplasmic antibodies and associated vasculitis in patients with hyperthyroidism treated with antithyroid drugs: A long-term followup study. *Arthritis Rheum* 2005;53:108-13.
21. Zhao MH, Chen M, Gao Y, Wang HY. Propylthiouracil-induced anti-neutrophil cytoplasmic antibody-associated vasculitis. *Kidney Int* 2006;69:1477-81.
22. Gao Y, Chen M, Ye H, Guo XH, Zhao MH, Wang HY. The target antigens of antineutrophil cytoplasmic antibodies (ANCA) induced by propylthiouracil. *Int Immunopharmacol* 2007;7:55-60.
23. Gao Y, Zhao MH, Guo XH, Xin G, Wang HY. The prevalence and target antigens of antithyroid drugs induced antineutrophil cytoplasmic antibodies (ANCA) in Chinese patients with hyperthyroidism. *Endocr Res* 2004;30:205-13.
24. de Lind van Wijngaarden RA, Hauer HA, Wolterbeek R, Jayne DR, Gaskin G, Rasmussen N, et al. Clinical and histologic determinants of renal outcome in ANCA-associated vasculitis: A prospective analysis of 100 patients with severe renal involvement. *J Am Soc Nephrol* 2006;17:2264-74.
25. Pavone L, Grasselli C, Chierici E, Maggiore U, Garini G, Ronda N, et al. Outcome and prognostic factors during the course of primary small-vessel vasculitides. *J Rheumatol* 2006;33:1299-306.