

Safety and Efficacy of Rituximab in Severe Juvenile Dermatomyositis: Results from 9 Patients from the French Autoimmunity and Rituximab Registry

BRIGITTE BADER-MEUNIER, HÉLÈNE DECALUWE, CHRISTINE BARNERIAS, ROMAIN GHERARDI, PIERRE QUARTIER, ALBERT FAYE, VINCENT GUIGONIS, ANNE PAGNIER, KARINE BROCHARD, JEAN SIBILIA, JACQUES-ERIC GOTTENBERG, and CHRISTINE BODEMER, for the Club Rhumatismes et Inflammation

ABSTRACT. Objective. To evaluate the safety and efficacy of rituximab (RTX) in juvenile dermatomyositis (JDM) in off-trial patients.

Methods. We conducted a multicenter prospective study of patients with JDM included in the French Autoimmunity and Rituximab (AIR) registry.

Results. Nine patients with severe JDM were studied. The main indication for RTX treatment was severe and/or refractory muscle involvement (7 patients), severe calcinosis (1 patient), or severe chronic abdominal pain associated with abdominal lipomatosis (1 patient). RTX was associated with corticosteroids, immunosuppressive drugs, and plasma exchange therapy in 9/9, 5/9, and 2/9 patients, respectively. Mild infections of the calcinosis sites occurred in 2 patients and an infusion-related event in 1. Complete clinical response was achieved in 3/6 patients treated with RTX for muscle involvement. In these responders steroid therapy was stopped or tapered to < 15% of the baseline dosage, with no relapse, with a followup ranging from 1.3 to 3 years. Calcinosis did not improve in the 6 affected patients.

Conclusion. This small series suggests that rituximab may be effective for treating muscle and skin involvement in a small subset of children with severe JDM, and that its safety profile was satisfactory. Further studies are needed to identify predictive factors of response to RTX in patients with severe JDM. (J Rheumatol First Release June 15 2011; doi:10.3899/jrheum.101321)

Key Indexing Terms:

JUVENILE DERMATOMYOSITIS

CALCINOSIS

RITUXIMAB

Juvenile dermatomyositis (JDM) represents up to 85% of childhood idiopathic inflammatory myopathies¹. It is a vasculopathic condition of presumed autoimmune etiology that primarily affects skeletal muscle and skin, but may affect many other organs. JDM is often a chronic disease whose prognosis has improved, notably due to the use of corticosteroids and immunosuppressive drugs and to better evaluation of disease activity in the last 3 decades. However,

innovative approaches are needed for some patients who are either refractory to conventional treatments or who have developed treatment-related complications.

Many aspects of the pathogenesis of JDM remain unknown. T lymphocytes are the predominant cell type involved. However, the presence of B cells in vessels and perivascular muscle² suggests that these cells also play a role. B lymphocytes might be involved by participating in

From the Department of Pediatric Immunology and Rheumatology, Paris Descartes University, AP-HP, Necker Hospital, Paris; Department of Pediatric Immunology and Rheumatology, Sainte-Justine Hospital, University of Montreal, Montreal, Quebec, Canada; Department of Pediatric Neurology, Necker Hospital, Paris; Department of Pathology, AP-HP, Henri Mondor Hospital, Créteil; Department of Pediatrics, Robert Debré Hospital, APHP, Paris; Department of Pediatrics, Dupuytren Hospital, Limoges; Department of Pediatrics, La Tronche Hospital, Grenoble; Department of Pediatrics, Purpan Hospital, Toulouse; Department of Rheumatology, Hautepierre Hospital, Strasbourg; and Department of Dermatology, Paris Descartes University, AP-HP, Necker Hospital, Paris, France.

The French Autoimmunity and Rituximab registry receives financial support from Roche (an unrestricted education grant).

B. Bader-Meunier, MD, Department of Pediatric Immunology and Rheumatology, Paris Descartes University, AP-HP, Necker Hospital; H. Decaluwe, MD, PhD, Department of Pediatric Immunology and Rheumatology, Paris Descartes University, AP-HP, Necker Hospital,

Department of Pediatric Immunology and Rheumatology, Sainte-Justine Hospital, University of Montreal; C. Barnerias, MD, Department of Pediatric Neurology, Necker Hospital; R. Gherardi, MD, PhD, Department of Pathology, AP-HP, Henri Mondor Hospital; P. Quartier, MD, Department of Pediatric Immunology and Rheumatology, Paris Descartes University, AP-HP, Necker Hospital; A. Faye, MD, PhD, Department of Pediatrics, Robert Debré Hospital, APHP; V. Guignonis, MD, PhD, Department of Pediatrics, Dupuytren Hospital; A. Pagnier, MD, Department of Pediatrics, La Tronche Hospital; K. Brochard, MD, Department of Pediatrics, Purpan Hospital; J. Sibilia, MD, PhD; J.-E. Gottenberg, MD, PhD, Department of Rheumatology, Hautepierre Hospital; C. Bodemer, MD, PhD, Department of Dermatology, Paris Descartes University, AP-HP, Necker Hospital.

Address correspondence to Dr. B. Bader-Meunier, Hôpital Necker, Service d'Immunologie, Hématologie et Rhumatologie Pédiatriques, Centre de Référence Arthrites Juvéniles, AP-HP, Paris, 75015 France.

E-mail: brigitte.bader-meunier@nck.aphp.fr

Accepted for publication February 3, 2011.

Personal non-commercial use only. The Journal of Rheumatology Copyright © 2011. All rights reserved.

the complement fixation and deposition in vessels and perivascular muscle, by collaborating with T cells, and by producing autoantibodies². Therefore, therapeutic options that specifically target B cells may be considered. However, to date, conflicting conclusions have been drawn regarding the efficacy of anti-CD20 treatment, from noncontrolled studies and case reports including only 32 patients with dermatomyositis (DM) diagnosed in adults^{3,4,5,6,7,8,9,10,11,12} or children^{7,13,14}.

We report a series with anti-CD20 monoclonal antibody therapy in off-trial patients with JDM included in the French Autoimmunity and Rituximab registry (AIR), describing its safety and efficacy.

MATERIALS AND METHODS

All patients receiving rituximab (RTX) before age 16 years for JDM, and included in the AIR registry from September 2005 to September 2010, were eligible for the study. Definite or probable diagnosis of DM was carried out according to the Bohan and Peter criteria¹. The cutoff date for followup was September 2010. The AIR registry is an ongoing nationwide prospective cohort study that since September 2005 has collected data on patients with autoimmune diseases, and that aims to investigate the longterm safety and efficacy of RTX for treating these disorders. The AIR was set up by the French Society of Rheumatology and its section the Club Rhumatismes et Inflammation (CRI), and receives financial support from Roche (unrestricted education grant). Roche was not involved in the design, protocol, data collection, or statistical analysis of the study. All French hospital- and community-based units (rheumatology, internal medicine, dermatology, and pediatrics) were invited to take part in this observational registry. The registry includes data from 82 centers.

Data concerning patient characteristics, indications, therapy regimen, and tolerance and efficacy of RTX were collected at baseline and at 3- and 6-month followup, then every 6 months or at disease relapse, by use of an electronic case report form. Research study nurses were specifically trained in RTX treatment and the use of the case report form by the coordinator of the study (J-EG). Study nurses visited each center regularly to update patients' data. The amount of missing data was minimized by providing the physician in charge of the patient and the study nurses with summaries of missing data for each patient in each center, and requesting that the missing data be provided when possible. Inconsistencies in data were noted, and corrected when possible. The primary care physician or the private rheumatologist was contacted when patients did not have followup visits for ≥ 10 months. The recorded clinical data included assessment of muscle strength with manual muscle testing (MMT), presence of skin, digestive, musculoskeletal and pulmonary involvement, and calcinosis. Laboratory data included complete blood cell count, serum creatine kinase (CK), aldolase and aspartate aminotransferase (AST) levels, B cell count, and serum immunoglobulin levels.

The study was approved by the appropriate ethics committee. Permission for treatment was obtained from all patients' parents and assent was obtained from the patients; all were aware that RTX had not been approved for use in adults or children with DM. Patients received oral information and gave oral consent for being enrolled in the study. In accord with French regulations, patient's informed written consent was not needed for this observational study.

The response to treatment was analyzed by comparing muscle strength and specific organ involvement before and after RTX perfusion at each evaluation. Muscle strength was assessed with MMT. Skin, articular, and/or digestive involvement was assessed according to the physician evaluation as absent or present. For the study, we defined complete clinical response as a clinical state in which rash (heliotope rash, Gottron's papules, or skin ulcers) is absent, and there is no evidence of active myositis (normal

strength and normal muscle enzyme levels), arthritis, or digestive involvement without any modification of immunosuppressive medications within at least the 3 months preceding and following the first infusion of RTX. A severe infection was defined as an infection requiring hospitalization and/or intravenous antibiotics and/or resulting in death. Complete B cell depletion was defined as a peripheral CD19 + B lymphocyte count < 5 cells/ μ l.

RESULTS

Patients. Among the 595 patients registered in the AIR registry between September 2005 and May 2010, 9 patients with JDM (8 girls and 1 boy; Table 1) were enrolled from 5 pediatric and 1 dermatology center. Demographic characteristics and disease duration and manifestations are shown in Table 1. Definite JDM was diagnosed in 7 patients and probable JDM in 2 patients (Table 1). One patient also had cystic fibrosis (Patient 8). The ages of patients at the time of the first infusion of RTX ranged from 6.2 to 16 years. The mean duration of DM from the onset of DM to the first infusion of RTX was 3.4 years (range 1 month to 8.4 yrs). All patients but one had been previously treated with immunosuppressive agents, without efficacy, and experienced a chronic disease course lasting from 11 months to 8.4 years (Table 1). The remaining patient (Patient 1) was newly diagnosed and received corticosteroids, plasma exchange therapy, and RTX because of life-threatening DM with severe muscle involvement associated with capillary leak syndrome (Patient 1). The main indication for RTX treatment was active muscle involvement (7 patients), severe calcinosis (1 patient), or severe abdominal pain associated with abdominal lipomatosis (1 patient). Muscle involvement was associated with skin involvement (7 patients) and gastrointestinal involvement (2 patients). CK level was increased in all patients at diagnosis of JDM, but in only 2 patients at initiation of RTX (Patients 3 and 7). The prolonged disease course before the start of RTX and the poor nutritional status of most of the patients may explain these normal muscle enzyme levels. In Patient 1, CK levels decreased dramatically after receiving plasmapheresis before RTX.

Rituximab regimen. There was wide heterogeneity in the rituximab regimen (Table 1). Premedication with diphenhydramine, paracetamol, and/or methylprednisolone was given 30–60 minutes before the rituximab infusion in all courses. One patient received 2 courses of RTX (Patient 2). All patients received prednisone, with dosage ranging from 0.2 to 2 mg/kg/day, when starting rituximab. Associated treatments are listed in Table 1. RTX was associated with corticosteroid use in 9/9 patients and plasma exchanges in 2/9 patients, and was added to stable background therapy with immunosuppressive drugs in 5/9 patients. Five patients (6 courses) received intravenous immunoglobulins (IGIV) as a replacement treatment after RTX (Patients 1, 2, 3, 7, and 8).

Safety monitoring. One patient (Patient 6) experienced a moderately acute infusion-related event at the onset of the first infusion of RTX, leading to discontinuation of treat-

Table 1. Demographic characteristics at onset of treatment and outcome of 9 patients with JDM treated with rituximab (RTX).

Patient	Course/ Sex	Age at onset of JDM/RTX, yrs	Symptoms	Ab	Previous Treatment (mo since last treatment)	RTX Regimen	Clinical Outcome/ Relapse	Duration of Followup Since First RTX infusion, yrs
1	1 F	8/8.1	Myositis*, rash* (d)	—	PRED* (1.5 mg/kg/day), MP*, PE*, IVIG (0.5)	4 × 375 mg/m ²	CCR/No	3
2	2a F	10/12	Myositis*, rash*, calcinosis*, GI disease* (d)	—	PRED*, MP*, CSA*, MTX (18)	2 × 500 mg/m ²	NE	
	2b F	10/13.3	Myositis*, rash*, calcinosis*, GI disease* (d)	—	PRED* (0.2 mg/kg/day), MMF*, CYC (14), CSA (13), MTX (34)	2 × 375 mg/m ²	CCR/No	2.5
3	3 F	4/7.1	Myositis*, rash*, calcinosis* (p)	ANA	PRED* (1.5 mg/kg/day), MTX*	4 × 375 mg/m ²	CCR/No	3.5
4	4 F	7.6/16	Myositis*, rash*, calcinosis*, GI disease* (d)	ANA	PRED** (0.5 mg/kg/day), PE*, MP, MMF (37), AZA (7), CSA (1), MTX (6)	2 × 500 mg/m ²	NR	2.2
5	5 F	1.5/6.2	Myositis*, rash*, calcinosis* (d)	—	PRED*, MTX (20), CSA (40)	2 × 500 mg/m ²	NR	2 (death)
6	6 F	8/9.6	Myositis*, rash* (p)	ANA	PRED* (0.5 mg/kg/day), MMF*	NE	NE	
7	7 F	9.4/10.3	Myositis*, rash (d)	Anti-Ku	PRED* (1 mg/kg/day), MTX*, PE (1), CSA (3), MP (12)	4 × 375 mg/m ²	NR	0.3
8	8 F	7.5/11.5	Myositis, rash, calcinosis* (d)	ANA	PRED* (0.5 mg/kg/day), MTX (14), CSA*	4 × 375 mg/m ²	NR	3.5
9	9 M	2.5/9	Myositis, rash, GI disease* (abnormal lipomatosis), calcinosis* (d)	ANA	PRED* (0.2 mg/kg/day), MTX (17), CSA (26), IVIG (14)	4 × 375 mg/m ²	NR	4

* Present at the time of starting rituximab; treatment was under way at time of starting rituximab, at a stable dosage for at least 3 months. PRED: prednisone; MP: methylprednisolone; PE: plasma exchange; IVIG: intravenous immunoglobulins; CSA: cyclosporine; MTX: methotrexate; MMF: mycophenolate mofetil; AZA: azathioprine; ANA: antinuclear antibodies; CCR: complete clinical response; NR: no response; NE: not evaluable; GI: gastrointestinal; (p): probable JDM according to Bohan and Peter criteria¹; (d): definite JDM according to Bohan and Peter criteria; Ab: autoantibodies N: normal values.

ment. Another RTX course was not undertaken because of the occurrence of an intestinal perforation 2 weeks after a combination of methylprednisolone pulses and RTX infusions in a patient with severe muscle, cutaneous, and digestive involvement (Patient 2). A second course of RTX, administered 16 months later, was well tolerated in this patient. Localized bacterial infection of the calcinosis sites occurred 2 and 11 months after RTX in Patients 7 and 9, who had had normal IgG level and neutrophil counts at the time of infection. Infections resolved after treatment with oral antibiotics. One patient died suddenly after a fall, from unexplained causes, 2 years after RTX onset, while she still had moderately active myositis (Patient 5).

Clinical and biological responses. A complete clinical response was achieved in 3/6 evaluable courses in 3 patients who had both active muscle and skin involvement (Patients 1, 2, 3), including 2 patients (Patients 2 and 3) who received one immunosuppressive drug at a stable dosage at least 3 months before and then after the onset of RTX, and in one patient (Patient 1) who received plasmapheresis before and during the RTX course (Table 1). Patient 2 also had a digestive involvement, which went into complete remission after RTX infusion. MMT scores achieved normal values within 3 months (Figure 1). Two of these responder patients had normal muscle enzyme levels (CK, AST, aldolase) at onset of RTX and during the followup. The third patient had moderately elevated baseline muscle enzymes (CK 220 U/l, normal 30–150; AST 130 U/l, normal 7–50; aldolase 25 U/l,

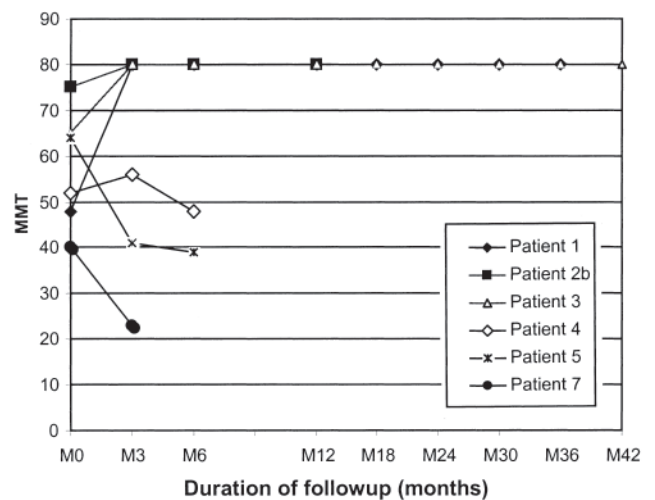


Figure 1. Changes in muscle strength assessed with manual muscle testing scores (MMT) following treatment with rituximab (RTX) in the 6 evaluable patients treated with RTX for severe muscle involvement.

normal 5–18), which normalized 3 months after the onset of treatment. In these 3 responders, steroid therapy was either stopped (Patients 1, 2) 1.5 to 2 years after the first infusion of RTX, or tapered to 15% of the baseline dosage (Patient 3). Among the remaining 3 nonresponder patients who presented with active muscle, skin, and/or digestive involvement, the disease activity remained unchanged in all domains. RTX was also ineffective in treating calcinosis in

the 6 affected patients (Patients 2, 3, 4, 5, 8, and 9) and also chronic abdominal pain (Patient 9). Responders had a shorter disease duration before RTX (< 3.5 yrs) than nonresponders (Figure 1). Complete remission lasted in all of the responders, with a followup ranging from 1.3 to 3 years.

B cell depletion and immunoglobulin level. Complete CD19-positive B cell depletion was effective in all the patients. It lasted more than 7 months in all patients except one nonresponder, in whom it lasted only 4 months (Patient 4). CD19-positive B cell counts returned to normal values within 2 years. Serum immunoglobulin IgM data were available for all the evaluable courses. IgM decreased < 0.35 g/l in 3 patients (Patients 2, 5, 7). One patient who did not receive substitution IVIG had an IgG level < 6 g/l (Patient 5).

DISCUSSION

This open-label study of patients with JDM from the French AIR registry shows that RTX had a satisfactory tolerance profile and clinical efficacy, with a corticosteroid-sparing effect, in a small subset of patients with severe muscle and skin involvement. Conversely, it was not more effective for treating calcinosis than numerous other treatments that were tested.

Tolerance was satisfactory because only 1 patient experienced a moderate infusion-related reaction, despite premedication with antihistamines and methylprednisolone. The main side effect usually attributable to RTX is severe infection, which did not occur in our series. The role of RTX in the 2 reported calcinosis-site infections is questionable, given that such infections also occurred before the onset of treatment and that the patients presented with normal IgG levels and neutrophil counts. The intestinal perforation that occurred 2 weeks after methylprednisolone pulses in combination with RTX in one girl was more likely due to methylprednisolone than to RTX, since the retreatment with RTX was well tolerated. However, the recent report of a possibly T cell-mediated severe ulcerative colitis¹⁵ suggests that RTX must be used with caution in JDM patients with digestive involvement. The death following a fall did not seem to be related to JDM or RTX.

The frequency of some RTX-related side effects, especially the occurrence of hypogammaglobulinemia and neutropenia¹⁶, may have been underestimated as not all patients had been investigated in this regard, in this retrospective study. In addition, longterm followup is required, considering the report of progressive multifocal leukoencephalopathy in a few patients treated with RTX for autoimmune disorders, especially in patients who received immunosuppressive drugs before RTX¹⁷.

We were unfortunately unable to use the response criteria that have been developed^{18,19,20} for this study, since some of the core variables used were not available in the questionnaire developed by the registry. However, we defined complete clinical response as being the physician's

clinical evaluation, the assessment of muscle strength using MMT, and muscle enzyme levels, as was proposed in a recent JDM study²¹. Using these criteria, we found that RTX resulted in a complete clinical response of active muscle, skin, and digestive involvement in 3/6 evaluable patients treated for severe muscle involvement. In these patients, cutaneous and digestive manifestations paralleled the muscle remission, which was observed within 3 months after the first infusion of RTX. RTX was probably effective in 2 of these patients, in whom it was added to a stable background therapy with immunosuppressive drugs. Efficacy per se was more questionable in the third patient, who simultaneously received RTX and plasmapheresis at diagnosis of life-threatening JDM. As described^{6,8,13}, we found that B cell recovery did not always parallel a muscle relapse, in contrast to what has been observed in patients with systemic lupus erythematosus²².

To date, the safety and efficacy of B cell depletion in refractory DM had been assessed in only one small noncontrolled study and a few case reports^{3,4,5,6,7,8,9,10,11,12,13,14}, which gave conflicting results. This variable efficacy of RTX could be explained in part by the differences in the main indication for RTX and in the different outcome measures used, but also by the heterogeneity of JDM, especially the expression of pathological muscle changes. It has recently been shown that the structure of muscle lymphocytic infiltration correlates with the response to treatment, since a lymphoid follicle-like structure was associated with severe and difficult-to-treat disease, whereas diffuse infiltrates or lymphocytic aggregates lacking the follicle-like organization were responsive to standard therapy with steroids and methotrexate²³. The authors hypothesized that follicle-like structures represented inflammatory foci that were more difficult to disrupt with first-line treatment, and that anti-B cell therapy might be beneficial in such cases.

Recent survey data and expert opinion resulted in a consensus on the initial use of corticosteroids and methotrexate for treating moderately severe JDM²⁴. In patients who have insufficient response to or severe side effects with these treatments, the choice of second-line treatment remains empiric. Cyclosporine has been used in many centers as a steroid-sparing agent, but efficacy was supported only by findings from several small case series¹; a randomized trial to compare initial treatment with corticosteroids against treatment with corticosteroids plus methotrexate or corticosteroids plus cyclosporine is under way²⁵. Recently, mycophenolate mofetil was shown to yield a significant decrease in both muscle and skin inflammation in patients with JDM^{26,27}. Additional controlled studies are required to determine the roles of these treatments and RTX in second-line therapy for refractory JDM.

There are several limitations to our study. First, because of the retrospective assessment of efficacy, some data were missing, particularly an objective cutaneous disease activity

score. We think the physician's evaluation of cutaneous disease activity may be taken into account in this series since a complete clinical response was recorded, comprising a complete remission of active skin lesions. Second, the absence of early muscle strength assessment within the month following the first infusion of RTX did not allow precise evaluation of the delay of response. Third, the frequency of some RTX-related side effects, particularly hypogammaglobulinemia and neutropenia, may have been underestimated because of unrelated investigations. Finally, the lack of a control group of JDM patients who did not receive RTX did not allow for definite conclusions.

This small series from the AIR registry suggested that RTX may be effective for treating muscle and skin involvement in a subset of children with refractory JDM, and that its safety profile was satisfactory. Further controlled trials are needed to identify patients with JDM who might benefit from RTX treatment.

ACKNOWLEDGMENT

We thank Catherine Villeneuve for help in preparing the report.

REFERENCES

- Feldman BM, Rider LG, Reed AM, Pachman LM. Juvenile dermatomyositis and other idiopathic inflammatory myopathies of childhood. *Lancet* 2008;371:2201-12.
- Khanna S, Reed AM. Immunopathogenesis of juvenile dermatomyositis. *Muscle Nerve* 2010;41:581-92.
- Chung L, Genovese MC, Fiorentino DF. A pilot trial of rituximab in the treatment of patients with dermatomyositis. *Arch Dermatol* 2007;143:763-7.
- Touma Z, Arayssi T, Kibbi L, Masri AF. Successful treatment of cardiac involvement in dermatomyositis with rituximab. *Joint Bone Spine* 2008;75:334-7.
- Haroon M, Devlin J. Rituximab as a first-line agent for the treatment of dermatomyositis. *Rheumatol Int* 2010 Mar 26. [Epub ahead of print]
- Levine TD. Rituximab in the treatment of dermatomyositis: an open-label pilot study. *Arthritis Rheum* 2005;52:601-7.
- Dinh HV, McCormack C, Hall S, Prince HM. Rituximab for the treatment of the skin manifestations of dermatomyositis: a report of 3 cases. *J Am Acad Dermatol* 2007;56:148-53.
- Noss EH, Hausner-Sypek DL, Weinblatt ME. Rituximab as therapy for refractory polymyositis and dermatomyositis. *J Rheumatol* 2006;33:1021-6.
- Feist E, Dorner T, Sorensen H, Burmester GR. Long lasting remissions after treatment with rituximab for autoimmune myositis. *J Rheumatol* 2008;35:1230-2.
- Sultan SM, Ng KP, Edwards JC, Isenberg DA, Cambridge G. Clinical outcome following B cell depletion therapy in eight patients with refractory idiopathic inflammatory myopathy. *Clin Exp Rheumatol* 2008;26:887-93.
- Rios Fernández R, Callejas Rubio JL, Sánchez Cano D, Sáez Moreno JA, Ortego Centeno N. Rituximab in the treatment of dermatomyositis and other inflammatory myopathies. A report of 4 cases and review of the literature. *Clin Exp Rheumatol* 2009;27:1009-16.
- Gottenberg JE, Guillevin L, Lambotte O, Combe B, Allanore Y, Cantagrel A, et al. Tolerance and short term efficacy of rituximab in 43 patients with systemic autoimmune diseases. *Ann Rheum Dis* 2005;64:913-20.
- Cooper MA, Willingham DL, Brown DE, French AR, Shih FF, White AJ. Rituximab for the treatment of juvenile dermatomyositis: a report of four pediatric patients. *Arthritis Rheum* 2007; 56:3107-11.
- Tzaribachev N, Koetter I, Kuemmerle-Deschner JB, Schedel J. Rituximab for the treatment of refractory pediatric autoimmune diseases: a case series. *Cases J* 2009;2:6609.
- Ardelean DS, Gonska T, Wires S, Cutz E, Griffiths A, Harvey E, et al. Severe ulcerative colitis after rituximab therapy. *Pediatrics* 2010;126:e243-6.
- Voog E, Morschhauser F, Solal-Celigny P, Benyunes MC, Multani PS, Saunders A. Neutropenia in patients treated with rituximab. *N Engl J Med* 2003;348:2691-3.
- Carson KR, Evens AM, Richey EA, Habermann TM, Focosi D, Seymour JF, et al. Progressive multifocal leukoencephalopathy after rituximab therapy in HIV-negative patients: a report of 57 cases from the Research on Adverse Drug Events and Reports project. *Blood* 2009;113:4834-8.
- Rider LG, Giannini EH, Harris-Love M, Joe G, Isenberg D, Pilkington C, et al. Defining clinical improvement in adult and juvenile myositis. *J Rheumatol* 2003;30:603-17.
- Oddis CV, Rider LG, Reed AM, Ruperto N, Brunner HI, Konneru B, et al. International consensus guidelines for trials of therapies in the idiopathic inflammatory myopathies. *Arthritis Rheum* 2005;52:2607-15.
- Ruperto N, Pistorio A, Ravelli A, Rider LG, Pilkington C, Oliveira S, et al. The Paediatric Rheumatology International Trials Organisation provisional criteria for the evaluation of response to therapy in juvenile dermatomyositis. *Arthritis Care Res* 2010;62:1533-41.
- Stringer E, Singh-Grewal D, Feldman BM. Predicting the course of juvenile dermatomyositis: significance of early clinical and laboratory features. *Arthritis Rheum* 2008;58:3585-92.
- Willems M, Haddad E, Niaudet P, Koné-Paut I, Bensman A, Cochat P, et al. Rituximab therapy for childhood-onset systemic lupus erythematosus. *J Pediatr* 2006;148:623-7.
- López De Padilla CM, Vallejo AN, Lacomis D, McNallan K, Reed AM. Extranodal lymphoid microstructures in inflamed muscle and disease severity of new-onset juvenile dermatomyositis. *Arthritis Rheum* 2009;60:1160-72.
- Huber AM, Giannini EH, Bowyer SL, Kim S, Lang B, Lindsley CB, et al. Protocols for the initial treatment of moderately severe juvenile dermatomyositis: results of a Children's Arthritis and Rheumatology Research Alliance Consensus Conference. *Arthritis Care Res* 2010;62:219-25.
- Pediatric Rheumatology International Trials Organization. Juvenile dermatomyositis trial. [Internet. Accessed March 14, 2011.] Available from: http://www.printo.it/project_ongoing_detail.asp?ProjectID=14
- Rouster-Stevens KA, Morgan GA, Wang D, Pachman LM. Mycophenolate mofetil, a possible therapeutic agent for children with juvenile dermatomyositis. *Arthritis Care Res* 2010;62:1446-51.
- Dagher R, Desjonquères M, Duquesne A, Quartier P, Bader-Meunier B, Fischbach M, et al. Mycophenolate mofetil in juvenile dermatomyositis: a case series. *Rheumatol Int* 2010 Dec 9. [Epub ahead of print]