

Use of Muscle Biopsies for Diagnosis of Systemic Vasculitides

BAPTISTE HERVIER, CÉCILE DURANT, AGATHE MASSEAU, THIERRY PONGE, MOHAMED HAMIDOU, and JEAN-MARIE MUSSINI

ABSTRACT. Objective. Few studies have investigated the use of muscle biopsies (MB) for the diagnosis of systemic vasculitides (SV). We aimed to evaluate the diagnostic use of MB in this condition.

Methods. We reviewed 310 consecutive MB performed in our center between 2000 and 2008 and correlated them with clinical data from the corresponding patients. Thirty-one of the patients, representing a total of 33 MB, were diagnosed with active SV. MB were considered positive when they demonstrated either necrotizing vasculitis or nonnecrotizing vasculitis.

Results. Twenty-two of the 33 MB were positive (sensitivity of 66.7%), with necrotizing vasculitis and nonnecrotizing vasculitis being equally frequent. The SV were antineutrophil cytoplasmic antibody (ANCA)-associated in 22 patients (71%), and ANCA-negative in 9 cases (29%). Neither the type nor the clinical spectrum of the SV was predictive of MB positivity. None of the muscle symptoms (myalgias or biological rhabdomyolysis) were correlated with MB positivity. All the biopsies were performed uneventfully.

Conclusion. The feasibility and positive predictive value of MB make it a valuable tool for ruling out a diagnosis of SV. Since no clinical signs could predict its positivity, MB should be considered in all suspected cases of SV. Unlike other biopsies, including kidney biopsy, MB had no prognostic value. (J Rheumatol First Release Dec 1 2010; doi:10.3899/jrheum.100390)

Key Indexing Terms:

MUSCULAR BIOPSY VASCULITIS ANTINEUTROPHIL CYTOPLASMIC ANTIBODY

The diagnosis of systemic vasculitides (SV), including antineutrophil cytoplasmic antibody (ANCA)-associated vasculitides and ANCA-negative vasculitides, requires histologic confirmation¹. In most cases, biopsy of an involved tissue is performed. However, the diagnosis of SV can be particularly difficult in certain patients, including severely affected patients, those with biopsy contraindications, or in cases of a negative biopsy.

Muscle biopsies (MB) are regularly performed for the diagnosis of other conditions such as myositis, and the feasibility and safety of this procedure are usually excellent. However, very few data are available regarding the use of MB in SV. Indeed, MB is rarely performed in SV because a physical examination usually does not reveal any neuromuscle involvement².

To our knowledge, use of MB in SV has not been studied separately from that of peripheral nerve biopsy^{3,4}. We retro-

spectively analyzed all MB performed at our center. We then analyzed the sensitivity and specificity of MB in patients with SV.

MATERIALS AND METHODS

In our retrospective study, we reviewed all the MB and neuromuscular biopsies (n = 310) performed between January 2000 and October 2008 at our university hospital, together with the corresponding patient diagnoses. We retrospectively identified 3 conditions in the subset of patients with SV who underwent an MB in all but 3 cases. These conditions included unexplained myalgias and/or increased creatine phosphokinase (CPK) level (15 cases), unexplained fever and/or blood inflammation (6 cases), and suspicion of SV but with other organ biopsy contraindications or previous negative result (9 cases).

The diagnosis of SV involving medium size and small vessels was made according to Chapel Hill criteria⁵. Patients with giant cell arteritis or localized vasculitides were excluded. The diagnosis for each patient was based on histologic data, including MB, and/or a positive serological test (including ANCA, cryoglobulinemia, or rheumatoid factor).

When performed alone, MB was done in a highly vascularized muscle (the vastus lateralis of quadriceps femoris muscle). Neuromuscular biopsies were performed in the peroneus brevis muscle (n = 4). When a cutaneous biopsy was necessary, the MB was performed in tibialis anterior (n = 4) or extensor hallucis longus muscle (n = 1). All these MB were "open MB."

A positive MB was defined by the presence of necrotizing vasculitis or nonnecrotizing vasculitis (also defined as microvasculitis^{6,7}: inflammatory cells infiltrating small-vessel walls with no necrosis) seen by optical microscopy (Figures 1 and 2). Immunohistochemical analyses were not performed systematically. In our study, the histological specificity of the vasculitis (i.e., the location of the fibrinoid necrosis into the vessel wall, and/or its association to a granuloma or fibrosis, the cellular type of the cell infiltrate) was not recorded.

From the Department of Internal Medicine and Department of Pathology, Hôtel Dieu, Centre Hospitalier Universitaire (CHU) de Nantes, Nantes, France.

B. Hervier, MD; C. Durant, MD; A. Masseau, MD; T. Ponge, MD; M. Hamidou, MD, PhD, Department of Internal Medicine; J.-M. Mussini, MD, Department of Internal Medicine and Department of Pathology, Hôtel Dieu, CHU de Nantes.

Address correspondence to Dr. B. Hervier, Hôtel Dieu, Place Alexis Ricordeau, 44093 Nantes cedex, France. E-mail: bhervier@yahoo.fr
Accepted for publication October 5, 2010.

Personal non-commercial use only. The Journal of Rheumatology Copyright © 2010. All rights reserved.

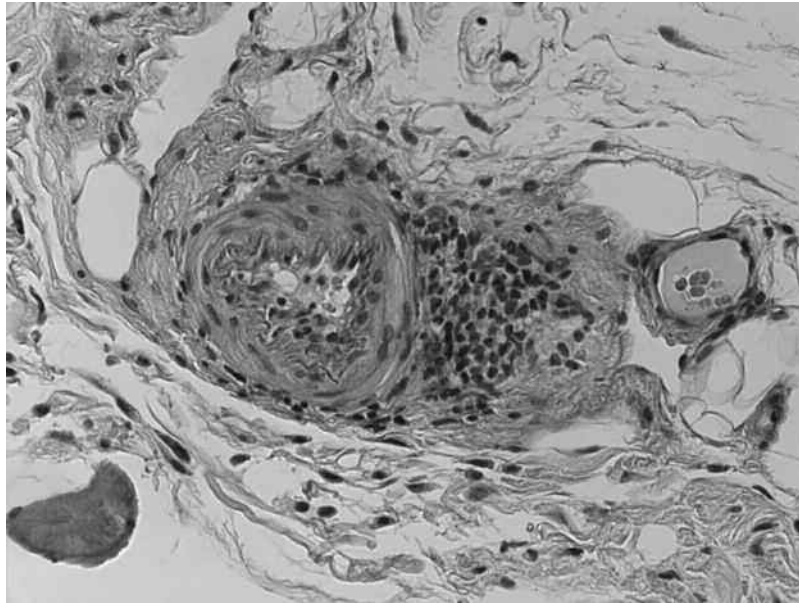


Figure 1. Paraffin section of quadriceps muscle (4 μ m, H&E stain). Necrotizing vasculitis of a small arteriole exhibiting acute lesions with fibrinoid necrosis of the adventice, media, and intima.

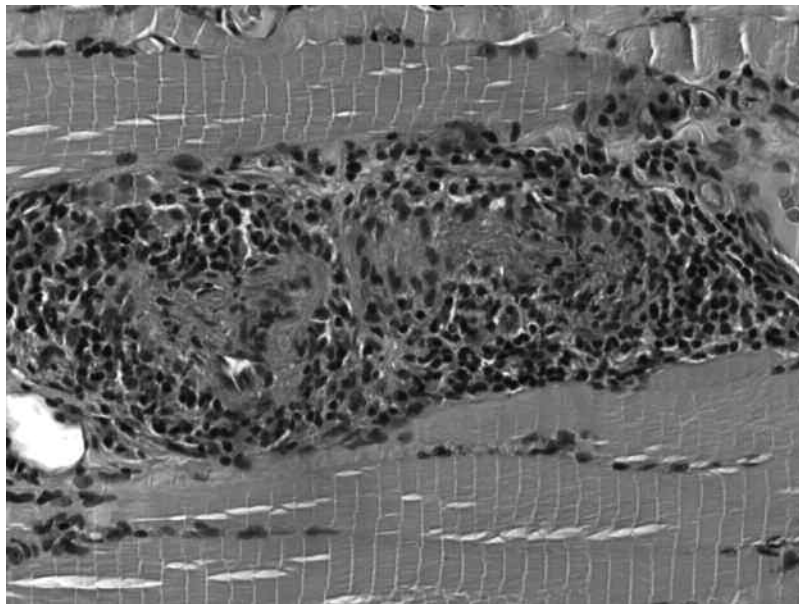


Figure 2. Paraffin section of quadriceps muscle (4 μ m, H&E stain). Nonnecrotizing vasculitis of a small vessel: note inflammatory cells (lymphocytes) infiltrating and disorganizing the adventitia. Necrosis is absent.

Statistical analysis was performed using GraphPad software. Fisher's exact test was used to compare categorical data.

Our hospital ethical committee approved our study. Because the patients were anonymously reported, in accord with French law, no patient consent form was required.

RESULTS

Of the 310 consecutive MB and neuromuscular biopsies,

117 showed signs of dermatomyositis or polymyositis, according to Bohan and Peter's criteria⁸; 11 showed inclusion body myositis and 22 showed vasculitis. The remaining 160 biopsies were considered nonspecific or normal.

Among the patients who provided these biopsies, 31 presented with an SV (18 men, 13 women, median age 69 yrs, range 32–83). Two of those patients underwent 2 MB during

their disease course, so a total of 33 MB were performed during active SV. The SV distribution was ANCA-negative SV (n = 9, 29%) and ANCA-associated SV (n = 22, 71%). The SV corresponded to Wegener's granulomatosis (n = 7, 23%), microscopic polyangiitis (n = 8, 26%), Churg-Strauss syndrome (n = 7, 23%), polyarteritis nodosa (n = 5, 16%), rheumatoid arthritis-associated vasculitides (n = 2, 6%), and cryoglobulinemia (n = 2, 6%).

Twenty-two of the 33 MB performed in the patients with SV were positive and 11 were negative. Histology of the positive biopsies showed equal incidences of necrotizing vasculitis (n = 11) and nonnecrotizing vasculitis (n = 11; Figures 1 and 2). The sensitivity of MB was 67% and the specificity was > 99%. In 2 cases, MB provided the only specific evidence of SV, and we therefore calculated the specificity on the assumption that these 2 cases could be false positives. The negative and positive predictive values of MB were 96% and 92%, respectively.

The clinical spectra of the 33 episodes of active SV are summarized in Table 1. Thirteen patients had started steroids prior to the muscle biopsy.

No correlation with any specific organ involvement was detected. Myalgia was not associated with muscle vasculitis (3/11 vs 10/22 patients; $p = 0.46$), and an increased CPK level (1/11 vs 3/22; $p = 1$) was not correlated with a positive MB.

Electromyography and muscular magnetic resonance imaging were not systematically performed, and we were therefore unable to study any correlation between these and the presence of muscle vasculitis. MB was performed uneventfully in all cases.

In addition to MB, a total of 50 other biopsies were performed in patients with SV, including skin (n = 15), temporal artery (n = 9), sinus (n = 8), kidney (n = 6), lung (n = 5), peripheral nerve (n = 4), liver (n = 2), and heart (n = 1). When performed (n = 4), peripheral nerve biopsies were always combined with MB. A total of 19 biopsies excluding MB disclosed the presence of an SV. The sensitivity of these histologic techniques varied from 0% (sinus) to 100% (peripheral nerve or heart). A positive MB was the only histological finding for the SV diagnosis in 10 cases (30%). However, in 5 other cases, MB could have allowed the clinician to avoid performing 2 temporal arteritis biopsies, 2 nerve biopsies, and 1 myocardial biopsy, which are considered riskier than MB. So we could consider that MB was essential in 15/33 cases (45%).

DISCUSSION

The sensitivity of MB for detecting muscle vasculitis or microvasculitis in this series was good (67%). This sensitivity was comparable with that reported in a previous series of neuromuscular biopsies⁹. Further, the specificity of MB was close to 100%.

The positive and negative predictive values of this technique were excellent, irrespective of the type of SV

(ANCA-associated or ANCA-negative vasculitis). Indeed, in our series of SV, 6 different SV subtypes were reported, and each subtype was as frequent as previously reported⁹. Based on these results, we suggest that MB should be a major tool for the diagnosis of SV.

Interestingly, MB positivity in SV was not related to either clinical or biological signs of muscle involvement (including myalgia or CPK level). This could be due to the lack of an ischemic effect on muscle fibers. Indeed, while many capillaries are obstructed in dermatomyositis, affected vessels in SV do not belong to the terminal vascular system. In dermatomyositis¹⁰, vessel obstruction causes necrosis, while vascular compensation can occur in SV, and in our study, necrotic or regenerating fibers were thus seen in only 7 cases. Also, myalgias are not specifically caused by ischemia, but can also occur in cases of systemic inflammation (viral infections and autoinflammatory syndromes, for example), when the levels of inflammatory cytokines [including interleukin 1 (IL-1), IL-6, or tumor necrosis factor- α] are increased.

The absence of clinico-histologic correlations suggests that MB should be performed more frequently in the context of SV, especially given that MB performed without peripheral nerve biopsy had no apparent side effects. However, SV in all 4 patients with peripheral nerve neuropathies was diagnosed by nerve biopsies. This confirmed a more useful result of peripheral nerve biopsy compared to MB in cases with neurological symptoms. This could be due to the fact that peripheral nerve biopsies were performed in an involved tissue (all the patients complained of paresthesia), while MB were effectively performed blind (absence of myalgias or diffuse but not localized myalgias in some cases). In cases of SV, a positive MB demonstrates the systemic involvement of highly vascularized tissues. However, false-negative MB can occur because the amount of muscle removed for the MB is very small compared to the entire muscle mass.

The sensitivity of MB in this patient series was greater than that of any other organ, except for peripheral nerves, but including sinus, temporal artery, lung, and even skin biopsies (positivity of 60%)¹. This also suggests that MB should be performed more frequently.

However, MB had no prognostic value, unlike renal biopsy, and may not be helpful for differential diagnosis, especially in cases with pulmonary nodules. We did not investigate the persistence of muscle vasculitis during the course of the disease, and were therefore unable to determine if a positive MB result alone could diagnose relapse.

The role of MB in the diagnosis of SV requires further prospective evaluation, but our results suggest that MB should be performed more frequently in this context. The sensitivity and feasibility of MB are better than those of many other organ biopsies. With the exception of cases with kidney and peripheral nerve involvement, MB could repre-

Table 1. Patient characteristics and histology.

Patient	Age, yrs	Diagnosis	Autoimmunity	Myalgia	Increased CPK	Organ Involvement	Muscle Biopsy Result	Other Noncontributive Biopsy	Other Contributive Biopsy
1	79	WG	PR3-ANCA			CNS, L, K, A, S, GI	Negative	K	
2	77	MPA	MPO-ANCA			N, K	Negative		N, K
3	71	PAN		Yes		N, A, S	Negative	TA	S
4	46	WG	MPO-ANCA			L, A, S, ENT, O	Negative	S	L
5	69	WG	PR3-ANCA	Yes		N, K, A, S, ENT	Negative	S, ENT	K
6	42	CSS				L, S, H	Negative	S	
7	72	MPA	MPO-ANCA	Yes		L, A, S, ENT, O	Negative	S, L	
8	76	WG	PR3-ANCA			L, S, ENT, H	Negative	S, ENT	
9	75	Cryo	Cryo			N	Negative	TA	N
10	81	WG	MPO-ANCA			L, A, ENT	Negative	ENT, L	
11	32	CSS			Yes	L, K, S, ENT	Negative	K, S	
12	79	WG	PR3-ANCA			L, CNS	Vasculitis		
13	49	RA	RF			N, S, P	Vasculitis	S	
14	65	MPA	MPO-ANCA	Yes		N, S	Vasculitis		TA
15	68	PAN*		Yes		N, A, S	Vasculitis	TA	
16	79	WG	PR3-ANCA	Yes	Yes	A, ENT	Vasculitis	TA, ENT	
17	57	PAN				N, A, S	Vasculitis	S	N
18	55	CSS			Yes	N, L, ENT	Vasculitis	ENT	N
19	55	MPA	MPO-ANCA	Yes		N, A	Vasculitis		
20	61	RA	RF			N, A, S	Vasculitis	Liv	S
21	75	MPA	MPO-ANCA			L, K	Vasculitis	Liv, TA	K
22 [†]	74	WG	MPO-ANCA	Yes		L, K, A, S, ENT	Vasculitis	TA, S, ENT, Liv	K
23	79	CSS	MPO-ANCA			N, K, A, S, ENT	Nonnecrotizing vasculitis		
24	72	PAN		Yes	Yes	L, K, A, ENT	Nonnecrotizing vasculitis	ENT	TA
25	73	MPA	MPO-ANCA			N, L	Nonnecrotizing Vasculitis		L
26	54	PAN*		Yes		N, A	Nonnecrotizing Vasculitis		
27	57	MPA	MPO-ANCA	Yes		N, S	Nonnecrotizing vasculitis		
28	43	Cryo	Cryo	Yes		N, A, S	Nonnecrotizing vasculitis		S
29 [†]	73	MPA	MPO-ANCA	Yes		N, S	Nonnecrotizing vasculitis		S
30	83	CSS				L, K	Nonnecrotizing vasculitis	TA	
31	57	MPA	MPO-ANCA			N, S, O	Nonnecrotizing vasculitis		S
32	57	CSS	MPO-ANCA			N, L, ENT	Nonnecrotizing vasculitis	ENT	
33	56	CSS				N, L, S, H	Nonnecrotizing vasculitis		H

* Diagnosis based only on the muscle biopsy. [†] Second biopsy for same patient (Patients 7 and 10). CPK: creatine phosphokinase; WG: Wegener's granulomatosis; ANCA: antineutrophil cytoplasmic antibodies; PR3: proteinase 3; MPO: myeloperoxidase; MPA: microscopic polyangiitis; PAN: polyarteritis nodosa; CSS: Churg-Strauss syndrome; RA: rheumatoid arthritis; Cryo: cryoglobulinemia; RF: rheumatoid factor; N: peripheral nerve; O: ophthalmic involvement; L: lung; S: skin; CNS: central nervous system; GI: gastrointestinal tract; A: arthralgia/arthritis; K: kidney; Liv: liver; H: heart; TA: temporal artery; P: prostate; ENT: ear, nose, and throat.

sent a major tool for the diagnosis of SV, especially in severe cases.

REFERENCES

- Jayne D. The diagnosis of vasculitis. *Best Pract Res Clin Rheumatol* 2009;23:445-53.
- Birnbaum J, Danoff S, Askin FB, Stone JH. Microscopic polyangiitis presenting as a "pulmonary-muscle" syndrome: is subclinical alveolar hemorrhage the mechanism of pulmonary fibrosis? *Arthritis Rheum* 2007;56:2065-71.
- Bennett DL, Groves M, Blake J, Holton JL, King RH, Orrell RW, et al. The use of nerve and muscle biopsy in the diagnosis of vasculitis: a 5 year retrospective study. *J Neurol Neurosurg Psychiatry* 2008;79:1376-81.
- Vital C, Vital A, Canron MH, Jaffre A, Viallard JF, Ragnaud JM, et

- al. Combined nerve and muscle biopsy in the diagnosis of vasculitic neuropathy. A 16-year retrospective study of 202 cases. *J Peripher Nerv Syst* 2006;11:20-9.
5. Jennette JC, Falk RJ, Andrassy K, Bacon PA, Churg J, Gross WL, et al. Nomenclature of systemic vasculitides. Proposal of an international consensus conference. *Arthritis Rheum* 1994;37:187-92.
6. Dyck PJ, Norell JE, Dyck PJ. Microvasculitis and ischemia in diabetic lumbosacral radiculoplexus neuropathy. *Neurology* 1999;53:2113-21.
7. Vincent D, Dubas F, Hauw JJ, Godeau P, Lhermitte F, Buge A, et al. Nerve and muscle microvasculitis in peripheral neuropathy: a remote effect of cancer? *J Neurol Neurosurg Psychiatry* 1986;49:1007-10.
8. Bohan A, Peter JB. Polymyositis and dermatomyositis (second of two parts). *N Engl J Med* 1975;292:403-7.
9. Pagnoux C, Seror R, Henegar C, Mahr A, Cohen P, Le Guern V, et al. Clinical features and outcomes in 348 patients with polyarteritis nodosa: a systematic retrospective study of patients diagnosed between 1963 and 2005 and entered into the French Vasculitis Study Group Database. *Arthritis Rheum* 2010;62:616-26.
10. Dalakas MC, Hohlfeld R. Polymyositis and dermatomyositis. *Lancet* 2003;362:971-82.