



evaluating BME in the cervical spine has shown that it is a common finding in individuals with RA who have neck pain or myelopathy, but it is not known whether the same is true for asymptomatic patients<sup>4</sup>.

The aims of this study were (1) to test the reliability and feasibility of a new MRI scoring system devised to quantify BME, synovitis, and erosions in the RA cervical spine; and (2) to determine whether neck pain or other markers of rheumatoid disease activity were associated with MRI features of inflammation or damage in the cervical spine.

## MATERIALS AND METHODS

We prospectively studied 30 patients (15 with neck pain, 15 without) over the age of 18 years with seropositive erosive RA, who had at least moderately active disease [Disease Activity Score 28-joint count (DAS28) > 3.2] from a single center in Auckland, New Zealand. We excluded patients with a history of previous neck surgery, a known cause of neck pain (other than RA), or renal impairment (glomerular filtration rate < 50 ml/min), or who were unable to have an MRI scan for any reason. The study was approved by the Northern Regional X Ethics Committee, New Zealand. Patients gave their written informed consent for participation in the study.

A full clinical evaluation including disease history, joint count, and neurological examination was performed. Neurological status was recorded according to a modified Ranawat score<sup>12</sup>: grade 0 = no neurological abnormality; grade 1: hyperreflexia, asymptomatic; grade 2 = sensory alteration; grade 3 = motor weakness, ambulatory; grade 4 = motor weakness, non-ambulatory.

Laboratory tests [C-reactive protein (CRP)], erythrocyte sedimentation rate, rheumatoid factor, anti-cyclic citrullinated peptide antibodies, and plain radiographs of the neck in flexion and extension were performed on the same day as the MRI scan. Participants recorded neck pain, global health, and overall pain on a visual analog scale (VAS), and completed a Health Assessment Questionnaire version 2 (HAQ II).

**MRI imaging protocol.** All patients were scanned on a 1.5 Tesla system (Siemens Avanto, Siemens Medical, Erlangen, Germany) using a phased-array neck coil. The following sequences were acquired: sagittal T1-weighted (T1w) turbo spin-echo [TR 581 ms, TE 14 ms, field of view (FOV) 230 mm, thickness 3 mm, turbo factor 5]; sagittal short-tau inversion recovery (STIR): TR 3500 ms, TE 54 ms, FOV 230 mm, thickness 3 mm, turbo factor 7, TI 140 ms; coronal STIR (TR 4050 ms, TE 54 ms, FOV 230 mm, thickness 3 mm, turbo factor 7, TI 150 ms); and axial T2-weighted turbo spin-echo (TR 3000 ms, TE 90 ms, FOV 180 mm, thickness 4 mm, turbo factor 11). After injection of intravenous gadodiamide contrast agent (Omniscan 10 cc; GE Healthcare, Princeton, NJ, USA) these sequences were acquired: sagittal fat-suppressed T1w turbo spin-echo (TR 545 ms, TE 14 ms, FOV 230 mm, thickness 3 mm, turbo factor 5) and coronal volumetric interpolated breath-hold examination (VIBE). VIBE is a gradient-echo T1w water excitation sequence (TR 14.6 ms, TE 6.07 ms, FOV 230 mm, thickness 1.5 mm). Images were viewed on standard Dicom-compliant workstations.

**MRI scoring.** A new scoring system was developed by 3 of the authors (RS, FM, and AD); to score MRI BME, each cervical vertebra (C1–C7) was divided into 4 components: (1) body, (2) left facet joint and transverse process, (3) right facet joint and transverse process, and (4) laminae and spinous process. For C1, the anterior arch substituted for the body. The dens of C2 was considered an additional fifth component. Each vertebral component was semiquantitatively scored 0–3 based on the estimated volume of BME present (where score 0 = no BME; 1 = < 33% BME; 2 = 33%–66% BME; and 3 = > 66% BME. The maximum possible score for BME was 87. Synovitis and erosions were recorded as present (score = 1) or absent (score = 0) for each vertebral level as a whole. Below the C2 level, this meant that only the facet joints were scored for synovitis. The maximum possible

score for synovitis and erosions was 7 for each. Images were independently scored by 2 authors (AD and RR), both specialist radiologists with experience in reading musculoskeletal MRI scans. These readers were blinded to clinical details. All MRI sequences obtained were used to determine the most accurate BME, erosion, and synovitis score. Examples of the sequences used to score BME are shown in Figure 1. The MRI scores generated by AD (the more experienced of the 2 readers) were used for analysis of correlations between all radiographic and clinical variables.

**Plain radiographs of cervical spine.** Each patient had a plain radiograph in standard flexion and extension views of the cervical spine. The anterior atlantodental interval (AADI) was measured from the posterior inferior margin of the anterior arch of C1 to the anterior border of the dens. This distance was measured perpendicular to the dens in flexion and extension. An AADI > 3 mm in either flexion or extension was considered abnormal<sup>13</sup>.

**Feasibility questionnaire.** The 2 radiologists (AD and RR) who performed the scoring completed a feasibility questionnaire regarding the scoring method after completion of the scoring (data not shown).

**Statistical analysis.** SPSS 17 was used for statistical analysis. Intraclass correlation coefficients (ICC) were used to determine interobserver reliability. The means of continuous variables were compared between groups using Student's *t* tests. Chi-square tests were used for categorical variables. Variables assessed for correlation between clinical and radiological parameters were not normally distributed; therefore a nonparametric approach based on ranks was required, using the Spearman rank correlation coefficient method. *P* values < 0.05 were considered statistically significant.

## RESULTS

Patient characteristics including disease activity, global health, functional scores, and medication use are shown in Table 1. Overall, pain scores were higher in patients with neck pain than in those without (mean VAS 39.9 vs 17.8, respectively; *p* < 0.01) and 68 tender joint counts were also higher (25.0 vs 13.7; *p* = 0.03). Otherwise there were no significant differences in disease activity scores or disease duration between the groups. Disease duration ranged from 2 to 528 months. BME was present in 14 patients, of whom 9/14 (64%) had atlantoaxial BME, 10/14 (71%) had subaxial BME, and 5/14 (36%) had both. AADI > 3 mm (range 4–9 mm) was found in 5 patients and 4 of these belonged to the group with neck pain. Three of the 5 patients had atlantoaxial BME, and all 5 had erosions and synovitis at the atlantoaxial level. Abnormal neurological findings (modified Ranawat score ≥ 1) were observed in 8/30 patients: 1 with hyperreflexia only (score 1), 3 with objective sensory abnormalities (score 2), and 4 who had objective motor weakness but who remained ambulatory (score 3).

**Reliability.** Results of the reliability analysis are shown in Table 2. The ICC for interobserver reliability for all BME scores was moderate (ICC = 0.51). There was better agreement between observers for subaxial scores (ICC = 0.59) than for atlantoaxial scores (ICC = 0.40). Reliability improved to 0.67 if only the vertebral bodies and dens were considered in the scoring system. Omission of scans where fat suppression failed did not make a significant difference to interobserver reliability for BME (data not shown). If the presence of BME was dichotomized to “yes” or “no” for each vertebral body, the reliability was lower (ICC = 0.48)

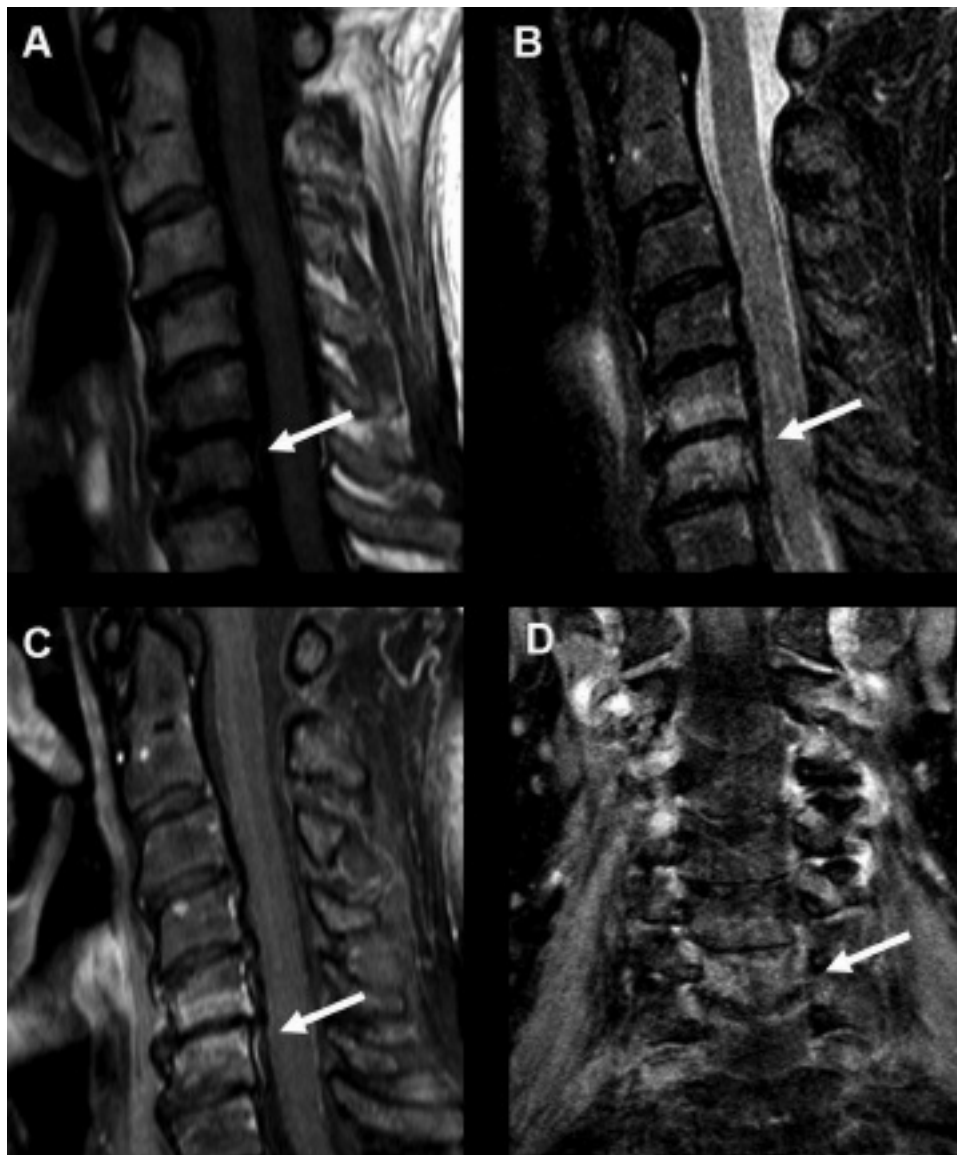

Figure 1. A. Sagittal T1-weighted image. B. Sagittal short-tau inversion recovery image. C. Sagittal T1-weighted postcontrast image. D. Coronal VIBE (volumetric interpolated breath-hold examination) image. Note bone marrow edema at C5 and C6 (arrows).

than if the vertebral bodies were semiquantitatively scored 0–3 (ICC = 0.67). The ICC for synovitis and erosions was moderate at 0.57 for both.

**Correlations.** Correlations were investigated using data from the senior radiologist (AD). Spearman’s rho for the correlation between total BME score and the total erosion score was 0.70 ( $p < 0.01$ ). This association was weaker when individual levels were examined, i.e., the correlation between BME of the vertebral bodies (including dens) and erosion at the same level was 0.39 ( $p < 0.05$ ). There was a strong correlation between the total erosion score and total synovitis score (Spearman’s rho = 0.88,  $p < 0.01$ ) and also for synovitis at the same site as erosion (Spearman’s rho =

0.60,  $p < 0.01$ ). The erosion score correlated with neurological status as determined by the modified Ranawat scale (Spearman’s rho = 0.48,  $p < 0.01$ ). Two of the 5 patients with AADI > 3 mm had abnormal neurological findings ( $\geq 1$  on the modified Ranawat scale) compared to 6/25 with a normal AADI ( $p = 0.59$ ).

Clinical measures of rheumatoid disease activity (DAS scores, CRP, tender or swollen joint counts) did not correlate with BME, MRI erosions, or synovitis in the cervical spine. The details of these relationships are shown in Table 3. There was a weak but statistically significant correlation between rheumatoid factor titer, BME, and synovitis (Spearman’s rho = 0.39 and 0.40, respectively,  $p < 0.05$  for

Table 1. Patient characteristics. All measures are mean values unless otherwise specified.

	No Neck Pain, n = 15	Neck Pain, n = 15	p
Age, yrs	57.9	57.6	NS
M/F, n	2/13	1/14	NS
Duration of disease, mo	156	186	NS
HAQ II score	0.73	1.23	NS
68 tender joint count	13.7	25.0	0.03
66 swollen joint count	7.6	5.7	NS
ESR, mm/h	40.0	28.7	NS
CRP, mg/l	11.1	6.9	NS
Morning stiffness, min	13.5	43.7	NS
Overall pain VAS, 0–100 mm	17.8	39.9	0.004
Patient global VAS, 0–100 mm	24.8	34.0	NS
DAS28 3-variable with CRP	3.96	4.37	NS
Methotrexate, mg (n)	15.3 (8)	15.7 (11)	NS
Other DMARD*, n (%)	10 (67)	10 (67)	NS
Prednisone, mg (n)	9.0 (8)	9.0 (10)	NS
Anti-TNF therapy, n (%)	4 (27)	2 (13)	NS
Positive RF or anti-CCP antibodies, n (%)	15 (100)	15 (100)	NS
Peripheral erosions, n (%)	15 (100)	15 (100)	NS

\* Leflunomide, sulfasalazine, and hydroxychloroquine. DMARD: disease modifying antirheumatic drug; HAQII: Health Assessment Questionnaire version II; ESR: erythrocyte sedimentation rate; CRP: C-reactive protein; VAS: visual analog score; DAS28: Disease Activity Score 28 joint count; TNF: tumor necrosis factor; RF: rheumatoid factor; CCP: cyclic citrullinated peptide.

Table 2. Reliability between readers for MRI scores.

	No. of Paired Observations	ICC	95% CI
BME: total individual units*	870	0.51	0.44–0.57
BME: axial individual units*	270	0.40	0.24–0.66
SME: subaxial individual units*	600	0.59	0.52–0.66
BME: vertebral body and dens only, individual units*	210	0.67	0.56–0.75
Overall BME score for an individual patient	30	0.46	NS
Erosions	210	0.57	0.43–0.67
Synovitis	210	0.57	0.43–0.67
All observations combined: BME total individual units, synovitis, and erosions	1290	0.52	0.46–0.57

\* An individual unit refers to a single section of vertebrae that was semi-quantitatively scored 0–3. For example, the C2 left facet joint in a single patient is one unit. Total individual BME units = 29 sections of bone scored per patients multiplied by 30 patients = 870 observations. BME: bone marrow edema; ICC: intraclass correlations coefficient.

both). Duration of disease correlated with erosions (Spearman's rho = 0.43,  $p < 0.05$ ) and synovitis (Spearman's rho 0.37,  $p < 0.05$ ), but not with BME or disease activity. There was no association between any of the medications listed in Table 1 and MRI or neck pain scores. AADI scored on plain radiographs when analyzed as a scale

variable did not correlate with neck pain (VAS score), disease activity measures, disease duration, neurological status, BME, erosions, or synovitis. However, 4 patients with neck pain had an AADI > 3 mm, compared to only 1 without neck pain. This was not statistically significant.

**Feasibility.** It took each radiologist an average of 10–15 minutes to complete the scoring for each individual MRI scan. The length of the scoring process was considered too long for practical use. Of the sequences used to visualize and quantify bone edema, the STIR sequence was considered the best, but the VIBE and T1-weighted sequences (pre- and postcontrast) provided additional complementary information. T1w postcontrast sequences were useful when fat suppression worked well but spatial resolution was inferior to that achieved using the VIBE sequence. In addition, the T1-weighted postcontrast and VIBE sequences were acquired in different planes from each other and were affected by different types of artefact (VIBE sequences were most susceptible to vascular and aliasing artefact, whereas T1-weighted postcontrast sequences were more liable to volume averaging and uneven fat suppression artefact). The other sequences were not useful in quantifying BME. Both readers found it difficult to score the facet joints and vertebral spinous processes because these bony regions were small and irregularly shaped, which created difficulties with volume averaging. Small veins and arteries were also present around the facet joints and spinous processes, causing vascular artefact.

## DISCUSSION

This attempt at a new scoring system for BME in the cervical spine highlights the difficulties encountered with MRI scanning of this area. Even with 3 different sequences that could potentially visualize BME with high sensitivity, there was only moderate agreement between readers. The difficult anatomy, especially blood vessels around the atlantoaxial region, and differences in the level of experience between the 2 readers may have contributed to some of this discrepancy. Narvaez, *et al* used consensus between readers for scoring BME in the cervical spine<sup>4</sup>. We felt that using a consensus score would not inform us about the reproducibility of a scoring system. Using our method, we were able to provide interobserver reliability estimates and determine the areas that were the more difficult to interpret on MRI. Based on this we can make an evidence-based recommendation on how the scoring system should be improved.

A major limitation of using BME to determine rheumatoid disease activity is that it is not specific to RA. BME is well described in other inflammatory conditions such as ankylosing spondylitis<sup>14</sup>, but also in noninflammatory conditions such as osteoarthritis<sup>15</sup> and mechanical repetitive stress<sup>16</sup>. The latter 2 conditions could well be associated with the bone edema shown in Figure 1 rather than active RA.

Table 3. Spearman Rank correlations between clinical and laboratory variables and cervical spine MRI scores.

	BME Total	BME Vertebral Body	Erosion	Synovitis
RF titer	0.391*	0.350	0.291	0.396*
Modified Ranawat score	0.239	0.366*	0.484**	0.224
HAQ II	0.206	0.140	0.098	0.170
68 tender joint count	0.049	0.020	0.226	0.309
66 swollen joint count	-0.218	-0.151	-0.217	-0.078
ESR	0.189	0.081	0.102	0.267
CRP	0.073	0.035	0.034	0.228
Morning stiffness	0.148	0.243	0.102	0.120
Neck pain, VAS	0.150	0.187	0.020	0.130
Overall pain, VAS	0.105	0.087	-0.132	0.005
Patient global	0.227	0.273	0.115	0.162
DAS28 3-variable with CRP	0.100	0.021	0.204	0.321
Anti-CCP antibody titer	0.058	0.221	-0.024	0.037

\* p = 0.05 (2 tailed); \*\* p = 0.01 (2 tailed). BME: bone marrow edema; RF: rheumatoid factor, HAQ II: Health Assessment Questionnaire version II; ESR: Erythrocyte sedimentation rate; CRP: C-reactive protein; VAS: Visual analog scale score; DAS28: Disease activity score using 28 joint count; CCP: cyclic citrullinated peptide.

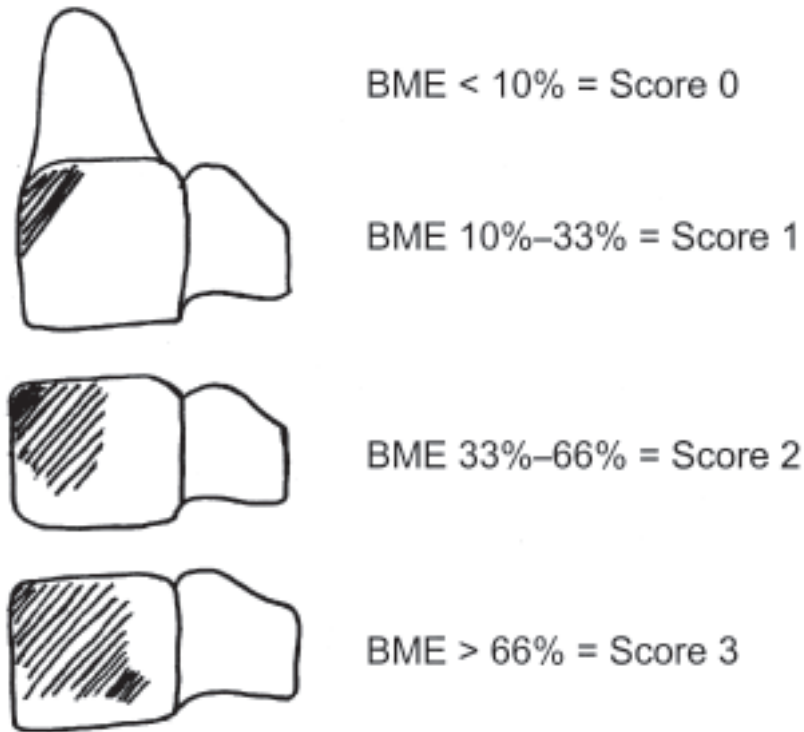
In its original form, the scoring system was time-consuming and reliability was suboptimal. When the facet joints, transverse processes, laminae and spinous process, and all of C1 were excluded, the scoring of BME became more reliable. In this scenario, only the body of each vertebra (plus the dens) would be semiquantitatively scored 0–3 based on estimated volume of bone edema compared to total bone volume. This is similar to what was used by Narvaez, *et al*<sup>4</sup>, although it is not clear whether they differentiated the dens from the body of C2 and whether the volume of spinous and transverse process was included in the total bone volume. Further simplification of the scoring to “any BME” or “no BME” for each vertebral body resulted in reduced interreader reliability ICC in our post-hoc analysis. This is probably because visible BME fell into 2 categories: obvious and doubtful. As a consequence, different thresholds between observers for making a determination of “any BME” (score of at least 1 on the original scale) would have significantly altered the outcome. The results may have been different if the readers were specifically instructed to have a high threshold for scoring “yes” for “any BME.” For example, instructions to score BME as present only if it was seen on at least 2 sequential slices and the signal abnormality comprised at least 10% of the vertebrae by volume might have resulted in better interreader agreement.

Our method of scoring synovitis and erosions was very simple: yes (score = 1) or no (score = 0) at each level. However, despite this simplicity there was only moderate interobserver reliability. This is consistent with reports from other groups utilizing MRI to assess synovitis and erosions at the spine in spondyloarthritis<sup>17</sup> and probably reflects differing observer thresholds for assigning a positive score. We anticipate that clearer guidelines for what degree of abnormality should receive a positive score would improve reliability. In addition, the majority of the synovium of the cer-

vical spine is located at the C1-C2 level. Our method of scoring synovitis put the same emphasis on synovitis scored at C1-C2 level as that scored at subaxial facet joints. Increasing the relative weighting of synovitis at the atlantoaxial level could improve reliability.

Based on our experience from this study we propose a simplified scoring system for the MRI features of BME, synovitis, and erosion at the cervical spine (Figure 2). Until there is evidence to support better reliability from an even simpler method, we recommend that the body of the vertebrae be semiquantitatively scored 0–3 for BME based on estimated volume. Clear instructions are needed for when to score the presence of “any BME” (score of 1). Synovitis and erosions should be scored “yes” or “no” at each vertebral level, with clear guidance on how to make this determination. Semiquantitative scoring of synovitis and erosions may need to be reevaluated in future studies. STIR sequences should be included in any protocol that is used to assess cervical spine BME in RA.

Overall, there was no difference in cervical spine MRI features between those patients with neck pain and those without. There was also no correlation between MRI-determined cervical spine rheumatoid activity (BME, synovitis, or erosions) and clinically determined disease activity, radiographic damage (AADI), or neck pain. These findings support previous evidence that cervical spine involvement may be asymptomatic in some patients with RA but may still lead to future irreversible damage<sup>1,3,18</sup>. In our cohort, patients with neck pain tended to have generalized pain. This was reflected in higher tender joint counts and overall pain scores. Even with the higher tender joint counts, these patients did not have more active disease as determined by DAS scores. Therefore, in some patients, neck pain may have been a manifestation of a secondary pain syndrome, rather than reflecting rheumatoid disease activity. However,



*Figure 2.* Bone marrow edema (BME) is scored for each vertebral body C2-C7. The dens is scored separately from the body of C2. The spinous process, facet joints, and transverse processes are not scored. To achieve a score of 1, BME should be represented by appropriate sequence-specific signal change, occupy at least 10% of the total volume of bone being scored, and be seen on at least 2 sequential slices of a STIR, VIBE, or T1-weighted post-contrast sequence. Total possible score for BME = 21. Synovitis and erosions are scored as present (score = 1) or absent (score = 0) at each level (including presence or absence at the facet joints). Synovitis is scored only if visible on at least 2 appropriate sequential images. Erosions are scored only if clearly visible in 2 different planes.

we did find moderate to strong associations between total cervical spine scores for BME and erosions and between scores for synovitis and erosions, emphasizing the importance of these MRI lesions that are not detectable by plain radiography. At the periphery, BME in particular has been shown to be a precursor of erosions and joint damage<sup>19</sup>.

In summary, we have shown that neither neck pain nor traditional parameters of RA disease activity correlate with MRI evidence of disease activity in the cervical spine. This highlights the need for developing a simple method to quantify MRI change at this site. We present preliminary work to lay the foundation for a cervical MRI scoring system. We intend to use data from this study to formally test the simplified scoring method that we have developed. If this proves successful, the next step is to follow a cohort of patients longitudinally to determine whether BME (or other MRI parameters) can predict future damage at the cervical spine, and therefore guide treatment decisions.

## REFERENCES

1. Kim DH, Hilibrand AS. Rheumatoid arthritis in the cervical spine. *J Am Acad Orthop Surg* 2005;13:463-74.
2. Monsey RD. Rheumatoid arthritis of the cervical spine. *J Am Acad Orthop Surg* 1997;5:240-8.
3. Nguyen HV, Ludwig SC, Silber J, Gelb DE, Anderson PA, Frank L, et al. Rheumatoid arthritis of the cervical spine. *Spine J* 2004;4:329-34.
4. Narvaez JA, Narvaez J, de Albert M, De Lama, Serrallonga M, Nolla JM. Bone marrow edema in the cervical spine of symptomatic rheumatoid arthritis patients. *Semin Arthritis Rheum* 2009;38:281-8.
5. Neva MH, Hakkinen A, Makinen H, Hannonen P, Kauppi M, Sokka T. High prevalence of asymptomatic cervical spine subluxation in patients with rheumatoid arthritis waiting for orthopaedic surgery. *Ann Rheum Dis* 2006;65:884-8.
6. Rawlins BA, Girardi FP, Boachie-Adjei O. Rheumatoid arthritis of the cervical spine. *Rheum Dis Clin North Am* 1998;24:55-65.
7. McQueen FM, Benton N, Perry D, Crabbe J, Robinson E, Yeoman S, et al. Bone edema scored on magnetic resonance imaging scans of the dominant carpus at presentation predicts radiographic joint damage of the hands and feet six years later in patients with rheumatoid arthritis. *Arthritis Rheum* 2003;48:1814-27.
8. Breedveld FC, Weisman MH, Kavanaugh AF, Cohen SB, Pavelka K, van Vollenhoven R, et al. The PREMIER study: A multicenter, randomized, double-blind clinical trial of combination therapy with adalimumab plus methotrexate versus methotrexate alone or

- adalimumab alone in patients with early, aggressive rheumatoid arthritis who had not had previous methotrexate treatment. *Arthritis Rheum*, 2006;54:26-37.
9. Heiberg MS, Rodevand E, Mikkelsen K, Kaufmann C, Didriksen A, Mowinckel P, et al. Adalimumab and methotrexate is more effective than adalimumab alone in patients with established rheumatoid arthritis: results from a 6-month longitudinal, observational, multicentre study. *Ann Rheum Dis* 2006;65:1379-83.
  10. Weinblatt ME, Keystone EC, Furst DE, Moreland LW, Weisman MD, Birbara CA, et al. Adalimumab, a fully human anti-tumor necrosis factor alpha monoclonal antibody, for the treatment of rheumatoid arthritis in patients taking concomitant methotrexate: the ARMADA trial. *Arthritis Rheum* 2003;48:35-45.
  11. Kauppi MJ, Neva MH, Laiho K, Kautiainen H, Luukkainen R, Karjalainen A, et al. Rheumatoid atlantoaxial subluxation can be prevented by intensive use of traditional disease modifying antirheumatic drugs. *J Rheumatol*, 2009;36:273-8.
  12. Eyres KS, Gray DH, Robertson P. Posterior surgical treatment for the rheumatoid cervical spine. *Br J Rheumatol* 1998;37:756-9.
  13. Grauer JN, Tingstad EM, Rand N, Christie MJ, Hilibrand AS. Predictors of paralysis in the rheumatoid cervical spine in patients undergoing total joint arthroplasty. *J Bone Joint Surg Am* 2004;86:1420-4.
  14. Baraliakos X, Landewe R, Hermann KG, Listing J, Golder W, Brandt J, et al. Inflammation in ankylosing spondylitis: a systematic description of the extent and frequency of acute spinal changes using magnetic resonance imaging. *Ann Rheum Dis* 2005;64:730-4.
  15. Carrino JA, Blum J, Paredada JA, Schweitzer ME, Morrison WB. MRI of bone marrow edema-like signal in the pathogenesis of subchondral cysts. *Osteoarthritis Cartilage* 2006;14:1081-5.
  16. Hoy G, Wood T, Phillips N, Connell D, Hughes DC. When physiology becomes pathology: the role of magnetic resonance imaging in evaluating bone marrow oedema in the humerus in elite tennis players with an upper limb pain syndrome. *Br J Sports Med* 2006;40:710-3.
  17. Hoenen-Clavert V, Rat AC, Loeuille D, Bettembourg-Brault I, Michel-Batot C, Blum A, et al. Inflammatory and structural evaluation in spondyloarthritis: magnetic resonance imaging analysis of axial and peripheral involvement. *J Rheumatol* 2007;34:762-8.
  18. Kauppi MJ, Barcelos A, da Silva JA. Cervical complications of rheumatoid arthritis. *Ann Rheum Dis* 2005;64:355-8.
  19. McQueen FM, Ostendorf B. What is MRI bone oedema in rheumatoid arthritis and why does it matter? *Arthritis Res Ther* 2006;8:222.