

Brachial Artery Endothelial-dependent Flow-mediated Dilation Identifies Early-stage Endothelial Dysfunction in Systemic Sclerosis and Correlates with Nailfold Microvascular Impairment

DANIELA ROLLANDO, GIAN PAOLO BEZANTE, ALBERTO SULLI, MANRICO BALBI, NICOLETTA PANICO, CARMEN PIZZORNI, SIMONE NEGRINI, CLAUDIO BRUNELLI, ANTONIO BARSOTTI, MAURIZIO CUTOLO, FRANCESCO INDIVERI, and MASSIMO GHIO

ABSTRACT. Objective. To assess possible correlations between endothelial-dependent flow-mediated dilation (FMD) of the brachial artery and nailfold videocapillaroscopy (NVC) in patients with systemic sclerosis (SSc). Evidence has shown that vascular impairment in SSc may be a sign of endothelial dysfunction involving both microvascular and macrovascular systems, although the pathological mechanisms of the dysfunction are poorly understood.

Methods. Forty-three consecutive patients (mean age 51 ± 11 yrs) with SSc were studied. Thirty patients had limited cutaneous SSc, 13 had diffuse cutaneous SSc. Twenty-seven healthy subjects (mean age 48 ± 8 yrs) were recruited as controls. Ultrasound assessment of FMD was performed on all subjects in order to evaluate macrovascular function. Patients were divided into 3 patterns of microvascular damage on the basis of NVC (early, active, and late), and the microangiopathy evolution score was calculated, as reported elsewhere.

Results. FMD was significantly reduced in patients with SSc compared to healthy subjects [median 8.0% (3.0%–9.0%) vs 15.0% (12.0%–16.0%), respectively; $p < 0.0001$]. Patients with an early pattern of microangiopathy showed reduced FMD values compared to controls ($p = 0.0001$). FMD was significantly reduced in patients with SSc who had the late NVC pattern of microangiopathy compared to active and early patterns ($p = 0.003$ and $p = 0.001$, respectively). FMD was inversely correlated with the microvascular damage rate in patients with SSc ($p < 0.0001$).

Conclusion. We demonstrated the simultaneous presence of macrovascular and microvascular impairment in patients with SSc, which was already present in the early phase of the vascular disease. (J Rheumatol First Release May 1 2010; doi:10.3899/jrheum.091116)

Key Indexing Terms:

ULTRASONOGRAPHY

SYSTEMIC SCLEROSIS

CARDIOVASCULAR DISEASE

Systemic sclerosis (SSc) is a clinically heterogeneous disease characterized by disturbances of the immune system and massive deposition of collagen and other extracellular matrix proteins in the connective tissue of the skin and inter-

nal organs¹. Vascular impairment is one of the main features in the pathogenesis of SSc and it is detectable in the early phase of the disease. It has recently been hypothesized that the endothelial injury can explain the pathogenesis of the vascular lesions, even if the pathological mechanisms of the dysfunction are poorly understood². Raynaud's phenomenon (RP), together with capillary morphological abnormalities, is the most common and earliest finding of SSc and can be considered the main expression of microvascular dysfunction³. Nailfold videocapillaroscopy (NVC) is a simple technique that is useful in the early identification of microvascular involvement in patients with SSc. Recently, attempts have been made to identify disease-specific capillary abnormalities, as well as to define specific capillaroscopy patterns of microangiopathy in order to assess the progression of the microvascular damage in patients with SSc^{4,5}.

Structural histopathological changes in the wall of arteri-

From the Academic Unit of Cardiovascular Diseases, the Research Laboratory and Academic Unit of Clinical Rheumatology, and the Academic Unit of Clinical Immunology, Department of Internal Medicine, University of Genoa, Genoa, Italy.

D. Rollando, MD; G.P. Bezante, MD, FACC; M. Balbi, MD; C. Brunelli, MD; A. Barsotti, MD, Academic Unit of Cardiovascular Diseases, Department of Internal Medicine, University of Genoa; A. Sulli, MD; C. Pizzorni, MD; M. Cutolo, MD, Research Laboratory and Academic Unit of Clinical Rheumatology, Department of Internal Medicine, University of Genoa; N. Panico, MD; S. Negrini, MD; F. Indiveri, MD; M. Ghio, MD, Academic Unit of Clinical Immunology, Department of Internal Medicine, University of Genoa.

Address correspondence to Dr. G.P. Bezante, Cardiology Unit, Department of Internal Medicine, University of Genoa, Genoa, Italy.
E-mail: gian.paolo.bezante@unige.it

Accepted for publication February 3, 2010.

Personal non-commercial use only. The Journal of Rheumatology Copyright © 2010. All rights reserved.

oles, such as intimal proliferation, intimal and medial hypertrophy, and disruption of the internal elastic lamina, are well recognized in SSc⁶. But few data are available regarding the functional changes of small elastic conduit arteries, such as brachial and radial arteries. Recent evidence has shown that SSc vascular impairment may be a sign of endothelial dysfunction involving both microvascular and macrovascular systems^{7,8}.

Ultrasound assessment of brachial artery endothelial-dependent flow-mediated dilation (FMD) is a noninvasive instrumental evaluation that is routinely performed as an index of macrovascular function. This technique, described by Celermajer, *et al* in 1992⁹, measures brachial artery diameter before and after an ischemic stimulus, and shows the vasodilatory response to blood flow-associated shear stress increase. Forearm ischemia causes a marked drop in peripheral resistance, followed by an increase in wall shear stress in the conduit artery after the release of ischemia. Shear stress increase stimulates both endothelial production and the release of several vasodilators, primarily endothelial nitric oxide (NO). The resulting augmentation of arterial diameter, expressed as percentage of increase, estimates the NO release and, vicariously, the endothelium-dependent vasodilatation. Thus, a small percentage of FMD response is interpreted as low NO bioavailability and is associated with an increased risk of vascular disease¹⁰.

Our study was designed to assess the possible involvement of macrovasculature dysfunction in SSc, as well as the correlations between macrovascular and microvascular impairment.

MATERIALS AND METHODS

Patient population. Forty-three consecutive patients were studied (37 women and 6 men, mean age 51 ± 11 yrs). They were diagnosed as having SSc as defined by the American College of Rheumatology criteria¹¹ and were referred to the Academic Units of Clinical Rheumatology and Immunology of the University of Genoa. Thirty patients (mean age 51.0 ± 11.7 yrs) had limited cutaneous SSc (lcSSc) and 13 (mean age 50 ± 9.5 yrs) had diffuse cutaneous SSc (dcSSc)¹². All enrolled patients reported the presence of RP. Age at onset of both SSc and RP was investigated in all patients. The duration of SSc at the time of study entry was evaluated by clinical interview and/or from clinical file data. In particular, the duration of SSc was calculated from the time of the first complaints of clinical signs or symptoms clearly related to SSc, or from the time of instrumental and/or serological examinations specific for SSc.

All of the 43 enrolled patients were treated with vasodilators and/or calcium channel blockers. One month of washout from these drugs was done prior to carrying out cardiovascular examinations. A few patients taking nonsteroidal antiinflammatory drugs were banned from taking them in the 30 days before the study. Exclusion criteria included history of cigarette smoking, diabetes mellitus, hypercholesterolemia, cancer, heart and pulmonary failure, myocardial infarction, and angina pectoris. Twenty-seven healthy subjects (20 women, 7 men, mean age 49 ± 8 yrs) were recruited as controls. Informed consent was obtained from all patients and controls before entry into the study. The local ethics committee approved the study. FMD and NVC assessment were performed on all subjects.

Electrocardiography and echocardiography. Surface electrocardiography (ECG) and transthoracic echocardiography were performed on all subjects.

All echocardiographic studies were performed using a high-resolution ultrasonographic scanner, C512 Acuson Sequoia (Siemens Medical Solutions Inc., Mountain View, CA, USA) equipped with a 1.0–4.0 MHz wideband multihertz imaging probe (4V1c). The overall monodimensional left ventricular measurements and the bidimensional (apical, 4-chamber, and 2-chamber) views were obtained according to the recommendations of the American Society of Echocardiography¹³.

FMD in the brachial artery. All assessments were performed by the same operator in an air-conditioned room at 21–24°C, after overnight fasting and following a 30-min rest. Heavy foods, including high-fat foods and caffeine-containing beverages, were prohibited the night before the study.

Ultrasound scans were performed using the C512 Acuson Sequoia, equipped with a 5.0–8.0 MHz linear wideband multihertz imaging probe (8L5).

The brachial artery was scanned over a longitudinal section 2–3 cm above the antecubital fossa, based on individual anatomical variability. When an adequate image was obtained, the ultrasound probe was positioned using a mechanical probe stabilizer. After baseline measurements of brachial artery diameter, the pressure cuff was kept inflated for 5 min at 50 mm Hg over systolic blood pressure on the proximal portion of the forearm, as reported¹⁴. No patients experienced significant discomfort during or after cuff occlusion.

Postischemic artery diameter recording was started 30 s before rapid deflation of the blood pressure cuff and the longitudinal image of the artery was recorded continuously for up to 4 min. FMD was expressed as percentage of increase in arterial diameter from baseline to the postocclusive period. Ultrasound images were analyzed offline by averaging the arterial diameter along 10 mm segments. Diameters from 3 consecutive end-diastolic frames (identified by the electrocardiographic R wave) were averaged to yield the brachial artery diameter during the respective experimental stages. The intraoperator variability was 3.8%. FMD measurements were blindly performed with respect to the NVC evaluation.

Nailfold videocapillaroscopy. Morphological evaluation of skin capillaries is generally performed at the nailfold because this area is easily accessible for examination, and because the major axis of the capillaries is parallel to the skin surface (in other areas, it has a perpendicular status).

The same operator performed all the NVC using a videocapillaroscopy optical probe equipped with a magnification $\times 200$ contact lens and connected to image analysis software (Videocap, DS MediGroup, Milan, Italy). Each subject was in the test room for a minimum of 15 min before the nailfold examination, and the room temperature was 20–22°C. The nailfold (distal row) of the 2nd, 3rd, 4th, and 5th fingers was examined in each patient.

Based on the NVC abnormalities, the patients with SSc were classified by the most appropriate NVC pattern¹⁵. The patterns included (1) “early” pattern: few giant capillaries (< 4 altered capillaries per mm), few capillary hemorrhages, relatively well preserved capillary distribution, no evident loss of capillaries; (2) “active” pattern: frequent giant capillaries (> 6 altered capillaries per mm), frequent capillary hemorrhages, moderate loss of capillaries (20%–30%), mild disorganization of the capillary architecture (4–6 altered capillaries per mm), absent or mild ramified capillaries; and (3) “late” pattern: irregular enlargement of the capillaries, few or absent giant capillaries and hemorrhages, severe loss of capillaries (50%–70%) with large avascular areas, disorganization of the normal capillary array, and evident ramified capillaries¹⁵.

The following capillaroscopic measurements were taken into consideration, as they were found to correlate with progression of the nailfold microangiopathy, as described: loss of capillaries, disorganization of the microvascular array, and capillary ramifications^{4,5}. A semiquantitative rating scale to score each capillary abnormality was adopted according to previous studies (0 = no changes; 1 = less than 33% of capillary alterations/reduction; 2 = 33%–66% of capillary alterations/reduction; and 3 = more than 66% of capillary alterations/reduction, per mm)⁵. The mean score value for each capillaroscopic measurement was calculated from the

analysis of 4 consecutive fields (1 mm for each) in the middle of the nail-fold of each digit; the average score values of the 8 digits were added together, and the final value was divided by 8. The resulting value represented the score for each capillaroscopic measurement that was analyzed. The scores of these measurements were added together to globally assess the variation of the SSc microangiopathy over time [microangiopathy evolution score (MES): 0–9]. The intraoperator variability was 3%. NVC measurements were blindly performed with respect to the FMD evaluation.

Autoantibody detection. Serum antinuclear (ANA), antitopoisomerase I (Scl-70), and anticentromere (ACA) antibodies were investigated in all patients. ANA were detected by indirect immunofluorescence using HEp-2 cells as substrate (Euroimmun, Luebeck, Germany). ACA and Scl-70 were measured using an enzyme-linked immunosorbent assay (ELISA; Euroimmun).

Statistical analysis. Results are expressed as median and 25th–75th percentiles. The Kruskal-Wallis test was used to assess differences among the distributions of variables, as appropriate. The Mann-Whitney U test was used to compare continuous variables with nominal variables. Regression tests were used to evaluate any possible relationship between continuous variables as well as the Spearman's rank correlation test. A *p* value ≤ 0.05 was considered statistically significant.

RESULTS

Clinical characteristics. Characteristics of patients and controls are summarized in Table 1. None of the patients had signs or symptoms of cardiovascular disease. Sinus rhythm but no other major abnormalities were found at ECG in all subjects. All echocardiographic measurements were within the normal range¹³. Left and right ventricular function was normal and no pericardial effusion was detected in any of the subjects. Systolic pulmonary pressure, determined by the peak flow velocity of the tricuspid regurgitation, was normal in all patients (< 40 mm Hg)¹⁶.

No major differences were observed between patients with SSc and healthy controls in means of height, weight, systolic and diastolic blood pressure, resting heart rate, brachial artery diameter, or levels of low-density or high-density lipoprotein cholesterol. Serum ACA and Scl-70 were positive in 18 (48.6%) and 8 patients with SSc (21.6%), respectively (Table 1).

Vascular evaluation. All enrolled patients showed a sclero-

derma pattern of microangiopathy at NVC examination: early NVC pattern was found in 13 patients, active pattern in 15 patients, and late pattern in 15 patients. FMD was significantly reduced in patients with SSc compared to healthy subjects [median 8.0% (25th and 75th percentiles 3.0–9.0) vs 15.0% (12.0–16.0), respectively; *p* < 0.0001; Figure 1]. Notably, patients with SSc who had the early pattern of microangiopathy showed lower FMD values than the healthy controls (*p* = 0.001). Further, FMD was significantly reduced in patients with SSc who had the late NVC pattern compared to the active and early patterns [median 3.0% (0.5–5.8) vs 8.6% (3.2–10.0) and 9.0% (6.1–10.1); *p* = 0.003 and *p* = 0.001, respectively; Figure 2]. Microangiopathy evolution score was significantly different in patients with SSc in all 3 NVC patterns of microangiopathy [median 0.0 (0.0–2.0), 3.0 (2.7–4.2), and 6.0 (6.0–8.0), respectively (*p* < 0.0001)]. A negative correlation between FMD and MES was found in patients with SSc (*p* < 0.0001; Figure 3). No statistically significant difference concerning FMD values, MES, and NVC patterns was found between patients with lcSSc and those with dcSSc.

DISCUSSION

In our study we showed a significant, blunted macrovascular response at FMD evaluation in patients with SSc who were asymptomatic for cardiovascular diseases as compared to healthy subjects. This is the first study to report that FMD is already reduced in patients with SSc with the early pattern of microangiopathy, and that lower FMD values are found in patients with the late NVC pattern of microangiopathy compared to those with the active and early patterns. Moreover, a significant, inverse correlation between FMD values and the rate of microvascular damage was found in patients with SSc.

Vascular dysfunction is a key element of SSc pathogenesis, and it occurs in almost all patients with SSc. Functional and structural changes may occur in microvessels, digital arteries, and sometimes even in the more proximal vessels

Table 1. Clinical characteristics of the patients with SSc and controls. Data are expressed as mean ± SD or percentage.

Variables	SSc	dcSSc	lcSSc	Control	<i>p</i>
Subjects, n	43	13	30	27	NS
Age, yrs	51.0 ± 10.8	50.0 ± 9.5	51.0 ± 11.7	49.0 ± 8.4	NS
Women/men, n	37/6	10/3	27/3	20/7	NS
Body surface area, m ²	1.8 ± 0.1	1.3 ± 0.1	1.6 ± 0.1	1.6 ± 0.1	NS
Heart rate, beats/min	78.0 ± 6.0	76.0 ± 8.0	74.0 ± 5.0	77.0 ± 6.0	NS
Mean arterial pressure, mmHg	99.0 ± 6.0	96.5 ± 7.0	98.7 ± 7.0	95.5 ± 8.0	NS
Disease duration, yrs	14.2 ± 9.4	12.6 ± 9.0	13.7 ± 8.4	—	NS
ACA positivity, %	48.6	38.4	52.0	—	NS
Scl-70 positivity, %	21.6	46.1	12.0	—	NS

SSc: scleroderma; dcSSc: diffuse cutaneous systemic sclerosis; lcSSc: limited cutaneous systemic sclerosis; ACA: anticentromere antibodies; Scl-70: antitopoisomerase I.

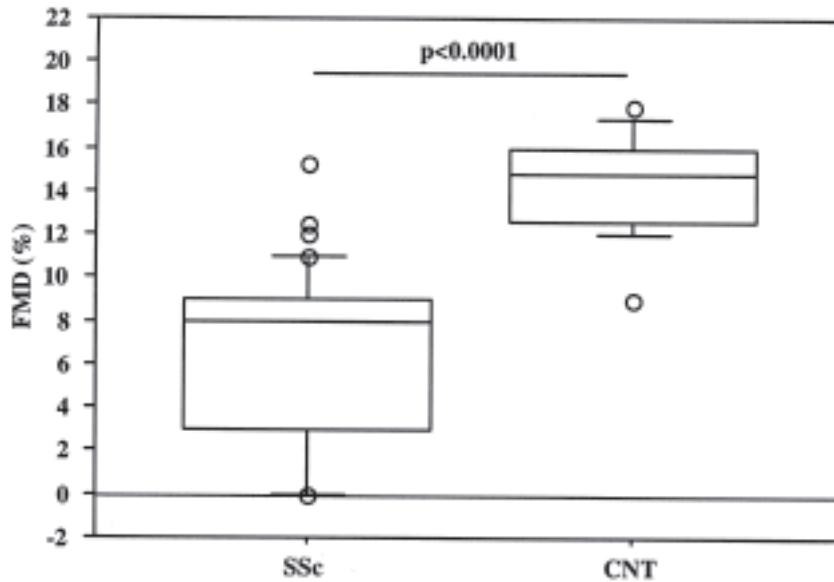


Figure 1. Flow-mediated dilation (FMD) in patients with SSc and in healthy controls (CNT). Data are given as 5th, 10th, 50th (median), 90th, and 95th percentiles.

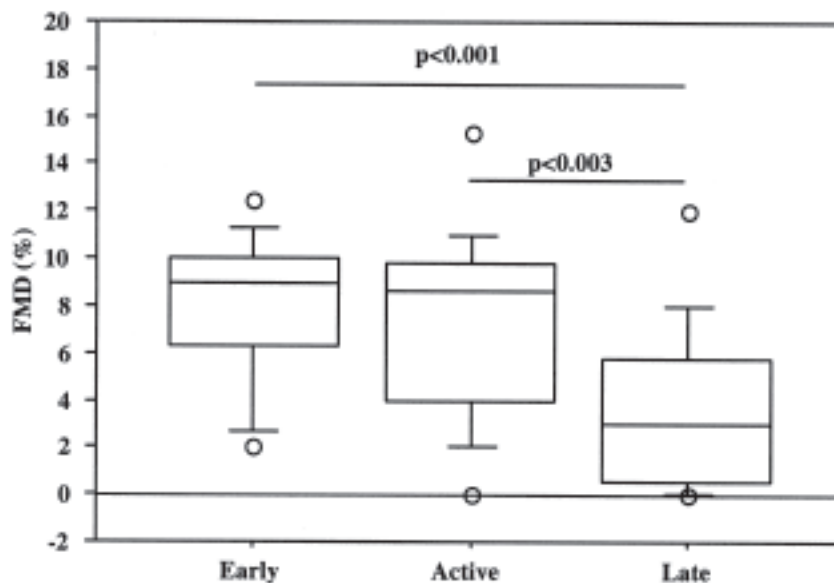


Figure 2. Flow-mediated dilation (FMD) in patients with SSc with different nailfold videocapillaroscopy patterns of microangiopathy (early, active, and late). Data are given as 5th, 10th, 50th (median), 90th, and 95th percentiles.

of these patients¹⁷. Peripheral impairment in SSc can be caused by several things, e.g., abnormalities of neuroendothelial control mechanisms; structural abnormalities of the vasculature involving both microvessels and the digital arteries; and intravascular factors, including a procoagulant tendency and increased oxidative stress¹⁷. Structural changes affect both peripheral capillaries, which can be carefully studied by NVC, and digital arteries, in which the

most characteristic histologic lesions are marked intimal hyperplasia and fibrosis^{4,18,19}.

NVC microvascular impairment in SSc is characterized by the early detection of giant capillaries, followed in the advanced stages by capillary reduction, neoangiogenesis, and disorganization^{5,14,20}. Three distinct NVC patterns of microangiopathy (early, active, and late) have recently been identified and are useful for evaluating the stage and sever-

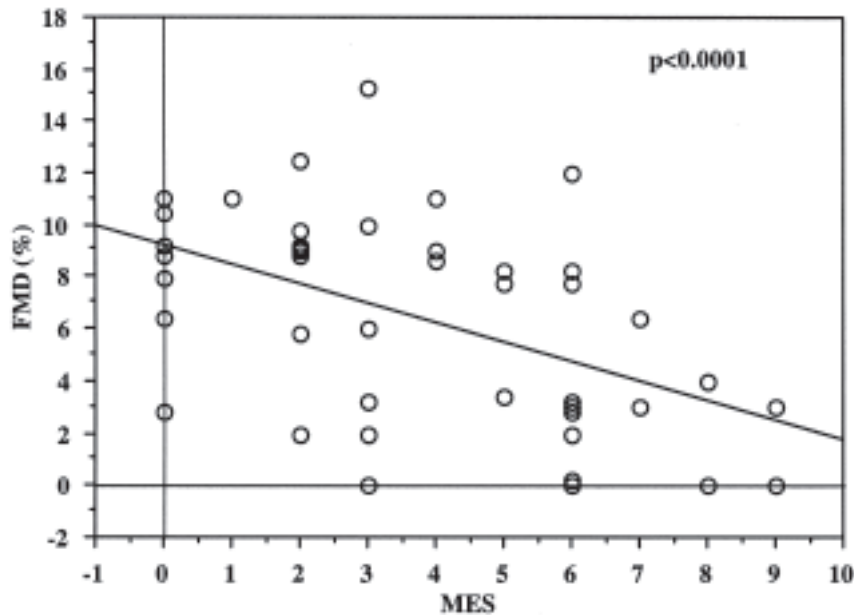


Figure 3. Inverse correlation between flow-mediated dilation (FMD) and microangiopathy evolution score (MES), as evaluated by nailfold videocapillaroscopy.

ity of microvascular damage in SSc⁵. On the other hand, 3 capillaroscopic measurements (loss of capillaries, disorganization of the microvascular array, and capillary ramifications) were found to correlate with progression of the microvascular damage in SSc, and a composite score has been proposed to monitor microvascular evolution⁵. Our study proves that macrovascular impairment is already present in the early phase of SSc microangiopathy as demonstrated by the reduction of FMD in patients with the early NVC pattern, which becomes more evident in the advanced stage of microangiopathy, as confirmed by the inverse correlation between FMD values and MES. The lack of statistical difference between early and active NVC patterns might be related to the small sample data ($p = 0.10$), suggesting that a larger population of patients with SSc should be studied. But if the involvement of conduit arteries was believed to be unusual, in the last 15 years considerable interest has been shown in the hypothesis that patients who have SSc have an increased prevalence of large-vessel disease^{16,21,22}.

Vasodilation and vasoconstriction are dependent upon both intact endothelium and neural control mechanisms²³. It is likely that both of these elements are dysfunctional and/or damaged in SSc and that vascular dysregulation is associated with increased risk of vascular disease⁹. In SSc, the balance between vasodilation and vasoconstriction is disturbed in favor of reduced vasodilation or increased vasoconstriction²⁴. Ultrasound assessment of FMD is an index of macrovascular function and, vicariously, of NO release²⁵. Conflicting data have been reported in SSc regarding abnor-

mal vasodilation (endothelial-dependent and endothelial-independent), but reduced availability of NO is a common feature found in SSc. The significance of this reduced availability was outlined in a review by Herrick², who reported on endothelial-dependent and endothelial-independent vasodilation in both the dermal microvasculature and large peripheral vessels of patients with SSc. The NO produced by the endothelium acts directly on the vascular smooth muscle, and results in vasodilation²⁶. The endothelial-dependent vasodilation, which is related to an intact endothelium, was found to be compromised in SSc, while the endothelial-independent vasodilation, which does not require a functioning endothelium and evaluates smooth muscle function, is still uncertain^{17,27}. Our data suggest that the vascular dysregulation shown by FMD examination is associated with morphological alterations observed in the different phases of SSc microangiopathy. Although the pathogenesis of microvascular damage progression is not well known, based on our finding of an inverse correlation between FMD and MES, we suggest that the progression into different microangiopathic patterns might be related to the endothelial dysfunction, which is already detected by FMD evaluation in the early phase of microvascular impairment of SSc. The capillary abnormalities that characterize the progression of the SSc microvascular damage (early, active, and late patterns of microangiopathy) do not relate only to endothelial-dependent impairment. Other factors might also be involved.

Our study shows the simultaneous presence of macrovascular and microvascular impairment in patients with SSc

that is already detectable in the early phase of the vascular disease and is probably related to a multifaceted derivation that requires further investigation. FMD evaluation might lead to early detection of macrovascular impairment in SSs when the vascular capillary anatomy is still preserved, because NVC detects the microvascular changes that characterize the disease at an early stage²⁸. Further studies are needed to better understand the pathogenetic pathways that are responsible for the composite vascular abnormalities that characterize the multiple aspects of endothelial biology and vascular dysfunction in patients with SSs.

REFERENCES

1. Derk CT, Jimenez SA. Systemic sclerosis: current views of its pathogenesis. *Autoimmun Rev* 2003;2:181-91.
2. Herrick AL. Vascular function in systemic sclerosis. *Curr Opin Rheumatol* 2000;12:527-33.
3. LeRoy CE. Systemic sclerosis: a vascular perspective. *Rheum Dis Clin North Am* 1996;22:675.
4. Cutolo M, Pizzorni C, Secchi ME, Sulli A. Capillaroscopy. *Best Pract Res Clin Rheumatol* 2008;22:1093-108.
5. Sulli A, Secchi ME, Pizzorni C, Cutolo M. Scoring the nailfold microvascular changes during the capillaroscopic analysis in systemic sclerosis patients. *Ann Rheum Dis* 2008;67:885-97.
6. D'Angelo WA, Fries JF, Masi AT, Shulman LE. Pathologic observations in systemic sclerosis (scleroderma): a study of fifty-eight autopsy cases and fifty-eight matched controls. *Am J Med* 1969;46:428-40.
7. Ho M, Veale DJ, Eastmond C, Nuki G, Belch J. Macrovascular disease in systemic sclerosis. *Ann Rheum Dis* 2000;59:39-43.
8. Matucci Cerinic M, Fiori G, Grenbaum E, Shoenfeld Y. Macrovascular disease in systemic sclerosis. In: Furst D, Clements P. *Systemic sclerosis*. Baltimore, MD: Lippincott Williams & Wilkins; 2003:241.
9. Celermajer DS, Sorensen KE, Gooch VM, Spiegelhalter DJ, Miller OI, Sullivan ID, et al. Non-invasive detection of endothelial dysfunction in children and adults at risk of atherosclerosis. *Lancet* 1992;340:1111-5.
10. Joannides R, Haefeli WE, Linder L, Richard V, Bakkali EH, Thuillez C, et al. Nitric oxide is responsible for flow-dependent dilatation of human peripheral conduit arteries in vivo. *Circulation* 1995;91:1314-9.
11. Masi AT, Rodnan GP, Medsger TA Jr, Altman RD, D'Angelo WA, Fries JF, et al. Subcommittee for Scleroderma Criteria of the American Rheumatism Association Diagnostic and Therapeutic Criteria Committee. Preliminary criteria for the classification of systemic sclerosis (scleroderma). *Arthritis Rheum* 1980;23:581-90.
12. LeRoy EC, Black CM, Fleischmajer R, Jablonska S, Krieg T, Medsger TA, et al. Scleroderma (systemic sclerosis); classification, subsets and pathogenesis. *J Rheumatol* 1988;15:202-5.
13. Quinones MA, Otto CM, Stoddard M, Waggoner A, Zoghbi WA. Doppler Quantification Task Force of the Nomenclature and Standards Committee of the American Society of Echocardiography. Recommendations for quantification of Doppler echocardiography: a report from the Doppler Quantification Task Force of the Nomenclature and Standards Committee of the American Society of Echocardiography. *J Am Soc Echocardiogr* 2002;15:167-84.
14. Corretti MC, Anderson TJ, Benjamin EJ, Celermajer D, Charbonneau F, Creager MA, et al. International Brachial Artery Reactivity Task Force. Guidelines for the ultrasound assessment of endothelial-dependent flow-mediated vasodilation of the brachial artery: a report of the International Brachial Artery Reactivity Task Force. *J Am Coll Cardiol* 2002;39:257-6.
15. Cutolo M, Sulli A, Pizzorni C, Accardo S. Nailfold videocapillaroscopy assessment of microvascular damage in systemic sclerosis. *J Rheumatol* 2000;27:155-60.
16. McLaughlin VV, Archer SL, Badesch DB, Barst RJ, Farber HW, Lindner JR, et al. ACCF/AHA 2009 expert consensus document on pulmonary hypertension: a report of the American College of Cardiology Foundation Task Force on Expert Consensus Documents and the American Heart Association. *J Am Coll Cardiol* 2009;53:1573-619.
17. Herrick A. Diagnosis and management of scleroderma peripheral vascular disease. *Rheum Dis Clin North Am* 2008;34:89-114.
18. Cutolo M, Pizzorni C, Tuccio M, Burroni A, Craviotto C, Basso M, et al. Nailfold videocapillaroscopic patterns and serum autoantibodies in systemic sclerosis. *Rheumatology* 2004;43:719-26.
19. Rodnan GP, Myerowitz RL, Justh GO. Morphological changes in the digital arteries of patients with progressive systemic sclerosis (scleroderma) and Raynaud phenomenon. *Medicine* 1980;59:393-408.
20. Koenig M, Joyal F, Fritzler MJ, Roussin A, Abrahamowicz M, Boire G, et al. Autoantibodies and microvascular damage are independent predictive factors for the progression of Raynaud's phenomenon to systemic sclerosis: a twenty-year prospective study of 586 patients, with validation of proposed criteria for early systemic sclerosis. *Arthritis Rheum* 2008;58:3902-12.
21. Veale DJ, Collidge TA, Belch JFF. Increased prevalence of symptomatic macrovascular disease in systemic sclerosis. *Ann Rheum Dis* 1995;54:853-5.
22. Youseff P, Brama T, Englert H, Bertouch J. Limited scleroderma is associated with increased prevalence of macrovascular disease. *J Rheumatol* 1995;22:469-72.
23. Generini S, Matucci Cerinic M. Raynaud's phenomenon and vascular disease in systemic sclerosis. *Adv Exp Med Biol* 1999;455:93-100.
24. Sunderkötter C, Riemekasten G. Pathophysiology and clinical consequences of Raynaud's phenomenon related to systemic sclerosis. *Rheumatology* 2006;45:iii33-5.
25. Andersen GN, Mincheva-Nilsson L, Kazzam E, Nyberg G, Klintlund N, Petersson AS, et al. Assessment of vascular function in systemic sclerosis: indications of the development of nitrate tolerance as a result of enhanced endothelial nitric oxide production. *Arthritis Rheum* 2002;46:1324-32.
26. Lekakis J, Papamichael C, Mavrikakis M, Voutsas A, Stamateopoulos S. Effect of longterm estrogen therapy on brachial arterial endothelium-dependent vasodilation in women with Raynaud's phenomenon secondary to systemic sclerosis. *Am J Cardiol* 1998;15:82:1555-7.
27. Cypienie A, Laucevicius A, Venalis A, Dadoniene J, Ryliskyte L, Petrulioniene Z, et al. The impact of systemic sclerosis on arterial wall stiffness parameters and endothelial function. *Clin Rheumatol* 2008;27:1517-22.
28. De Angelis R, Grassi W, Cutolo M. The reasons for a growing need for capillaroscopy in rheumatology. *Arthritis Rheum* 2009;61:405-10.