

# Osteonecrosis of the Jaw Correlated to Bisphosphonate Therapy in Non-oncologic Patients: Clinicopathological Features of 24 Patients

GIANFRANCO FAVIA, GIOVANNI PIETRO PILOLLI, and EUGENIO MAIORANO

**ABSTRACT.** *Objective.* Osteonecrosis of the jaws (ONJ) is a well known side effect of bisphosphonate therapies in patients with multiple myeloma or other malignancies. Its real incidence is still undetermined, and only few cases of ONJ in patients taking bisphosphonates for non-oncologic diseases have been reported. It was postulated that the clinical features, predisposing factors, and treatment outcome of this subset of patients might be different from those of oncologic patients.

*Methods.* Over a 4 year period, a total of 102 bisphosphonate-treated patients affected by ONJ were identified. Among these, 24 patients underwent bisphosphonate therapy for non-neoplastic disease and their profile was analyzed.

*Results.* In this study cohort, bisphosphonates had been administered mainly for postmenopausal osteoporosis (20/24 patients, 83.3%), the duration of therapy until presentation of ONJ ranging from 11 to 40 months and the most common triggering event being dentoalveolar surgery. All patients were nonsmokers; 6 manifested multiple ONJ lesions and only 3 of them had possible comorbidities. Surgical debridement was performed in 19 patients for a total of 22 lesions, which were individually considered in the followup. The latter showed complete remission of ONJ in 21/22 lesions.

*Conclusion.* Although it might be considered a rare condition in non-oncologic patients, ONJ is a harmful side effect of bisphosphonate therapies. Clinicians must be aware of this entity, inform patients of the risks related to dental surgery, and possibly undertake adequate preventive measures. (J Rheumatol First Release Nov 1 2009; doi:10.3899/jrheum.090455)

## Key Indexing Terms:

BISPHOSPHONATES      OSTEOPOROSIS      BONE      OSTEONECROSIS      JAWBONE

Bisphosphonates are a class of drugs that have been increasingly recommended for the therapy of cancer-induced bone diseases such as hypercalcemia of malignancy, osteolytic tumor localizations, and other lesions associated with bone loss, such as osteoporosis or Paget's disease. They are incorporated into the skeleton and suppress bone resorption, without being degraded<sup>1-3</sup>. Some bisphosphonates have shown direct anti-tumor effects possibly related to reduced growth factor release and inhibition of cell adhesion<sup>3,4</sup>.

Although a good safety profile has been reported for these drugs, mild and transient adverse events, such as bone pain, pyrexia, anemia, nausea, gastroesophagitis, and dyspnea have been reported. Occasionally, acute renal failure,

which was probably related to the infusion rate, atrial fibrillation, and esophageal carcinoma<sup>5,6</sup>, mainly occurring in patients on longterm bisphosphonate therapy, have been reported<sup>1,7</sup>.

More recently, osteonecrosis of the jaws (ONJ) has been characterized as a main side effect of bisphosphonate therapy<sup>8-11</sup>. The most frequent clinical sign of ONJ is bone exposure, frequently associated with pain, swelling, and purulent secretion that does not heal over a period of 6–8 weeks<sup>12</sup>. While ONJ has been strongly associated with prolonged use of intravenous bisphosphonates (zoledronate and pamidronate) in cancer patients<sup>8-11</sup>, limited data are available about the risk of ONJ in patients affected by non-neoplastic diseases and receiving other types of bisphosphonates<sup>11-13</sup>. In the latter subset of patients, the risk of developing ONJ seems as low as 0.7/100,000 person/years exposure to alendronate<sup>12</sup>. Other nitrogen-containing oral bisphosphonates are expected to show a similar risk profile, ranging between 1 event per 20,000–110,000 patient-years<sup>13</sup>.

Our study was aimed at reporting on the salient clinicopathological features, predisposing factors, and treatment modalities of ONJ of a cohort of 24 bisphosphonate-treated patients with non-oncologic diseases.

---

From the Division of Oral Pathology, Department of Odontostomatology and Surgery, and Department of Pathological Anatomy, University of Bari, Bari, Italy.

G. Favia, MD, PhD, Professor of Oral Pathology; G.P. Pilolli, DMD, Research Fellow, Division of Oral Pathology, Department of Dental Sciences and Surgery, Faculty of Medicine; E. Maiorano, MD, MS, Professor of Pathology, Department of Pathological Anatomy, Faculty of Medicine.

Address correspondence to Dr. G.P. Pilolli, Dipartimento di Odontostomatologia e Chirurgia, Piazza G. Cesare 11, 70124 Bari, Italy. E-mail: giovannipilolli@yahoo.it

Accepted for publication June 5, 2009.

## MATERIALS AND METHODS

From May 2004 to October 2008, 102 bisphosphonate-treated patients with signs and symptoms of ONJ were referred to the Department of Dental Sciences of the University of Bari. According to the American Dental Association Council on Scientific Affairs<sup>12</sup>, the diagnosis of ONJ was based on the patients' medical history and clinical and histopathological evaluation.

Among these, 24 patients had undergone bisphosphonate therapy for non-neoplastic disease. Two patients with a history of malignancy and who received chemotherapy in addition to bisphosphonates were excluded from this study.

Complete medical history including indication for bisphosphonate therapy, type, dose, frequency, therapy duration and discontinuation, comorbidities, and dental history was collected and analyzed along with ONJ signs, symptoms, stage (according to the classification reported by Ruggiero, *et al*<sup>14</sup>), and radiographic and histological data. All patients underwent prolonged (not less than 3 weeks) parenteral antibiotic therapy (intramuscular sodium ceftriaxone 1 g daily and metronidazole 500 mg twice a day orally). Subsequently, 19/24 patients who had persistent ONJ-related symptoms received surgical therapy consisting of surgical debridement using piezosurgery, a minimally invasive procedure using ultrasonic vibrations to cut bone, thus minimizing the extent of damage to adjacent soft tissues, including nerves and blood vessels. The remaining 5 patients received nonsurgical management with 0.12% chlorhexidine mouth rinses and antibiotic (as described above). Data on the success of the surgery were recorded and analyzed with a mean followup of  $16.4 \pm 7.6$  months.

## RESULTS

*Clinicopathological features.* The salient clinical data of patients, including the site of osteonecrosis, associated symptoms, and type of treatment, are listed in Table 1.

All patients were female, ranging in age from 53 to 83 years (mean age  $\pm$  standard deviation  $71.5 \pm 8.1$  yrs; median 72). Six patients presented multiple osteonecrotic events and a total of 30 bone lesions were identified.

Postmenopausal osteoporosis (20/24 patients, 83.3%) and 2 cases each of corticosteroid-induced osteoporosis and orthopedic surgery were the clinical conditions that led to bisphosphonate administration. Dentoalveolar surgery, such as tooth extraction and dental implants, was by far the most common triggering factor for ONJ, and only one case of spontaneous bone exposure occurred in a patient with ill-fitting dentures. As to the type of bisphosphonate, 15 patients used alendronate, 3 patients clodronate, 2 patients each risedronate or ibandronate (one patient with rheumatoid arthritis (RA) and one with systemic lupus erythematosus (SLE), both also taking corticosteroids and the latter also receiving methotrexate), 1 patient used alendronate plus clodronate, and the remaining patient clodronate plus risedronate (Table 1). The duration of bisphosphonate therapy at presentation ranged from 11 to 40 months. Three patients had received implant rehabilitation procedures before the start of bisphosphonates and they did not show any signs of inflammation at the time implantation was performed.

The mandible (21 lesions) was affected more commonly than the maxilla (9 lesions), and the most frequent sign at presentation was bone exposure, frequently associated with pain and suppuration (Figures 1A, 2A). Sinus involvement or cutaneous fistulas were not observed.

Panoramic radiograms and computed tomographic (CT) scans were available for all patients and usually showed mixed radiolucent/radiopaque lesions, consistent with osteonecrosis, alterations of bone architecture with loss of medullary bone, trabeculation, or increased bone density (Figures 1B, 1C, 2B, 2C). All patients were nonsmokers; 11 of them did not show related comorbidities (Table 1) and only one patient (Patient 1) had comorbidities (diabetes mellitus and cryoglobulinemia) that could negatively influence wound-healing.

*Histological features.* Histopathological analyses were performed on a total of 22 samples obtained from the 19 patients who had undergone surgical debridement of the bone lesions. The surgical specimens had been briefly decalcified in 2 M EDTA buffer solution, fixed in 10% neutral formalin, embedded in paraffin, and cut and stained with hematoxylin-eosin. Microscopically, a spectrum of bone alterations were evident, including areas with active osteomyelitis filled with abundant inflammatory infiltrates, acellular necrotic debris, dilated blood vessels, prominent scalloping of the borders of bone trabeculae, non-necrotic areas with large osteonic structures, and abundant deposition of interosteonic woven bone. Areas of intense osteogenesis were also evident.

*Treatment and followup.* All patients underwent longterm parenteral antimicrobial therapy, as described above, and bisphosphonate therapy was withdrawn following ONJ in accordance with their referring physicians. Such treatment modality was effective in 5 patients (for a total of 8 lesions) in whom an improvement of ONJ was achieved with resolution of the clinical symptoms.

Surgical debridement was performed in 22 lesions from 19 patients and was curative in 21/22 lesions in terms of both epithelial coverage of the bone exposure and lack of persistent signs of active osteomyelitis, as illustrated in Figure 3.

## DISCUSSION

Since its first description by Marx<sup>15</sup> and Wang, *et al*<sup>16</sup> in 2003, cases of bisphosphonate-related ONJ are being increasingly reported in oncologic patients, in line with the increased use of bisphosphonates for treatment of lytic bone lesions. All previous observations pointed to the potential role of bisphosphonates (mainly zoledronate and pamidronate) as the main pathogenetic factor of ONJ<sup>13,15-21</sup>. The real incidence of ONJ is currently unknown but it was estimated to range from 4.5% to 12.8% in patients with multiple myeloma and 1.2%–12% for patients with metastatic breast cancer<sup>21-23</sup>.

In the last decade, other bisphosphonates such as alendronate, risedronate, clodronate, etc. have been increasingly used to treat bone loss occurring in patients with non-neoplastic disease due to their capacity to reduce the risk of vertebral and nonvertebral fractures in osteoporotic women and

Table 1. Clinical characteristics of patients with osteonecrosis of the jaws.

Patient Age, yrs	Disease	Site	Triggering Event	Pain	Suppuration	Paresthesia	Sinus Involvement	Cutaneous/ Fistulas/ Mandibular Border	No. Lesions	Stage	Bisphosphonate	Direction of Therapy, mo	Interruption of Therapy, Before Surgery, mo	Surgery	Followup (mo)	Comorbidities
1	Osteoporosis	Maxilla	24–25 Extraction	+	+	-	-	-	1	I	Alendronate	12	8	+	Complete healing (34)	Diabetes hepatopathy, eryo- globulinemia
2	Osteoporosis	Maxilla	12–21 Implant surgery	+	+	-	-	-	1	II	Alendronate	12	5	+	Complete healing (15)	-
3	Orthopedic surgery	Mandible	42–43 Periodontal disease	+	+	-	-	-	1	I	Clodronate	16	5	+	Complete healing (18)	-
4	Orthopedic surgery	Mandible	46–47 Implant surgery	+	+	-	-	-	1	I	Clodronate	18	3	+	Complete healing (20)	-
5	Osteoporosis	Mandible	36–37 Extraction	-	+	-	-	-	1	II	Alendronate	11	4	+	Complete healing (20)	-
6	Osteoporosis	Mandible	33 Extraction	+	+	-	-	-	1	II	Clodronate Alendronate	18	8	+	Complete healing (23)	Hypertension
7a	Osteoporosis	Mandible	45 Extraction	+	-	+	-	-	2	II	Alendronate	22	-	-	-	Hypertension
7b	Osteoporosis	Mandible	36 Periapical granuloma	+	-	+	-	-	2	II	Alendronate	22	-	-	-	-
8	Osteoporosis	Mandible	35–36 Extraction	+	-	-	-	-	1	II	Alendronate	28	5	+	Complete healing (30)	-
9	Osteoporosis	Maxilla	24–25 Extraction	+	+	-	-	-	1	I	Clodronate	22	5	+	Complete healing (24)	-
10	Osteoporosis	Mandible	33–35 Extraction	+	+	-	-	-	1	II	Alendronate	12	4	+	Complete healing (16)	-
11	Osteoporosis	Mandible	34–36 Extraction	+	-	-	-	-	1	I	Alendronate	15	4	+	Complete healing (17)	-
12	Osteoporosis	Mandible	37–38 Spontaneous	+	+	-	-	-	1	II	Alendronate	24	6	+	Complete healing (17)	Hypertension
13	Osteoporosis	Mandible	43–45 Extraction	+	-	-	-	-	1	II	Clodronate Risedronate	40	-	-	-	Hypertension
14	Osteoporosis	Maxilla	24 Extraction	+	+	-	-	-	1	II	Alendronate	12	3	+	Complete healing (16)	OLP, HCV
15a	Osteoporosis	Mandible	32 Extraction	+	+	-	-	-	2	II	Alendronate	20	4	+	Complete healing (15)	Hypo- thyroiditis
15b	Osteoporosis	Mandible	42 Extraction	+	+	-	-	-	2	II	Alendronate	20	4	+	Complete healing (15)	-
16	Osteoporosis	Mandible	36 Extraction	+	+	-	-	-	1	II	Alendronate	36	3	+	Complete healing (17)	Gastritis
17a	Osteoporosis	Maxilla	14–15 Periodontal disease	+	+	-	-	-	2	II	Risedronate	24	3	+	Complete healing (16)	-
17b	Osteoporosis	Maxilla	16–18 Extraction	+	+	-	-	-	2	II	Risedronate	24	3	+	Complete healing (16)	-
18	Osteoporosis	Maxilla	14 Periodontal disease	+	+	-	-	-	1	II	Risedronate	20	3	+	Complete healing (16)	-
19a	Osteoporosis	Mandible	43 Implant surgery	+	+	-	-	-	2	I	Alendronate	24	3	-	-	-
19b	Osteoporosis	Mandible	33 Implant surgery	+	+	-	-	-	2	II	Alendronate	24	3	-	-	-

Table 1. Continued.

Patient	Age, yrs	Disease	Site	Triggering Event	Pain	Suppuration	Paresthesia	Sinus Involvement	Cutaneous Fistulas/Mandibular Border	No. Lesions	Stage	Bisphosphonate	Direction of Therapy, mo	Interruption of Therapy Before Surgery, mo	Surgery	Followup (mo)	Comorbidities
20	65	Osteoporosis	Mandible	44-45 Extraction	+	+	-	-	-	1	II	Alendronate	24	5	+	Complete healing (5)	Hypertension
21	82	Osteoporosis	Mandible	33-34 Extraction	+	+	-	-	-	1	II	Alendronate	25	4	+	Complete healing (5)	Hypertension
22a	78	Osteoporosis	Mandible	45-47 Periodontal disease	+	+	-	-	-	2	I	Alendronate	32	12	+	Complete healing (4)	Hypertension
22b			Mandible	35-37 Periodontal disease	+	+	-	-	-		II				+	Complete healing (4)	
23a	67	Corticosteroid induced osteoporosis	Maxilla	14-17 Extraction	+	+	-	-	-	2	II	Ibandronate	12		-		RA
23b			Mandible	44-48 Extraction	+	+	-	-	-		II				-		
24	72	Corticosteroid induced osteoporosis	Maxilla	24-26 Extraction	+	+	-	-	-	1	II	Ibandronate	15		-		SLE, methotrexate

Bisphosphonate dosage: alendronate: oral administration, 70 mg at weekly intervals; clodronate: intramuscular administration, 100 mg at weekly intervals; ibandronate: oral administration, 150 mg at monthly intervals; risedronate: oral administration, 35 mg at weekly intervals. OLP: oral lichen planus; HCV: hepatitis C virus.

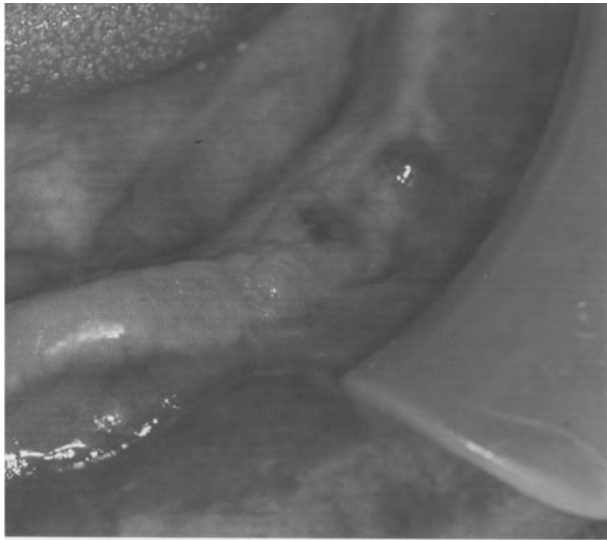
to induce the stabilization of orthopedic prostheses after surgery, as reported<sup>24-26</sup>. Nevertheless, the prevalence of ONJ in non-neoplastic patients is rare<sup>17,18</sup> and the cancer and non-cancer patient populations differ in terms of bisphosphonate administration, dosage, potency, comorbidities, and estimated life expectancy.

All bisphosphonates share several common properties, such as poor intestinal absorption, high bone affinity, inhibitory effects on bone resorption, and prolonged bone retention. Their poor bioavailability and the use of relatively low doses might be related to differences among the distinct classes of bisphosphonates. It was speculated that the concentration of bisphosphonate present in bone mineral as well as the total dose administered over a long period of time are important for reducing the magnitude of bone turnover<sup>27</sup>.

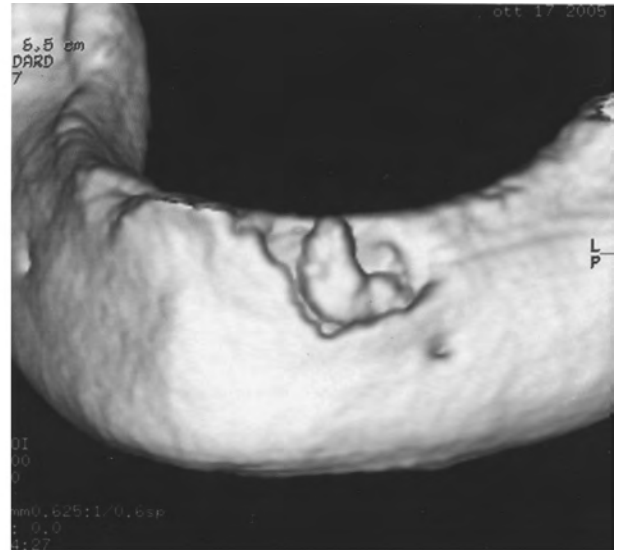Our study describes the clinical features, predisposing factors, salient histological features, and treatment modalities of bisphosphonate-induced ONJ in a relatively large cohort of non-neoplastic patients. Patients received different types of bisphosphonates (with a relative prevalence of alendronate) on a weekly regimen, with only 2 patients receiving ibandronate monthly. The mean duration of the treatment from first administration of bisphosphonate to the clinical observation of ONJ was 20.6 months (range 11-40 mo). Apparently, the development of ONJ may be related to duration of bisphosphonate therapy, and we were able to detect such lesions as early as 11 months from the start of therapy. This finding is not in agreement with several recent studies in which a time interval of at least 3 years from start of bisphosphonate therapy was proposed as the minimum to allow clinical presentation of ONJ<sup>17,28</sup>.

Several clinical symptoms of ONJ appear to be similar in neoplastic and non-neoplastic bisphosphonate-treated patients, including pain, bone exposure, and purulent secretion. However, more severe lesions such as sinus involvement, mandibular paresthesia, discontinuation of the inferior mandibular border, or cutaneous fistulae, which are frequently detected in neoplastic patients, were not observed in our series, thus supporting a possibly more indolent clinical course of ONJ in non-neoplastic patients.

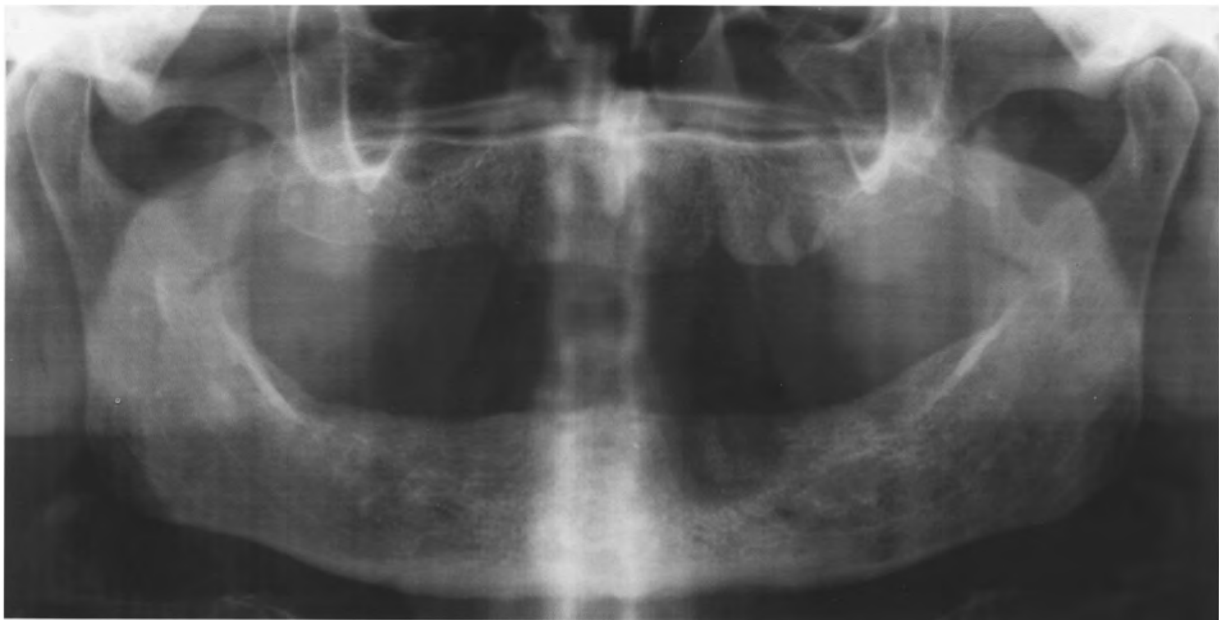
It is known that bisphosphonate-related ONJ may be triggered by implant surgery<sup>29,30</sup>, and in our current study group 3 patients who had received implant surgery after the start of bisphosphonate therapy developed ONJ, at variance with 3 patients in whom implant restoration was performed before start of bisphosphonate therapy who did not develop ONJ. Consequently, ONJ seems strictly related to the surgical procedure performed during dental implantation. In view of the current lack of contraindications for dental implants in patients undergoing bisphosphonate therapy, patients eligible for such procedures should be carefully informed of these possible harmful side effects<sup>28-34</sup>. Also, it is advisable that a consensus be promptly reached on how to manage



**A**



**C**



**B**

*Figure 1.* A. Clinical view of multiple fistulae of the mandibular alveolar bone. B. Panoramic radiograph showing an ill-defined radiolucent lesion, which is better demonstrated on CT scan. (C) 3-dimensional reconstruction.

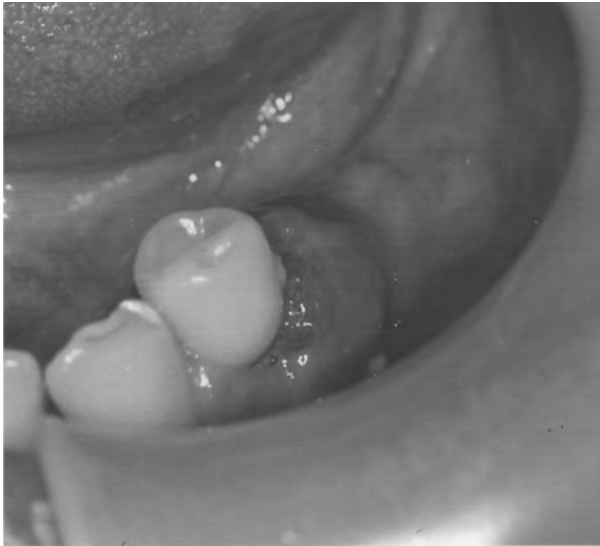patients to be treated with bisphosphonates, and that appropriate screening guidelines be developed to possibly prevent occurrence of ONJ.

Although the diagnosis may be straightforward in cases with overt bone exposure, the clinical relevance of symptoms such as pain, swelling, and paresthesia frequently is underestimated for several months, probably due to the lack of awareness of this condition by physicians, dentists, and patients. In fact, at early stages of ONJ, panoramic radiographs may not adequately rule out this condition, especially after extraction procedures, as they may show only post-extraction sockets with scarce tendency to wound-healing.

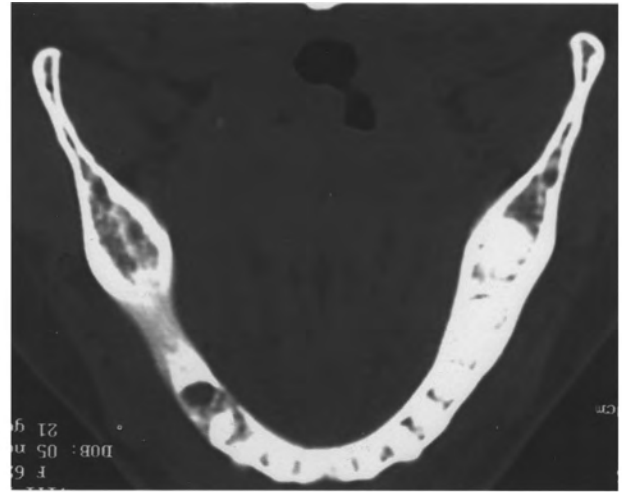
In such instances, CT scans should be ordered to further assess the involved site and better define bone damage.

We were able to confirm that ONJ more commonly affects the mandible than the maxilla, despite the more abundant vascular supply of the latter. These findings are consistent with previous reports<sup>18,31,32</sup> supporting the abolition of osteoclast-mediated bone resorption, rather than antiangiogenic properties of bisphosphonates, as an etiologic factor.

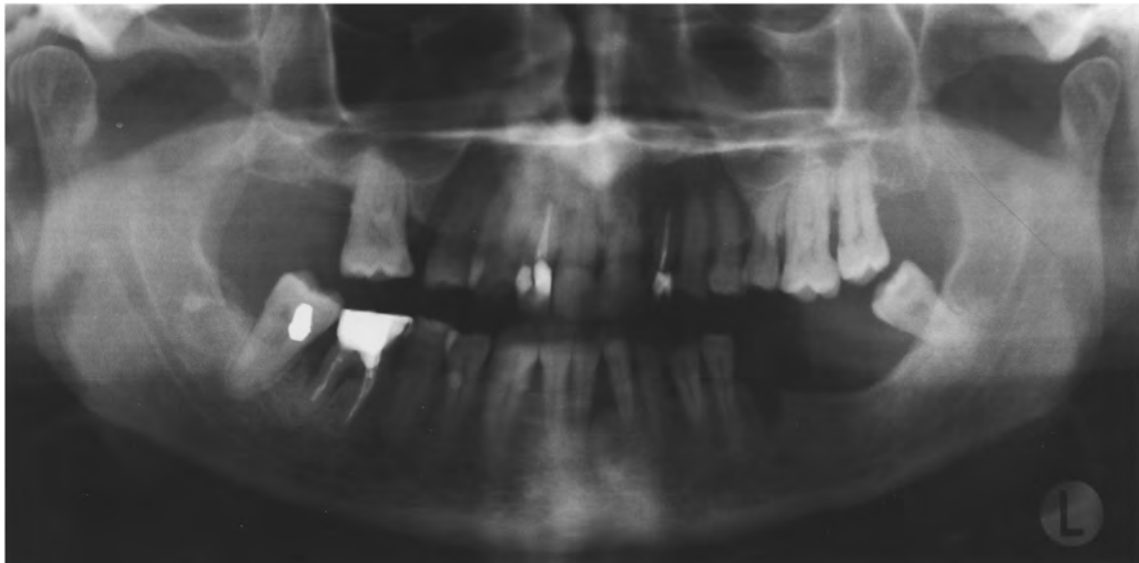To date, no definitive consensus has been reached on the treatment of ONJ, and several studies reported relatively poor results following surgery, antibiotics, or hyperbaric



**A**



**C**



**B**

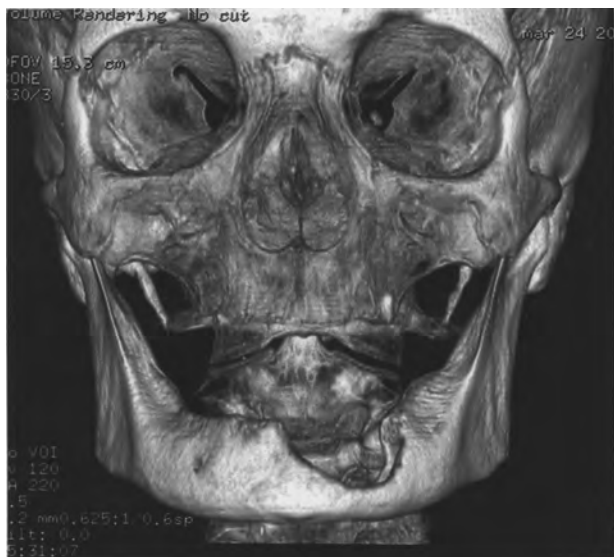Figure 2. A. Clinical view of a periodontal fistula of the alveolar bone close to the first inferior premolar. B. The radiograph clearly shows a nonhealing socket 4 months after tooth extraction. C. Wider bone damage is shown by CT scan.

oxygen administration<sup>12,31-33</sup>. Although surgery was found to be nonbeneficial for neoplastic patients with ONJ taking intravenous bisphosphonates, it is accepted<sup>31,32</sup> that surgical procedures may achieve better outcomes in non-neoplastic patients. This may be due to relevant differences in types of bisphosphonate, route of administration, dosage, and length of treatment. Consequently, we considered surgical debridement with the use of piezosurgery (a less invasive procedure compared to conventional knife or scalpel surgery), a potentially safer procedure in this subset of patients. In addition, we also recommended discontinuation of bisphosphonate therapy for at least 3 months before surgical debridement. The use of this therapeutic protocol, in combination with prolonged antibiotic therapy, allowed relevant and persistent

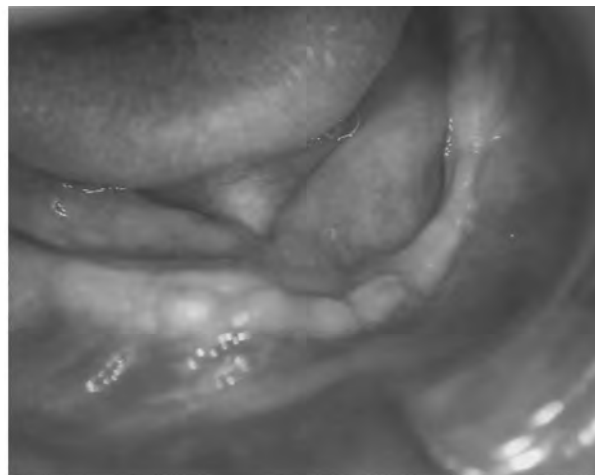
benefits in the majority of treated patients (18/19) with clinico-radiological healing of 21/22 bone exposures.

Currently, discontinuation of bisphosphonate therapies before and after any dental procedure has been repeatedly advised<sup>17,35</sup>. It should be noted, however, that there are no uniform data demonstrating that the discontinuation of bisphosphonates will improve outcomes for patients with ONJ. On the other hand, other authors postulated that, given the long retention time of bisphosphonates within the skeleton, temporary discontinuation of bisphosphonate therapy is unlikely to have beneficial effects on a patient's skeletal conditions<sup>28</sup>.

No major comorbidities were ascertained in our series, although 3 patients were taking low-dose steroid therapy for



**A**



**B**

Figure 3. Twenty-three month followup of the case illustrated in Figure 1 shows complete healing of the lesion.

SLE and low-dose immunosuppressing agents for RA and diabetes/cryoglobulinemia, respectively. The synergistic effects of comorbidity factors in the pathogenesis and prognosis of ONJ should be further investigated in larger series of patients.

Interestingly, in 2007, Yarom, *et al*<sup>32</sup> reported on the possible correlation between cigarette smoking and development, course, and prognosis of bisphosphonate-related ONJ. The results of our study, which involved nonsmoking patients only, do not support a major role of cigarette smoking in ONJ development, at least in non-neoplastic patients.

Marx, *et al*<sup>17</sup> proposed the dosage of serum C-telopeptide (CTX) to assess the risks of ONJ development and guide therapeutic decisions in bisphosphonate-treated patients. Nevertheless, the real usefulness of such a procedure has recently been questioned by the American Society for Bone and Mineral Research<sup>35</sup>, which concluded that the above recommendations were based on the observation of a very small group of patients in a study that did not include a control group. Moreover, CTX and other metabolic bone markers seem to only weakly predict occurrence of additional lesions and progression of the disease following the first clinical manifestation of ONJ<sup>36</sup>.

ONJ in non-neoplastic patients seems to be a relatively rare condition. As suggested by the American Dental Association<sup>12</sup>, dentists should inform their patients undertaking bisphosphonate therapy about the risk of developing ONJ before any dental procedure, even if minimally invasive. Moreover, it is our opinion that the prescribing physician should also discuss this issue with the patient as a part of the general instructions for oral bisphosphonate use and consider referring the patient for dental examination before start of therapy. Finally, healthcare providers should encour-

age their patients who are starting or continuing to take bisphosphonates to practice good oral hygiene and have regular dental visits before starting and during therapy, to receive proper dental care and prevent harmful side effects of such therapies.

## REFERENCES

1. McClung MR. Bisphosphonates. *Endocrinol Metab Clin North Am* 2003;32:253-71.
2. Rodan GA, Fleisch HA. Bisphosphonates: Mechanisms of action. *J Clin Invest* 1996;97:2692-6.
3. Santini D, Vespasiani Gentilucci U, Vincenzi B, Picardi A, Vasaturo F, et al. The antineoplastic role of bisphosphonates: from basic research to clinical evidence. *Ann Oncol* 2003;14:1468-76.
4. Boissier S, Magnetto S, Frappart L, Cuzin B, Ebetino FH, Delmas PD, et al. Bisphosphonates inhibit prostate and breast carcinoma cell adhesion to unmineralized and mineralized bone extracellular matrices. *Cancer Res* 1997;57:3890-4.
5. Wysowski DK. Reports of esophageal cancer with oral bisphosphonate use. *N Engl J Med* 2009;360:89-90.
6. Loke YK, Jeevanantham V, Singh S. Bisphosphonates and atrial fibrillation: systematic review and meta-analysis. *Drug Saf* 2009;32:219-28.
7. Conte P, Guarneri V. Safety of intravenous and oral bisphosphonates and compliance with dosing regimens. *Oncologist* 2004;9:28-37.
8. Ibrahim T, Barbanti F, Giorgio-Marrano G, Mercatali L, Ronconi S, Vicini C, et al. Osteonecrosis of the jaw in patients with bone metastases treated with bisphosphonates: a retrospective study. *Oncologist* 2008;13:330-6.
9. Hewitt C, Farah C. Bisphosphonate-related osteonecrosis of the jaws: a comprehensive review. *J Oral Pathol Med* 2007;36:319-28.
10. Cavanna L, Bertè R, Arcari A, Mordenti P, Pagani R, Vallisa D. Osteonecrosis of the jaw. A newly emerging site-specific osseous pathology in patients with cancer treated with bisphosphonates. Report of five cases and review of the literature. *Eur J Intern Med* 2007;18:417-22.
11. Bagan JV, Jimenez Y, Murillo J, Hernandez S, Poveda R, Sanchis

- JM, et al. Jaw osteonecrosis associated with bisphosphonates: multiple exposed areas and its relationship to teeth extractions. Study of 20 cases. *Oral Oncol* 2006;42:327-9.
12. American Dental Association Council on Scientific Affairs. Dental management of patients receiving oral bisphosphonate therapy: Expert panel recommendations. *J Am Dent Assoc* 2006;137:1144-50.
  13. Rizzoli R, Burler N, Cahall D, Delmas PD, Eriksen EF, Felsenberg D, et al. Osteonecrosis of the jaw and bisphosphonate treatment for osteoporosis. *Bone* 2008;42:841-7.
  14. Ruggiero SL, Fantasia J, Carlson E. Bisphosphonate-related osteonecrosis of the jaw: background and guidelines for diagnosis, staging and management. *Oral Surg Oral Med Oral Pathol Oral Radiol Endod* 2006;102:433-41.
  15. Marx RE. Pamidronate (Aredia) and zoledronate (Zometa) induced avascular necrosis of the jaws: a growing epidemic. *J Oral Maxillofac Surg* 2003;61:1115-7.
  16. Wang J, Goodger NM, Pogrel MA. Osteonecrosis of the jaws associated with cancer chemotherapy. *J Oral Maxillofac Surg* 2003;61:1104-7.
  17. Marx RE, Cillo JE Jr, Ulloa JJ. Oral bisphosphonate-induced osteonecrosis: risk factors, prediction of risk using serum CTX testing, prevention, and treatment. *J Oral Maxillofac Surg* 2007;65:2397-410.
  18. Ruggiero SL, Mehrotra B, Rosenberg TJ, Engroff SL. Osteonecrosis of the jaws associated with the use of bisphosphonates: A review of 63 cases. *J Oral Maxillofac Surg* 2004;62:527-34.
  19. Migliorati CA, Schubert MM, Peterson DE, Seneda LM. Bisphosphonate associated osteonecrosis of mandibular and maxillary bone: An emerging oral complication of supportive cancer therapy. *Cancer* 2005;104:83-93.
  20. Migliorati CA. Bisphosphonates and oral cavity avascular bone necrosis. *J Clin Oncol* 2003;21:4253-4.
  21. Melo MD, Obeid G. Osteonecrosis of the maxilla in a patient with a history of bisphosphonate therapy. *J Can Dent Assoc* 2005;71:111-3.
  22. Durie BG, Katz M, Crowley J. Osteonecrosis of the jaw and bisphosphonates. *N Engl J Med* 2005;353:99-102.
  23. Bamias A, Kastritis E, Bamia C, Mouloupoulos LA, Melakopoulos I, Bozas G, et al. Osteonecrosis of the jaw in cancer after treatment with bisphosphonates: incidence and risk factors. *J Clin Oncol* 2005;23:8580-7.
  24. Watts NB, Chines A, Olszynski WP, McKeever CD, McClung MR, Zhou X, et al. Fracture risk remains reduced one year after discontinuation of risedronate. *Osteoporos Int* 2008;19:365-72.
  25. Cranney A, Guyatt G, Griffith L, Wells G, Tugwell P, Rosen C. Summary of meta-analyses of therapies for postmenopausal osteoporosis. *Endocr Rev* 2002;23:570-8.
  26. Hilding M, Aspenberg P. Postoperative clodronate decreases prosthetic migration: 4-year follow-up of a randomized radiostereometric study of 50 total knee patients. *Acta Orthop* 2006;77:912-6.
  27. Chapurlat RD, Delmas PD. Drug insight: Bisphosphonates for postmenopausal osteoporosis. *Nat Clin Pract Endocrinol Metab* 2006;2:211-9.
  28. Khosla S, Burr D, Cauley J, Dempster DW, Ebeling PR, Felsenberg D, et al. Bisphosphonate-associated osteonecrosis of the jaw: report of a task force of the American Society for Bone and Mineral Research. *J Bone Miner Res* 2007;22:1479-91.
  29. Brooks JK, Gilson AJ, Sindler AJ, Ashman SG, Schwartz KG, Nikitakis NG. Osteonecrosis of the jaws associated with use of risedronate: report of 2 new cases. *Oral Surg Oral Med Oral Pathol Oral Radiol Endod* 2007;103:780-6.
  30. Wang HL, Weber D, McCauley LK. Effect of long-term oral bisphosphonates on implant wound healing: literature review and a case report. *J Periodontol* 2007;78:584-94.
  31. Marx RE, Sawatari Y, Fortin M, Broumand V. Bisphosphonate-induced exposed bone (osteonecrosis/osteopetrosis) of the jaws: risk factors, recognition, prevention, and treatment. *J Oral Maxillofac Surg* 2005;63:1567-75.
  32. Yarom N, Yahalom R, Shoshani Y, Hamed W, Regev E, Elad S. Osteonecrosis of the jaw induced by orally administered bisphosphonates: incidence, clinical features, predisposing factors and treatment outcome. *Osteoporos Int* 2007;18:1363-70.
  33. Elad S, Yarom N, Hamed W, Ayalon S, Yahalom R, Regev E. Osteomyelitis and necrosis of the jaw in patients treated with bisphosphonates. A comparative study. *Clin Lab Haematol* 2006;28:393-8.
  34. Serra MP, Llorca CS, Donat FJ. Oral implants in patients receiving bisphosphonates: a review and update. *Med Oral Patol Oral Cir Bucal* 2008;13:E755-60.
  35. American Society for Bone and Mineral Research Task Force on Osteonecrosis of the Jaw. Oral bisphosphonate-induced osteonecrosis: risk factors, prediction of risk using serum CTX testing, prevention, and treatment. *J Oral Maxillofac Surg* 2008;66:1320-1.
  36. Bagan JV, Jiménez Y, Gómez D, Sirera R, Poveda R, Scully C. Collagen telopeptide (serum CTX) and its relationship with the size and number of lesions in osteonecrosis of the jaws in cancer patients on intravenous bisphosphonates. *Oral Oncol* 2008;44:1088-9. Epub 2008 Apr 8.