

# Pulmonary Nodulosis and Aseptic Granulomatous Lung Disease Occurring in Patients with Rheumatoid Arthritis Receiving Tumor Necrosis Factor- $\alpha$ -Blocking Agent: A Case Series

ERIC TOUSSIROT, JEAN MARIE BERTHELOT, EDOUARD PERTUISET, BÉATRICE BOUVARD, PHILIPPE GAUDIN, DANIEL WENDLING, JOSÉ le NOACH, ANNE LOHSE, EMMANUELLE LECUYER, and Le CRI

**ABSTRACT. Objective.** To describe cases of development of pulmonary nodulosis or aseptic granulomatous lung disease in patients with rheumatoid arthritis (RA) receiving anti-tumor necrosis factor- $\alpha$  (TNF- $\alpha$ ) therapy.

**Methods.** A call for observation of such cases was sent to members of the French “Club Rhumatismes et Inflammation.” The cases had to occur after introduction of TNF- $\alpha$ -blocking therapy.

**Results.** Eleven cases were examined: 6 patients were treated with etanercept, 2 with infliximab, and 3 with adalimumab. Pulmonary nodular lesions were observed after a mean treatment period of 23.3  $\pm$  15.3 months. Clinical symptoms were observed in 5 cases. Radiographs or computed tomography of the chest showed single or multiple nodular lesions in 10 cases and hilar adenopathies in 1 case. Biopsy of the nodular chest lesions or mediastinal lymphadenopathies were performed in 8 patients, and revealed typical rheumatoid nodules in 4 cases and noncaseating granulomatous lesions in 4 cases. Mycobacterial or opportunistic infections were excluded for all cases. Outcome was favorable for all the patients, with either discontinuation or maintenance of anti-TNF- $\alpha$  treatment.

**Conclusion.** Aseptic pulmonary nodular inflammation corresponding to rheumatoid nodules or non-caseating granulomatous inflammation can occur during anti-TNF- $\alpha$  therapy for RA, mainly etanercept. The mechanism explaining such a reaction is not clear but certainly includes different processes. These cases of pulmonary nodular inflammation generally have a benign course and do not systematically require withdrawal of treatment. (J Rheumatol First Release Oct 1 2009; doi:10.3899/jrheum.090030)

## Key Indexing Terms:

NODULOSIS RHEUMATOID ARTHRITIS TUMOR NECROSIS FACTOR- $\alpha$  ANTAGONISTS

From the Department of Rheumatology, University Hospital Jean Minjot, and EA 3186 Agents Pathogènes et Inflammation, IFR 133 University of Franche-Comté, Besançon; CIC Biotherapy 506, St. Jacques Hospital Besançon, Besançon; Department of Rheumatology, University Hospital Nantes, Nantes; Department of Rheumatology, René Dubos Hospital, Pontoise; Department of Rheumatology, University Hospital Angers, Angers; Department of Rheumatology, University Hospital Grenoble, Grenoble; Department of Rheumatology, Cholet; Department of Rheumatology, Belfort; Department of Pneumology and Infectious Diseases, St. Quentin; and Club Rhumatismes et Inflammation, University Hospital Pitié Salpêtrière, Paris, France.

E. Toussiro, MD, PhD, Department of Rheumatology, University Hospital Jean Minjot, EA 3186 Agents Pathogènes et Inflammation, IFR 133 University of Franche-Comté, CIC Biotherapy 506, St. Jacques Hospital; J.M. Berthelot, MD, PhD, Department of Rheumatology, University Hospital Nantes; E. Pertuiset, MD, Department of Rheumatology, René Dubos Hospital; B. Bouvard, MD, Department of Rheumatology, University Hospital Angers; P. Gaudin, MD, PhD, Department of Rheumatology, University Hospital Grenoble; D. Wendling, MD, PhD, Department of Rheumatology, University Hospital Jean Minjot, EA 3186 Agents Pathogènes et Inflammation, IFR 133 University of Franche-Comté; J. le Noach, MD, Department of Rheumatology, Cholet; A. Lohse, MD, Department of Rheumatology, Belfort; E. Lecuyer, MD, Department of Pneumology and Infectious Diseases, St. Quentin; Le Cri, Club Rhumatismes et Inflammation, University Hospital Pitié Salpêtrière.

Address correspondence to Dr. E. Toussiro, Department of Rheumatology, University Hospital Jean Minjot, Bd Fleming, 25000 Besançon, France.  
E-mail: etoussiro@chu-besancon.fr

Accepted for publication June 27, 2009.

Rheumatoid nodules occur in approximately 25% of patients with rheumatoid arthritis (RA) and are mainly located subcutaneously at pressure points such as elbows or hands. They may also be observed in internal tissues and can compromise organ function leading to clinical symptoms. The liver, eyes, heart, and lungs may be affected by such nodules.

Tumor necrosis factor- $\alpha$  (TNF- $\alpha$ ) antagonists are now widely used for treating RA. Various side effects have been described with the different TNF- $\alpha$  antagonists available, mainly infections. The efficacy of these agents for treatment of extraarticular features of RA such as rheumatoid nodules has not been specifically evaluated in large placebo-controlled randomized trials. However, it has been reported that etanercept has no influence on subcutaneous nodules in RA<sup>1</sup>. Conversely, there are some reports of accelerated cutaneous nodulosis<sup>2</sup> and descriptions of development of histologically proved pulmonary rheumatoid nodules or granulomatous inflammation in patients receiving anti-TNF- $\alpha$  therapy<sup>3,4</sup>.

We report the largest series of patients with RA under treatment with TNF- $\alpha$  antagonist developing pulmonary

nodular lesions that corresponded to rheumatoid nodules or aseptic noncaseating granulomatous inflammation.

## MATERIALS AND METHODS

Between 2005 and 2008, all members of the Club Rhumatismes et Inflammation (a section of the French Society of Rheumatology including 866 rheumatologists and internal medicine practitioners) were contacted by e-mail to collect reports of patients with RA who presented with pulmonary nodules during anti-TNF- $\alpha$  therapy. To be enrolled in this case study analysis, the pulmonary nodules had to occur after the introduction of TNF- $\alpha$ -blocking agent and had to correspond to rheumatoid nodules that were proved histologically. A rheumatoid nodule was defined as a central necrotic fibrinoid tissue, surrounded by a palisaded layer of mononuclear cells and a peripheral vascular zone with chronic inflammation<sup>5</sup>. Alternatively, pulmonary nodules may also correspond to aseptic and noncaseating granulomatous inflammation that relates to a chronic organized inflammatory lesion defined by the presence of macrophages (some of which may be giant multinuclear or epithelioid cells) surrounded by a lymphoid infiltrate and fibrosis. This granuloma may be well formed or alternatively poorly organized, and may be centered on a noncaseating necrotic zone<sup>6</sup>. The patients also had to have a normal chest radiograph before the anti-TNF- $\alpha$  treatment. Patients who had preexisting nodular lung lesions prior to the anti-TNF- $\alpha$  treatment and who developed new pulmonary nodules were also included. Other causes of pulmonary nodules had to be excluded, especially opportunistic and mycobacterial infections and malignant neoplastic diseases. These conditions were excluded using specific bacteriological procedures and histological analysis.

## RESULTS

**Patient demographics.** Eleven patients were reported, 8 men and 3 women, with a mean age of  $56.3 \pm 10.8$  years and mean disease duration of  $9.2 \pm 7.1$  years. Subcutaneous rheumatoid nodules were present in 3 cases before starting the anti-TNF- $\alpha$  agent. Two patients had preexisting lung pulmonary lesions prior to the anti-TNF- $\alpha$  treatment that were diagnosed as rheumatoid nodules. Other extraarticular findings were vasculitis in one patient and pulmonary fibrosis in another. Five patients had leflunomide and 3 had methotrexate as associated therapy to the TNF- $\alpha$  blocker. They all had corticosteroids at a mean dosage of  $5.7 \pm 4.6$  mg prednisolone. Six patients received etanercept, 2 had infliximab, and 3 adalimumab. Before starting anti-TNF- $\alpha$  treatment, each patient was screened for tuberculosis and underwent a chest radiograph, a clinical pulmonary examination, and a PPD test according to French agency recommendations. The mean delay between onset of anti-TNF- $\alpha$  and development of lung nodular lesions was  $23.3 \pm 15.3$  months (Table 1).

**Clinical symptoms and biological findings.** Asthenia, cough, dyspnea, or chest pain was reported by 5 patients, while the others were asymptomatic. Patients had active disease as shown by a mean Disease Activity Score (DAS28) of  $3.5 \pm 1.3$  and increased values of erythrocyte sedimentation rate ( $23.5 \pm 20.7$  mm/h) and C-reactive protein ( $31.2 \pm 37.9$  mg/l). Rheumatoid factors were positive in 10 cases and anti-cyclic citrullinated peptide antibodies in 7 patients. Sputum cultures were performed for all patients and were negative for mycobacteria and fungi. No patient reported

new onset of subcutaneous nodules. Ten patients responded to the anti-TNF- $\alpha$  treatment with a significant improvement of the DAS28 score.

**Radiological and computed tomography findings.** Single or multiple nodules were found in 10 cases and hilar adenopathies in one case. Cavitated lesions were observed in 2 cases (Cases 2 and 10 in Table 1). They were found in 2 male patients: the first was under adalimumab treatment and the second etanercept. Both were asymptomatic. Extensive studies for microbial organisms (mycobacteria and opportunistic infections) were all negative (including cultures from bronchoscopy and bronchoalveolar lavage specimens for Case 2 and nodular lung biopsy examination for Case 10 with tissue stains for acid-fast bacillus and fungi, as well as microscopic examination of stained specimens). One patient had conflating nodular lesions (Case 6 in Table 1). Nodular lesions were observed both at the bases and at the apical regions of the lungs. Subpleural nodules were also observed (Figures 1, 2, 3).

**Histological examination.** An open lung biopsy of the nodules was performed in 7 cases and hilar adenopathies were also biopsied for the patient without a nodular lesion. A biopsy was not performed for the 3 other patients for various reasons (one patient had hemophilia, another had preexisting lung rheumatoid nodules and a systematic new chest radiograph showed the development of new multiple nodular lesions; after a followup of more than 2 years, outcome for the third patient was favorable with discontinuation of anti-TNF- $\alpha$  therapy; in addition, the pneumologist considered that the nodular chest lesion was very suggestive of a rheumatoid nodule). Characteristic rheumatoid nodule was found in 4 cases, one patient had a chronic and granulomatous inflammatory lesion, 2 others had a granulomatous lesion with central fibrinoid necrosis, and the last corresponded to lymphadenopathy, which showed noncaseating granuloma formation with silica particles. Cultures of biopsy specimens for all these patients were negative for opportunistic infectious agents including mycobacteria and fungi. In addition, angiotensin-converting enzyme levels were normal.

**Patient outcomes.** Anti-TNF- $\alpha$  treatment was discontinued in 6 cases and was maintained for the others. In most cases, including those who continued anti-TNF- $\alpha$  treatment and after a mean monitoring period of 2 years, there was no evidence of progression of the lung nodules; in one case (Case 2, who did not undergo a biopsy), the nodule resolved spontaneously. For one patient (Case 11), anti-TNF- $\alpha$  treatment was reintroduced after a 6-month withdrawal period, and again, new nodular lung lesions were observed. Finally, 2 patients who discontinued the TNF- $\alpha$ -blocking agent received rituximab, with resolution of the nodules.

## DISCUSSION

Rheumatoid nodules are considered the most characteristic

Table 1. Case series of pulmonary nodulosis and hilar adenopathies occurring in patients with rheumatoid arthritis under anti-TNF- $\alpha$  treatment.

Case	Age, Sex	Disease duration, yrs	Extraarticular Disease	DMARD	Anti-TNF- $\alpha$ Agent and Delay (mo)	Clinical Symptoms	Chest Radiograph and Computed Tomography	Biopsy	Outcome
1	70 M	10	—	LEF	IFX (48)	—	Multiple nodular lesions in the 2 lung bases	Rheumatoid nodule	IFX maintained No progression of the nodules
2	57 M	7	Subcutaneous nodules	LEF	ADA (12)	Asthenia	Cavitated lesion at the apical part of the right lung	No	ADA discontinued Resolution
3	74 M	8	Subcutaneous nodules	MTX	IFX (48)	—	Large nodule in right midzone and disseminated micronodules	Rheumatoid nodule	IFX discontinued. No progression of the nodules
4	70 F	9	Subcutaneous nodules	LEF	ETA (9)	—	Disseminated bilateral nodules	Chronic and inflammatory granulomatous lesion	ETA discontinued. Resolution with rituximab treatment
5	54 M	2	—	MTX	ETA (6)	Asthenia, cough	Large nodule in left lung with disseminated micronodular lesions	Granulomatous lesion with central necrosis	ETA discontinued. Resolution with rituximab treatment
6	45 F	12	Pulmonary fibrosis	—	ETA (24)	Cough	Bilateral merging nodules predominating at the apical part of the 2 lungs	Rheumatoid nodules	ETA maintained. No progression of nodules
7	56 M	29	Vasculitis	—	ETA (13)	Chest pain	Bilateral hilar adenopathies	Noncaseating granulomatous lesion with silica particles	ETA discontinued. No progression of nodules
8	45 F	4	—	LEF	ADA (12)	Cough, dyspnea	Appearance of new nodular lesion in each lung	No	ADA maintained. No progression of nodules
9	52 M	7	—	—	ETA (36)	—	Nodules in apical region of the 2 lungs	No	ETA maintained. No progression of nodules
10	54 M	8	—	MTX	ETA (31)	—	Multiple cavitating nodular lesion in right lung base	Granulomatous lesion with central necrosis	ETA discontinued. No progression of nodules
11	42 M	6	—	LEF	ADA (17)	—	3 nodules in apical region of right lung	RN	ADA discontinued and then restarted: development of new nodules

DMARD: disease-modifying antirheumatic drug; LEF: leflunomide; MTX: methotrexate; IFX: infliximab; ETA: etanercept; ADA: adalimumab; RN: rheumatoid nodule.

extraarticular feature of RA. Predisposing factors for development of rheumatoid nodules in RA have been identified as genetic factors (HLA-DRB1\*04), smoking, severe articular disease, and positivity for rheumatoid factors. Pathogenic mechanisms leading to the development of rheumatoid nodules are not well understood, but it is thought that local trauma, vasculitis, proteolytic enzymes, and immune complexes play a role. Vascular events probably initiate the nodule formation, followed by immune complex activation of local monocytes and macrophages and then by the release of cytokines and proteinases by activated macrophages, resulting in the palisaded arrangement of cells<sup>5</sup>. Some similarities

between the rheumatoid nodule and the rheumatoid synovium have been emphasized; indeed, they both included activated macrophages and a process of new vessel formation<sup>3</sup>. However, compared to inflamed synovium, the anatomical organization of the rheumatoid nodule has some differences<sup>3</sup>: there is no lymphoid organization, no B cells or plasma cells, no major cellular infiltration by T cells, and interleukin 1 concentrations are higher in rheumatoid nodules, while TNF- $\alpha$  concentrations are lower<sup>7</sup>.

We describe here 11 cases corresponding to the development of nodular lung lesions in 8 cases, the appearance of new nodular lesions in 2 cases, and the development of hilar

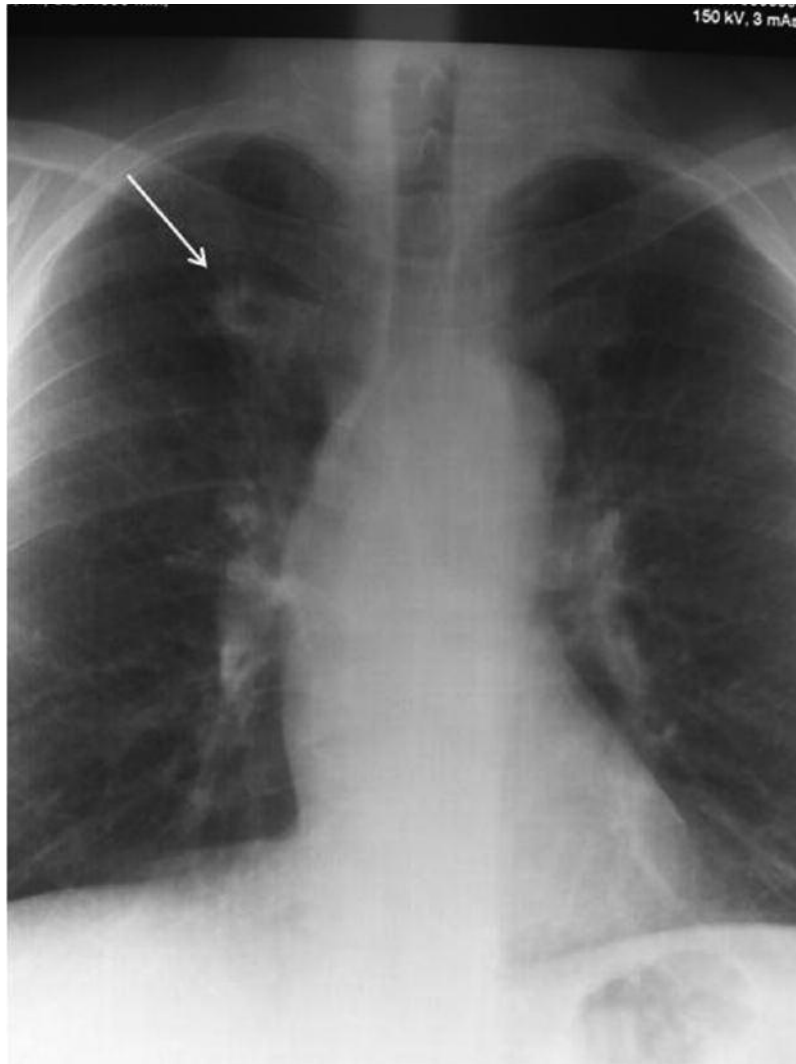


Figure 1. Chest radiograph showing cavitated nodular lesion in the apical part of the right lung (arrow).

adenopathies with granulomatous reaction in another case. The nodular lung lesions corresponded to typical histologically proved rheumatoid nodules in 4 cases and aseptic and noncaseating granulomatous lung inflammation in 3 cases. These cases were mainly observed with etanercept (6/11) and occurred in patients receiving associated disease-modifying antirheumatic drugs (DMARD) such as methotrexate or leflunomide in 8 cases. However, we did not observe cutaneous nodulosis in this series. With the discontinuation of the TNF- $\alpha$ -blocking agent, all the patients had a favorable outcome, with stability or even resolution of the nodular lesion. Interestingly, 4 patients continued their treatment (including etanercept in 2 cases) without progression of the nodular lesion. Conversely, in one patient, the reintroduction of the TNF- $\alpha$ -blocking agent again induced the development of nodular lung lesions.

Uncommon cases of cutaneous nodulosis have been reported under treatment with the 3 anti-TNF- $\alpha$  agents<sup>2,3,8</sup>

(Table 2). There are also a limited number of reports of pulmonary nodulosis in patients with RA receiving anti-TNF- $\alpha$  therapy: 5 cases were identified in the literature search<sup>3,9-12</sup>. All these patients were treated with etanercept with a treatment duration ranging from 2 months to 2 years. In 3 cases, patients with RA had subcutaneous nodules before the administration of etanercept<sup>3,10,11</sup>. Clinical symptoms for pulmonary nodulosis were cough or dyspnea in 2 cases. All the nodular lesions were biopsied, revealing characteristic rheumatoid nodules. These nodular lung lesions were resolved with discontinuation of etanercept. In one case, etanercept was maintained, and there was no evidence of progression of the lung nodules<sup>12</sup>. In common with the 4 cases from our series, pulmonary granulomatous inflammation or sarcoid-like granulomatous disease located in the lungs was reported in 10 patients with RA under etanercept treatment<sup>4,13-15</sup>. A biopsy of the nodular lesions showed well formed or less organized aseptic and noncaseating granulo-

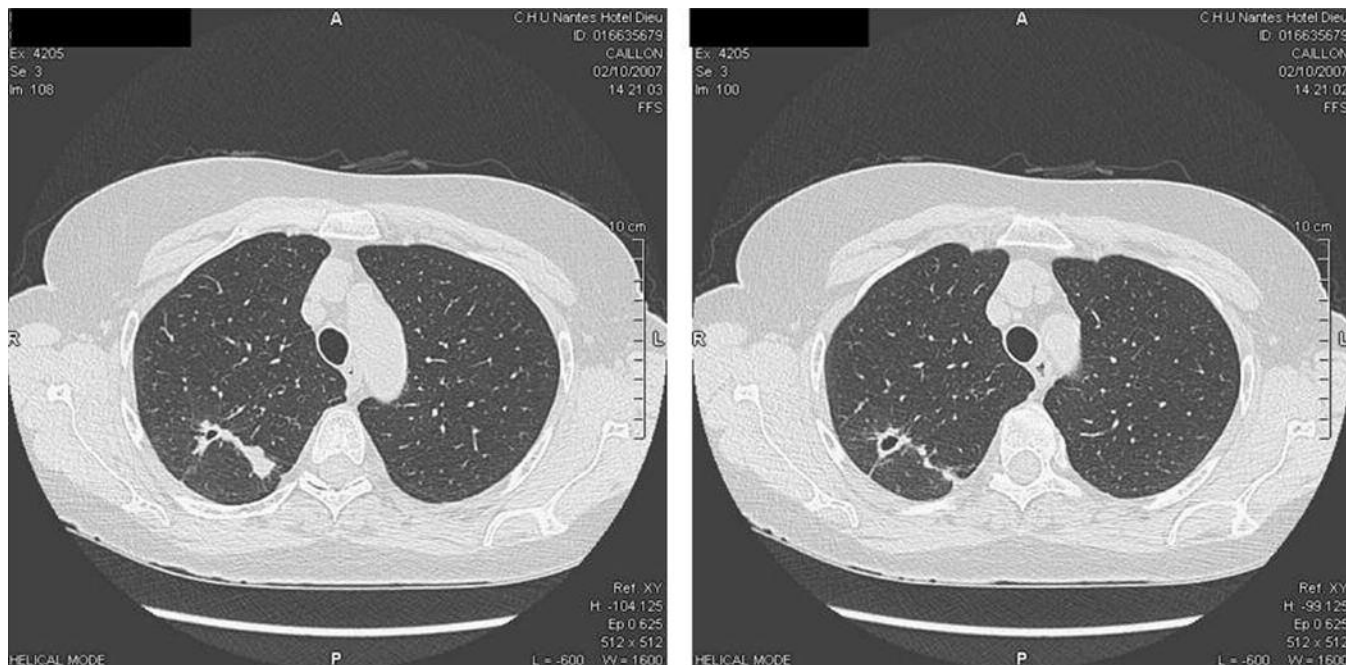


Figure 2. Computed tomography of the chest showing a pulmonary nodule in the right lung with cavitation.

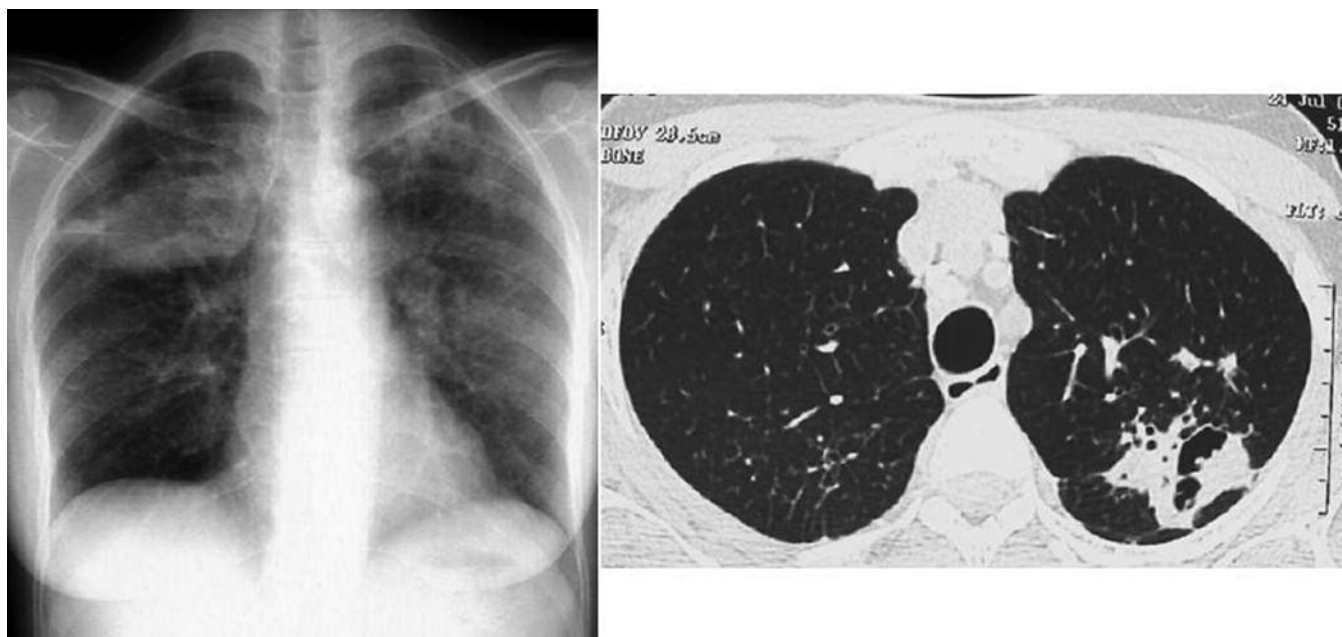


Figure 3. Chest radiograph and computed tomography showing disseminated bilateral and merging nodules.

matous inflammation with negative cultures for mycobacteria or fungi. All these patients had a favorable outcome after cessation of the drug, and no recurrence of the pulmonary disease was observed with the introduction of adalimumab in 4 cases<sup>4</sup>.

An unexpected finding in one patient in our series was silica particles within the noncaseating granulomatous reaction. This patient had mediastinal lymphadenopathies with-

out lung involvement. He was not known to have silica exposure. The relationship between silica exposure and the development of autoimmune disease such as RA has been reported, and pathological findings of silica-infiltrated lymph nodes correspond to granuloma-like structures<sup>16</sup>. Microscopic crystalline particulates have been identified from lung biopsy specimens in a patient with RA who had diffuse reticulonodular infiltrate while receiving etaner-

Table 2. Cases of subcutaneous and pulmonary nodulosis in patients receiving anti-TNF- $\alpha$  agents.

Report	Location of Nodules	Age, Sex	Anti-TNF- $\alpha$ and delay	Associated Treatment	Preexisting Nodules	Clinical Symptoms	Biopsy	Treatment	Outcome
Mackley <sup>2</sup>	SC	—	IFX (1 yr)	—	No	Nodules of hands	RN	ND	ND
Cunnane <sup>3</sup>	SC	52 M	ETA (2 mo)	CS	SC	Development of new cutaneous nodules	No	Maintenance of ETA	No progression of nodules
	SC	50 M	(3 mo)	CS	SC	Development of new cutaneous nodules	No	Maintenance of ETA	Resolution of pulmonary nodules
	Lungs	67 M	(2 mo)	CS	Pulmonary nodule	Dyspnea: cavitating pulmonary nodules	RN	ETA discontinued	
Scivo <sup>8</sup>	SC	45 F	ADA (2 yrs)	CS	No	Nodules of elbows	No	Maintenance of ADA	No progression of nodules
Kekow <sup>9</sup>	SC and lungs	53 F	ETA (7 mo)	CS	No	Nodules of hands and elbows; nodular lesion on chest radiograph	RN	ETA discontinued	Diminished size of nodules
Hübscher <sup>10</sup>	SC and lung	41 F	ETA ( yr)	LEF + CS	SC	Development of new cutaneous nodules and appearance of nodular lung lesion	RN	ETA discontinued	ND
Van Ede <sup>11</sup>	Lungs	50 M	ETA (2 yrs)	LEF	SC	Nodular lesions on chest radiograph	RN	ETA discontinued	Resolution of cutaneous and pulmonary nodules
Watson <sup>12</sup>	Lungs	57 F	ETA (1 yr)	LEF + CS	No	Dry cough	No	ETA maintained	No progression of nodules

SC: subcutaneous; CS: corticosteroids; LEF: leflunomide; MTX: methotrexate; RN: rheumatoid nodule; ND: not determined.

cept<sup>13</sup>. In this case, transbronchial lung biopsy showed non-caseating granuloma, and it is thought that these particulates may favor inflammatory reaction. The addition of anti-TNF- $\alpha$  treatment in this situation may interfere with this reaction, and one may hypothesize that blocking TNF- $\alpha$  may be a predisposing factor for the development of this granulomatous reaction (resulting in pulmonary infiltrate or adenopathies).

The mechanisms that may explain nodular lung lesions under anti-TNF- $\alpha$  are unclear. Pulmonary rheumatoid nodules were mainly observed with etanercept, but not exclusively (5 cases per 5 in the literature but only one case per 4 in our series). It is known that rheumatoid nodules are characterized by low levels of apoptosis, and etanercept does not induce apoptosis compared to the anti-TNF- $\alpha$  monoclonal antibodies. Thus, the different immunological properties of etanercept may account in part for the differences in incidence of pulmonary nodulosis<sup>17</sup>. Alternatively, vasculitis is involved in rheumatoid nodule formation and anti-TNF- $\alpha$  agents may paradoxically induce vasculitis<sup>18,19</sup>. Anti-TNF- $\alpha$  agents reduce cell trafficking to inflamed joints, and it has been suggested that they may favor the cellular infiltration of other inflamed tissue such as rheumatoid nodules<sup>3</sup>. TNF- $\alpha$  concentrations are lower in the supernatants of rheumatoid nodule cultures and the administration of TNF- $\alpha$ -blocking agents may have fewer effects on rheumatoid nodules compared to the inflamed synovium.

Interestingly, cases of pulmonary sarcoidosis were described in patients receiving anti-TNF- $\alpha$  agents<sup>20</sup>. The

cases of pulmonary aseptic and noncaseating granulomatous inflammation described previously had features similar to sarcoidosis and were exclusively observed during etanercept therapy (10 cases per 10 in the literature and 4 in 4 in our series). The mechanisms that have been proposed to explain such reactions (sarcoidosis and sarcoidosis-like diseases) resemble those leading to rheumatoid nodules, i.e., distinctive immunological properties and differing modes of action of etanercept and the anti-TNF- $\alpha$  monoclonal antibodies (including binding avidity, clearance, binding to membrane TNF- $\alpha$ , and binding to lymphotoxin- $\alpha$ )<sup>4,13,14,15,20</sup>. In addition, variation in cytokine concentrations during anti-TNF- $\alpha$  treatment may also play a role: indeed, anti-TNF- $\alpha$  monoclonal antibodies inhibit interferon- $\gamma$  (IFN- $\gamma$ ) expression, in contrast to etanercept, and IFN- $\gamma$  contributes to granuloma formation<sup>17</sup>. TNF- $\alpha$  inhibits transforming growth factor- $\beta$ , which is known to downregulate granuloma formation in conditions such as sarcoidosis<sup>21</sup>. Of interest, the pulmonary nodular lesions in our series occurred while patients were improved by the anti-TNF- $\alpha$  treatment, suggesting a different mechanism of action for the 2 manifestations.

Accelerated cutaneous or pulmonary nodulosis is a well recognized complication of methotrexate and leflunomide<sup>11</sup>. In our series, 8 patients had leflunomide (n = 5) or methotrexate (n = 3) as associated therapy. However, these DMARD had been taken for many years, and it was thus unlikely that they could be related to the lung injury.

Pulmonary nodulosis and aseptic granulomatous lung disease are rare during anti-TNF- $\alpha$  therapy. The exact inci-

dence of this side effect is difficult to estimate but is probably around 0.042%, since 26,000 patients are currently receiving TNF- $\alpha$ -blocking agents in France (11 cases/26,000). However, our study has limitations deriving from the observational design and some cases would certainly have been missed, or not declared, or alternatively not diagnosed in the case of asymptomatic patients.

We conclude that aseptic and inflammatory pulmonary nodules may appear in patients receiving anti-TNF- $\alpha$  agents, and that they correspond to rheumatoid nodules or granulomatous inflammation. These lesions are mainly observed during etanercept therapy, particularly in cases of granulomatous inflammatory disease. The mechanism explaining such a reaction is not clear, but certainly includes several different processes. These cases of inflammatory pulmonary nodules generally have a benign course and do not systematically require withdrawal of treatment. Since the differential diagnosis of such pulmonary lesions includes a large spectrum of diseases, mainly infections and malignancies, it is essential for clinicians to be aware that a pulmonary rheumatoid or granulomatous inflammatory nodule may develop during anti-TNF- $\alpha$  therapy.

#### ACKNOWLEDGMENT

The authors are indebted to Frances Sheppard (CIC-Biotherapy 506, Besançon, France) for help in preparing the manuscript.

#### REFERENCES

1. Kaiser MJ, Bozonnet MC, Jorgensen C, Daurès JP, Sany J. Effect of etanercept on tenosynovitis and nodules in rheumatoid arthritis. *Arthritis Rheum* 2002;46:559-60.
2. Mackley CL, Ostrov BE, Ioffreda MD. Accelerated cutaneous nodulosis during infliximab therapy in a patient with rheumatoid arthritis. *J Clin Rheumatol* 2004;10:336-8.
3. Cunnane G, Warnock M, Fye KH, Daikh DI. Accelerated nodulosis and vasculitis following etanercept therapy for rheumatoid arthritis. *Arthritis Rheum* 2002;47:445-9.
4. Ogenovski VM, Clark Ojo T, Fox DA. Etanercept-associated pulmonary granulomatous inflammation in patients with rheumatoid arthritis. *J Rheumatol* 2008;35:2279-82.
5. Ziff M. The rheumatoid nodule. *Arthritis Rheum* 1990;33:761-7.
6. Boros DL. Granulomatous inflammations. *Prog Allergy* 1978;24:183-267.
7. Wikaningrum R, Highton J, Parker A, Coleman M, Hessian PA, Roberts-Thompson PJ, et al. Pathogenic mechanisms in the rheumatoid nodule: comparison of proinflammatory cytokine production and cell adhesion molecule expression in rheumatoid nodules and synovial membranes from the same patient. *Arthritis Rheum* 1998;41:1783-97.
8. Scrivo R, Sparado A, Iagnocco A, Valesini G. Appearance of rheumatoid nodules following anti-tumor necrosis factor treatment with adalimumab for rheumatoid arthritis. *Clin Exp Rheumatol* 2007;25:117.
9. Kekow J, Welte T, Kellner U, Pap T. Development of rheumatoid nodules during anti-tumor necrosis factor with etanercept. *Arthritis Rheum* 2002;46:843-4.
10. Hubscher O, Re R, Iotti R. Pulmonary rheumatoid nodules in an etanercept-treated patient. *Arthritis Rheum* 2003;48:2077-8.
11. Van Ede AE, Den Broeder AA, Wagenaar M, Van Riel PLCM, Creemers MCW. Etanercept-related extensive pulmonary nodulosis in a patient with rheumatoid arthritis. *J Rheumatol* 2007;34:1590-2.
12. Watson P, Simler N, Sceaton N, Lillicrap M. Management of accelerated pulmonary nodulosis following etanercept therapy in a patient with rheumatoid arthritis. *Rheumatology* 2008;47:928-9.
13. Peno-Green L, Lluberas G, Kingsley T, Brantley S. Lung injury linked to etanercept therapy. *Chest* 2002;122:1858-60.
14. Yousem SA, Dacic S. Pulmonary lymphohistiocytic reactions temporally related to etanercept therapy. *Modern Pathol* 2005;18:651-5.
15. Kudrin A, Chilvers ER, Ginawi A, Hazleman BL, Griffiths MH, Thiru S, et al. Sarcoid-like granulomatous disease following etanercept treatment for rheumatoid arthritis. *J Rheumatol* 2007;34:648-50.
16. Calvert GM, Rice FL, Boiano JM, Sheehy JW, Sanderson WT. Occupational silica exposure and risk of various diseases: an analysis using death certificates from 27 states of the United States. *Occup Environ Med* 2003;60:122-9.
17. Furst DE, Wallis R, Broder M, Beenhouwer DO. Tumor necrosis factor antagonists: different kinetics and/or mechanisms of action may explain differences in the risk for developing granulomatous infection. *Semin Arthritis Rheum* 2006;36:159-67.
18. De Bandt M, Saint-Marcoux B. Tumor necrosis factor alpha blockade and the risk of vasculitis. *Ann Rheum Dis* 2006;65:1534-5.
19. Ramos-Casals M, Brito-Zeron P, Soto MJ, Cuadrado MJ, Khamashta MA. Autoimmune diseases induced by TNF-targeted therapies. *Best Pract Res Clin Rheumatol* 2008;22:847-61.
20. Toussirot E, Pertuiset E, Wendling D. Sarcoidosis occurring during anti-TNF treatment for inflammatory rheumatic diseases: report of two cases. *Clin Exp Rheumatol* 2008;26:471-5.
21. Verrecchia F, Pessah M, Atfi A, Mauviel A. Tumor necrosis factor alpha inhibits transforming growth factor beta/Smad signaling in human dermal fibroblast via AP-1 activation. *J Biol Chem* 2000;275:30226-31.