

# Effect of Blockade of Tumor Necrosis Factor- $\alpha$ with Etanercept on Surgical Wound Healing in SWISS-OF1 Mice

ESTIBALIZ IGLESIAS, FRANCISCO O'VALLE, JUAN SALVATIERRA, JOSE ANEIROS-FERNÁNDEZ, JESUS CANTERO-HINOJOSA, and PEDRO HERNÁNDEZ-CORTÉS

**ABSTRACT.** *Objective.* To assess whether blockade of tumor necrosis factor- $\alpha$  (TNF- $\alpha$ ) influences surgical wound healing in a normal mouse experimental model.

*Methods.* Wound healing time course and degree of surgical wound collagenization were measured by morphological techniques and digital image analysis in 80 male SWISS-OF1 mice (40 received subcutaneous etanercept at a dose of 0.1 mg/25g/ at -7, 0, 7, and 14 days).

*Results.* No significant differences were observed between treated and untreated animals in wound healing, re-epithelialization, or formation of inflammatory infiltrate or granulation tissue at days 7, 15, or 20 after surgery. At 20 days, the collagen area was larger in treated versus untreated mice ( $109029 \pm 28489 \mu\text{m}^2$  vs  $79305 \pm 19798 \mu\text{m}^2$ ,  $p = 0.026$ , Mann-Whitney U test).

*Conclusion.* Surgical wounds showed a higher degree of collagenization at 20 days in etanercept-treated versus untreated mice, with no differences in the time course of wound healing. These data suggest that biological therapies to block TNF- $\alpha$  do not affect wound healing and do not need to be suspended during the perioperative period. (J Rheumatol First Release Sept 1 2009; doi:10.3899/jrheum.081285)

*Key Indexing Terms:*

TUMOR NECROSIS FACTOR

ETANERCEPT

WOUND HEALING

Tumor necrosis factor- $\alpha$  (TNF- $\alpha$ ) is a pivotal proinflammatory cytokine in rheumatoid arthritis (RA). Over the past decade, biological therapies against this cytokine have proven highly effective to treat patients with rheumatoid arthritis (RA) or other autoimmune diseases<sup>1,2</sup>. Various cytokines, including TNF- $\alpha$  and interleukin 1, participate in the wound-healing response to surgical incisions<sup>3</sup>. For this reason, anti-TNF- $\alpha$  treatment is usually suspended perioperatively to avoid possible cicatrization complications<sup>4,5</sup>. However, this practice is not supported by any clinical studies, and very little experimental research has been published on TNF- $\alpha$ -induced changes in wound-healing<sup>6,7</sup>.

We used digital microscopic image analysis to determine whether exposure to etanercept affects the time course of wound healing and formation of collagen in a murine experimental model.

---

From the Departments of Orthopaedic Surgery, Rheumatology, and Pathology, University Hospital of Granada, and University of Granada, Spain.

E. Iglesias, MD, PhD, Department of Rheumatology; F. O'Valle, MD, PhD, Department of Pathology; J. Salvatierra, MD, PhD; J. Aneiros-Fernández, MD; J. Cantero-Hinojosa, MD, PhD, Department of Rheumatology; P. Hernández-Cortés, MD, PhD, Department of Orthopaedic Surgery.

Address correspondence to Dr. Hernández-Cortés, Department of Orthopaedic Surgery, University San Cecilio Hospital of Granada, Av Madrid s/n 18012, Granada, Spain. E-mail: hdezcp@hotmail.com  
Accepted for publication May 27, 2009.

## MATERIALS AND METHODS

*Experimental study in mice.* Eighty male 35–40 g SWISS-OF1 mice kept in individual cages with food and drink *ad libitum* were randomly divided between a group treated with 0.1 mg/25 g of subcutaneous etanercept (Enbrel® Wyeth Europe Ltd.) on days 1, 2, 7, and 14 (N = 40) and a control group (N = 40). On day 0, all mice were anesthetized intraperitoneally, their backs were shaved, and a 5 × 5 mm incision was performed, withdrawing cutaneous and subcutaneous cell tissue. The study complied with current European legislation on research ethics and was approved by the ethical commission for animal research of our institution.

*Measurement of wound-healing and collagen areas.* Photographs of the wound were taken on days 0, 7, 15, and 20 using a Sony Cyber-Shot DSC-P120 digital camera at a constant distance and under identical conditions (Figure 1). The wound-healing area was measured from these photographs using the AutoCad2005® program (Tronix SRL). Wound-healing areas in each mouse were recorded as percentages of the area on day 0. Morphological changes in the widest section of the wound were semiquantitatively evaluated using hematoxylin and eosin and Masson trichrome methods. Re-epithelialization was scored on a 3-point scale: 0 = no epithelial lining, 1 = partial epithelial lining, and 2 = complete re-epithelialization. The thickness of the epithelial lining was measured (in microns) on light microscopy images (20×) using the AutoCad2005® program. A millimeter scale in the eyepiece of a BH2 microscope (Olympus Optical Company, Ltd., Tokyo, Japan) with 40× objective was used to count fibroblasts, granulocytes, and mononuclear cells per mm<sup>2</sup>. Results were expressed as cells/mm<sup>2</sup>. Connective tissue formation was evaluated by dyeing wound-tissue samples with Syrius red. The degree of collagenization of wound tissue and healthy tissue at the wound margin was measured from 5 images of each area taken with a video camera (20× objective) connected to an optic microscope, using the HR® fibrosis analysis program<sup>8</sup> for automatic measurement of connective tissue.

*Statistical analysis.* Values are expressed as mean  $\pm$  standard deviation (SD). Comparisons were evaluated with the Mann-Whitney U test and the Fischer

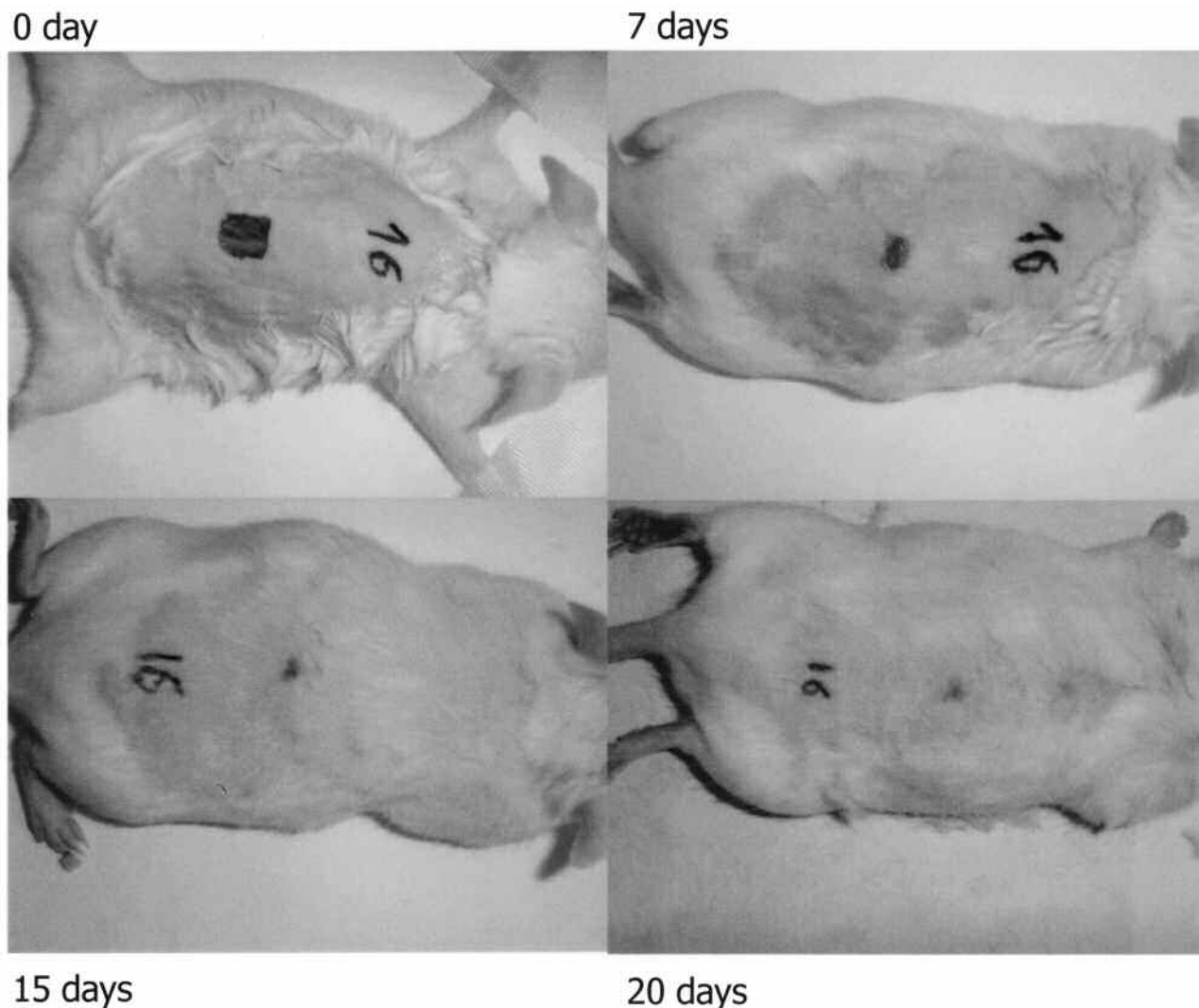


Figure 1. TNF- $\alpha$  blockade did not modify the time course of surgical wound healing in SWISS-OF1 mice. A marked reduction in area can be observed on day 20 with respect to day 0.

test. SPSS 15.0 for Windows (SPSS Inc, Chicago, IL, USA was used for the statistical analyses, considering  $p < 0.05$  to be significant.

## RESULTS

Table 1 shows the time course of surgical wound healing (percentage of wound-healing area with respect to area on day 0) and the collagenization of wound and healthy tissue. No significant differences in wound healing time course or morphological changes (Figure 2) were observed between treated and untreated animals on days 7, 15, or 20. The mean collagen area was significantly larger in treated than in untreated mice ( $109029 \pm 28489 \mu\text{m}^2$  vs  $79305 \pm 19798 \mu\text{m}^2$ ,  $p = 0.026$  Mann-Whitney U test, Figure 3), with no significant differences in collagenization of the healthy margin of the wound.

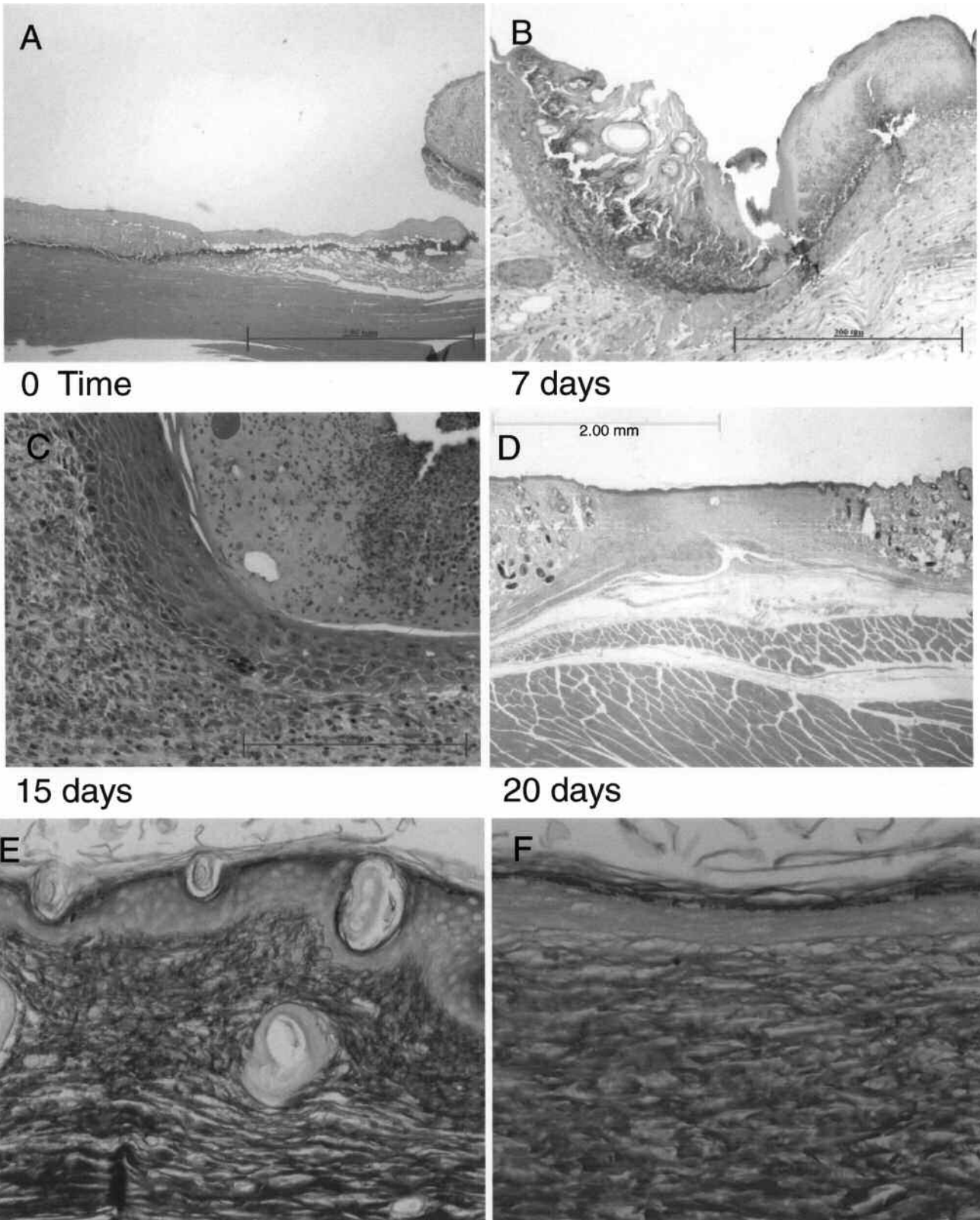
Table 2 shows the mean number of fibroblasts, polymorphonuclear leukocyte cells, and mononuclear cells present and the re-epithelialization rate for each group of animals and each measurement time point. No statistically significant differ-

Table 1. Mean percentage surgical wound reduction and mean collagen area in wound and healthy tissue from etanercept (ET)-treated and untreated mice.

	Day 7	Day 15	Day 20
Reduction in wound area vs day 0, %			
ET-treated	9.78 $\pm$ 38.78	82.28 $\pm$ 9.06	80.10 $\pm$ 7.35
Untreated	11.08 $\pm$ 28.45	72.23 $\pm$ 24.93	81.87 $\pm$ 6.87
Collagen area of wound tissue, $\mu\text{m}^2$			
ET-treated			109029.1 $\pm$ 28489.9*
Untreated			79305.9 $\pm$ 19798.2*
Collagen area of healthy tissue, $\mu\text{m}^2$			
ET-treated			97620.9 $\pm$ 28195.2
Untreated			97731.5 $\pm$ 20622.8

\* Significant difference vs untreated mice,  $p = 0.026$  (Mann-Whitney U test).

ences were found between groups or time points. Inflammatory cell counts were higher in non-treated animals, but statistical significance was not reached.



*Figure 2.* Progression of wound in a treated SWISS-OF1 TNF- $\alpha$  mouse. A. Base and margin of the wound at time zero. B. Wound surface with inflammation and granulation tissue. C. Re-epithelialization. D. Wound healing with deposit of connective tissue (original hematoxylin-eosin, original magnification A, D, 4 $\times$ ; B, 10 $\times$ ; C, 20 $\times$ ). E. Connective tissue in dermis of SWISS-OF1 control mouse and (F) showing slight increase in SWISS-OF1 TNF- $\alpha$ -treated mouse at 20 days (Syrius red, original magnification 20 $\times$ ).

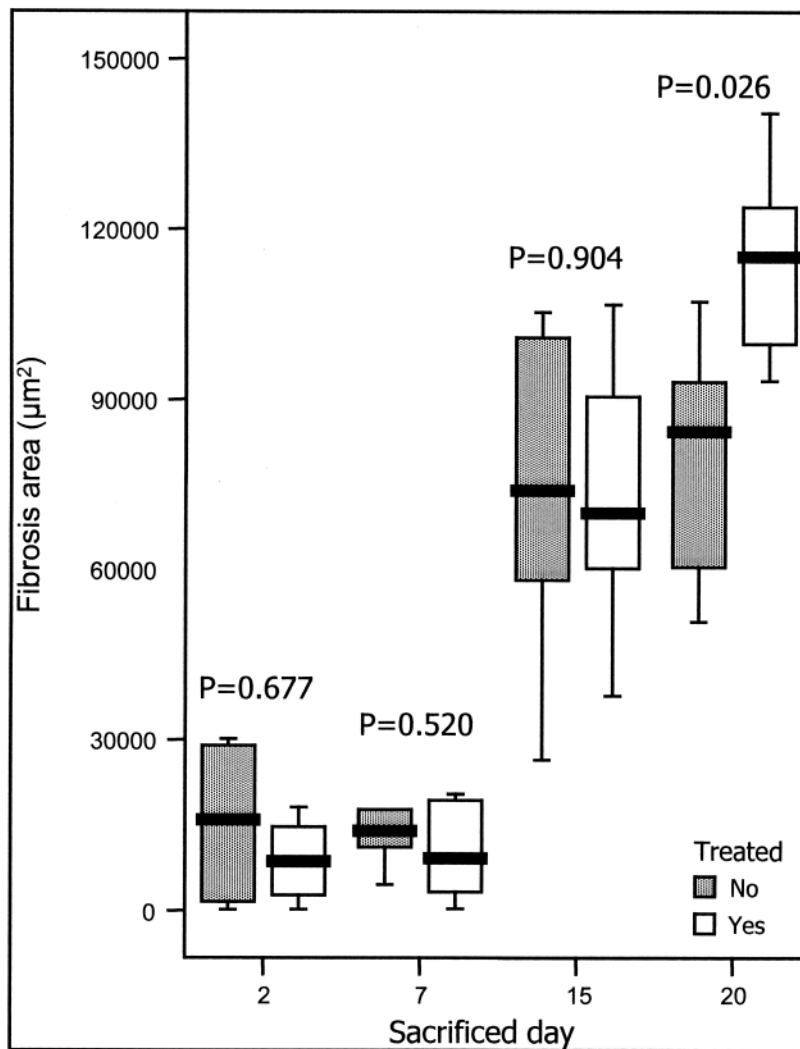


Figure 3. The mean collagen area at different time points in treated and untreated mice.

## DISCUSSION

TNF- $\alpha$  blockade did not modify the time course of surgical wound healing in SWISS-OF1 mice, but blockade increased collagenization of the wound at 20 days after incision, with no change in collagenization of healthy areas. We can find no published experimental study on the effects of TNF- $\alpha$  blockade on the time course of wound healing and collagenization in healthy mice. Digital microscopic image analysis was used in the histopathological study of the wounds. This method offers highly precise and reproducible detection of differences in the degree of wound collagenization, since it is an automatic procedure in which the only intervention of the researcher is to select the areas for analysis. The surgical wound area was measured at baseline and on days 7, 15, and 20, selected to represent 3 phases of cicatrization: hemostasis/inflammation, proliferation, maturation/remodeling.

During wound repair, TNF- $\alpha$  overexpression is involved in

neutrophil and monocyte chemotaxis, angiogenesis, fibroplasias, and metalloproteinase synthesis to destroy damaged extracellular matrix. Mori, *et al*<sup>6</sup> found a higher amount of estimated neutrophils on day 1 and higher monocyte infiltrate on day 6 after TNF- $\alpha$  administration in surgically-wounded mice with p55 receptor than in p55-receptor knockout mice, demonstrating the role of TNF- $\alpha$  as neutrophil and monocyte chemoattractant in the wound-healing process. Although no statistical differences were found, our observation of a greater inflammatory response (granulocytes and mononuclear cells per mm<sup>2</sup>) in non-treated animals, especially on days 7 and 15, is compatible with the role of TNF- $\alpha$  described by Mori, *et al*.

We found no differences between treated and untreated mice in the percentage reduction in wound healing area on day 7. Mori, *et al*<sup>6</sup> found a greater reduction in wound area in the knockout mice from day 3, suggesting an acceleration of cicatrization in the absence of TNF- $\alpha$ . We found no differences in the reduction of wound-healing area between treated and



**Table 2.** Quantification of the number of fibroblasts and inflammatory cells and the re-epithelialization rate in wound tissue from etanercept (ET)-treated and untreated mice. Values are expressed as means  $\pm$  standard deviation.

	Day 7	Day 15	Day 20
Fibroblasts, mm <sup>2</sup>			
ET-treated	840.50 $\pm$ 145.7	1014.51 $\pm$ 169.2	1248.38 $\pm$ 221.2*
Untreated	831.54 $\pm$ 182.2	904.83 $\pm$ 125.1	1363.7 $\pm$ 275.7
Monocytes, mm <sup>2</sup>			
ET-treated	422.58 $\pm$ 108.8	280.54 $\pm$ 54.7	222.22 $\pm$ 37.1*
Untreated	833.32 $\pm$ 157.5	448.38 $\pm$ 107.8	326.16 $\pm$ 105.9
Granulocytes, mm <sup>2</sup>			
ET-treated	1191.93 $\pm$ 471	238.71 $\pm$ 91.1	53.76 $\pm$ 17.2*
Untreated	2051.97 $\pm$ 1369	479.03 $\pm$ 243.4	60.93 $\pm$ 26.4
Re-epithelialization rate, %			
ET-treated	10	90	100**
Untreated	10	90	100
Epithelial thickness, $\mu$ m			
ET-treated	0.537 $\pm$ 0.146	0.479 $\pm$ 0.235	0.309 $\pm$ 0.167*
Untreated	0.575 $\pm$ 0.183	0.436 $\pm$ 0.161	0.237 $\pm$ 0.086

\* No significant difference vs untreated mice at any time (Mann-Whitney U test). \*\* No significant difference vs untreated mice at any time (Fisher test).

untreated animals on any day. These discrepancies are likely due to the difference in experimental models.

TNF- $\alpha$  appears to contribute to the formation of a collagen matrix of thicker fibers arranged parallel to stress lines<sup>2</sup>. However, we detected greater wound collagenization in the TNF- $\alpha$ -blocked mice, with no differences in healthy wound margins. Experimental studies of septic rats and diabetic mice with TNF- $\alpha$  overexpression<sup>7,9</sup> concluded that an excess of TNF- $\alpha$  inhibits cicatrization. Although our mice were healthy, the TNF- $\alpha$  blockade may have had a selective fibrogenetic role in areas with overexpression, as after a surgical incision. The higher degree of collagenization in our treated mice might also have resulted from an imbalance between TNF- $\alpha$  and tumor growth factor  $\beta$ , an antiinflammatory cytokine with fibroplastic effects<sup>10</sup>. This theory would explain the absence of significant differences in fibroblast count between treated and non-treated animals at any time point. Our histological findings do not demonstrate the known effect of TNF- $\alpha$  as inhibitor of fibroblast proliferation and promoter of fibroblast apoptosis.

In conclusion, this experimental study demonstrates greater collagenization of surgical wounds in mice treated with etanercept, with no differences in the time course of wound healing between treated and untreated mice. These data suggest that biological therapies to block TNF- $\alpha$  can be maintained during the perioperative period without increasing the risk of wound-healing complications.

#### ACKNOWLEDGMENT

The authors gratefully acknowledge the contribution of technicians María Dolores Rodríguez, Department of Pathology, and Serafín Vélez García and Carmen Ruiz Guzman, Department of Surgery, of Granada University.

#### REFERENCES

1. Furst DE, Breedveld FC, Kalden JR, Smolen JS, Burmester GR, Bijlsma JW, et al. Updated consensus statement on biological agents, specifically tumor necrosis factor alpha (TNF- $\alpha$ ) blocking agents and interleukin-1 receptor antagonist (IL-1 ra), for the treatment of rheumatic diseases, 2005. *Ann Rheum Dis* 2005;64 Suppl:iv2-iv14.
2. Broughton G, Manis JE, Attinger CE. The basic science of wound healing. *Plast Reconstr Surg* 2006;117 Suppl:12S-34S.
3. Finckh A, Huang J, Liang MH. Are there differences in the ability of infliximab and etanercept to prevent structural joint damage in rheumatoid arthritis? An interim analysis from a population cohort [abstract]. *Arthritis Rheum* 2003;48 Suppl:S333.
4. Busti AJ, Hooper JS, Amaya CJ, Kazi S. Effects of perioperative antiinflammatory and immunomodulating therapy on surgical wound healing. *Pharmacotherapy* 2005;25:1566-91.
5. Rosandich PA, Kelley JT, Conn DL. Perioperative management of patients with rheumatoid arthritis in the era of biologic response modifiers. *Curr Opin Rheumatol* 2004;16:192-8.
6. Mori R, Kondo T, Ohshima T, Ishida Y, Mukaida N. Accelerated wound healing in tumor necrosis factor receptor p55-deficient mice with reduced leukocyte infiltration. *FASEB J* 2002;16:963-74.
7. Maish GO 3rd, Shumate ML, Ehrlich HP, Cooney RN. Tumor necrosis factor binding protein improves incisional wound healing in sepsis. *J Surg Res* 1998;78:108-17.
8. Masseroli M, O'Valle F, Andújar M, Ramírez C, Gómez-Morales M, de Dios Luna J, et al. Design and validation of a new image analysis method for automatic quantification of interstitial fibrosis and glomerular morphometry. *Lab Invest* 1998;78:511-22.
9. Liu R, Bal HS, Desta T, Behl Y, Graves DT. Tumor necrosis factor-alpha mediates diabetes-enhanced apoptosis of matrix-producing cells and impairs diabetic healing. *Am J Pathol* 2006;168:757-64.
10. Jones CL, Fecondo J, Kelynack K, Forbes J, Walker R, Becker G. Tissue inhibitor of the metalloproteinases and renal extracellular matrix accumulation. *Exp Nephrol* 1995;3:80-6.