

Autologous Hematopoietic Stem Cell Transplant in Systemic Sclerosis: Quantitative High Resolution Computed Tomography of the Chest Scoring

DAVID LAUNAY, ZORA MARJANOVIC, CEDRIC de BAZELAIRE, LAURA FLOREA, SARAH ZOHAR, HOMAH KESHTMAND, CHRISTOPHE DELIGNY, AXELLE de RAIGNIAC, ATHOL U. WELLS, and DOMINIQUE FARGE

ABSTRACT. Objective. Using high resolution computed tomography (HRCT), to assess the lung involvement outcome after autologous hematopoietic stem cell transplant (AHSCT) in patients with scleroderma (systemic sclerosis, SSc).

Methods. HCRT scans prospectively performed before (n = 9 patients) and after (n = 47) AHSCT were blindly reviewed by 2 independent investigators using the Wells score.

Results. After a median 60 months' followup, the overall disease extent score from HCRT scans decreased from 10 (0–45) to 4 (0–36) (p = 0.04) 6 months after AHSCT, and thereafter increased up to 36 months and stabilized; the modified Rodnan skin score fell (p < 0.05).

Conclusion. The extent of SSc lung involvement on HRCT rapidly but transiently regressed after AHSCT. (J Rheumatol First Release June 15 2009; doi:10.3899/jrheum.081212)

Key Indexing Terms:

SYSTEMIC SCLEROSIS AUTOLOGOUS HEMATOPOIETIC STEM CELL TRANSPLANT
LUNG INVOLVEMENT FIBROSING ALVEOLITIS
HIGH RESOLUTION COMPUTED TOMOGRAPHY CHEST SCAN

Pulmonary fibrosis (PF) occurring in 50% to 80% of patients with systemic sclerosis (SSc) is their leading cause of death¹⁻³. In this context, cyclophosphamide (CYC) was shown to significantly improve patient's functional status, skin score, and, albeit modestly, lung function⁴. In the past 10 years, several phase I-II studies⁵⁻⁸ used high doses of CYC followed by autologous hematopoietic peripheral stem cell transplant (AHSCT)⁶. The studies showed complete or

partial remission with stable vital capacity (VC) and diffusing capacity for carbon monoxide (DLCO) on lung function tests up to 5 years after AHSCT in two-thirds of the patients treated for severe diffuse SSc. High resolution computed tomography (HRCT) of the chest is the most sensitive and reproducible method to analyze PF associated with SSc (PF-SSc)^{1,3}, but presently no data are available on HRCT after AHSCT. We designed this study with a special focus on HRCT analysis of PF-SSc in a subgroup of patients included in a single-institution pilot study as reported⁵ for whom longterm followup evaluation was available after AHSCT.

MATERIALS AND METHODS

Fifty-six HCRT scans (using sequential acquisition of 1-mm scans, spaced at 10 mm, intervals extending from the lung apices to below the costophrenic angles) were prospectively performed in 9 patients with SSc fulfilling the American College of Rheumatology preliminary diagnosis criteria, before (n = 9) and after (n = 47) AHSCT. All patients with diffuse cutaneous and severe SSc plus early visceral involvement treated by AHSCT as published⁵ and with at least 1 year followup after AHSCT were analyzed. Before AHSCT and quarterly thereafter, repeated evaluations during followup included: (1) skin involvement using the modified Rodnan skin score (mRSS); (2) lung function and involvement using the New York Heart Association (NYHA) functional class, pulmonary function tests, and HRCT scans.

Two independent investigators (CDB and DL) blindly and randomly reviewed each HRCT using the Wells score¹. HRCT were reviewed at 5 levels¹. To quantify the extent and the severity of CT patterns at each level, we analyzed (A) the disease extent of interstitial lung involvement, including both reticular pattern and ground-glass opacification, and (B) the coarseness of fibrosis as follows: 0, ground-glass opacification alone; 1, fine intralobular fibrosis; 2, microcystic reticular pattern comprising air

From Service de Médecine Interne, Hôpital Claude-Huriez, Université Lille 2, Lille; Service d'Hématologie, Hôpital Hôtel-Dieu, APHP; Service de Radiologie, Service de Médecine Interne et Pathologie Vasculaire, and Département de Biostatistique et Informatique Médicale, Hôpital Saint-Louis, APHP, Paris; Service de Médecine Interne, CHU, Fort-de-France, France; Interstitial Lung Disease Unit, Royal Brompton Hospital, London, UK; and Unité INSERM U976 France, Hôpital Saint-Louis, Paris, France.

D. Launay, MD, Service de Médecine Interne, Hôpital Claude-Huriez, Université Lille 2; Z. Marjanovic, MD, Service d'Hématologie, Hôpital Hôtel-Dieu, APHP; C. de Bazelaire, MD, Service de Radiologie, Hôpital Saint-Louis, APHP; L. Florea, MD, Service de Médecine Interne et Pathologie Vasculaire, Hôpital Saint-Louis, APHP; S. Zohar, MD, Département de Biostatistique et Informatique Médicale, Hôpital Saint-Louis, APHP; H. Keshtmand, MD, Service de Médecine Interne et Pathologie Vasculaire, Hôpital Saint-Louis, APHP; C. Deligny, MD, Service de Médecine Interne, CHU; A. de Raigniac, MD, Service de Médecine Interne et Pathologie Vasculaire, Hôpital Saint-Louis, APHP; A.U. Wells, MD, Interstitial Lung Disease Unit, Royal Brompton Hospital; D. Farge, MD, PhD, Service de Médecine Interne et Pathologie Vasculaire, and Unité INSERM U976 France, Hôpital Saint-Louis.

Address reprint requests to Dr. D. Farge, Service de médecine interne et pathologie vasculaire, Hôpital Saint-Louis, INSERM U976, 1 avenue Claude-Vellefaux, 75010 Paris, France.

E-mail: dominique.farge-bancel@sls.ap-hop-paris.fr

Accepted for publication February 11, 2009.

spaces ≤ 4 mm in diameter; and 3, a macrocystic reticular pattern comprising air spaces > 4 mm in diameter. This analysis allowed us to compute the overall (1) mean value of disease extent by averaging the measures obtained at each level; (2) proportion of ground-glass opacification; and (3) coarseness score for each patient, derived by summing the coarseness scores (0–3) at 5 levels (minimum score, 0; maximum score, 15). Then, on the whole HRCT, the overall grade of interstitial lung disease was evaluated according to the Wells score¹.

Statistical analysis. Categorical variables were summarized as counts and percentage, while numerical variables were summarized as median and full range. Groups were compared using Fisher's exact test for the categorical variables and nonparametric paired signed-rank test for numerical variables.

RESULTS

The baseline characteristics of the patients, aged 41 years (range 16–61), with clinical, functional, and HRCT development before and after AHSCT are given in Tables 1 and 2. All but 2 patients had chest skin involvement at baseline. During the 60 months (range 18–24) of followup after AHSCT, 1 death from disease progression including skin and lung progression occurred at 18 months and another from relapse after prior major response⁵, with septic shock originating from skin lesions at 24 months. Neither was treatment-related. A continuous and significant decrease in mRSS ($p < 0.05$) was observed. NYHA functional status remained stable with most patients sustained in class I/II. VC tended to be higher 24 months after than before AHSCT [83% (62–111%) vs 72% (37–108%), respectively; $p = 0.078$]. The same comparison including only the 7 patients alive at 60 months yielded similar results (data not shown). HRCT pattern analysis showed a significant fall in the mean overall disease extent 6 months after AHSCT [4 (0–36) vs 10 (0–45); $p = 0.04$], with further increase up to 36 months and stabilization thereafter (Figure 1). Notably, at 6 months compared to baseline, the overall disease improved in 5 and remained stable in 1 out of the 6 patients with baseline PF-SSc, while it remained stable in the 3 others. To further confirm that disease extent improved at 6 months and worsened at 1 year, it was recoded as: 1 if lowered, 2 if stable, and 3 if increased when compared to previous CT scan. Using the nonparametric paired signed-rank test, difference was significant between 6 months and 1 year ($p = 0.03$), confirming that disease extent improved at 6 months and worsened thereafter. Figure 1 shows individual development of the overall disease extent score. The overall coarseness remained stable and the overall proportion of ground-glass opacification decreased after AHSCT, but not significantly.

DISCUSSION

Reports from several European⁵⁻⁷ and North American⁸ studies have shown promising results in patients with severe diffuse SSc treated by AHSCT with significant, rapid, and durable fall in skin score, improved functional status, and stable lung function. However, none has yet analyzed the progression of HRCT pattern outcome after AHSCT using a validated methodology¹.

Table 1. Baseline clinical and serologic characteristics of the patients with SSc ($n = 9$) treated by autologous hematopoietic stem cell transplant according to the ISAMAIR protocol⁵ and followed at least 1 year after transplant with repeated CT scans.

Characteristic	Median (range)
Sex, F/M	6/3
Age, yrs	41 (16–61)
Disease duration*, yrs	9 (2–12)
Race, n	
Caucasian	6/9
Asian	1/9
Black/French West Indies	2/9
Antitopoisomerase antibody positivity, n	7/9
Anticentromere antibody positivity, n	0/9
Ever smoked cigarettes, n	1/9
Performance status	1.5 (0–4)
Organ involvement	0/9
Skin	
mRSS	36 (9–51)
Lung	
Chest radiograph	6/9
HRCT	6/9
VC $< 70\%$ predicted	4/9
DLCO $< 70\%$ predicted	9/9
PAH	0/9
Systolic PAP (mm Hg)	33 (27–40)
Cardiovascular symptoms	
Raynaud's phenomenon	9/9
Arterial hypertension	0/9
LVEF (%)	63 (57–70)
Kidney**	0/9
Creatinine ($\mu\text{mol/l}$)	66 (32–80)
Digestive tract involvement***	3/9
Muscle involvement	0/9

* Time elapsed between first non-Raynaud's phenomenon and autologous hematopoietic stem cell transplant. ** 24-h urinary protein > 0.5 g or serum creatinine $> 120 \mu\text{mol/l}$. *** Serum albumin < 25 g/l or weight loss $> 10\%$ body weight in the preceding year. mRSS: modified Rodnan skin score; HRCT: high resolution computed tomography of the chest; VC: slow inspiratory vital capacity; DLCO: diffusing capacity for carbon monoxide; PAH: pulmonary arterial hypertension as defined by systolic pulmonary arterial hypertension (PAP) > 40 mm Hg; LVEF: left ventricle ejection fraction as measured by cardiac echography or multiple gated acquisition CT scan.

The main finding of our pilot study of a small number of highly selected patients was to document a significant and rapid fall in the overall extent of PF-SSc on HRCT 6 months after AHSCT using the Wells score¹. Five of the 6 patients with evidence of PF-SSc before AHSCT experienced improvement of PF-SSc on HRCT as soon as 6 months after AHSCT. Moreover, 4 of these 6 patients had high grade 2 or 3 lesions on HRCT. Such results are important since, to our knowledge, no other study has shown the same rapid response in such a proportion of patients with severe SSc after 6 months of CYC therapy^{9,10}. All these data support the observation that AHSCT that includes high dose of CYC can rapidly reverse ground-glass opacification and decrease the extent of PF-SSc on CT scan even in SSc patients with

Table 2. Outcome of clinical characteristics, pulmonary function tests, and CT scan patterns after autologous hematopoietic stem cell transplant. Results are given as median (range).

Clinical Characteristics	Baseline	6 Months	1 Year	2 Years	3 Years	4 Years	5 Years
No. of patients	9	9	9	8	7	7	7
NYHA class of dyspnea I/II/III/IV	3/4/2/0	4/4/0/1	5/3/1/0	4/4/0/0	5/2/0/0	3/4/0/0	5/2/0/0
Respiration rate at rest	14 (14–20)	14 (12–24)	14 (12–15)	12 (12–25)	16 (12–16)	16 (14–18)	16 (16–20)
mRSS	36 (9–51)*	24 (4–37)*	25 (3–44)*	11 (0–48)*	11 (3–43)*	6 (2–35)*	6 (3–23)*
SHAQ	2.12 (0–2.7)	0.87 (0–2.12)	1 (0–3.25)	0.37 (0–2.3)	0.62 (0–2.1)	0.75 (0–2.2)	1 (0–2.25)
Pulmonary function tests, % predicted							
VC	72 (37–108)	74 (32–114)	76 (58–113)	83 (62–111) [†]	74 (58–112)	68 (44–115)	60 (34–122)
TLC	82 (42–114)	80 (43–100)	74 (63–109)	86 (76–118)	77 (67–115)	75 (64–116)	73 (54–114)
FEV1	69 (44–112)	83 (38–122)	83 (61–128)	79 (67–113)	78 (54–115)	73 (50–114)	67 (42–121)
DLCO	46 (28–61)	51 (12–76)	42 (36–53)	44 (38–74)	40 (31–60)	41 (33–85)	40 (16–74)
KCO	61 (36–86)	56 (16–80)	47 (32–74)	60 (56–84)	68 (53–71)	62 (52–84)	54 (31–78)
FEF75	86 (63–123)	93 (63–139)	93 (59–139)	104 (86–28)	99 (61–117)	86 (52–122)	72 (48–128)
FEF50	79 (52–182)	98 (69–131)	95 (73–141)	90 (76–139)	96 (78–119)	80 (52–126)	87 (48–119)
FEF25	82 (40–134)	113 (64–197)	82 (54–146)	78 (32–143)	76 (53–99)	68 (28–97)	70 (47–113)
Overall CT scan patterns							
Disease extent	10 (0–45)	4 (0–36)*	6 (0–39)	12 (0–32.5)	16 (1–38.8)	13 (1–32.5)	15 (1–33)
Ground-glass opacification, %	50 (12–90)	30.5 (0–90)	42 (0–67)	37 (0–60)	20 (0–45)	17 (0–50)	20 (3–55)
Coarseness score	8.1 (4–15)	10 (5–15)	8.3 (3.3–15)	10 (5–15)	10 (5–15)	10 (5–15)	10 (5–15)
Grade 1/2/3, n	2/2/2	1/2/3	1/5/2	0/5/2	0/3/4	0/4/3	0/3/4
Improvement/stability/worsening on serial HRCT	—	5/4/0	1/3/5	2/2/4	2/2/3	4/2/1	2/2/3

NYHA: New York Heart Association; mRSS: modified Rodnan skin score; SHAQ: Self Health Assessment Questionnaire; VC: slow inspiratory vital capacity; TLC: total lung capacity; DLCO: diffusing capacity for carbon monoxide; KCO: DLCO adjusted for alveolar volume; FEV1: forced expiratory volume in 1 second; FEF: forced expiratory flow rate; PF-SSc: fibrosing alveolitis (pulmonary function) associated with systemic sclerosis. * $p < 0.05$ compared to baseline. [†] $p < 0.1$ compared to baseline.

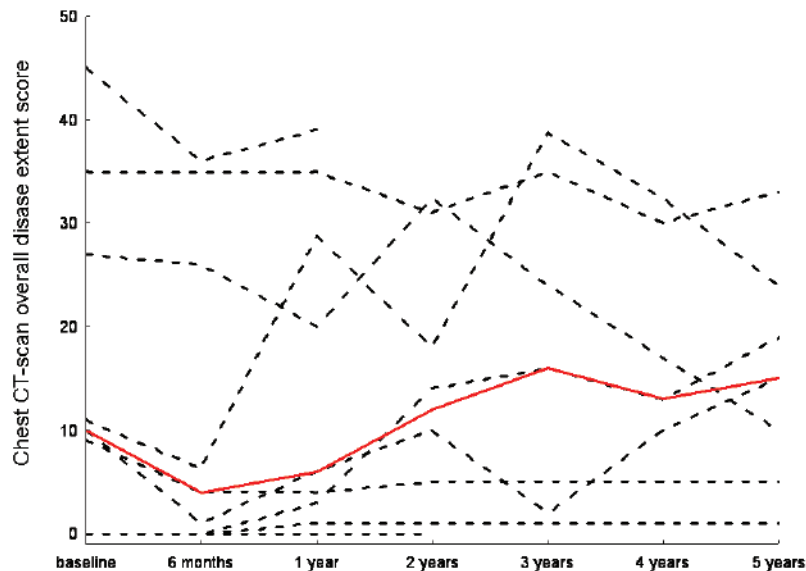


Figure 1. Progression of the individual overall disease extent scores on HRCT scans of the chest. Red line represents the median value.

severe disease. It is interesting that after an initial improvement, the overall extent of disease on serial HRCT increased again in some patients and was back to the pre-transplant extent 24 months after AHST, and then was relatively stable up to 60 months of followup. These results may illustrate

the attenuation with time of the effect of CYC¹¹ and a new increase in PF-SSc contrasted with a persistently improved skin score. Our study provides no new insight into this unexpected finding. Indeed, there is a possible uncoupling between skin and lung involvement in SSc, as patients with

limited cutaneous SSc can have severe interstitial lung disease. Moreover, in the Scleroderma Lung Study, there was also a relapse in interstitial lung disease after 18 months, whereas the skin score stabilized¹¹.

Our study confirmed that AHSCT induced a rapid and significant regression of skin fibrosis, as assessed by mRSS. It showed rather stable lung function after AHSCT and even pointed out a trend towards improved lung volumes at 24 months. The stability of lung volumes and of DLCO after AHSCT has to be seen as a good result in these patients with severe diffuse SSc. Indeed, Wells, *et al* recently pointed out that the attainment of complete stability in PF-SSc with treatment should not be underestimated¹².

A significant and rapid decrease of the extent of PF-SSc was observed on HRCT scans in patients treated for severe diffuse SSc 6 months after AHSCT. Longer-term followup showed that the impressive early treatment effects of AHSCT on the extent of PF-SSc decreased over time and were transient in some patients, which again raised questions about the need for maintenance immunosuppression after AHSCT. These results will have to be confirmed in larger numbers of patients, as intended in the ongoing European (ASTIS; www.astis-trial.com) and North American (SCOT; www.sclerodermatrial.org) studies comparing AHSCT to monthly intravenous CYC therapy.

REFERENCES

1. Desai SR, Veeraraghavan S, Hansell DM, et al. CT features of lung disease in patients with systemic sclerosis: comparison with idiopathic pulmonary fibrosis and nonspecific interstitial pneumonia. *Radiology* 2004;232:560-7.
2. Steen VD, Medsger TA. Changes in causes of death in systemic sclerosis, 1972-2002. *Ann Rheum Dis* 2007;66:940-4.
3. Goh N, Desai SR, Veeraraghavan S, et al. Interstitial lung disease in systemic sclerosis: a simple staging system. *Am J Respir Crit Care Med* 2008;177:1248-54.
4. Tashkin DP, Elashoff R, Clements PJ, et al. Cyclophosphamide versus placebo in scleroderma lung disease. *N Engl J Med* 2006;354:2655-66.
5. Farge D, Marolleau JP, Zohar S, et al. Autologous bone marrow transplantation in the treatment of refractory systemic sclerosis: early results from a French multicentre phase I-II study. *Br J Haematol* 2002;119:726-39.
6. Vonk MC, Marjanovic Z, van den Hoogen FH, et al. Long-term follow-up results after autologous haematopoietic stem cell transplantation for severe systemic sclerosis. *Ann Rheum Dis* 2008;67:98-104.
7. Farge D, Passweg J, van Laar JM, et al. Autologous stem cell transplantation in the treatment of systemic sclerosis: report from the EBMT/EULAR Registry. *Ann Rheum Dis* 2004;63:974-81.
8. Nash RA, McSweeney PA, Crofford LJ, et al. High-dose immunosuppressive therapy and autologous hematopoietic cell transplantation for severe systemic sclerosis: long-term follow-up of the US multicenter pilot study. *Blood* 2007;110:1388-96.
9. Davas EM, Peppas C, Maragou M, Alvanou E, Hondros D, Dantis PC. Intravenous cyclophosphamide pulse therapy for the treatment of lung disease associated with scleroderma. *Clin Rheumatol* 1999;18:455-61.
10. Wells AU, Rubens MB, du Bois RM, Hansell DM. Serial CT in fibrosing alveolitis: prognostic significance of the initial pattern. *AJR Am J Roentgenol* 1993;161:1159-65.
11. Tashkin DP, Elashoff R, Clements PJ, et al. Effects of 1-year treatment with cyclophosphamide on outcomes at 2 years in scleroderma lung disease. *Am J Respir Crit Care Med* 2007;176:1026-34.
12. Wells AU, Latsi P, McCune WJ. Daily cyclophosphamide for scleroderma: are patients with the most to gain underrepresented in this trial? *Am J Respir Crit Care Med* 2007;176:952-3.