

# Abnormal Nailfold Capillaroscopy Is Common in Patients with Connective Tissue Disease and Associated with Abnormal Pulmonary Function Tests

Anniek M. van Roon, Cato C. Huisman, Arie M. van Roon, Dan Zhang, Alja J. Stel, Andries J. Smit, Hendrika Bootsma, and Douwe J. Mulder

**ABSTRACT. Objective.** To assess the presence of a systemic sclerosis (SSc) pattern on nailfold capillary microscopy (NCM) in patients with Raynaud phenomenon (RP) and to explore its association with abnormal pulmonary function tests (PFT).

**Methods.** NCM patterns were assessed in 759 consecutive patients with RP. Patterns were classified as normal (n = 354), nonspecific (n = 159), or SSc pattern (n = 246). Abnormal PFT was defined as forced vital or diffusion capacity < 70%. Patients were classified as primary RP (n = 245), or secondary: no definite diagnosis (n = 391), SSc (n = 40), primary Sjögren syndrome (pSS; n = 30), systemic lupus erythematosus (SLE; n = 30), mixed connective tissue disease (MCTD; n = 7), rheumatoid arthritis (RA; n = 15).

**Results.** An SSc pattern on NCM was frequently observed in most patients with a definite diagnosis: SSc (88%), pSS (33%), SLE (17%), MCTD (71%), and RA (13%). In patients without definite diagnosis, 17% had a normal NCM pattern, 35% nonspecific, and 48% SSc pattern. Abnormal PFT was more frequent in patients with an SSc pattern (35.9% vs 19.5%,  $p = 0.002$ ), even when corrected for SSc diagnosis ( $p = 0.003$ ). Absence of an SSc pattern had high negative predictive value (88%); positive predictive values were low.

**Conclusion.** SSc pattern on NCM is common in patients with RP, and in those with connective tissue diseases other than SSc. It is associated with a higher prevalence of abnormal PFT, independent of the presence of an SSc diagnosis. Although these data need validation in a prospective setting, they underline the importance of NCM in RP and putative value to stratify the risk of pulmonary involvement in early stages of disease. (First Release December 15 2018; J Rheumatol 2019; 46:1109–16; doi:10.3899/jrheum.180615)

## Key Indexing Terms:

RAYNAUD PHENOMENON    MICROSCOPIC ANGIOSCOPY    SYSTEMIC SCLEROSIS  
CONNECTIVE TISSUE DISEASES    RESPIRATORY FUNCTION TESTS

From the Department of Internal Medicine, Division of Vascular Medicine, and the Department of Rheumatology and Clinical Immunology, University of Groningen, University Medical Center Groningen, Groningen; Department of Rheumatology, Medical Center Leeuwarden, Leeuwarden, the Netherlands.

A.M. van Roon, Department of Internal Medicine, Division of Vascular Medicine, University of Groningen, University Medical Center Groningen; C.C. Huisman, Department of Internal Medicine, Division of Vascular Medicine, University of Groningen, University Medical Center Groningen; A.M. van Roon, PhD, Department of Internal Medicine, Division of Vascular Medicine, University of Groningen, University Medical Center Groningen; D. Zhang, MD, Department of Rheumatology, Medical Center Leeuwarden; A.J. Stel, MD, PhD, Department of Rheumatology and Clinical Immunology, University of Groningen, University Medical Center Groningen; A.J. Smit, MD, PhD, Department of Internal Medicine, Division of Vascular Medicine, University of Groningen, University Medical Center Groningen; H. Bootsma, MD, PhD, Department of Rheumatology and Clinical Immunology, University of Groningen, University Medical Center Groningen; D.J. Mulder, MD, PhD, Department of Internal Medicine, Division of Vascular Medicine, University of Groningen, University Medical Center Groningen.

Address correspondence to A.M. van Roon, Department of Internal Medicine, Division of Vascular Medicine, University Medical Center Groningen, Huispostcode AA41, Hanzeplein 1, Postbus 30 001, Groningen, the Netherlands. E-mail: a.m.van.roon01@umcg.nl

Accepted for publication September 11, 2018.

Raynaud phenomenon (RP) can be primary (idiopathic), or secondary to an underlying connective tissue disease (CTD), most commonly systemic sclerosis (SSc). RP is the first presenting symptom in most patients with SSc; other symptoms can occur up to years later. In secondary RP (SRP), nailfold capillary changes can be seen with nailfold capillary microscopy (NCM). This can help to differentiate between primary RP (PRP) and SRP in an early stage of the disease. These typical NCM findings are included in the classification criteria for SSc<sup>1</sup>. Abnormal NCM has been shown to be associated with the presence and severity of internal organ involvement in SSc cohorts and has even been suggested to predict mortality<sup>2,3,4,5,6,7</sup>. A previous study shows an association between the presence of changes on NCM and the occurrence of cardiac/pulmonary involvement in patients with SSc, independent of specific antibodies<sup>8</sup>.

NCM might be a supportive tool in CTD other than SSc as well. However, in systemic lupus erythematosus (SLE), primary Sjögren syndrome (pSS), mixed CTD (MCTD), and rheumatoid arthritis (RA), NCM patterns and their value for

these patients have been less well established. In small studies, NCM seems to be an indicator for organ involvement in MCTD<sup>9,10,11,12</sup>. A recent review shows an association between abnormal NCM findings in SLE and disease activity<sup>13</sup>. About 10% of patients with pSS have SSc-like abnormalities on NCM<sup>14,15</sup>. Twenty-one percent of the patients with RA had SSc-like NCM abnormalities, although it is unknown how many of these patients experienced RP symptoms<sup>16</sup>. Both in pSS and RA, the association of NCM with any organ involvement is unknown. In all these CTD, pulmonary involvement can occur. Interstitial lung disease (ILD) is the most common type of pulmonary involvement in SSc, pSS, MCTD, and RA<sup>17,18</sup>. This makes it important to find accurate biomarkers to detect this in an early stage. Assessment of NCM may facilitate awareness and early recognition of (SSc-like) pulmonary involvement.

Our aim was to describe the presence of SSc patterns on NCM in a large cohort of consecutive patients with RP visiting the vascular laboratory for NCM in our tertiary referral center, and to explore whether a possible association exists between NCM patterns and abnormal pulmonary function tests (PFT).

## MATERIALS AND METHODS

Consecutive patients with bi- or triphasic discoloration and/or discomfort of the hands provoked by cold were included. They were referred to the vascular laboratory for NCM (n = 961). All were examined for suspected RP by (vascular) internists and/or rheumatologists and underwent routine daily practice examination, as described below. Patients visited the vascular laboratory between November 2008 and August 2013. NCM was performed by a standardized procedure, as described below. Clinical characteristics were collected between 2014 and 2016, two years or more following presentation. A different diagnosis, causing the discoloration or discomfort symptoms of the hands, was reported by the treating physician in 177 patients after the diagnostic examination; these patients were excluded. Twenty-five patients were excluded because capillaries were not assessable in any finger owing to physical limitations (4 of these patients were diagnosed with SSc). In 759 patients RP was diagnosed, based on discoloration with at least 2 phases (white, blue, and/or red) provoked by cold, or in case of diagnostic uncertainty RP was confirmed by a cooling procedure as described previously<sup>19</sup>. The study was approved by the local ethics committee (Medisch Ethische Toetsingscommissie Groningen, the Netherlands; approval number METc 2016.305) and they provided exemption from written informed consent, given that the study does not fall under the Dutch law of medical research in humans.

**NCM.** NCM was carried out by widefield videocapillaroscopy with a 180× enlargement, as described previously<sup>19,20</sup>. In short, NCM was performed at our vascular laboratory as a standardized procedure assessing the distal row of capillaries of the middle and ring finger (digits 3 and 4) of both hands. Figure 1 illustrates how NCM images were taken and assessed.

Capillary loss was defined as < 18 capillaries per 3-mm nailfold per finger; severe capillary loss was defined as < 9 capillaries per 3 mm, in line with definitions of Cutolo, *et al*<sup>21</sup>. Giant capillaries and dilated capillaries were judged visually by the observer as typical SSc-like enlarged loops, as seen in Figure 1. The patterns, based on the patterns by Cutolo, *et al*, were defined as follows: a normal pattern meant no capillary loss, the mean number of dilated capillaries per finger was ≤ 3 and no giant capillaries were observed; a nonspecific pattern as a mean number of > 3 dilated capillaries or capillary loss in the absence of giant capillaries; an early pattern as ≥ 1 giant capillaries, without loss of capillaries or hemorrhages; an active pattern

as ≥ 1 giant capillaries combined with capillary loss and/or hemorrhages; and a late pattern as severe loss of capillaries with none or few giant capillaries and none or few hemorrhages and signs of neovascularization<sup>22</sup>.

**Clinical and laboratory characteristics.** Antinuclear antibodies (ANA), tested by indirect immunofluorescence, were measured. When they were present, they were classified as speckled, homogeneous, anticentromere, or nucleolar. Also, extractable nuclear antigen (ENA) antibodies were tested by fluorescent enzyme immunoassay and specifically for U1-RNP, RNP70, Sm, SSA, SSB, Jo1, topoisomerase (Scl-70), and centromere proteins-B. Serology was defined positive for ANA titer ≥ 1:80 and ENA antibodies ≥ 10 U/ml. Anticentromere and Scl-70 are defined as SSc-specific autoantibodies<sup>1</sup>.

Patients were classified as PRP if NCM was normal and serology was negative, and no CTD was diagnosed during followup. If serology was not tested, it was presumed normal for the purpose of patient classification in our study (n = 37). When not primary, patients were labeled SRP. Those patients were divided into groups with a definite diagnosis: SSc, pSS, SLE, MCTD, or RA according to the classification criteria<sup>1,23,24,25,26</sup>. Patients who did not meet any of the criteria were classified as having no definite diagnosis. Patients without a definite diagnosis were subdivided into early SSc, based on the LeRoy criteria; incomplete pSS (ipSS), when patients had 3 out of 4 American-European Consensus Group criteria for pSS; incomplete SLE (iSLE), when patients had 2 or 3 out of 4 Systemic Lupus International Collaborating Clinics criteria for SLE; undifferentiated CTD (UCTD), according to the proposed classification criteria of Mosca, *et al*; and “other” when not meeting any of these criteria<sup>23,24,27,28</sup>. Patients in the group “other” are patients who have a nonspecific pattern on NCM but do not have any signs for a specific underlying disease. Because of the presence of a nonspecific pattern on NCM, these patients cannot be definitely classified as PRP, as was previously reported by Bernero, *et al*, who demonstrated that 18% of the patients with nonspecific changes on NCM progressed to an SSc pattern within the next 5 years<sup>29</sup>. None were diagnosed with polymyositis or dermatomyositis. Figure 2 gives a schematic representation of the patient diagnosis classification.

**Pulmonary involvement.** Potential pulmonary involvement was adjudicated using supplemental studies of PFT. These studies were performed in daily routine investigations of patients when deemed necessary by the treating physician based on clinical judgment or routine examination.

An abnormal PFT was defined as the DLCO (uncorrected for alveolar volume) and/or forced vital capacity (FVC) < 70%. If deemed necessary by the treating physician, high-resolution computed tomography (HRCT) and/or cardiac ultrasound were performed as additional tests. Definite pulmonary involvement was defined as an ILD, diagnosed by HRCT and judged by an experienced HRCT radiologist, or documented pulmonary hypertension (PH) by mean pulmonary arterial pressure ≥ 25 mmHg at rest measured by right heart catheterization<sup>30,31</sup>.

**Statistics.** Statistical analysis was carried out using IBM SPSS Statistics version 23. Data are described as mean ± SD, median (interquartile range) or number (percentage). Differences between groups were tested by t test for normally distributed continuous data, Mann-Whitney U test for other continuous data, or chi-square or Fisher's exact test for binomial values. Binary logistic regression was conducted with DLCO and/or FVC < 70% as dependent variable and corrected for confounders (such as age, sex, height, and weight) and presence of SSc diagnosis. Values of p < 0.05 were considered statistically significant. Positive and negative predictive value (PPV and NPV) were calculated.

## RESULTS

The total population of patients included in the analysis was 759. In Figure 2, a flowchart of patient classification is given, demonstrating 245 (32%) patients with PRP, and 514 (68%) SRP, of which 122 (24%) had a definite diagnosis, and 392 (76%) did not. All 40 patients with SSc had limited cutaneous

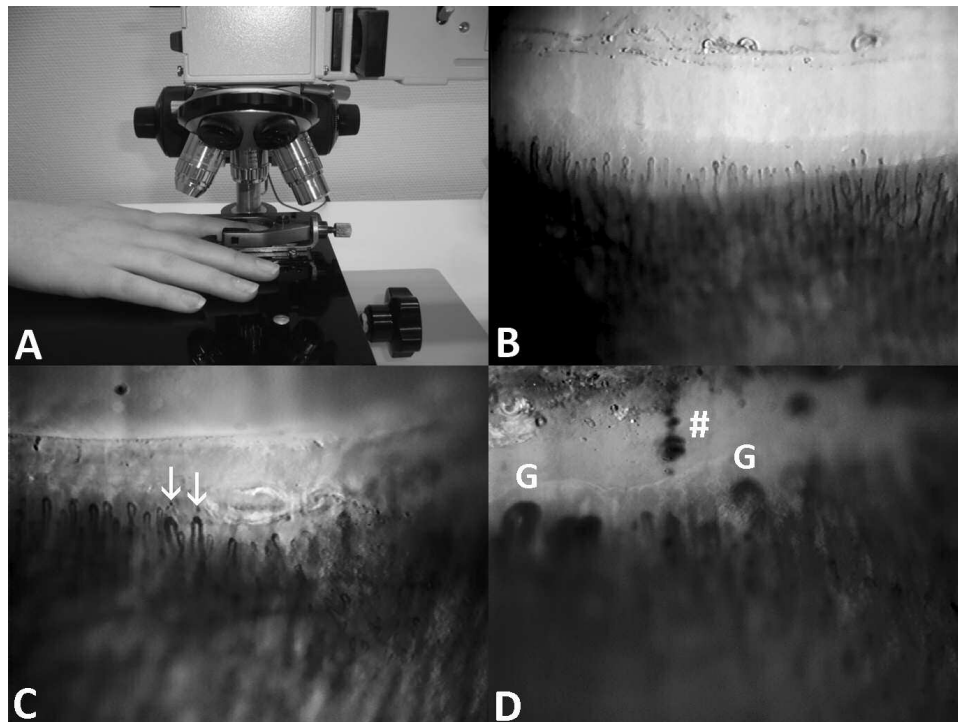


Figure 1. A. How nailfold capillary microscopy was performed with an Olympus BHMJ FW-32362 device, with a Grundig FA-85 Z/W video camera (Fürth/Bay) and an Osram XBO 75W xenon lamp with 180× enlargement and a 3-mm width. B. A normal pattern. C. A nonspecific pattern. Arrows indicate dilated capillaries. D. An active pattern. #: hemorrhage; G: giant capillaries.

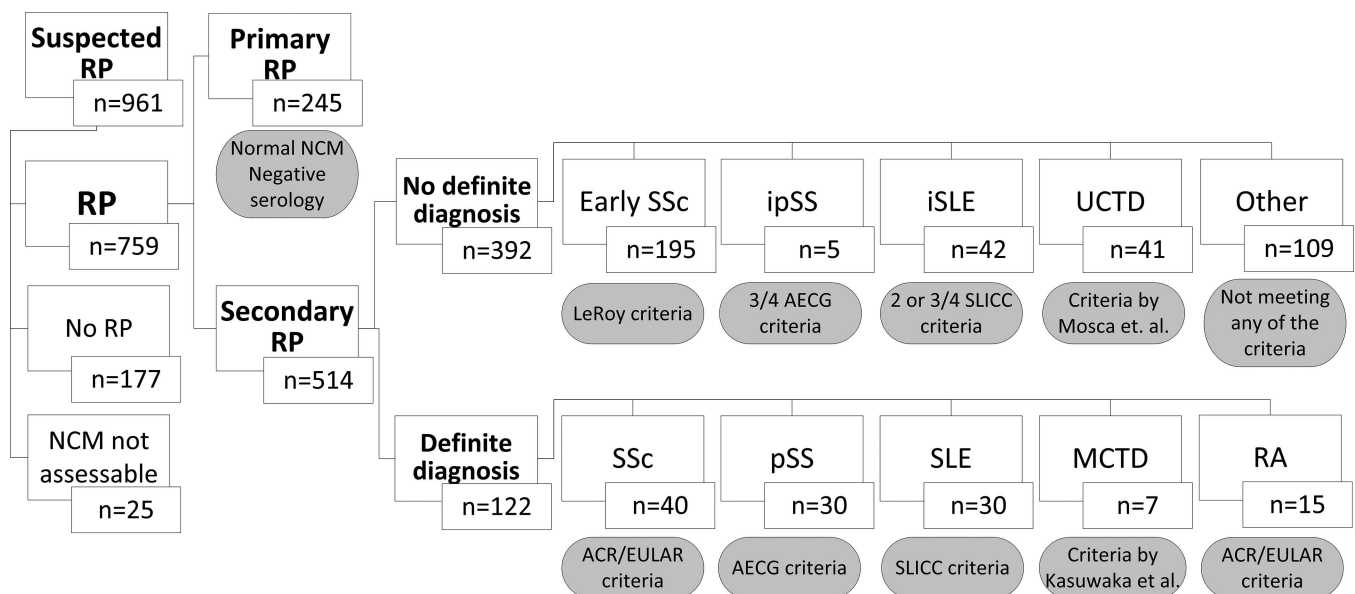


Figure 2. Flowchart of patient diagnosis classification. RP: Raynaud phenomenon; pSS: primary Sjögren syndrome; ipSS: incomplete pSS; SLE: systemic lupus erythematosus; iSLE: incomplete SLE; MCTD: mixed connective tissue disease; UCTD: undifferentiated CTD; NCM: nailfold capillary microscopy; RA: rheumatoid arthritis; SSc: systemic sclerosis; AECG: American-European Consensus Group; SLICC: Systemic Lupus International Collaborating Clinics; ACR: American College of Rheumatology; EULAR: European League Against Rheumatism.

SSc. Patient characteristics are given in Table 1. A normal NCM pattern was found in 354 (47%) patients, nonspecific in 159 (21%), SSc pattern in 246 (32%), including early in 139 (18%) and active in 107 (14%); a late pattern was not present in any of the patients. Patients with PRP and SRP did not differ in age ( $p = 0.862$ ); in the SRP group there were more women than in PRP ( $p = 0.006$ ). None of the patients had a history of SSc renal crisis or myositis.

**NCM pattern per patient diagnosis.** In Table 2, the NCM patterns and PFT are outlined per patient diagnosis. In SRP patients without a definite diagnosis, a specific SSc pattern was observed in 189 [48%; early 115 (29%), active 74 (19%); late not observed]. The percentage of a specific SSc pattern was similar in patients with a definite diagnosis, with a higher percentage of an active pattern.

As expected, an SSc pattern was observed in most patients with SSc (35; 88%) and in 189 (97%) patients with early SSc. Additionally, an SSc pattern was also observed in a considerable proportion of the other patients with a definite diagnosis: 10 (33%) of the patients with pSS, 5 (17%) SLE, 5 (71%) MCTD, and 2 (13%) RA. None of the ipSS and iSLE patients had an SSc pattern (Table 2). Patients with pSS and SLE who had an SSc pattern on NCM did not differ in their clinical characteristics from patients without an SSc pattern. For example, in patients with pSS, the NCM pattern did not differ between those with positive and negative anti-SSA/SSB antibodies or positive and negative salivary gland biopsy. They did not have other SSc-like symptoms, except 1 SLE patient who had puffy fingers. Further, the 5 SLE patients with glomerulonephritis did not have an SSc pattern. Hematological abnormalities (leukocytopenia, anemia, thrombocytopenia) and serositis were not associated with an SSc pattern. U1-RNP autoantibodies were also unrelated to any NCM pattern.

**Pulmonary involvement and NCM pattern.** The relation between NCM pattern and PFT is outlined in Figure 3. In 293 of all the RP patients, PFT were performed, of which 265 were classified as SRP. Patients with abnormal PFT were older ( $p < 0.001$ ) but did not differ in sex, height, or weight. When analyzing the patients with SRP, an abnormal PFT was more frequently observed in patients with an SSc pattern on NCM (Figure 3). When corrected for age and the presence of the diagnosis of SSc, this relation remained significant ( $p = 0.003$ ). An abnormal PFT was still more frequently observed in SRP patients with an SSc pattern on NCM, when analyzing only those patients in whom serology was performed ( $p = 0.007$ ). Pulmonary involvement is outlined per patient diagnosis in Table 2.

In addition to the NCM pattern, the presence of giant capillaries was more frequently observed in patients with abnormal PFT (Figure 3), also when corrected for SSc ( $p = 0.003$ ). No relation was found with capillary loss or dilated capillaries; thus a nonspecific pattern is therefore not related to an abnormal PFT.

A definite diagnosis of ILD was made in 17 patients, and 1 patient was diagnosed with PH. Of the patients with ILD, 8 were diagnosed with SSc, 1 SLE, 2 MCTD, 1 RA, 3 early SSc, and 2 iSLE. The patient with PH was diagnosed with pulmonary arterial hypertension (PAH) associated with SSc. In these 18 patients, an SSc pattern was prevalent [normal 4 (22%), nonspecific 2 (11%), early 5 (28%), active 7 (39%)].

In all patients with SRP, the NPV and PPV of positive serology were 82% and 35%, respectively, for predicting an abnormal PFT. The NPV and PPV of abnormal NCM for predicting abnormal PFT were 70% and 47%, respectively. When combining positive serology with abnormal NCM, the NPV and PPV increased to 88% and 46%, respectively. The NPV and PPV for abnormal PFT in the patients with SRP

Table 1. Patient characteristics.

Characteristics	All Patients		PRP		SRP	
N	759		245		514	
Age, yrs, mean $\pm$ SD	42.5	$\pm 17.4$	41.6	$\pm 17.9$	42.9	$\pm 17.1$
Female sex	555	(73)	167	(68)	388	(76)
Positive serology* (ANA titer $\geq 1:80$ )	254	(33)	0	(0)	256	(50)
SSc-specific autoantibodies <sup>#</sup>	44	(6)	0	(0)	44	(9)
Puffy fingers or sclerodactyly	43	(6)	0	(0)	43	(8)
Nailfold capillary microscopy*						
Normal	354	(47)	245	(100)	109	(21)
Nonspecific	159	(21)	0	(0)	159	(31)
Early	139	(18)	0	(0)	139	(27)
Active	107	(14)	0	(0)	107	(21)
Late	0	(0)	0	(0)	0	(0)
Pulmonary involvement						
Abnormal pulmonary function test	81	(11)	4	(2)	75	(15)
ILD	17	(2)	0	(0)	17	(3)
PAH	1	(0)	0	(0)	1	(0)

Values are n (%) unless otherwise specified. \* Used as criteria to classify as PRP or SRP. <sup>#</sup> Anticentromere and topoisomerase (Scl-70). ANA: antinuclear antibodies; ILD: interstitial lung disease; PAH: pulmonary arterial hypertension; RP: Raynaud phenomenon; PRP: primary RP; SRP: secondary RP.



Table 2. NCM and pulmonary function per patient diagnosis group.

N	Primary RP, n	Secondary RP									
	245	No definite diagnosis, n					Definite diagnosis, n				
		Early SSc 195	ipSS 5	iSLE 42	UCTD 41	Other 109	SSc 40	pSS 30	SLE 30	MCTD 7	RA 15
NCM patterns, n (%)											
Normal	245 (100)	4 (2)	4 (80)	31 (74)	27 (66)	0 (0)	3 (8)	11 (37)	16 (53)	2 (29)	11 (73)
Nonspecific	0 (0)	2 (1)	1 (20)	11 (26)	14 (34)	109 (100)	2 (5)	9 (30)	9 (30)	0 (0)	2 (13)
Early	0 (0)	115 (59)	0 (0)	0 (0)	0 (0)	0 (0)	12 (30)	7 (23)	2 (7)	2 (29)	1 (7)
Active	0 (0)	74 (38)	0 (0)	0 (0)	0 (0)	0 (0)	23 (56)	3 (10)	3 (10)	3 (43)	1 (7)
NCM specifics, median (IQR) or n (%)											
Capillaries per 3 mm per finger	23.3 (21.7–24.5)	21.0 (18.5–23.0)	23.5 (22.8–24.5)	22.8 (21.0–24.0)	23.1 (21.8–24.7)	22.7 (21.0–23.5)	18.5 (14.0–19.8)	23.3 (21.3–24.8)	21.5 (19.8–23.0)	20.3 (16.5–23.0)	23.5 (21.3–24.8)
No. patients with giants	0 (0)	188 (97)	0 (0)	0 (0)	0 (0)	0 (0)	35 (88)	10 (33)	5 (17)	5 (71)	2 (13)
No. patients with loss of capillaries	0 (0)	37 (19)	0 (0)	1 (2)	0 (0)	9 (8)	15 (40)	2 (7)	4 (14)	2 (29)	1 (7)
No. patients with hemorrhages	13 (5)	44 (23)	0 (0)	4 (10)	2 (5)	11 (10)	13 (32)	3 (10)	3 (10)	2 (29)	2 (13)
PFT, n (%)											
Abnormal PFT	4 (2)	29 (15)	0 (0)	6 (14)	3 (8)	3 (2)	18 (45)	4 (13)	7 (23)	3 (43)	2 (13)
DLCO < 70%	4 (2)	27 (14)	0 (0)	6 (14)	2 (5)	3 (2)	14 (35)	4 (13)	6 (20)	1 (14)	0 (0)
FVC < 70%	0 (0)	2 (1)	0 (0)	1 (2)	1 (3)	0 (0)	3 (8)	0 (0)	3 (10)	1 (14)	1 (7)

NCM: nailfold capillary microscopy; PFT: pulmonary function tests; SLE: systemic lupus erythematosus; iSLE: incomplete SLE; pSS: primary Sjögren syndrome; ipSS: incomplete pSS; MCTD: mixed connective tissue disease; UCTD: undifferentiated CTD; RA: rheumatoid arthritis; RP: Raynaud phenomenon; SSc: systemic sclerosis; IQR: interquartile range; FVC: forced vital capacity.

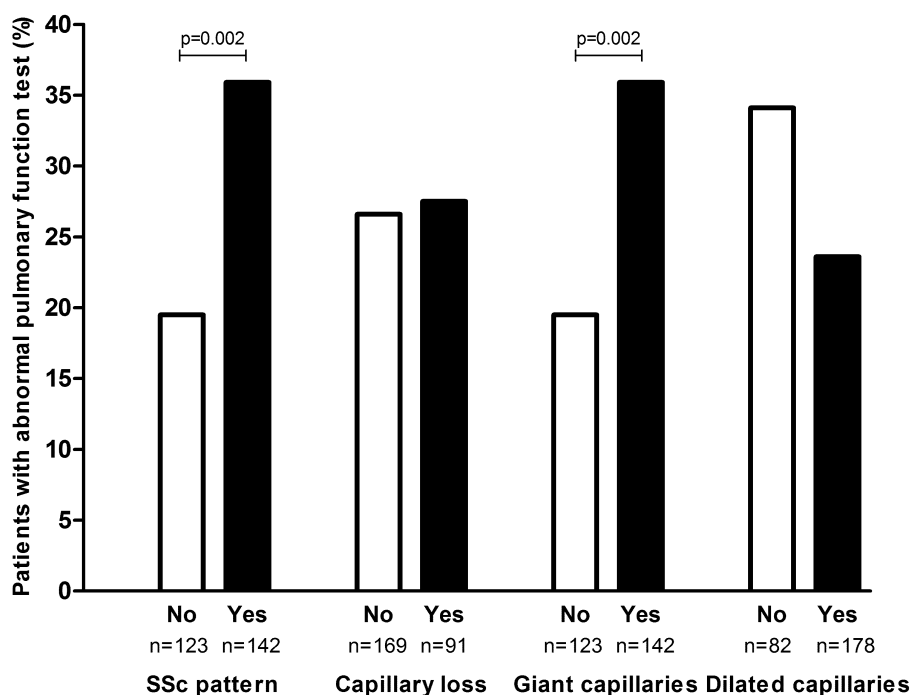


Figure 3. Abnormal pulmonary function test and nailfold capillaroscopy in patients with secondary Raynaud phenomenon. SSc: systemic sclerosis.

without a definite diagnosis (early SSc, iSLE, ipSS, UCTD, and “other”) for NCM only were 84% and 30%, respectively; for NCM and serology combined they were 92% and 41%, respectively.

## DISCUSSION

To our knowledge, this is the largest study in an academic referral center daily practice cohort, showing that SSc-like abnormalities on NCM are common in patients with SRP,

even in those without a definite CTD diagnosis. Moreover, we observed that a relationship existed between an SSc pattern on NCM and the presence of abnormal PFT, indicating potential pulmonary involvement, in unselected and consecutive patients with and without a CTD. This suggests that an SSc pattern is an important proxy for a first assessment of SSc-like pulmonary involvement in early stages of disease. Also, the high NPV of NCM combined with serology for PFT abnormalities in our cohort underlines the potential usefulness of NCM as a simple screening tool in all patients who present with RP in a referral care setting.

The percentages of patients with pSS, SLE, and MCTD in whom an SSc pattern was found on NCM were in line with previous findings<sup>9,10,11,12,14,32</sup>. Only for the patients with RA was the percentage of patients with an SSc pattern on NCM lower than expected<sup>16</sup>. In previous studies, the presence of SSc-like abnormalities on NCM in patients with SLE seems to be related to the presence of U1-RNP autoantibodies, suggesting an overlap syndrome with SSc<sup>33</sup>. Also, moderate/severe changes on NCM were more frequently observed in patients with pulmonary, cardiac, or renal involvement, even when no connection was found with any cutaneous manifestations<sup>34,35</sup>. In our cohort, there was only 1 SLE patient with an SSc pattern who presented with puffy fingers; there were no other with SSc symptoms. Additionally, we did not find a relationship between U1-RNP autoantibodies and an SSc pattern on NCM in patients with SLE as described<sup>33,35</sup>.

PFT are widely used to assess potential pulmonary involvement, because decreased DLCO and FVC have been shown to predict pulmonary involvement and are associated with the extension of ILD<sup>36,37,38,39</sup>. Markusse, *et al* found NCM to have NPV and PPV of 60% and 64%, respectively, for decreased DLCO (< 70%) in a group of patients with SSc<sup>8</sup>. In our patients with SRP, including SSc but other CTD as well, we found a somewhat higher NPV of 70% and a lower PPV of 47% for decreased DLCO and/or FVC (< 70%). The addition of FVC does not explain this difference, because only 5 patients in our study presented with decreased FVC without decreased DLCO, out of 81 with abnormal PFT. A possible explanation of the discrepancy with the results of Markusse, *et al* in NPV and PPV might be the difference in classification of an early pattern; we defined it as SSc pattern, while Markusse, *et al* chose to define it as normal because of low numbers<sup>8</sup>. Our study shows that when an early pattern on NCM is classified as normal, patients with pulmonary involvement might be missed. We found an association between SSc pattern and giant capillaries only on NCM with abnormal PFT, and could therefore not confirm the association between PFT and loss of capillaries as described by Castellví, *et al*, although their cohort consisted only of patients with SSc<sup>40</sup>. Further, our cohort consisted of patients mainly at an early stage of disease. None of these patients had a late pattern on NCM; therefore, there was little

variation in capillary count. This limited diversity in capillary loss might be why no association existed between capillary loss and PFT.

NCM is a method to assess microvasculopathy in patients and is thought to play an important role in the pathophysiology of SSc<sup>41</sup>. Microvasculopathy and fibrosis are both central features of SSc<sup>42</sup>. Although an abnormal NCM is clearly a representation of microvasculopathy, an abnormal PFT could be the expression of similar underlying pathology that cannot be readily visualized *in vivo*. Although preliminary, this could be an explanation of the association we found between an SSc pattern on NCM and abnormal PFT. This theory is strengthened by the study of Bredemeier, *et al*, where ground-glass opacities on HRCT in SSc patients were associated with avascular areas on NCM<sup>43</sup>. Also, the study by Smith, *et al* shows that NCM may predict novel future organ involvement in patients with SSc<sup>5</sup>. Further studies are needed, especially for other CTD.

Because this is a study with data collected from daily practice, the main limitation of our study is a relatively high percentage of missing data, especially in patients with mild disease or those deemed to have PRP. For example, the modified Rodnan skin score was not routinely performed at the time of patient recruitment and could therefore not be included in the analysis. Cardiac ultrasounds were not routinely performed; hence, subclinical cardiac involvement could not be assessed. Because the data were derived from daily practice, only 54 patients had an HRCT, of whom 18 patients had definite pulmonary involvement (ILD or PAH). This group was too small and biased to study the association between definite pulmonary involvement and NCM.

Further, abnormal PFT is not always a result of pulmonary involvement; smoking behavior and other lung diseases can decrease FVC and/or DLCO as well<sup>44</sup>. However, in our current study we were unable to take these variables into account because of the missing data. Nevertheless, because patients with a normal PFT are very unlikely to have pulmonary disease, the high NPV still is an accurate representation.

With the used NCM set-up, it was not possible to measure the exact width of the capillaries. Therefore, the definition of giant capillaries, because of the typical appearance, was more accurate than judging dilatation only. An early or active pattern was defined by the presence of only 1 giant capillary, which could possibly lead to an overestimation of abnormal NCM findings. Followup would be needed to verify this. Also, initial NCM is usually performed at an early stage of the disease when a late pattern is unlikely to be present. During the period of patient recruitment, it was customary at our hospital to assess only 4 fingers, instead of the more extensively used assessment of 8 fingers. Boulon, *et al* found that there was no difference in interobserver agreement between examining all fingers or only the left ring finger for establishing the NCM pattern<sup>45</sup>. Although the results do

suggest that the left ring finger gives the same results as all fingers in terms of pattern, it was not the main objective of the study. Because their method was not completely appropriate to draw this conclusion, it remains uncertain whether assessment of fewer than 8 fingers influences the outcome of the overall pattern classification.

An SSc pattern on NCM is common in patients with RP secondary to CTD, even in patients with CTD other than SSc. This shows that not only can patients with SSc develop this microvasculopathy, but other CTD patients with RP can as well. An SSc pattern on NCM appears to be associated with a higher prevalence of abnormal PFT, even corrected for the presence of an SSc diagnosis. We found that, with a high NPV, NCM when combined with serology can help to identify patients at low risk of having an abnormal PFT. These data underline the potential importance of assessing NCM, a cheap and noninvasive tool, in all patients with RP referred to secondary or tertiary care to evaluate the risk for pulmonary involvement in the early stages of the disease.

## REFERENCES

- van den Hoogen F, Khanna D, Fransen J, Johnson SR, Baron M, Tyndall A, et al. 2013 classification criteria for systemic sclerosis: an American College of Rheumatology/European League against Rheumatism collaborative initiative. *Arthritis Rheum* 2013; 65:2737-47.
- Arana-Ruiz JC, Silveira LH, Castillo-Martinez D, Amezcua-Guerra LM. Assessment of nailfold capillaries with a handheld dermatoscope may discriminate the extent of organ involvement in patients with systemic sclerosis. *Clin Rheumatol* 2016;35:479-82.
- De Santis M, Ceribelli A, Cavaciocchi F, Crotti C, Massarotti M, Belloli L, et al. Nailfold videocapillaroscopy and serum VEGF levels in scleroderma are associated with internal organ involvement. *Auto Immun Highlights* 2016;7:5.
- Cutolo M, Herrick AL, Distler O, Becker MO, Beltran E, Carpentier P, et al; CAP Study Investigators. Nailfold videocapillaroscopic features and other clinical risk factors for digital ulcers in systemic sclerosis: a multicenter, prospective cohort study. *Arthritis Rheumatol* 2016;68:2527-39.
- Smith V, Ricciari V, Pizzorni C, Decuman S, Deschepper E, Bonroy C, et al. Nailfold capillaroscopy for prediction of novel future severe organ involvement in systemic sclerosis. *J Rheumatol* 2013;40:2023-8.
- Kayser C, Sekiyama JY, Prospero LC, Camargo CZ, Andrade LE. Nailfold capillaroscopy abnormalities as predictors of mortality in patients with systemic sclerosis. *Clin Exp Rheumatol* 2013; 31:103-8.
- Hofstee HM, Vonk Noordegraaf A, Voskuyl AE, Dijkman BA, Postmus PE, Smulders YM, et al. Nailfold capillary density is associated with the presence and severity of pulmonary arterial hypertension in systemic sclerosis. *Ann Rheum Dis* 2009;68:191-5.
- Markus IM, Meijs J, de Boer B, Bakker JA, Schippers HP, Schouffoer AA, et al. Predicting cardiopulmonary involvement in patients with systemic sclerosis: complementary value of nailfold videocapillaroscopy patterns and disease-specific autoantibodies. *Rheumatology* 2017;56:1081-8.
- Maricq HR, LeRoy EC, D'Angelo WA, Medsger TA Jr, Rodnan GP, Sharp GC, et al. Diagnostic potential of in vivo capillary microscopy in scleroderma and related disorders. *Arthritis Rheum* 1980;23:183-9.
- Granier F, Vayssairat M, Priollet P, Housset E. Nailfold capillary microscopy in mixed connective tissue disease. Comparison with systemic sclerosis and systemic lupus erythematosus. *Arthritis Rheum* 1986;29:189-95.
- de Holanda Mafaldo Diogenes A, Bonfa E, Fuller R, Correia Caleiro MT. Capillaroscopy is a dynamic process in mixed connective tissue disease. *Lupus* 2007;16:254-8.
- Wu PC, Huang MN, Kuo YM, Hsieh SC, Yu CL. Clinical applicability of quantitative nailfold capillaroscopy in differential diagnosis of connective tissue diseases with Raynaud's phenomenon. *J Formos Med Assoc* 2013;112:482-8.
- Cutolo M, Melsens K, Wijnant S, Ingegnoli F, Thevissen K, De Keyser F, et al. Nailfold capillaroscopy in systemic lupus erythematosus: a systematic review and critical appraisal. *Autoimmun Rev* 2018;17:344-52.
- Corominas H, Ortiz-Santamaria V, Castellvi I, Moreno M, Morla R, Clavaguera T, et al; CapiCAT group. Nailfold capillaroscopic findings in primary Sjogren's syndrome with and without Raynaud's phenomenon and/or positive anti-SSA/Ro and anti-SSB/La antibodies. *Rheumatol Int* 2016;36:365-9.
- Capobianco KG, Xavier RM, Bredemeier M, Restelli VG, Brenol JC. Nailfold capillaroscopic findings in primary Sjogren's syndrome: clinical and serological correlations. *Clin Exp Rheumatol* 2005;23:789-94.
- Rajaei A, Dehghan P, Amiri A. Nailfold capillaroscopy in 430 patients with rheumatoid arthritis. *Caspian J Intern Med* 2017;8:269-74.
- Ruano CA, Lucas RN, Leal CI, Lourenco J, Pinheiro S, Fernandes O, et al. Thoracic manifestations of connective tissue diseases. *Curr Probl Diagn Radiol* 2015;44:47-59.
- Mira-Avendano IC, Abril A. Pulmonary manifestations of Sjogren syndrome, systemic lupus erythematosus, and mixed connective tissue disease. *Rheum Dis Clin North Am* 2015;41:263-77.
- van Roon AM, Smit AJ, van Roon AM, Bootsma H, Mulder DJ. Digital ischaemia during cooling is independently related to nailfold capillaroscopic pattern in patients with Raynaud's phenomenon. *Rheumatology* 2016;55:1083-90.
- Houtman PM, Kallenberg CG, Wouda AA, The TH. Decreased nailfold capillary density in Raynaud's phenomenon: a reflection of immunologically mediated local and systemic vascular disease? *Ann Rheum Dis* 1985;44:603-9.
- Cutolo M, Pizzorni C, Secchi ME, Sulli A. Capillaroscopy. *Best Pract Res Clin Rheumatol* 2008;22:1093-108.
- Cutolo M, Sulli A, Pizzorni C, Accardo S. Nailfold videocapillaroscopy assessment of microvascular damage in systemic sclerosis. *J Rheumatol* 2000;27:155-60.
- Vitali C, Bombardieri S, Jonsson R, Moutsopoulos HM, Alexander EL, Carsons SE, et al; European Study Group on Classification Criteria for Sjögren's Syndrome. Classification criteria for Sjögren's syndrome: a revised version of the European criteria proposed by the American-European Consensus Group. *Ann Rheum Dis* 2002;61:554-8.
- Petri M, Orbai AM, Alarcon GS, Gordon C, Merrill JT, Fortin PR, et al. Derivation and validation of the Systemic Lupus International Collaborating Clinics classification criteria for systemic lupus erythematosus. *Arthritis Rheum* 2012;64:2677-86.
- Kasukawa R, Tojo T, Miyawaki S. Preliminary diagnostic criteria for classification of mixed connective tissue disease. In: Kasukawa R, Sharp GC, editors. *Mixed connective tissue disease and antinuclear antibodies*. Amsterdam: Elsevier; 1987:41-7.
- Aletaha D, Neogi T, Silman AJ, Funovits J, Felson DT, Bingham CO 3rd, et al. 2010 rheumatoid arthritis classification criteria: an American College of Rheumatology/European League Against Rheumatism collaborative initiative. *Arthritis Rheum* 2010; 62:2569-81.
- LeRoy EC, Medsger TA Jr. Criteria for the classification of early systemic sclerosis. *J Rheumatol* 2001;28:1573-6.

28. Mosca M, Neri R, Bombardieri S. Undifferentiated connective tissue diseases (UCTD): a review of the literature and a proposal for preliminary classification criteria. *Clin Exp Rheumatol* 1999;17:615-20.
29. Bernero E, Sulli A, Ferrari G, Ravera F, Pizzorni C, Ruaro B, et al. Prospective capillaroscopy-based study on transition from primary to secondary Raynaud's phenomenon: preliminary results. *Reumatismo* 2013;65:186-91.
30. Galie N, Humbert M, Vachiery JL, Gibbs S, Lang I, Torbicki A, et al; ESC Scientific Document Group. 2015 ESC/ERS Guidelines for the diagnosis and treatment of pulmonary hypertension: The Joint Task Force for the Diagnosis and Treatment of Pulmonary Hypertension of the European Society of Cardiology (ESC) and the European Respiratory Society (ERS): Endorsed by: Association for European Paediatric and Congenital Cardiology (AEPC), International Society for Heart and Lung Transplantation (ISHLT). *Eur Heart J* 2016;37:67-119.
31. Bradley B, Branley HM, Egan JJ, Greaves MS, Hansell DM, Harrison NK, et al; British Thoracic Society Interstitial Lung Disease Guideline Group, British Thoracic Society Standards of Care Committee; Thoracic Society of Australia; New Zealand Thoracic Society; Irish Thoracic Society. Interstitial lung disease guideline: the British Thoracic Society in collaboration with the Thoracic Society of Australia and New Zealand and the Irish Thoracic Society. *Thorax* 2008;63 Suppl 5:v1-58.
32. Bergman R, Sharony L, Schapira D, Nahir MA, Balbir-Gurman A. The handheld dermatoscope as a nail-fold capillaroscopic instrument. *Arch Dermatol* 2003;139:1027-30.
33. Ingegnoli F, Zeni S, Meani L, Soldi A, Lurati A, Fantini F. Evaluation of nailfold videocapillaroscopic abnormalities in patients with systemic lupus erythematosus. *J Clin Rheumatol* 2005; 11:295-8.
34. Moneib HA, Salem SA, Aly DG, Khedr HT, Wafaey HA, Hassan HE. Assessment of serum vascular endothelial growth factor and nail fold capillaroscopy changes in systemic lupus erythematosus with and without cutaneous manifestations. *J Dermatol* 2012; 39:52-7.
35. Kuryliszyn-Moskal A, Ciolkiewicz M, Klimiuk PA, Sierakowski S. Clinical significance of nailfold capillaroscopy in systemic lupus erythematosus: correlation with endothelial cell activation markers and disease activity. *Scand J Rheumatol* 2009;38:38-45.
36. Wells AU, Hansell DM, Rubens MB, King AD, Cramer D, Black CM, et al. Fibrosing alveolitis in systemic sclerosis: indices of lung function in relation to extent of disease on computed tomography. *Arthritis Rheum* 1997;40:1229-36.
37. Steen V, Medsger TA Jr. Predictors of isolated pulmonary hypertension in patients with systemic sclerosis and limited cutaneous involvement. *Arthritis Rheum* 2003;48:516-22.
38. Le Gouellec N, Duhamel A, Perez T, Hachulla AL, Sobanski V, Faivre JB, et al. Predictors of lung function test severity and outcome in systemic sclerosis-associated interstitial lung disease. *PLoS One* 2017;12:e0181692.
39. Goh NS, Hoyles RK, Denton CP, Hansell DM, Renzoni EA, Maher TM, et al. Short-term pulmonary function trends are predictive of mortality in interstitial lung disease associated with systemic sclerosis. *Arthritis Rheumatol* 2017;69:1670-8.
40. Castellví I, Simeon-Aznar CP, Sarmiento M, Fortuna A, Mayos M, Geli C, et al. Association between nailfold capillaroscopy findings and pulmonary function tests in patients with systemic sclerosis. *J Rheumatol* 2015;42:222-7.
41. Allanore Y, Avouac J, Kahan A. Systemic sclerosis: an update in 2008. *Joint Bone Spine* 2008;75:650-5.
42. Balbir-Gurman A, Braun-Moscovici Y. Scleroderma - new aspects in pathogenesis and treatment. *Best Pract Res Clin Rheumatol* 2012;26:13-24.
43. Bredemeier M, Xavier RM, Capobianco KG, Restelli VG, Rohde LE, Pinotti AF, et al. Nailfold capillary microscopy can suggest pulmonary disease activity in systemic sclerosis. *J Rheumatol* 2004;31:286-94.
44. Ruppel GL, Enright PL. Pulmonary function testing. *Respir Care* 2012;57:165-75.
45. Boulon C, Devos S, Mangin M, Decamps-Le Chevoir J, Senet P, Lazareth I, et al. Reproducibility of capillaroscopic classifications of systemic sclerosis: results from the SCLEROCAP study. *Rheumatology* 2017;56:1713-20.