

Severe Rheumatoid Arthritis Developing in Conjunction with Gorlin Syndrome

To the Editor:

Gorlin syndrome, also known as nevoid basal cell carcinoma syndrome, is a rare multisystemic genodermatosis classically characterized by the development of numerous basal cell carcinomas (BCC)^{1,2,3}. Gorlin syndrome is caused by germline inactivating mutations in the patched (*PTCH*) gene, resulting in constitutively active hedgehog signaling^{1,2}. The hedgehog signaling pathway is important in the regulation of stem cell and progenitor cell proliferation, the maintenance and regeneration of adult tissues, and finally in carcinogenesis, including the development of sporadic BCC^{2,4}. Vismodegib, an oral inhibitor of hedgehog signaling, has demonstrated efficacy in Gorlin syndrome, as well as in patients with locally advanced or metastatic BCC^{2,4}.

Recently, dysregulated hedgehog signaling has also been implicated in the pathogenesis of rheumatoid arthritis (RA). Hedgehog signaling is highly active in the synovium of patients with RA *in vivo*, as well as in cultured fibroblast-like synoviocytes (FLS) from patients *in vitro*^{5,6}. In a mechanistically similar fashion to the malignant keratinocytes within BCC, hedgehog pathway activation in FLS results in synoviocyte proliferation, synovial hypertrophy, pannus tissue formation within the joint space, and ultimately joint destruction^{5,6,7}. Further, FLS exposed to antagonists of the hedgehog signaling pathway, or small interfering RNA targeting members of the hedgehog signaling pathway, demonstrate decreased proliferation as compared to untreated FLS^{6,8}.

We describe a case of severe RA developing in conjunction with the appearance of multiple BCC in a patient with Gorlin syndrome. Clinical improvement in both the tumor burden and the patient's RA symptoms was observed after 6 months of treatment with the hedgehog signaling pathway inhibitor vismodegib. A 65-year-old woman with a history of Gorlin syndrome and RA presented for medical and surgical evaluation of numerous BCC. The patient was previously diagnosed with Gorlin syndrome at age 28 based on the presence of 3 major and 2 minor criteria. The major criteria included (1) > 10 BCC first appearing in early adulthood; (2) 3 or more palmar pits; and (3) bilamellar calcification of the falx cerebri. The minor criteria include skeletal abnormalities such as scoliosis, and hypertelorism³. The patient also reported a symmetrical and polyarticular inflammatory arthritis of the hands, wrists, elbows, shoulders, knees, and feet, associated with morning stiffness, which first presented in close temporal proximity to the diagnosis of Gorlin syndrome. The patient was diagnosed with RA on the basis of clinical and laboratory findings, including an elevated rheumatoid factor, erythrocyte sedimentation rate, and C-reactive protein, and the patient was managed by rheumatology with prednisone, nonsteroidal antiinflammatory drugs, and hydroxychloroquine.

Physical examination revealed numerous large, erythematous and ulcerated plaques with brown-black pigmentation scattered on the scalp, face, and trunk (Figure 1). The patient was also found to have ulnar deviation, large subcutaneous nodules overlying the elbows, and skeletal deformities of the wrists, hands, and feet (Figure 2). Histological examination of a representative plaque on the back revealed a superficial and nodular pigmented BCC (Figure 3).

The patient was not a candidate for radiation therapy given the history of Gorlin syndrome, and the patient subsequently declined surgical interventions including Mohs micrographic surgery. The patient was started on vismodegib, and at the 6-month followup there was a significant reduction in the BCC tumor burden, with marked improvement in the degree of erythema, ulceration, and morbidity associated with wound care. The patient also reported subjective improvement in the severity of her RA symptoms, including a significant reduction in the tenderness of the bilateral wrists, shoulders, and knees. The patient's RA disease activity was quantified at baseline and after 6 months of treatment with vismodegib using the RA Clinical Disease Activity Index (CDAI)⁹. The CDAI is a validated disease activity measure for point-of-care clinical use in patients with RA, and is able to reliably reflect changes in disease activity over time, as well as

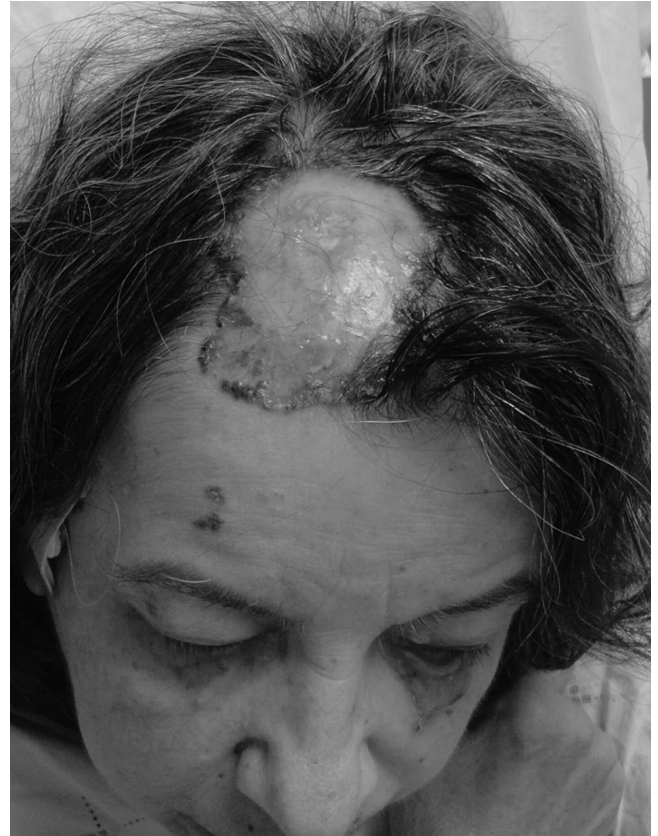

Figure 1. Clinical appearance of erythematous and eroded plaques with brown-black pigmentation representing basal cell carcinomas in a patient with Gorlin syndrome.

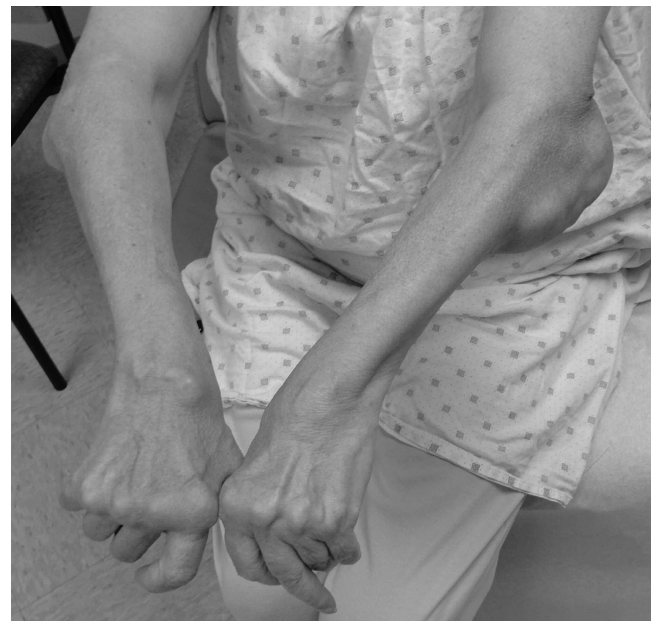

Figure 2. Examination of the extremities revealed evidence of chronic, severe rheumatoid arthritis, including ulnar deviation, large subcutaneous nodules overlying the elbows, and skeletal deformities of the metacarpophalangeal joints of the hands.

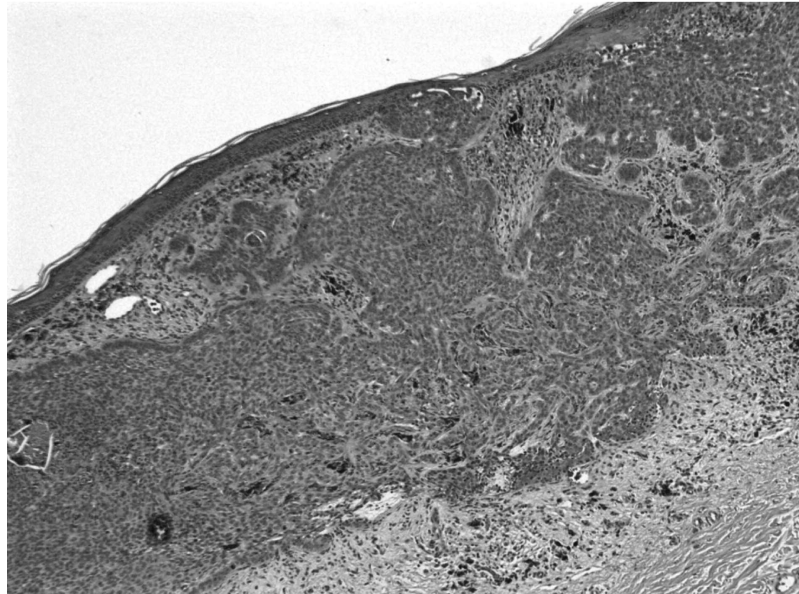


Figure 3. Histological examination (H&E stain, 20×) of an erythematous to brown plaque on the back, revealing a superficial and nodular, pigmented basal cell carcinoma.

discriminate between low, moderate, and high disease activity states^{9,10}. The patient's CDAI score decreased from a value of 21 before treatment with vismodegib, reflecting moderate clinical disease activity, to a value of 9 after treatment with vismodegib, reflecting low clinical disease activity. There were no other changes in medications during this period.

Although not classically associated with Gorlin syndrome, RA shares similar pathophysiological mechanisms involving overactive hedgehog signaling, which results in synovioyte proliferation, pannus tissue formation, and joint destruction. It is conceivable that an individual genetically predisposed to developing RA, who also carries a germline inactivating mutation in *PTCH*, may develop a particularly severe phenotype of RA driven by aberrant hedgehog signaling. This preliminary clinical observation supports the shared mechanistic pathophysiology of Gorlin syndrome, sporadic BCC, and RA, and suggests that pharmaceutical inhibition of hedgehog signaling may be a viable therapeutic target for patients with RA, in addition to patients with Gorlin syndrome and locally advanced or metastatic BCC.

JEFFREY F. SCOTT, MD, Louis Stokes Cleveland VA Medical Center, University Hospitals Case Medical Center, and Case Western Reserve University; JEREMY S. BORDEAUX, MD, MPH, Louis Stokes Cleveland VA Medical Center, University Hospitals Case Medical Center, and Case Western Reserve University, Cleveland, Ohio, USA. Address correspondence to Dr. J.F. Scott, University Hospitals Case Medical Center, 11100 Euclid Ave., Cleveland, Ohio 44106, USA.
E-mail: jeffrey.scott@uhhospitals.org

REFERENCES

1. Kimonis VE, Goldstein AM, Pastakia B, Yang ML, Kase R, DiGiovanna JJ, et al. Clinical manifestations in 105 persons with nevoid basal cell carcinoma syndrome. *Am J Med Genet* 1997;69:299-308.
2. Tang JY, Mackay-Wiggan JM, Aszterbaum M, Yauch RL, Lindgren J, Chang K, et al. Inhibiting the hedgehog pathway in patients with the basal-cell nevus syndrome. *N Engl J Med* 2012;366:2180-8.
3. Evans DG, Ladusans EJ, Rimmer S, Burnell LD, Thakker N, Farndon PA. Complications of the naevoid basal cell carcinoma syndrome: results of a population based study. *J Med Genet* 1993;30:460-4.
4. Sekulic A, Migden MR, Oro AE, Dirix L, Lewis KD, Hainsworth JD, et al. Efficacy and safety of vismodegib in advanced basal-cell carcinoma. *N Engl J Med* 2012;366:2171-9.
5. Wang M, Zhu S, Peng W, Li Q, Li Z, Luo M, et al. Sonic hedgehog signaling drives proliferation of synovioytes in rheumatoid arthritis: a possible novel therapeutic target. *J Immunol Res* 2014;2014:401903.
6. Qin S, Sun D, Li H, Li X, Pan W, Yan C, et al. The effect of SHH-Gli signaling pathway on the synovial fibroblast proliferation in rheumatoid arthritis. *Inflammation* 2016;39:503-12.
7. Kasperkovitz PV, Timmer TC, Smeets TJ, Verbeet NL, Tak PP, van Baarsen LG, et al. Fibroblast-like synovioytes derived from patients with rheumatoid arthritis show the imprint of synovial tissue heterogeneity: evidence of a link between an increased myofibroblast-like phenotype and high-inflammation synovitis. *Arthritis Rheum* 2005;52:430-41.
8. Zhu SL, Huang JL, Peng WX, Wu DC, Luo MQ, Li QX, et al. Inhibition of smoothened decreases proliferation of synovioytes in rheumatoid arthritis. *Cell Mol Immunol* 2015 Jul 20 [E-pub ahead of print].
9. Aletaha D, Smolen J. The Simplified Disease Activity Index (SDAI) and the Clinical Disease Activity Index (CDAI): a review of their usefulness and validity in rheumatoid arthritis. *Clin Exp Rheumatol* 2005;23:S100-8.
10. Anderson J, Caplan L, Yazdany J, Robbins ML, Neogi T, Michaud K, et al. Rheumatoid arthritis disease activity measures: American College of Rheumatology recommendations for use in clinical practice. *Arthritis Care Res* 2012;64:640-7. *J Rheumatol* 2016;43:7; doi:10.3899/jrheum.160062