

# Summary Findings of a Systematic Literature Review of the Ultrasound Assessment of Bone Erosions in Rheumatoid Arthritis

Marcin Szkudlarek, Lene Terslev, Richard J. Wakefield, Marina Backhaus, Peter V. Balint, George A.W. Bruyn, Emilio Filippucci, Frederique Gandjbakhch, Annamaria Iagnocco, Peter Mandl, Ingrid Möller, Esperanza Naredo, Wolfgang A. Schmidt, and Maria Antonietta d'Agostino

**ABSTRACT. Objective.** Bone erosions in rheumatoid arthritis (RA) have been studied in an increasing amount of research. Both earlier and present classification criteria of RA contain erosions as a significant classification component. Ultrasound (US) can detect bone changes in accessible surfaces. Therefore, the study group performed a systematic literature review of assessment of RA bone erosions with US.

**Methods.** A systematic search of PubMed and Embase was performed. Data on the definitions of RA bone erosions, their size, scoring, relation to synovitis, comparators, and elements of the OMERACT (Outcome Measures in Rheumatology Clinical Trials) filter were collected and analyzed.

**Results.** The selection process identified 58 original research papers. The assessed joints were most frequently metacarpophalangeal (MCP; 41 papers), proximal interphalangeal (19 papers), and metatarsophalangeal joints (MTP; 18 papers). The OMERACT definition of RA bone erosion on US was used most often (17 papers). Second and fifth MCP and fifth MTP were recommended as target joints. Conventional radiography was the most frequently used comparator (27 papers), then magnetic resonance imaging (17 papers) and computed tomography (5 papers). Reliability of assessment was presented in 20 papers and sensitivity to change in 11 papers.

**Conclusion.** This paper presents results of a systematic literature review of bone erosion assessment in RA with US. The survey suggests that US can be a helpful adjunct to the existing methods of imaging bone erosions in RA. It analyzes definitions, scoring systems, used comparators, and elements of the OMERACT filter. It also presents recommendations for a future research agenda based on the results of the review. (First Release December 1 2015; J Rheumatol 2016;43:12–21; doi:10.3899/jrheum.141416)

## Key Indexing Terms:

SYSTEMATIC REVIEW    ULTRASOUND    RHEUMATOID ARTHRITIS    BONE EROSIONS

From the Department of Rheumatology, Copenhagen University Hospital at Køge, Køge; Center for Rheumatology and Spine Diseases, Copenhagen University Hospital at Glostrup, Copenhagen, Denmark; Leeds Institute of Rheumatic and Musculoskeletal Medicine (LIRMM) Section of Musculoskeletal Disease, University of Leeds, Chapel Allerton Hospital, Leeds, UK; Department of Rheumatology and Clinical Immunology, Charité - Universitätsmedizin, Berlin; Immanuel Krankenhaus Berlin, Medical Centre for Rheumatology, Berlin-Buch, Germany; Third Department of Rheumatology, National Institute of Rheumatology and Physiotherapy, Budapest, Hungary; Department of Rheumatology, MC Groep, Lelystad, the Netherlands; Clinica Reumatologica, Università Politecnica delle Marche, Jesi, Ancona; Rheumatology Unit, Dipartimento Medicina Interna e Specialità Mediche, Sapienza Università di Roma, Rome, Italy; Rheumatology Department, Université Paris 6-Pierre et Marie Curie, Hôpital La Pitié Salpêtrière, Assistance Publique - Hôpitaux de Paris (APHP), Paris; Rheumatology Department, Université Paris Ouest-Versailles-Saint Quentin en Yvelines, Hôpital Ambroise Paré, Boulogne-Billancourt, France; Division of Rheumatology, University of Vienna, Vienna, Austria; Instituto Poal de Reumatologia-Hospital Platon, Barcelona; Department of Rheumatology, Hospital General Universitario Gregorio Marañón and Complutense University, Madrid, Spain.

M. Szkudlarek, MD, PhD, Department of Rheumatology, Copenhagen University Hospital at Køge; L. Terslev, MD, PhD, Center for Rheumatology and Spine Diseases, Copenhagen University Hospital at Glostrup; R.J. Wakefield, BM, FRCP, MD, Senior Lecturer and Honorary

Consultant Rheumatologist, LIRMM Section of Musculoskeletal Disease, University of Leeds, Chapel Allerton Hospital; M. Backhaus, Professor, Dr. Med., Department of Rheumatology and Clinical Immunology, Charité - Universitätsmedizin; P.V. Balint, MD, PhD, FRCP, Third Department of Rheumatology, National Institute of Rheumatology and Physiotherapy; G.A. Bruyn, MD, PhD, Department of Rheumatology, MC Groep; E. Filippucci, MD, PhD, Senior Lecturer in Rheumatology, Clinica Reumatologica, Università Politecnica delle Marche; F. Gandjbakhch, MD, Rheumatology Department, Université Paris 6-Pierre et Marie Curie, Hôpital La Pitié Salpêtrière, APHP; A. Iagnocco, MD, Adjunct Professor of Rheumatology, Rheumatology Unit, Dipartimento Medicina Interna e Specialità Mediche, Sapienza Università di Roma; P. Mandl, MD, PhD, Division of Rheumatology, University of Vienna; I. Möller, MD, PhD, Assistant professor of Human Anatomy, Instituto Poal de Reumatologia-Hospital Platon; E. Naredo, MD, PhD, Department of Rheumatology, Hospital General Universitario Gregorio Marañón and Complutense University; W.A. Schmidt, Prof. Dr. Med., Immanuel Krankenhaus Berlin, Medical Centre for Rheumatology; M.A. d'Agostino, Professor, MD, PhD, Rheumatology Department, Université Paris Ouest-Versailles-Saint Quentin en Yvelines, Hôpital Ambroise Paré.

Address correspondence to Dr. M. Szkudlarek, Department of Rheumatology, Copenhagen University Hospital at Køge, Lykkebakvej 1, 4600 Køge, Denmark. E-mail: marcin@dadlnet.dk

Accepted for publication August 27, 2015.

The identification of bone erosions is crucial to the early diagnosis, the prediction of future bone damage, and the monitoring of therapeutic outcomes in patients with rheumatoid arthritis (RA)<sup>1,2</sup>. Until relatively recently, conventional radiography (CR) had been considered the mainstay for their detection. However, with the availability of newer imaging techniques such as ultrasound (US), magnetic resonance imaging (MRI), and computed tomography (CT)<sup>3,4</sup>, it was acknowledged that radiography appeared less sensitive to detect early bone damage. In addition, some of the newer techniques (US and MRI) had the added advantage of being able to simultaneously visualize soft tissues. As a result, these new techniques were explored as potential alternatives for radiography. It was noted that each technique had its own strengths and weaknesses. For example, CT has a high resolution for bone damage, but is hampered by its radiation use, which makes it undesirable for repeated examinations. MRI has the benefit of simultaneously assessing soft tissue inflammation, but machine accessibility is generally low, it is expensive, and it is time-consuming to perform, especially for multijoint assessments. In contrast, US is safe, widely available, allows the simultaneous imaging of bone and soft tissue, and allows the examination of many joints in a relatively short period of time.

Increasing interest in US led to a consideration of how to standardize the technique. One of the first advances was the creation of the OMERACT (Outcome Measures in Rheumatology Clinical Trials) Ultrasound Task Force in 2004<sup>5</sup>. This resulted in the first published consensus-derived definitions for US-related pathologies, including erosions. Although work by different groups has been ongoing since then, there has been, to date, no clear agreement on which joints to examine and how to score and monitor changes, and therefore no agreement on how to implement US bone erosions in clinical and research practice.

The aim of our study was to systematically review current literature to identify levels of evidence for the use of US for the detection of bone erosions in patients with RA and to identify any gaps. The specific objectives of our study were (1) to determine the level of homogeneity in the US definitions for erosions in the published literature, and (2) to evaluate the metric properties of US for the detection and quantification of bone erosions according to the OMERACT filter, including recommendations for target joints. It was hoped that these data could then be used toward the development of guidelines at a later stage.

## MATERIALS AND METHODS

*Search strategy and study selection.* The search for original articles, published in English between January 1985 and May 2014 and referring to bone erosions and US, was carried out in PubMed and Embase databases. Reviews, letters, comments, and abstracts from scientific congresses were not included.

To obtain the largest number of references, the search was performed in PubMed and Embase with the following key words: "ultrasound OR ultrasonography OR sonography AND erosions OR cortical defect OR inter-

ruption of the bone surface OR change in the bone surface OR intra-articular discontinuity OR cortical break OR interruption of the bone margin AND rheumatoid arthritis".

Only references with available abstracts were assessed. Titles, abstracts, and full reports of articles identified were systematically screened by the first author (MS) with regard to inclusion and exclusion criteria. Final search was verified by the second and last authors (LT, MADA).

Articles that did not meet inclusion criteria were excluded at any step of the study selection.

*Data extraction.* All data were extracted from the selected articles using a standardized spreadsheet previously developed and validated for systematic reviews in musculoskeletal US<sup>6</sup>. All selected articles were rated to determine US definitions of bone erosions and size, and to evaluate the quality of the studies according to the OMERACT filter<sup>7</sup>. A standardized tool for assessing the quality of the analyzed studies was developed and assessed in a binary mode (yes/no) based on a set of 6 predefined criteria: (1) Was the patient population well-defined in the methods section? (2) Was the definition of US erosions clearly formulated? (3) Was there a description of an erosion score? (4) What joints were evaluated and were target joints recommended? (5) Was the choice of comparator adequately explained and results completely given? and (6) Was 2-dimensional or 3-D evaluation performed? Attention was also given to the quantification of erosions and the simultaneous presence of synovial changes (synovial hypertrophy ± Doppler signal) detected with US.

*Evaluation methods.* Face validity, construct validity, criterion validity, and discriminant validity (i.e., reliability and responsiveness) were independently evaluated in every paper, including whether the methods for assessing it and their measurement were available or not. Face validity, essentially subjective, was analyzed according to the conclusions of the authors. Criterion validity was considered achieved when US results were compared with a true "gold standard" (CR, MRI, CT, macroscopic view, or phantom).

Construct validity was considered as achieved when US evaluation of erosions was demonstrated to be consistent with theoretical concepts. The reliability was evaluated according to the design used (images reading reliability or patient scanning reliability).

Responsiveness or sensitivity to change was evaluated by the ability of the tool to demonstrate change, usually in response to an intervention.

*Statistical analysis.* Descriptive statistics were used to report data. Frequencies and percentages were used for categorical variables.

## RESULTS

The primary search identified 147 articles in PubMed and 166 in Embase, which after further analysis were reduced to 58 original research papers (Figure 1). The selected papers were then divided among the group members and assessed according to an agreed scoring sheet (for results of Evaluation score, see Table 1)<sup>4,5,8-17,18-27,28-37,38-47,48-57,58,59,60,61,62,63</sup>.

The data extracted from the articles during the search are displayed in Table 1, Table 2, and Table 3.

The assessed articles included 43 case series, 11 case control studies, 2 reliability studies, 1 expert consensus, and 1 experimental study. As the inclusion criteria stated, all studies involved patients with RA, apart from the expert consensus<sup>5</sup> and the experimental study<sup>41</sup>, which were selected because they brought original data not requiring patients to be assessed. Other arthritides, such as psoriatic arthropathy, juvenile idiopathic arthritis, spondyloarthropathy, gout, and osteoarthritis, were also represented, either in control groups or in parts of more heterogeneous study populations.

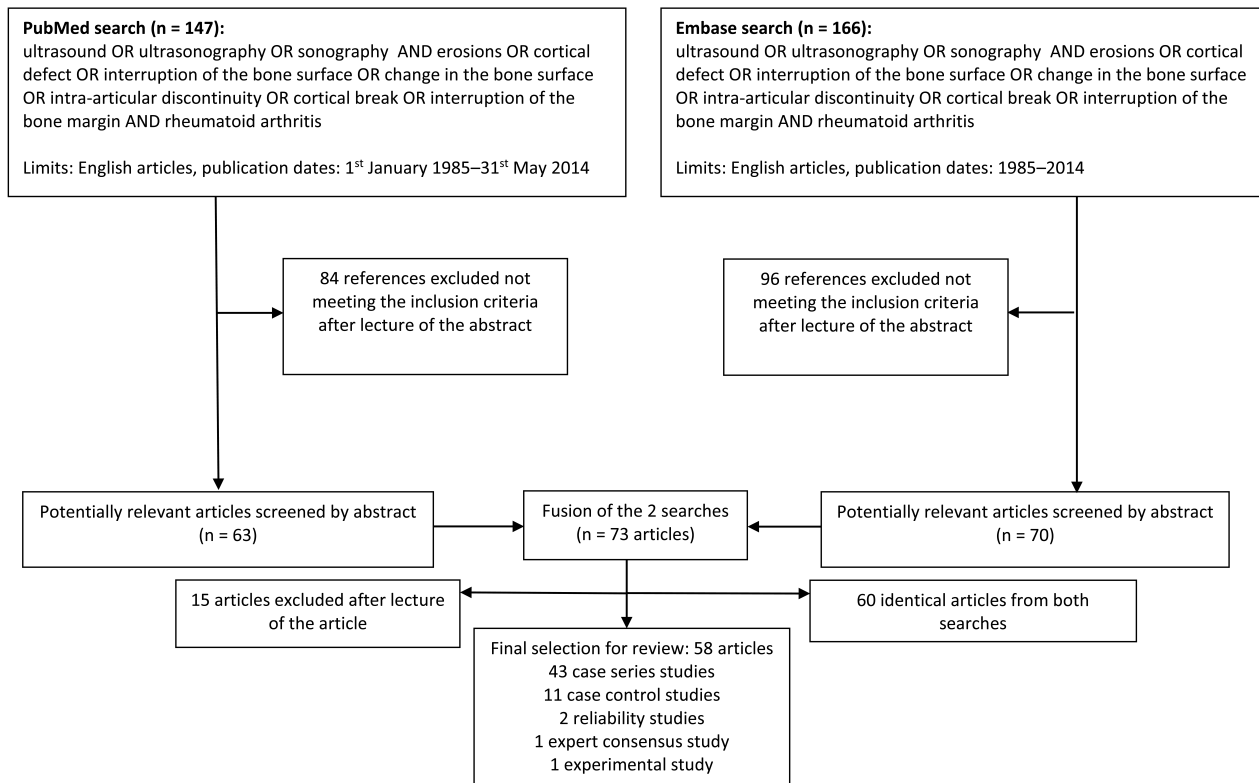


Figure 1. Flow chart of the selection of articles.

The assessed joints were predominantly the finger joints: metacarpophalangeal (MCP) in 41 studies, proximal interphalangeal (PIP) in 19 studies, and distal interphalangeal in 1 study. In 5 studies, the finger joints were scanned only from the dorsal positions; in all the others, both from dorsal and volar. The erosions in metatarsophalangeal (MTP) joints were described in 18 papers. The erosive changes in wrists were analyzed by 13 papers, the elbows by 2, and the shoulders by 6; the distal ulna as a separate joint area was analyzed in 5 papers. Erosions of the knee were studied in 3 papers, and the heel and the sternoclavicular joint in 1 paper each.

**Definitions, size, and scoring of bone erosions on US.** In 46 papers (79%), there was a clear description or definition of bone erosions. In 17 papers, the authors used the definition proposed by the OMERACT group<sup>6</sup>. Other definitions included visualization of erosive findings in 2 planes, and described the changes as “cortical breaks,” “interruptions,” or “defects.” A suggestion of an irregular floor of the change was also raised<sup>32</sup>. When the size of the cortical break was proposed for determining the change as an erosion, the detection limit was set at 2 mm in diameter in 7 papers (14%) and at 1 mm in 2 papers (4%).

In 26 studies, a semiquantitative scale of evaluation of bone erosions was used, most frequently with a scale from 0 to 3, based on either the extent of the changes or their size.

**Recommendation of target joints and relation to synovitis.** Only a few papers addressed the subject of recommended joints for detection or monitoring of bone erosions. The suggested joints were the second MCP joint, fifth MCP joint, fifth MTP joint (5 papers each), MCP joints in general (2 studies), PIP joints (2 papers), elbow joint (1 paper), and the distal ulna (1 paper).

The relationship of bone erosions to US synovitis (synovial hypertrophy ± Doppler signal) of the affected joint was assessed in 15 papers (26%). Yet the direct relationship between the presence of synovitis and the development of bone erosions detected with US was not studied. Ohrndorf, *et al* showed in a cohort of patients with RA a fall in greyscale and Doppler variables in parallel with a decrease in the erosion score, suggesting a healing process of erosions under treatment<sup>62</sup>.

**Elements of the OMERACT filter, used comparators, and type of visualization**

Table 3 presents the results of the 58 selected papers when tested according to the OMERACT filter.

**Truth.** Face validity was achieved in 50 studies, criterion validity assessed in 27 papers, and construct validity in 20 studies. The most frequent comparator was CR (27 papers, 47%), then MRI (17 studies, 30%), CT (5 studies, 9%), and macroscopic artificial bone erosions in 1 paper (2%).

Table 1. Characteristics of the studies.

Study	Yr of Publication	Evaluation Score, 0–6	Type of Publication	Sample Size	Population Assessed	Assessed Joint Area	Dorsal/volar, Only for Finger Joints
1. Grassi, <i>et al</i> <sup>8</sup>	1993	4	Case control	20 + 20	RA + healthy controls	MCP	Dorsal + volar
2. Østergaard, <i>et al</i> <sup>9</sup>	1995	4	Case control	20	RA, JIA, SpA, OA, healthy controls	Knee	NA
3. Lund, <i>et al</i> <sup>10</sup>	1995	5	Case series	29 + 10	RA + healthy controls	MCP, wrist	Dorsal + volar
4. Alasaarela, <i>et al</i> <sup>11</sup>	1998	4	Case series	26	RA	Humeral head	NA
5. McGonagle, <i>et al</i> <sup>12</sup>	1999	3	Case series	10	RA	MCP	NM
6. Backhaus, <i>et al</i> <sup>13</sup>	1999	3	Case series	60	Arthritides	MCP, PIP, DIP	Dorsal + volar
7. Wakefield, <i>et al</i> <sup>14</sup>	2000	5	Case series	165	RA + healthy controls	First to fifth MCP, dominant hand	Dorsal + volar
8. Grassi, <i>et al</i> <sup>15</sup>	2001	3	Case series	6	RA	Second and fifth MCP	Dorsal + volar
9. Klocke, <i>et al</i> <sup>16</sup>	2001	4	Case series	15	RA	Wrist, MCP, and MTP	Dorsal
10. Naranjo, <i>et al</i> <sup>17</sup>	2002	4	Case series	57 + 32	RA + healthy controls	Shoulder	NA
11. Frediani, <i>et al</i> <sup>18</sup>	2002	2	Case series	80	PsA, RA	Quadriceps enthesis	NA
12. Frediani, <i>et al</i> <sup>19</sup>	2002	2	Case series	160	PsA + RA + healthy controls	Quadriceps enthesis	NA
13. Backhaus, <i>et al</i> <sup>20</sup>	2002	4	Case series	49	Arthritides	MCP, PIP, DIP	Dorsal + volar
14. Weidekamm, <i>et al</i> <sup>21</sup>	2003	5	Case series	47	RA	Wrist, MCP, PIP	Dorsal
15. Szkudlarek, <i>et al</i> <sup>22</sup>	2003	5	Case series	30	RA	MCP, PIP, MTP	Dorsal + volar
16. Lerch, <i>et al</i> <sup>23</sup>	2003	6	Case series	320	RA	Elbow	NA
17. Falsetti, <i>et al</i> <sup>24</sup>	2003	4	Case control	598	OA, RA, PsA, healthy controls	Heel	NA
18. Hermann, <i>et al</i> <sup>25</sup>	2003	5	Case series	43	RA	Shoulder	NA
19. Lopez-Ben, <i>et al</i> <sup>26</sup>	2004	5	Case control	10 + 5	RA + healthy controls	MCP and MTP	Dorsal + volar
20. Hoving, <i>et al</i> <sup>27</sup>	2004	4	Case series	46	RA	Wrist, MCP, PIP	Dorsal + volar
21. Szkudlarek, <i>et al</i> <sup>28</sup>	2004	5	Case series	40 + 20	RA + healthy controls	MTP	NA
22. Magnani, <i>et al</i> <sup>29</sup>	2004	5	Case control	13 + 10	RA + patients with arthralgia	Wrists and MCP	Dorsal + volar
23. Wakefield, <i>et al</i> <sup>5</sup>	2005	2	Expert consensus	NA	NA	NA	NA
24. Szkudlarek, <i>et al</i> <sup>30</sup>	2006	6	Case control	40 + 20	RA + healthy controls	Second to fifth MCP and PIP bilaterally	Dorsal + volar
25. Døhn, <i>et al</i> <sup>4</sup>	2006	4	Case series	19	RA	Second to fifth MCP	Dorsal + volar
26. Scheel, <i>et al</i> <sup>31</sup>	2006	5	Case series	16	RA	Second to fifth MCP and PIP bilaterally	Dorsal + volar
27. Bajaj, <i>et al</i> <sup>32</sup>	2007	5	Case control	21 + 5	RA + healthy controls	Bilateral second MCP, bilateral fifth MCP, bilateral fifth MTP, most swollen PIP	Dorsal + volar
28. Bowen, <i>et al</i> <sup>33</sup>	2008	2	Case series	31	RA	Second and fifth plantar forefoot	NA
29. Chaiamnuay, <i>et al</i> <sup>34</sup>	2008	5	Case series	144 cross-sectional, 58 longitudinal	Suspected inflammatory arthropathy	Wrist, MCP, fifth MTP, PIP	NM
30. Filippucci, <i>et al</i> <sup>35</sup>	2009	3	Case series	2	RA	Second to fifth MCP	Dorsal + volar
31. Reynolds, <i>et al</i> <sup>36</sup>	2009	4	Case series	25	RA	1 MCP or 1 PIP	Dorsal
32. Sheane, <i>et al</i> <sup>37</sup>	2009	6	Case series	30	Inflammatory arthritis: RA and UA	Fifth MTP bilaterally	NA
33. Hammer, <i>et al</i> <sup>38</sup>	2009	5	Case series	70	RA	Distal ulna	NA
34. Naredo, <i>et al</i> <sup>39</sup>	2010	3	Case series	2	RA	Second MCP, the styloid of the ulna, bilaterally	Dorsal
35. Sanja, <i>et al</i> <sup>40</sup>	2010	2	Case series	178	RA, degenerative shoulder disease	Shoulder	NA
36. Koski, <i>et al</i> <sup>41</sup>	2010	4	Experimental study	21 bovine legs	NA	NA	NA
37. Botar-Jid, <i>et al</i> <sup>42</sup>	2010	4	Case series	34	RA	MCP, PIP	Dorsal + volar
38. Gutierrez, <i>et al</i> <sup>43</sup>	2011	4	Case series	22	RA	MCP, ulnar styloid, and fifth MTP	Dorsal + volar
39. Døhn, <i>et al</i> <sup>44</sup>	2011	6	Case series	52	RA	First to fifth MCP	Dorsal + volar
40. Filer, <i>et al</i> <sup>45</sup>	2011	4	Case series	58	Arthritis: mixed PsA, RA, reactive arthritis, miscellaneous conditions	38 joints: knee, ankle, MCP, and MTP, elbow, wrist, and shoulder	Dorsal + volar
41. Finzel, <i>et al</i> <sup>46</sup>	2011	5	Case control	26	RA, PsA and healthy controls	Second to fourth MCP palmar, dorsal, radial for 2 MCP	Dorsal + volar
42. Ceccarelli, <i>et al</i> <sup>47</sup>	2011	3	Case series	77	RA	MCP, PIP, MTP	Dorsal + volar
43. Iagnocco, <i>et al</i> <sup>48</sup>	2011	3	Case series	9	RA, OA	Radiocarpal, MCP, PIP, and DIP of 1 hand	NM
44. Amin, <i>et al</i> <sup>49</sup>	2012	4	Case control	50 + 15	RA + controls	Shoulder	NA
45. Broll, <i>et al</i> <sup>50</sup>	2012	4	Case series	50	Suspected arthritis	Wrist, MCP	Dorsal + volar
46. Ohrndorf, <i>et al</i> <sup>51</sup>	2012	3	Reliability study	6	RA	MCP, PIP, MTP	Dorsal + volar
47. Macchioni, <i>et al</i> <sup>52</sup>	2013	5	Case series	24	RA	MCP	Dorsal + volar
48. Chavez-Lopez, <i>et al</i> <sup>53</sup>	2013	4	Reliability study	8	RA	Wrist, MCP, and PIP	Lateral
49. Schmidt, <i>et al</i> <sup>54</sup>	2013	5	Case series	26	RA	MCP joints 2–5 or MTP 1–5 of dominant hand/foot and bilateral MCP 2, 5 and MTP 5	Dorsal + volar



Table 1. Continued.

Study	Yr of Publication	Evaluation Score, 0–6	Type of Publication	Sample Size	Population Assessed	Assessed Joint Area	Dorsal/volar, Only for Finger Joints
50. Naredo, <i>et al</i> <sup>55</sup>	2013	3	Case series	23	RA	MCP	Dorsal + volar
51. Døhn, <i>et al</i> <sup>56</sup>	2013	6	Case series	49	RA	MCP 2–5	Dorsal + volar
52. Funck-Brentano, <i>et al</i> <sup>57</sup>	2013	6	Case series	127	Early RA	MCP 2 and 5, and MTP 5	Dorsal + volar
53. Backhaus, <i>et al</i> <sup>58</sup>	2013	3	Case series	432	RA	MCP, PIP, MTP, wrist	Dorsal + volar
54. Rodríguez-Henríquez, <i>et al</i> <sup>59</sup>	2013	3	Case control	206	RA + healthy controls	SC joint	NA
55. Kawashiri, <i>et al</i> <sup>60</sup>	2014	3	Case series	29	RA	Wrists, MCP, and PIP	Dorsal
56. Zayat, <i>et al</i> <sup>61</sup>	2015	5	Case control	310	RA, OA, gout + healthy controls	Distal radius and ulna; second, third, and fifth MCP and PIP; first and fifth MTP	Dorsal + volar
57. Ohrndorf, <i>et al</i> <sup>62</sup>	2014	5	Case series	38	RA	Wrist, MCP, PIP, MTP	Dorsal + volar
58. Tamas, <i>et al</i> <sup>63</sup>	2014	4	Case series	185, 110 + 75	RA, other erosive disease, healthy controls	MCP 2–5, ulnar head, 1 and 5 MTP	Dorsal + volar

RA: rheumatoid arthritis; JIA: juvenile idiopathic arthritis; SpA: spondyloarthritis; OA: osteoarthritis; PsA: psoriatic arthritis; MCP: metacarpophalangeal; PIP: proximal interphalangeal; DIP: distal interphalangeal; MTP: metatarsophalangeal; SC: sternoclavicular; NA: nonapplicable; NM: not mentioned; UA: undifferentiated arthritis.

**Discrimination: Reliability.** Reliability of detection of bone erosions was described in 21 papers; both intra- and inter-observer reliability were assessed. Most often (in 13 out of 21 studies, 62%) reliability was tested dynamically by different ultrasonographers examining the same patients, but assessment on sets of static images and videos were also used.

**Discrimination: Responsiveness.** Sensitivity to change was assessed in 11 studies and in 2 of them, a reduction in size of erosions in the evaluated joints was reported<sup>55,61</sup>. In 6/11 studies, where sensitivity to change was studied, erosive changes were described as present/absent. In 5/11, scoring systems were used, 3 based on size and 2 based on description.

**Feasibility.** None of the analyzed papers reported information about the feasibility of US for examining erosions.

**Visualization.** The use of 3-D probes for detection of bone erosions was assessed only in 3 papers. In 2 papers, the numbers of patients were extremely small (2 in each).

## DISCUSSION

US is increasingly being used as a tool by rheumatologists for the assessment of patients with suspected or proven RA. Its many advantages include its wide availability and ability to be performed at the point of care, supplementing the clinical examination with important information. Bone erosions are one of the major features of RA and prevention of their emergence is one of the main aims of the treatment, stressing the need for sensitive imaging methods. Moreover, their presence is a prognostic sign of aggressive disease. Therefore, the detection and followup of bone erosions in RA are of major importance for initial and current evaluation of the progression of the disease and affect further treatment decisions.

Our systematic literature review shows that researchers most frequently use US to assess finger and toe joints, followed by the wrists and shoulders, and rarely the knee joints; this is in accordance with studies showing that the earliest detectable erosive bone changes appear in the small joints in patients with RA<sup>64</sup>. As shown in the systematic review by Baillet, *et al*<sup>65</sup>, US is more sensitive for detecting erosions in both the small and large joints of the extremities than CR, especially in early RA, and has a sensitivity similar to MRI<sup>6</sup>. This is especially true for joint surfaces that are easily available for US; while in the areas with no or only limited accessibility for US, MRI has an obvious advantage as shown by Døhn, *et al*<sup>4</sup>.

The definitions used in describing erosions showed greater homogeneity after the publication of the OMERACT consensus definitions by Wakefield, *et al*<sup>5</sup>, predominantly using the definitions presented there. The OMERACT definition did not encompass the size criterion, and with the increasing resolution of the US probes, it may be necessary to include both shape and size of the findings. The most frequently suggested cutoff between a normal variation in bone surfaces and a true erosion was 2 mm. Studies showing that there are erosion-like changes such as vessel channels<sup>46</sup> even in healthy controls underline the necessity for further studies that explore the limits between normality and findings regarded as true bone erosions.

The literature review also revealed a lack of consensus regarding scoring systems for erosive changes. Moreover, the common limitation for many of the suggested scoring systems is the inability to show progression once the top score is reached (e.g., erosion > 4 mm). In the case of counting the number of erosions as a scoring system, the problem arises when 2 or more erosions melt and become 1 big erosion — in fact, a progression that will be scored as an improvement. This highlights the necessity for a consensus-based scoring system that takes these issues into account.

Table 2. Ultrasound definition and description of bone erosions on ultrasound.

Study	Definition or Description of Erosions	Described Size of Erosions	Scoring of Erosions	Recommendation as Target Joints	Relation to Synovitis	2-dimensional or 3-D	Assessment
1. Grassi, <i>et al</i> <sup>8</sup>	Y	N	N	N	N	2-D	Live
2. Østergaard, <i>et al</i> <sup>9</sup>	Y	N	N	N	N	2-D	Live
3. Lund, <i>et al</i> <sup>10</sup>	Y	Y	Semiquantitative scale from 0–3	MCP	N	2-D	Images
4. Alasaarela, <i>et al</i> <sup>11</sup>	N	Y	Y	N	N	2-D	Live
5. McGonagle, <i>et al</i> <sup>12</sup>	Y	Y, between 2–4 mm	N	N	N	2-D	Live
6. Backhaus, <i>et al</i> <sup>13</sup>	N	N	N	N	N	2-D	Live
7. Wakefield, <i>et al</i> <sup>14</sup>	N	N	Y, no, possible or definite erosion	Y	N	2-D	Live/video
8. Grassi, <i>et al</i> <sup>15</sup>	N	N	N	NA	N	2-D	Live
9. Klocke, <i>et al</i> <sup>16</sup>	Y	N	N	NA	NA	2-D	Live
10. Naranjo, <i>et al</i> <sup>17</sup>	Y	N	N	N	N	2-D	Live
11. Frediani, <i>et al</i> <sup>18</sup>	N	N	N	N	N	2-D	Live
12. Frediani, <i>et al</i> <sup>19</sup>	N	N	N	N	N	2-D	Live
13. Backhaus, <i>et al</i> <sup>20</sup>	Y	N	N	N	Y	2-D	Live
14. Weidekamm, <i>et al</i> <sup>21</sup>	Y	N	Y	N	Y	2-D	Live
15. Szkudlarek, <i>et al</i> <sup>22</sup>	Y	N	0–3	Y	N	2-D	Live
16. Lerch, <i>et al</i> <sup>23</sup>	Y	> 2 mm	Y	Elbow	Y	2-D	Live/images/ video
17. Falsetti, <i>et al</i> <sup>24</sup>	Y	N	N	N	N	2-D	Live
18. Hermann, <i>et al</i> <sup>25</sup>	Y	Y	Y	N	Y	2-D	Live
19. Lopez-Ben, <i>et al</i> <sup>26</sup>	Y	Y, 2–8 mm, average size of 3.4 mm	N	Fifth MTP	N	2-D	Images
20. Hoving, <i>et al</i> <sup>27</sup>	Y	N	N	N	N	2-D	Live
21. Szkudlarek, <i>et al</i> <sup>28</sup>	Y	N	Y, 0–3	N	N	2-D	Live
22. Magnani, <i>et al</i> <sup>29</sup>	Y	Diameter ≥ 2 mm	Present/absent ≥ 2 mm interruption	N	NA	2-D	Live/images
23. Wakefield, <i>et al</i> <sup>5</sup>	Y	N	NA	NA	NA	2-D	NA
24. Szkudlarek, <i>et al</i> <sup>30</sup>	Y	N	Y	Y	N	2-D	Live
25. Døhn, <i>et al</i> <sup>4</sup>	Y	N	N	N	N	2-D	Live
26. Scheel, <i>et al</i> <sup>31</sup>	Y	Y	N	Second, third, fifth MCP and PIP	Y	2-D	Images
27. Bajaj, <i>et al</i> <sup>32</sup>	Y	> 2 mm cortical defect	Present/absent > 2 mm interruption	Second MCP, followed by the most swollen PIP at time of examination	Y	2-D	Images
28. Bowen, <i>et al</i> <sup>33</sup>	N	N	N	N	N	2-D	Live
29. Chaiamnuay, <i>et al</i> <sup>34</sup>	Y	N, > 2 mm	N	Second and fifth MCP, fifth MTP, wrist, most affected PIP (10 joints per patient) bilaterally	Y	2-D	Live
30. Filippucci, <i>et al</i> <sup>35</sup>	Y	Y	From < 1 to > 4 mm	N	N	2-D and 3-D	Images
31. Reynolds, <i>et al</i> <sup>36</sup>	Y	Y, > 2 mm	Y	N	Y	2-D	Videos
32. Sheane, <i>et al</i> <sup>37</sup>	Y	N	Y	Fifth MTP	Y	2-D	Live
33. Hammer, <i>et al</i> <sup>38</sup>	N	Y	Y	Y	N	2-D	Live
34. Naredo, <i>et al</i> <sup>39</sup>	OMERACT	N	N	N	NA	2-D and 3-D	Live/3-D volumes
35. Sanja, <i>et al</i> <sup>40</sup>	N	N	N	N	N	2-D	Live
36. Koski, <i>et al</i> <sup>41</sup>	Y	Y	Y	N	N	2-D	Live
37. Botar-Jid, <i>et al</i> <sup>42</sup>	OMERACT	N	Y	N	N	2-D	Live
38. Gutierrez, <i>et al</i> <sup>43</sup>	OMERACT	Y	Y, 0–4	NA	N	2-D	Live
39. Døhn, <i>et al</i> <sup>44</sup>	Y	Y	0-3	Y	Y	2-D	Images
40. Filer, <i>et al</i> <sup>45</sup>	OMERACT	N	N	N	N	2-D	Images
41. Finzel, <i>et al</i> <sup>46</sup>	Y	Y	Y, 0–5 according to size	N	N	2-D	Live
42. Ceccarelli, <i>et al</i> <sup>47</sup>	OMERACT	N	N	N	N	2-D	Live
43. Iagnocco, <i>et al</i> <sup>48</sup>	N	N	N	N	N	2-D	Live
44. Amin, <i>et al</i> <sup>49</sup>	N	N	Y	N	N	2-D	Live
45. Broll, <i>et al</i> <sup>50</sup>	Y	N	N	N	N	2-D	Live
46. Ohrndorf, <i>et al</i> <sup>51</sup>	N	N	N	Y	N	2-D	Live
47. Macchioni, <i>et al</i> <sup>52</sup>	OMERACT	N	Y	N	Y	2-D	Live
48. Chavez-Lopez, <i>et al</i> <sup>53</sup>	OMERACT	In mm	0–3	N	N	2-D	Live
49. Schmidt, <i>et al</i> <sup>54</sup>	OMERACT	≥ 1 mm in each direction	Y	N	N	2-D	Live
50. Naredo, <i>et al</i> <sup>55</sup>	OMERACT	N	N	N	N	3-D	Images
51. Døhn, <i>et al</i> <sup>56</sup>	OMERACT	mm	0–3	MCP	N	2-D	Images

Table 2. Continued.

Study	Definition or Description of Erosions	Described Size of Erosions	Scoring of Erosions	Recommendation as Target Joints	Relation to Synovitis	2-dimensional or 3-D	Assessment
52. Funck-Brentano, <i>et al</i> <sup>57</sup>	OMERACT	mm	0-4	MCP second and fifth, MTP fifth	Y	2-D	Live
53. Backhaus, <i>et al</i> <sup>58</sup>	OMERACT	N	N	N	Y	2-D	Live
54. Rodríguez-Henríquez, <i>et al</i> <sup>59</sup>	OMERACT	N	N	N	Y	2-D	Live
55. Kawashiri, <i>et al</i> <sup>60</sup>	OMERACT	N	N	N	Y	2-D	Live
56. Zayat, <i>et al</i> <sup>61</sup>	OMERACT	Y	Y	Distal ulna, second and fifth MCP, fifth MTP	N	2-D	Images
57. Ohrndorf, <i>et al</i> <sup>62</sup>	OMERACT	Y	Y	N	Y	2-D	Live
58. Tamas, <i>et al</i> <sup>63</sup>	OMERACT	> 1 mm long and transverse	N	Second, fifth MCP and fifth MTP	N	2-D	Live

Y: yes; N: no; NA: nonapplicable; MCP: metacarpophalangeal; PIP: proximal interphalangeal; MTP: metatarsophalangeal; OMERACT: Outcome Measures in Rheumatology Clinical Trials; 2-D: 2-dimensional.

Bone erosions can be detected with US in all joints affected by RA; however, our review demonstrates that the recommended target joints include MCP and MTP, and in particular the second and fifth MCP joints and the fifth MTP joint.

Some publications also reported on the presence of synovitis concomitant with the presence of bone erosions in the assessed joints, referring to the possible causal effect of the pannus on the emergence of bone erosions. Yet the studies on coexistence of synovial changes and development of bone erosions with US are too few to conclude anything substantial.

The metric properties of US for erosions were analyzed using the OMERACT filter and the analyzed literature reported good intra- and interobserver reliability. The sensitivity to change was assessed in 11 papers, showing that it was possible to assess changes in bone erosions over time, either as present/absent or with scoring systems. However, the weakness of the analysis lies in the differences among the systems, making general conclusions difficult. The criterion validity (comparison to micro- or macroscopic appearance) was assessed in only 1 paper using macroscopic bovine changes as a comparator<sup>41</sup>. The construct validity was analyzed mainly in relation to MRI and CR, showing good correlation with the former and better sensitivity than the latter, especially in early RA, for detection of bone erosions. Somewhat surprisingly, CT was used as the gold standard in only 5 publications. CT is more advantageous than MRI for the assessment of bones. However, its inability to detect inflammation such as synovitis, tenosynovitis, or bone marrow edema, and the radiation risk are undoubtedly the principal reasons limiting its use in daily clinical practice and in trials.

A novel technique for evaluating bone erosions by US is the 3-D US<sup>35,39,55</sup>. This technique was evaluated in only 3 papers and further studies are warranted before its use for diagnosis and monitoring can be assessed, but especially for monitoring, the modality holds promise for the future.

The assessed papers did not allow confirmation that differentiation between arthritides with US on the basis of presence, character, and localization of bone erosions is possible. However, as shown by Zayat, *et al*, the presence of any erosive changes in the fifth MTP was specific for RA<sup>61</sup>. It should be pointed out that some of the included papers in this review<sup>15,35,39,48,51,53</sup> contain a small number of patients and therefore their importance lies more in supporting evidence from larger studies and demonstrating the development of US in erosion diagnostics and monitoring.

US may be useful in the detection of RA bone erosions. It appears as a valid (especially for face and content validity) and reliable tool for evaluating erosions. The definition is fairly congruent, but a consensus on scoring erosions is required to improve the comparability of studies and to improve the value of US in RA management. Recommendations for future research include (1) assessment of joints other than MCP, PIP, and MTP (wrists, ankles, knees, elbows, and shoulders for bone erosions); (2) consensus on a size-based definition; (3) longitudinal studies of development of erosions and especially development of erosions when inflammation is well controlled; (4) more widespread use of CT as comparator; (5) more widespread use of 3-D visualization of bone erosions; (6) differentiation between arthritides with US on the basis of presence, character, and localization of bone erosions; and (7) differentiation between bone erosions and physiological bone profile interruptions.

## REFERENCES

- Arnett FC, Edworthy SM, Bloch DA, McShane DJ, Fries JF, Cooper NS, *et al*. The American Rheumatism Association 1987 revised criteria for the classification of rheumatoid arthritis. *Arthritis Rheum* 1988;31:315-24.
- Aletaha D, Neogi T, Silman AJ, Funovits J, Felson DT, Bingham CO 3rd, *et al*. 2010 rheumatoid arthritis classification criteria: an American College of Rheumatology/European League Against Rheumatism collaborative initiative. *Ann Rheum Dis* 2010; 69:1580-8. Erratum in: *Ann Rheum Dis* 2010;69:1892.

Table 3. Elements of the OMERACT filter.

Study	Face Validity	Reliability, Intra- and Interobserver + Method	Sensitivity to Change	Construct Validity	Criterion Validity	Type of Comparator
1. Grassi, <i>et al</i> <sup>8</sup>	Y	N	N	Y	N	CR
2. Østergaard, <i>et al</i> <sup>9</sup>	N	N	N	Y	N	MRI, CR
3. Lund, <i>et al</i> <sup>10</sup>	Y	ICC	N	N	N	N
4. Alasaarela, <i>et al</i> <sup>11</sup>	Y	N	N	Y	N	CR, MRI, CT
5. McGonagle, <i>et al</i> <sup>12</sup>	N	N	N	N	N	N
6. Backhaus, <i>et al</i> <sup>13</sup>	Y	IVC	N	Y	Y	CR, MRI
7. Wakefield, <i>et al</i> <sup>14</sup>	Y	Cohen $\kappa$ and a 0–2 confidence scale	N	Y	Y	CR, MRI
8. Grassi, <i>et al</i> <sup>15</sup>	Y	N	N	N	Y	CR
9. Klocke, <i>et al</i> <sup>16</sup>	N	N	NA	NA	Y	CR
10. Naranjo, <i>et al</i> <sup>17</sup>	Y	N	N	Y	N	CR
11. Frediani, <i>et al</i> <sup>18</sup>	N	N	N	N	N	N
12. Frediani, <i>et al</i> <sup>19</sup>	Y	N	N	N	N	N
13. Backhaus, <i>et al</i> <sup>20</sup>	Y	N	Y	Y	Y	CR, MRI
14. Weidekamm, <i>et al</i> <sup>21</sup>	Y	N	N	Y	N	CR
15. Szkudlarek, <i>et al</i> <sup>22</sup>	Y	ICC/ $\kappa$ /overall agreement	N	Y	N	N
16. Lerch, <i>et al</i> <sup>23</sup>	Y	Overall agreement	Y	N	Y	CR
17. Falsetti, <i>et al</i> <sup>24</sup>	N	N	N	Y	N	CR
18. Hermann, <i>et al</i> <sup>25</sup>	Y	N	N	Y	N	MRI, CR
19. Lopez-Ben, <i>et al</i> <sup>26</sup>	Y	N	N	N	Y	CR
20. Hoving, <i>et al</i> <sup>27</sup>	N	N	N	Y	N	MRI, CR
21. Szkudlarek, <i>et al</i> <sup>28</sup>	Y	N	N	Y	Y	MRI, CR
22. Magnani, <i>et al</i> <sup>29</sup>	Y	NA	NA	Y	N	MRI
23. Wakefield, <i>et al</i> <sup>5</sup>	NA	NA	N	NA	NA	NA
24. Szkudlarek, <i>et al</i> <sup>30</sup>	Y	N	N	Y	Y	MRI
25. Døhn, <i>et al</i> <sup>4</sup>	Y	N	N	Y	Y	CT
26. Scheel, <i>et al</i> <sup>31</sup>	Y	N	Y	Y	N	MRI, CR
27. Bajaj, <i>et al</i> <sup>32</sup>	N	$\kappa$	Y	N	N	CR
28. Bowen, <i>et al</i> <sup>33</sup>	Y	$\kappa$	N	N	N	N
29. Chaiamnuay, <i>et al</i> <sup>34</sup>	Y	N	N	N	N	CR
30. Filippucci, <i>et al</i> <sup>35</sup>	Y	$\kappa$	N	N	N	N
31. Reynolds, <i>et al</i> <sup>36</sup>	Y	N	N	N	N	N
32. Sheane, <i>et al</i> <sup>37</sup>	Y	N	N	Y	N	CR
33. Hammer, <i>et al</i> <sup>38</sup>	Y	N	Y	Y	N	CR, MRI
34. Naredo, <i>et al</i> <sup>39</sup>	Y	$\kappa$	NA	NA	NA	NA
35. Sanja, <i>et al</i> <sup>40</sup>	Y	N	N	N	N	N
36. Koski, <i>et al</i> <sup>41</sup>	Y	$\kappa$	N	N	Y	Bovine bones
37. Botar-Jid, <i>et al</i> <sup>42</sup>	Y	N	N	N	N	N
38. Gutierrez, <i>et al</i> <sup>43</sup>	Y	$\kappa$ and overall agreement	N	N	N	N
39. Døhn, <i>et al</i> <sup>44</sup>	Y	ICC	Y	Y	Y	CR, MRI, CT
40. Filer, <i>et al</i> <sup>45</sup>	Y	N	N	N	N	CR
41. Finzel, <i>et al</i> <sup>46</sup>	Y	N	N	N	Y	Micro-CT
42. Ceccarelli, <i>et al</i> <sup>47</sup>	Y	$\kappa$ + overall agreement	Y	N	N	N
43. Iagnocco, <i>et al</i> <sup>48</sup>	Y	Descriptive	N	N	Y	MRI
44. Amin, <i>et al</i> <sup>49</sup>	Y	N	N	Y	N	MR
45. Broll, <i>et al</i> <sup>50</sup>	Y	N	N	Y	N	MRI
46. Ohrndorf, <i>et al</i> <sup>51</sup>	Y	$\kappa$ and overall agreement	N	N	N	N
47. Macchioni, <i>et al</i> <sup>52</sup>	Y	$\kappa$	Y	N	N	CR
48. Chavez-Lopez, <i>et al</i> <sup>53</sup>	Y	Weighted $\kappa$ , overall agreement	N	Y	N	N
49. Schmidt, <i>et al</i> <sup>54</sup>	Y	Cohen $\kappa$	N	Y	Y	MRI, CR
50. Naredo, <i>et al</i> <sup>55</sup>	Y	ICC	Y	N	N	N
51. Døhn, <i>et al</i> <sup>56</sup>	Y	N	N	Y	Y	CT
52. Funck-Brentano, <i>et al</i> <sup>57</sup>	Y	N	N	Y	Y	CR
53. Backhaus, <i>et al</i> <sup>58</sup>	Y	N	Y	Y	Y	N
54. Rodríguez-Henríquez, <i>et al</i> <sup>59</sup>	Y	$\kappa$	N	N	N	N
55. Kawashiri, <i>et al</i> <sup>60</sup>	Y	N	N	N	N	N
56. Zayat, <i>et al</i> <sup>61</sup>	Y	Quadrated weighted $\kappa$	N	N	N	N
57. Ohrndorf, <i>et al</i> <sup>62</sup>	Y	N	Y	Y	N	CR
58. Tamas, <i>et al</i> <sup>63</sup>	Y	N	N	Y	N	N

Y: yes; N: no; NA: nonapplicable; CR: conventional radiography; MRI: magnetic resonance imaging; CT: computed tomography; ICC: intraclass correlation coefficient; IVC: intraobserver variation coefficient.



3. Klarlund M. Magnetic resonance imaging of wrist and finger joints in rheumatoid arthritis and early unclassified polyarthritis (PhD dissertation). Copenhagen: University of Copenhagen; 2000, 103 p.
4. Døhn UM, Ejbjerg BJ, Court-Payen M, Hasselquist M, Narvestad E, Szkudlarek M, et al. Are bone erosions detected by magnetic resonance imaging and ultrasonography true erosions? A comparison with computed tomography in rheumatoid arthritis metacarpophalangeal joints. *Arthritis Res Ther* 2006;8:R110.
5. Wakefield RJ, Balint PV, Szkudlarek M, Filippucci E, Backhaus M, D'Agostino MA, et al; OMERACT 7 Special Interest Group. Musculoskeletal ultrasound including definitions for ultrasonographic pathology. *J Rheumatol* 2005;32:2485-7.
6. Joshua F, Lassere M, Bruyn GA, Szkudlarek M, Naredo E, Schmidt WA, et al. Summary findings of a systematic review of the ultrasound assessment of synovitis. *J Rheumatol* 2007;34:839-47.
7. Boers M, Brooks P, Strand CV, Tugwell P. The OMERACT filter for outcome measures in rheumatology. *J Rheumatol* 1998;25:198-9.
8. Grassi W, Tittarelli E, Pirani O, Avaltroni D, Cervini C. Ultrasound examination of metacarpophalangeal joints in rheumatoid arthritis. *Scand J Rheumatol* 1993;22:243-7.
9. Østergaard M, Court-Payen M, Gideon P, Wieslander S, Cortsen M, Lorenzen I, et al. Ultrasonography in arthritis of the knee. A comparison with MR imaging. *Acta Radiol* 1995;36:19-26.
10. Lund PJ, Heikal A, Maricic MJ, Krupinski EA, Williams CS. Ultrasonographic imaging of the hand and wrist in rheumatoid arthritis. *Skeletal Radiol* 1995;24:591-6.
11. Alasaarela E, Suramo I, Tervonen O, Lähde S, Takalo R, Hakala M. Evaluation of humeral head erosions in rheumatoid arthritis: a comparison of ultrasonography, magnetic resonance imaging, computed tomography and plain radiography. *Br J Rheumatol* 1998;37:1152-6.
12. McGonagle D, Gibbon W, O'Connor P, Blythe D, Wakefield R, Green M, et al. A preliminary study of ultrasound aspiration of bone erosion in early rheumatoid arthritis. *Rheumatology* 1999;38:329-31.
13. Backhaus M, Kamradt T, Sandrock D, Loreck D, Fritz J, Wolf KJ, et al. Arthritis of the finger joints: a comprehensive approach comparing conventional radiography, scintigraphy, ultrasound, and contrast-enhanced magnetic resonance imaging. *Arthritis Rheum* 1999;42:1232-45.
14. Wakefield RJ, Gibbon WW, Conaghan PG, O'Connor P, McGonagle D, Pease C, et al. The value of sonography in the detection of bone erosions in patients with rheumatoid arthritis: a comparison with conventional radiography. *Arthritis Rheum* 2000;43:2762-70.
15. Grassi W, Filippucci E, Farina A, Salaffi F, Cervini C. Ultrasonography in the evaluation of bone erosions. *Ann Rheum Dis* 2001;60:98-103.
16. Klocke R, Glew D, Cox N, Blake DR. Sonographic erosions of the rheumatoid little toe. *Ann Rheum Dis* 2001;60:896-7.
17. Naranjo A, Marrero-Pulido T, Ojeda S, Francisco F, Erasquin C, Rúa-Figueroa I, et al. Abnormal sonographic findings in the asymptomatic arthritic shoulder. *Scand J Rheumatol* 2002;31:17-21.
18. Frediani B, Falsetti P, Storri L, Allegri A, Bisogno S, Baldi F, et al. Ultrasound and clinical evaluation of quadriceps tendon enthesitis in patients with psoriatic arthritis and rheumatoid arthritis. *Clin Rheumatol* 2002;21:203-6.
19. Frediani B, Falsetti P, Storri L, Allegri A, Bisogno S, Baldi F, et al. Ultrasound and clinical evaluation of quadriceps tendon enthesitis in patients with psoriatic arthritis and rheumatoid arthritis. *Clin Rheumatol* 2002;21:294-8.
20. Backhaus M, Burmester GR, Sandrock D, Loreck D, Hess D, Scholz A, et al. Prospective two year follow up study comparing novel and conventional imaging procedures in patients with arthritic finger joints. *Ann Rheum Dis* 2002;61:895-904.
21. Weidekamm C, Köller M, Weber M, Kainberger F. Diagnostic value of high-resolution B-mode and doppler sonography for imaging of hand and finger joints in rheumatoid arthritis. *Arthritis Rheum* 2003;48:325-33.
22. Szkudlarek M, Court-Payen M, Jacobsen S, Klarlund M, Thomsen HS, Østergaard M. Interobserver agreement in ultrasonography of the finger and toe joints in rheumatoid arthritis. *Arthritis Rheum* 2003;48:955-62.
23. Lerch K, Borisch N, Paetzel C, Grifka J, Hartung W. Sonographic evaluation of the elbow in rheumatoid arthritis: a classification of joint destruction. *Ultrasound Med Biol* 2003;29:1131-5.
24. Falsetti P, Frediani B, Fioravanti A, Acciai C, Baldi F, Filippou G, et al. Sonographic study of calcaneal entheses in erosive osteoarthritis, nodal osteoarthritis, rheumatoid arthritis and psoriatic arthritis. *Scand J Rheumatol* 2003;32:229-34.
25. Hermann KG, Backhaus M, Schneider U, Labs K, Loreck D, Zühlsdorf S, et al. Rheumatoid arthritis of the shoulder joint: comparison of conventional radiography, ultrasound, and dynamic contrast-enhanced magnetic resonance imaging. *Arthritis Rheum* 2003;48:3338-49.
26. Lopez-Ben R, Bernreuter WK, Moreland LW, Alarcón GS. Ultrasound detection of bone erosions in rheumatoid arthritis: a comparison to routine radiographs of the hands and feet. *Skeletal Radiol* 2004;33:80-4.
27. Hoving JL, Buchbinder R, Hall S, Lawler G, Coombs P, McNealy S, et al. A comparison of magnetic resonance imaging, sonography, and radiography of the hand in patients with early rheumatoid arthritis. *J Rheumatol* 2004;31:663-75.
28. Szkudlarek M, Narvestad E, Klarlund M, Court-Payen M, Thomsen HS, Østergaard M. Ultrasonography of the metatarsophalangeal joints in rheumatoid arthritis: comparison with magnetic resonance imaging, conventional radiography, and clinical examination. *Arthritis Rheum* 2004;50:2103-12.
29. Magnani M, Salizzoni E, Mulè R, Fusconi M, Meliconi R, Galletti S. Ultrasonography detection of early bone erosions in the metacarpophalangeal joints of patients with rheumatoid arthritis. *Clin Exp Rheumatol* 2004;22:743-8.
30. Szkudlarek M, Klarlund M, Narvestad E, Court-Payen M, Strandberg C, Jensen KE, et al. Ultrasonography of the metacarpophalangeal and proximal interphalangeal joints in rheumatoid arthritis: a comparison with magnetic resonance imaging, conventional radiography and clinical examination. *Arthritis Res Ther* 2006;8:R52.
31. Scheel AK, Hermann KG, Ohrndorf S, Werner C, Schirmer C, Detert J, et al. Prospective 7 year follow up imaging study comparing radiography, ultrasonography, and magnetic resonance imaging in rheumatoid arthritis finger joints. *Ann Rheum Dis* 2006;65:595-600.
32. Bajaj S, Lopez-Ben R, Oster R, Alarcón GS. Ultrasound detects rapid progression of erosive disease in early rheumatoid arthritis: a prospective longitudinal study. *Skeletal Radiol* 2007;36:123-8.
33. Bowen CJ, Dewbury K, Sampson M, Sawyer S, Burridge J, Edwards CJ, et al. Musculoskeletal ultrasound imaging of the plantar forefoot in patients with rheumatoid arthritis: inter-observer agreement between a podiatrist and a radiologist. *J Foot Ankle Res* 2008;1:5.
34. Chaiamnuay S, Lopez-Ben R, Alarcón GS. Ultrasound of target joints for the evaluation of possible inflammatory arthropathy: associated clinical factors and diagnostic accuracy. *Clin Exp Rheumatol* 2008;26:875-80.
35. Filippucci E, Meenagh G, Delle Sedie A, Salaffi F, Riente L, Iagnocco A, et al. Ultrasound imaging for the rheumatologist. XX. Sonographic assessment of hand and wrist joint involvement in rheumatoid arthritis: comparison between two- and three-dimensional ultrasonography. *Clin Exp Rheumatol* 2009;27:197-200.
36. Reynolds PP, Heron C, Pilcher J, Kiely PD. Prediction of erosion

- progression using ultrasound in established rheumatoid arthritis: a 2-year follow-up study. *Skeletal Radiol* 2009;38:473-8.
37. Sheane BJ, Beddy P, O'Connor M, Miller S, Cunnane G. Targeted ultrasound of the fifth metatarsophalangeal joint in an early inflammatory arthritis cohort. *Arthritis Rheum* 2009;61:1004-8.
  38. Hammer HB, Haavardsholm EA, Bøyesen P, Kvien TK. Bone erosions at the distal ulna detected by ultrasonography are associated with structural damage assessed by conventional radiography and MRI: a study of patients with recent onset rheumatoid arthritis. *Rheumatology* 2009;48:1530-2.
  39. Naredo E, Möller I, Acebes C, Batlle-Gualda E, Brito E, de Agustín JJ, et al. Three-dimensional volumetric ultrasonography. Does it improve reliability of musculoskeletal ultrasound? *Clin Exp Rheumatol* 2010;28:79-82.
  40. Sanja MR, Mirjana ZS. Ultrasonographic study of the painful shoulder in patients with rheumatoid arthritis and patients with degenerative shoulder disease. *Acta Reumatol Port* 2010;35:50-8.
  41. Koski JM, Alasaarela E, Soini I, Kempainen K, Hakulinen U, Heikkinen JO, et al. Ability of ultrasound imaging to detect erosions in a bone phantom model. *Ann Rheum Dis* 2010;69:1618-22.
  42. Botar-Jid C, Bolboaca S, Fodor D, Bocsa C, Tamas MM, Micu M, et al. Gray scale and power Doppler ultrasonography in evaluation of early rheumatoid arthritis. *Med Ultrason* 2010;12:300-5.
  43. Gutierrez M, Filippucci E, Ruta S, Salaffi F, Blasetti P, Di Geso L, et al. Inter-observer reliability of high-resolution ultrasonography in the assessment of bone erosions in patients with rheumatoid arthritis: experience of an intensive dedicated training programme. *Rheumatology* 2011;50:373-80.
  44. Døhn UM, Ejbjerg B, Boonen A, Hetland ML, Hansen MS, Knudsen LS, et al. No overall progression and occasional repair of erosions despite persistent inflammation in adalimumab-treated rheumatoid arthritis patients: results from a longitudinal comparative MRI, ultrasonography, CT and radiography study. *Ann Rheum Dis* 2011;70:252-8.
  45. Filer A, de Pablo P, Allen G, Nightingale P, Jordan A, Jobanputra P, et al. Utility of ultrasound joint counts in the prediction of rheumatoid arthritis in patients with very early synovitis. *Ann Rheum Dis* 2011;70:500-7.
  46. Finzel S, Ohrndorf S, Englbrecht M, Stach C, Messerschmidt J, Schett G, et al. A detailed comparative study of high-resolution ultrasound and micro-computed tomography for detection of arthritic bone erosions. *Arthritis Rheum* 2011;63:1231-6.
  47. Ceccarelli F, Perricone C, Fabris M, Alessandri C, Iagnocco A, Fabro C, et al. Transforming growth factor  $\beta$  869C/T and interleukin 6 -174G/C polymorphisms relate to the severity and progression of bone-erosive damage detected by ultrasound in rheumatoid arthritis. *Arthritis Res Ther* 2011;13:R111.
  48. Iagnocco A, Perella C, D'Agostino MA, Sabatini E, Valesini G, Conaghan PG. Magnetic resonance and ultrasonography real-time fusion imaging of the hand and wrist in osteoarthritis and rheumatoid arthritis. *Rheumatology* 2011;50:1409-13.
  49. Amin MF, Ismail FM, El Shereef RR. The role of ultrasonography in early detection and monitoring of shoulder erosions, and disease activity in rheumatoid arthritis patients; comparison with MRI examination. *Acad Radiol* 2012;19:693-700.
  50. Broll M, Albrecht K, Tarner I, Müller-Ladner U, Strunk J. Sensitivity and specificity of ultrasonography and low-field magnetic resonance imaging for diagnosing arthritis. *Clin Exp Rheumatol* 2012;30:543-7.
  51. Ohrndorf S, Fischer IU, Kellner H, Strunk J, Hartung W, Reiche B, et al. Reliability of the novel 7-joint ultrasound score: results from an inter- and intraobserver study performed by rheumatologists. *Arthritis Care Res* 2012;64:1238-43.
  52. Macchioni P, Magnani M, Mulè R, Galletti S, Catanoso M, Pignotti E, et al. Ultrasonographic predictors for the development of joint damage in rheumatoid arthritis patients: a single joint prospective study. *Clin Exp Rheumatol* 2013;31:8-17.
  53. Chávez-López MA, Hernández-Díaz C, Moya C, Pineda C, Ventura-Ríos L, Möller I, et al. Inter- and intra-observer agreement of high-resolution ultrasonography and power Doppler in assessment of joint inflammation and bone erosions in patients with rheumatoid arthritis. *Rheumatol Int* 2013;33:173-7.
  54. Schmidt WA, Schicke B, Ostendorf B, Scherer A, Krause A, Walther M. Low-field MRI versus ultrasound: Which is more sensitive in detecting inflammation and bone damage in MCP and MTP joints in mild or moderate rheumatoid arthritis? *Clin Exp Rheumatol* 2013;31:91-6.
  55. Naredo E, Acebes C, Brito E, de Agustín JJ, de Miguel E, Mayordomo L, et al; Ultrasound School of the Spanish Society of Rheumatology. Three-dimensional volumetric ultrasound: a valid method for blinded assessment of response to therapy in rheumatoid arthritis. *J Rheumatol* 2013;40:253-60.
  56. Døhn UM, Terslev L, Szkudlarek M, Hansen MS, Hetland ML, Hansen A, et al. Detection, scoring and volume assessment of bone erosions by ultrasonography in rheumatoid arthritis: comparison with CT. *Ann Rheum Dis* 2013;72:530-4.
  57. Funck-Brentano T, Gandjbakhch F, Etchepare F, Jousse-Joulin S, Miquel A, Cyteval C, et al. Prediction of radiographic damage in early arthritis by sonographic erosions and power Doppler signal: a longitudinal observational study. *Arthritis Care Res* 2013; 65:896-902.
  58. Backhaus TM, Ohrndorf S, Kellner H, Strunk J, Hartung W, Sattler H, et al. The US7 score is sensitive to change in a large cohort of patients with rheumatoid arthritis over 12 months of therapy. *Ann Rheum Dis* 2013;72:1163-9.
  59. Rodríguez-Henríquez P, Solano C, Peña A, León-Hernández S, Hernández-Díaz C, Gutiérrez M, et al. Sternoclavicular joint involvement in rheumatoid arthritis: clinical and ultrasound findings of a neglected joint. *Arthritis Care Res* 2013;65:1177-82.
  60. Kawashiri SY, Suzuki T, Nakashima Y, Horai Y, Okada A, Iwamoto N, et al. Ultrasonographic examination of rheumatoid arthritis patients who are free of physical synovitis: power Doppler subclinical synovitis is associated with bone erosion. *Rheumatology* 2014;53:562-9.
  61. Zayat AS, Ellegaard K, Conaghan PG, Terslev L, Hensor EM, Freeston JE, et al. The specificity of ultrasound-detected bone erosions for rheumatoid arthritis. *Ann Rheum Dis* 2015;74:897-903.
  62. Ohrndorf S, Messerschmidt J, Reiche BE, Burmester GR, Backhaus M. Evaluation of a new erosion score by musculoskeletal ultrasound in patients with rheumatoid arthritis: is US ready for a new erosion score? *Clin Rheumatol* 2014;33:1255-62.
  63. Tâmaş MM, Filippucci E, Becciolini A, Gutierrez M, Di Geso L, Bonfiglioli K, et al. Bone erosions in rheumatoid arthritis: ultrasound findings in the early stage of the disease. *Rheumatology* 2014;53:1100-7.
  64. van der Heijde DM. Plain X-rays in rheumatoid arthritis: overview of scoring methods, their reliability and applicability. *Baillieres Clin Rheumatol* 1996;10:435-53.
  65. Baillet A, Gaujoux-Viala C, Mouterde G, Pham T, Tebib J, Saraux A, et al. Comparison of the efficacy of sonography, magnetic resonance imaging and conventional radiography for the detection of bone erosions in rheumatoid arthritis patients: a systematic review and meta-analysis. *Rheumatology* 2011;50:1137-47.

## Correction

Summary Findings of a Systematic Literature Review of the Ultrasound Assessment of Bone Erosions in Rheumatoid Arthritis

Szkudlarek M, Terslev L, Wakefield RJ, Backhaus M, Balint PV, Bruyn GA, Filippucci E, Gandjbakhch F, Iagnocco A, Mandl P, et al. Summary findings of a systematic literature review of the ultrasound assessment of bone erosions in rheumatoid arthritis. *J Rheumatol* 2016;43:12-21. The affiliation of co-author Peter Mandl should be Division of Rheumatology, Medical University of Vienna, Vienna, Austria.

doi:10.3899/jrheum.141416.C1

---