

Case Report and Literature Review: Quinacrine-induced Cholestatic Hepatitis in Undifferentiated Connective Tissue Disease

To the Editor:

A 45-year-old African American woman presented to the rheumatology clinic with a history of undifferentiated connective tissue disease (UCTD), manifesting as biopsy-proven urticarial dermatitis, inflammatory arthritis,

fatigue, and weight loss in the setting of positive immunofluorescence antinuclear antibodies (1:160, speckled pattern), anti-RNP, anti-Sm/RNP, and antichromatin antibodies. She started treatment with quinacrine 100 mg per day for her disease. Quinacrine was chosen because she developed a pruritic rash after taking hydroxychloroquine for 2 months. At the time she started treatment with quinacrine, she was also receiving 5 mg of prednisone, diphenhydramine as needed, ergocalciferol, and norgestimate-ethinyl estradiol. All of these were longterm medications.

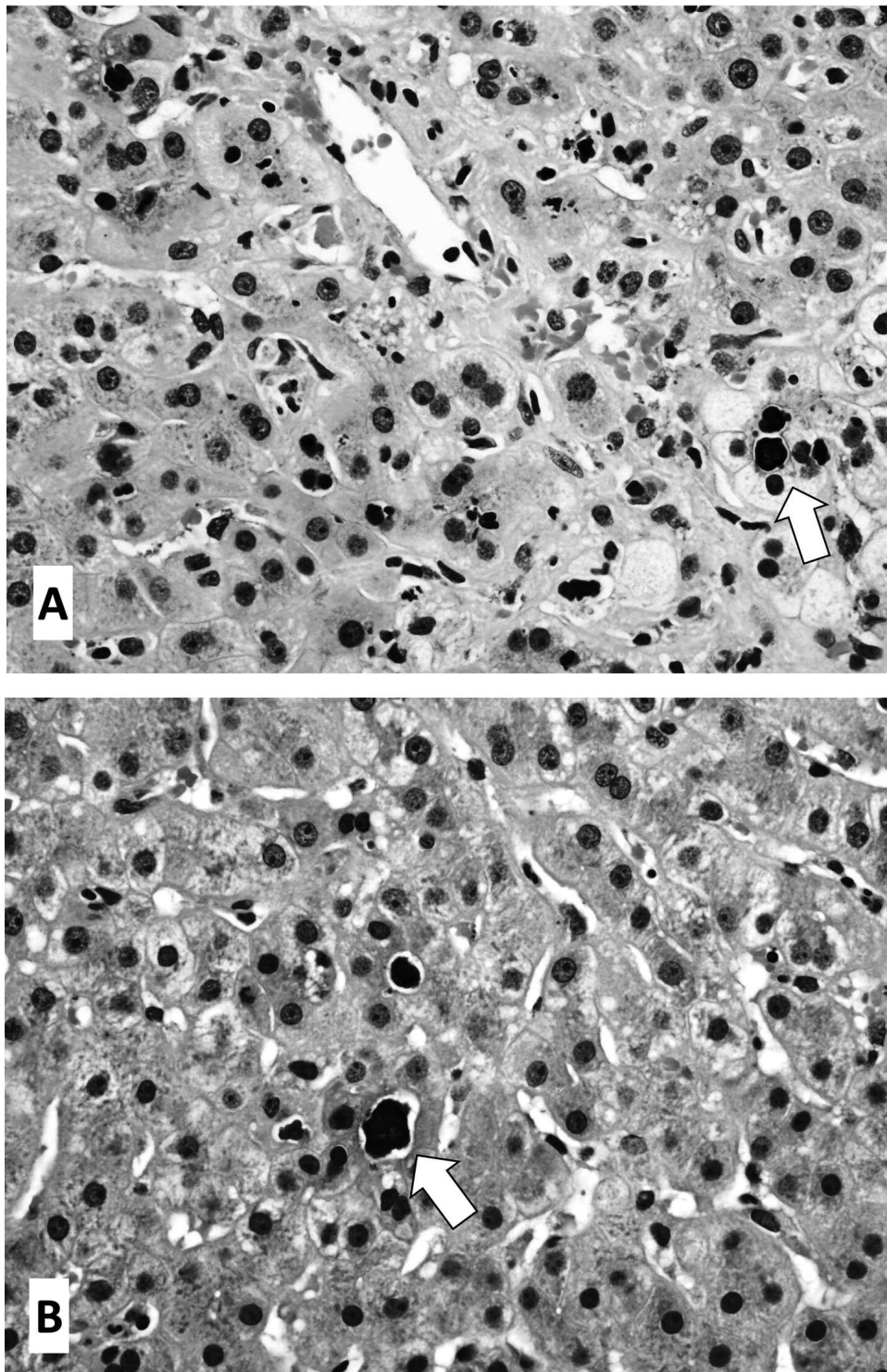


Figure 1. A. Liver biopsy H&E stain 400x revealing a central vein with canalicular cholestasis (arrow) without periportal cholestatic ductular reaction. B. Liver biopsy H&E stain 400x revealing bile plugs within the canaliculae (arrow) indicating canalicular cholestasis.

Four weeks after starting quinacrine, she presented to the emergency department with generalized fatigue, loss of appetite, nausea, diffuse abdominal pain, scleral icterus, and dark tea-colored urine. She reported no history of new medications, supplements, or alcohol intake. Laboratory investigations demonstrated aspartate aminotransferase (AST) 629 (8–30 IU/l), alanine aminotransferase (ALT) 913 (≤ 35 IU/l), alkaline phosphatase 914 (30–130 IU/l), total bilirubin 11.0 (0.2–1.2 mg/dl), direct bilirubin 9.0, and indirect bilirubin 2.0. Abdominal ultrasound was unremarkable. An interim diagnosis of acute cholestatic hepatitis was given. Infectious and autoimmune hepatitis investigations were negative. The hepatology service felt the liver injury was secondary to a mixed hepatocellular and cholestatic pattern in the context of recently starting quinacrine.

The patient was discharged from the hospital, but a week after discharge, her liver function tests worsened with an AST level of 540, ALT 856, alkaline phosphatase 1300, and total bilirubin 22.9. She underwent a liver biopsy that revealed canalicular cholestasis without comparable periportal cholestatic ductular reaction, strongly suggesting a metabolic cause such as drug therapy. A patchy loss of pericentral hepatocytes with stellate sinusoidal fibrosis indicating prior central zone injury was also demonstrated (Figure 1). The Roussel Uclaf Causality Assessment Method¹ scale was calculated to be 6, indicating probable causal relationship between the offending drug and liver damage. In the context of the clinical history, laboratory investigations, and liver biopsy findings, the diagnosis of quinacrine-induced cholestatic hepatitis was made. Her bilirubin and transaminases did not peak until 3 weeks after she initially developed the cholestatic jaundice (Table 1). All of the medications were held during this time, other than the 5 mg of prednisone that she had been taking for the last year. Liver enzymes normalized over a period of about 5 months after stopping the medication.

Quinacrine is a synthetic, acridine-based drug developed in the 1930s. It is an antimalarial that has demonstrated effectiveness in controlling refractory lupus erythematosus². Quinacrine is used by both dermatologists and rheumatologists, although less commonly than chloroquine and hydroxychloroquine. The highest concentrations of this medication are found in the liver, spleen, lungs, and adrenal glands, with liver concentrations reaching 20,000 times that of plasma³. Although small amounts are excreted in bile, sweat, and saliva, the major route of quinacrine elimination is through the renal system. In terms of side effects, persistent abdominal cramping or diarrhea have been reported. Longterm, high-dose antimalarial therapy was occasionally reported to be associated with reversible hepatitis, presumably because of its tendency to concentrate in the liver⁴. Transient acute quinacrine hepatitis has been reported on 1 occasion in 1985 in a patient with UCTD; however, this was attributed to doses 3 times that of the recommended dose⁵. It has been reported that antimalarial therapy with chloroquine can lead to a massive porphyrinuria with fever, nausea, and increase in hepatic enzymes^{6,7}. Occasional cases of hepatic necrosis when chloroquine is prescribed in full dosage have also been reported^{6,7}. Another side

effect associated with quinacrine, seen in malaria prophylaxis, is bull's-eye maculopathy⁸. Toxic psychosis because of quinacrine treatment has also been reported. This is an infrequent but serious psychiatric complication⁹.

To our knowledge this is the first reported case of quinacrine-induced cholestatic hepatitis in UCTD. This case demonstrates a potentially new and serious complication of quinacrine use, of which physicians need to be aware.

RAJAIE NAMAS, MD; APRIL MARQUARDT, MD, Department of Internal Medicine, Division of Rheumatology, University of Michigan, Ann Arbor, Michigan, USA. Address correspondence to Dr. R. Namas, Department of Internal Medicine, Division of Rheumatology, University of Michigan, Ann Arbor, Michigan 48109, USA.
E-mail: rnamas@med.umich.edu

REFERENCES

1. Danan G, Benichou C. Causality assessment of adverse reactions to drugs—I. A novel method based on the conclusions of international consensus meetings: application to drug-induced liver injuries. *J Clin Epidemiol* 1993;46:1323-30.
2. Wallace DJ. The use of quinacrine (Atabrine) in rheumatic diseases: a reexamination. *Semin Arthritis Rheum* 1989;18:282-96.
3. Shannon JA, Earle DP, Brodie BB, Taggart JV, Berliner RW; The Resident Staff Of The Research Service. The pharmacological basis for the rational use of Atabrine in the treatment of malaria. *J Pharmacol Exp Ther* 1944;81:307-30.
4. Ehsanian R, Van Waes C, Feller SM. Beyond DNA binding - a review of the potential mechanisms mediating quinacrine's therapeutic activities in parasitic infections, inflammation, and cancers. *Cell Commun Signal* 2011;9:13.
5. Gibb W, Isenberg DA, Snaith ML. Mepacrine induced hepatitis. *Ann Rheum Dis* 1985;44:861-2.
6. Liu AC. Hepatotoxic reaction to chloroquine phosphate in a patient with previously unrecognized porphyria cutanea tarda. *West J Med* 1995;162:548-51.
7. Haendchen L, Jordão JM, Haider O, Araújo F, Skare TL. Porphyrin cutanea tarda and systemic lupus erythematosus. *An Bras Dermatol* 2011;86:173-5.
8. Browning DJ. Bull's-eye maculopathy associated with quinacrine therapy for malaria. *Am J Ophthalmol* 2004;137:577-9.
9. Lindenmayer JP, Vargas P. Toxic psychosis following use of quinacrine. *J Clin Psychiatry* 1981;42:162-4.

J Rheumatol 2015;42:7; doi:10.3899/jrheum.150050

Table 1. Liver function test (LFT) values at beginning of treatment with quinacrine, while under treatment, and after treatment was stopped. Dates are all in 2014.

Variables	Medication First Administered		Values of LFT While Patient Took Medication				Values of LFT after Medication Stopped		
	4/21	6/26	6/27	7/1	7/11	7/22	8/4	9/10	10/15
Protein, 6.0–8.3 g/dl	8.0	8.3	6.7	7.6	7.9	6.9	7.3	7.8	8.4 (H)
Albumin, 3.5–4.9 g/dl	4.5	4.4	3.5	4.0	4.1	3.9	4.2	4.5	5.1 (H)
AST, 8–30 IU/l	26	629 (H)	592 (H)	541 (H)	597 (H)	474 (H)	256 (H)	114 (H)	66 (H)
ALT, ≤ 35 IU/l	16	913 (H)	805 (H)	781 (H)	901 (H)	832 (H)	381 (H)	150 (H)	84 (H)
Alkaline phosphatase, 30–130 IU/l	51	914 (H)	809 (H)	1172 (H)	1646 (H)	1471 (H)	1083 (H)	446 (H)	165 (H)
Bilirubin, direct, 0.0–0.3 mg/dl			8.3 (H)				7.6 (H)	1.8 (H)	0.7 (H)
Bilirubin, total, 0.2–1.2 mg/dl	0.3	11.0 (H)	9.7 (H)	18.1 (H)	26.5 (H)	16.1 (H)	8.8 (H)	2.0 (H)	0.9

AST: aspartate aminotransferase; ALT: alanine aminotransferase; H: high.