



joint destruction is one of the most important objectives of JIA treatment. In a previous study<sup>5</sup>, we found a dramatic improvement in radiological damage even in the large weight-bearing joints of patients with sJIA following TCZ treatment. However, several patients showed radiological progression despite improvements in clinical and laboratory findings. Because our previous study involved a small number of cases, in the current study we performed clinical, hematological, and radiological examinations of 40 patients treated with TCZ.

## MATERIALS AND METHODS

**Patients and clinical responses to TCZ.** This is a retrospective study of radiological evaluations in previous clinical trials (NCT00144599 and NCT00144612) at our institution<sup>2,3</sup>. It was approved by the Institutional Review Board of Yokohama City University, Yokohama, Japan, and all participants provided written informed consent. Sixty patients with refractory sJIA, including 56 patients in clinical trials and 4 patients in clinical practice, aged 2–19 years, who fulfilled the International League of Associations for Rheumatology criteria<sup>1</sup>, were treated with TCZ between 2002 and 2012. Radiographs either before or during TCZ treatment were missing in 20 patients in trials; therefore, the remaining 40 patients were enrolled whose serial radiographs before and during TCZ treatment were available (Figure 1). If patients met the following criteria<sup>6</sup> despite receiving conventional treatment, they were considered to have refractory sJIA and TCZ was indicated: (1) persistent inflammation and clinical symptoms such as fever, rash, and arthritis; (2) prolonged use of high-dose glucocorticoids (0.2 mg/kg<sup>-1</sup>/day<sup>-1</sup> or more of prednisolone) and severe adverse reactions induced by glucocorticoids; and (3) use of high-dose glucocorticoids to suppress inflammation and clinical symptoms to render the disease inactive, but which could lead to glucocorticoid-induced adverse reactions. All patients received 8 mg/kg of intravenous TCZ every 2 weeks, which is the fixed dose in our clinical trial and practice.

Patient characteristics were reviewed, and their clinical data before treatment and at subsequent visits when the radiographs were obtained were examined, including the active joint count; number of joints with limited range of motion; and laboratory markers such as peripheral white

blood cell (WBC) count, serum C-reactive protein (CRP), erythrocyte sedimentation rate (ESR), matrix metalloproteinase-3 (MMP-3), and fibrin degradation product-E (FDP-E). Glucocorticoid doses were also evaluated. American College of Rheumatology Pediatric (ACR Pedi) 30, 50, and 70 responses (i.e., at least 3 of 6 ACR Pedi variables improved by at least 30%, 50%, and 70%, respectively, with no more than 1 variable worsening by more than 30%<sup>7</sup>) were evaluated for 32 patients at 4, 12, 24, and 48 weeks during TCZ treatment.

**Radiological assessment.** Radiographs of 12 joints including the shoulders, elbows, wrists or hands, hips, knees, and ankles were obtained within 2 weeks before TCZ was started and at least once during TCZ treatment. If radiographs were obtained several times during TCZ treatment, we evaluated the radiograph obtained at the last followup. Because of the retrospective nature of the study, the timepoints at which radiographs were obtained during TCZ treatment varied from 1 to 10 years, i.e., 1 year in 3 cases, 2–4 years in 17 cases, and 5–10 years in 20 cases (overall mean, 4.5 years). The followup period during TCZ treatment was the duration between the times at which the first and last radiographs were obtained. We used the Poznanski method<sup>8</sup>, modified Larsen method<sup>9</sup>, and Childhood Arthritis Radiographic Score of the Hip (CARSH)<sup>10</sup> to evaluate radiographs of the hands and large joints.

The Poznanski method was developed to assess the radiological progression in the wrists of patients with JIA. The radiometacarpal (RM) and second metacarpal bone lengths were measured on right and left hand radiographs, and the number of SD between the expected and observed RM length was calculated. This method is independent of the degree of ossification, and negative scores reflect the degree of damage.

The modified Larsen scoring method is one of the most commonly used methods to assess the degree of damage in the large joints of patients with adult rheumatoid arthritis. Radiographs of the right and left hands and large joints (i.e., shoulders, elbows, hips, knees, and ankles) were examined to evaluate the degree of joint destruction. The grading scale reflects the degree of progression and ranges from 0 (normal joint) to 5 (mutilating changes) for each joint. There were 24 areas for each patient, including 16 in the hands and 8 in the wrists. Thus, the total modified Larsen score of the hands and the 10 large joints ranged from 0 to 120 and from 0 to 50, respectively. We used standard radiographs of children of different ages for each joint. If the patient was able to stand unaided, standing radiographs were used to evaluate the weight-bearing joints. Radiological analyses were

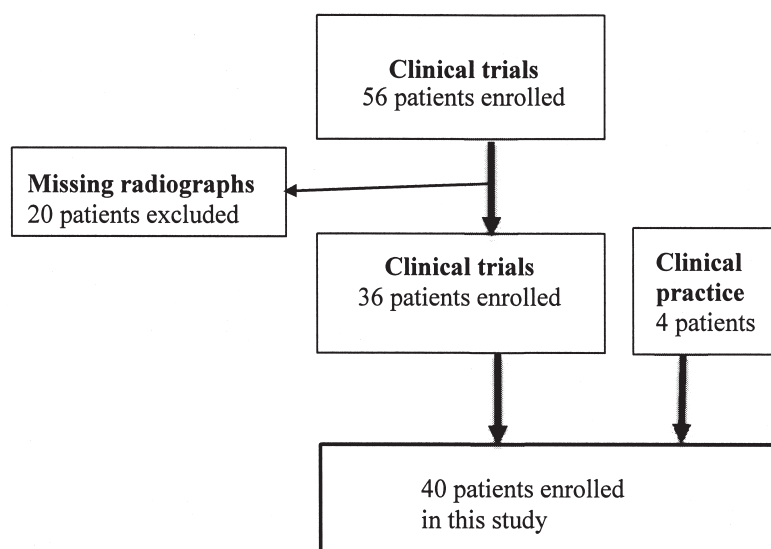


Figure 1. Flow chart for patient inclusion. Among 56 patients in trials, radiographs either before or during tocilizumab treatment were missing in 20 patients. Therefore, the remaining 36 patients in trials and 4 patients in clinical practice were assessed in the current study.

performed in a blinded fashion independently by 2 observers (CA and HC) twice, and the results were averaged.

The CARSH was developed to assess radiographic damage in the hip and its progression in patients with JIA. The following radiographic abnormalities were assessed and scored: joint space narrowing (range: 0–3), erosion (0–4), growth abnormality (0–2), subchondral cysts (0–2), malalignment (0–2), sclerosis of the acetabulum (0–1), and avascular necrosis of the femoral head (0 or 2). The maximum possible score for both hips was 32, and increased scores reflect the degree of progression. We also assessed the correlation between the modified Larsen score of the hips and the CARSH.

Damage to the large joints involved in sJIA, especially the weight-bearing joints, causes impairment in activities of daily living. Because we aimed to identify the factors that influence disease progression in the large joints in patients with sJIA, we divided the patients into 3 groups according to the change in the modified Larsen score of the large joints after TCZ treatment. We then compared the clinical characteristics and laboratory data among these groups. Groups A, B, and C consisted of patients whose modified Larsen score improved (decreased score), remained unchanged, or worsened (increased score), respectively, during TCZ treatment.

**Statistical analysis.** A Wilcoxon t test was used to assess the differences in clinical data before and after treatment. A Mann-Whitney U test with a Bonferroni correction was used to assess the differences among the 3 groups. A p value of < 0.05 was considered significant. Interobserver and intraobserver agreement of the modified Larsen (range: 0–5 for each joint) and Poznanski scores were analyzed, and a weighted κ index was used to investigate the level of agreement. We also performed logistic regression analysis to determine the characteristics and laboratory data that were risk factors for joint progression. Statistical analyses were performed using SAS 9.3 for Windows (SAS Inc.) and SPSS 16.0J (SPSS Inc.).

## RESULTS

**Characteristics of patients and clinical responses.** Our retrospective study included 40 patients (21 boys, 19 girls). The patients' baseline characteristics are shown in Table 1. The mean age at sJIA onset was 4.7 years (range, 0.4–13.6 yrs), mean age at the start of TCZ treatment was 9.2 years (range, 2.0–18.6 yrs), and mean followup period during TCZ treatment (i.e., the duration between the start of treatment and the time the last radiographs were obtained) was 4.5 years (range, 0.9–9.7 yrs). The mean period from sJIA onset to the start of TCZ treatment (i.e., disease duration) was 4.5 years (range, 0.4–16.1 yrs). Methotrexate (MTX) was used in 7 cases before TCZ treatment, and no patient had received prior biological therapy.

Table 2 shows the response variables for the patients. The mean active joint count was decreased after TCZ treatment; however, the mean number of joints with limited motion did not change. After TCZ treatment, the mean WBC count, CRP, ESR, MMP-3, FDP-E, and glucocorticoid dose values were significantly decreased, and 14 patients (35%) discontinued glucocorticoid treatment. Among 32 patients, ACR Pedi 30, 50, and 70 responses were achieved by 75%, 66%, and 47% at 4 weeks; 90%, 84%, and 68% at 12 weeks; 91%, 88%, and 78% at 24 weeks; and 91%, 88%, and 81% at 48 weeks, respectively.

**Radiological assessment.** We examined radiographs of both hands to determine the Poznanski score and modified Larsen score in 38 cases, and radiographs of the large joints to determine the modified Larsen score and CARSH in 40 cases. The mean Poznanski score of 76 hands increased (improved) from  $-1.5 \pm 2.0$  before TCZ treatment to  $-1.1 \pm 2.2$  at the final followup ( $p = 0.19$ ), whereas the mean modified Larsen score of the hands increased (worsened) significantly from  $7.0 \pm 15.7$  before TCZ treatment to  $10.0 \pm 15.1$  at the final followup ( $p < 0.01$ ). The mean modified Larsen score of the 398 large joints evaluated increased (worsened) from  $5.9 \pm 9.5$  before TCZ treatment to  $6.8 \pm 9.2$  at the final followup ( $p = 0.190$ ).

The changes in Larsen grade of joints grouped according to the initial Larsen grade are shown in Figure 2. Before TCZ treatment, 257 joints (65%) were categorized as grade 0; 79% of these joints (203/257) were unchanged after treatment. Of the 71 joints classified as grade I before TCZ treatment, 73% (52/71) improved or were unchanged. Of the 70 joints categorized as grade II to V before TCZ treatment, 94% (65/70) improved or were unchanged. When we compared the change in the Larsen score before and after TCZ treatment for specific joints, only the Larsen score of the hips increased (worsened) significantly from  $0.83 \pm 0.14$  before treatment to  $1.36 \pm 0.18$  after treatment ( $p = 0.001$ ). There was no significant difference before and after TCZ treatment in the Larsen score for the shoulders (0.66 and 0.69), elbows (0.41 and 0.38), knees (0.64 and 0.60), or ankles (0.48 and 0.41).

Table 1. Characteristics of the patients in each of the 3 groups. Data are mean (SD) unless otherwise indicated.

	Total	Group A (Improved)	Group B (Unchanged)	Group C (Worsened)
Cases, n	40	11	8	21
Sex, M/F, n	21/19	6/5	3/5	12/9
Age at onset, yrs	4.7 (3.1)	3.2 (2.6)	3.7 (1.5)	5.7 (3.4)
Duration of disease, yrs	4.5 (3.8)	6.1 (2.0)	5.9 (5.9)	3.2 (3.3)
Age at start of TCZ therapy, yrs	9.2 (3.9)	9.4 (2.9)	9.5 (4.4)	8.9 (4.3)
Duration of TCZ therapy, yrs	4.5 (2.3)	5.3 (2.9)	4.3 (1.2)	3.8 (1.9)
Previous MTX therapy, n	7	4	0	3
Previous glucocorticoid dosage, mg/day	18.1 (10.1)	13.8 (9.0)	14.9 (6.0)	25.2 (10.9)
Modified Larsen score for the large joints	5.9 (9.5)	11.0 (9.9)	8.1 (15.6)	2.3 (3.2)

TCZ: tocilizumab; MTX: methotrexate.

Table 2. Response variables for the patients in each of the 3 groups. Data are mean (SD) unless otherwise indicated.

Variables	Total, n = 40		p	Group A (Improved), n = 11		Group B (Unchanged), n = 8		Group C (Worsened), n = 21	
	Before TCZ	After TCZ		Before TCZ	After TCZ	Before TCZ	After TCZ	Before TCZ	After TCZ
Modified Larsen score for the large joints	5.9 (9.5)	6.8 (9.2)	0.190	11.0 (9.9)	3.5 (4.6)	8.1 (16.5)	8.1 (3.2)	2.3 (3.2)	8.1 (7.8)
Active joint count, n	4.6 (1.2)	0.7 (0.3)	< 0.001	3.6 (5.6)	0.0 (0.0)	7.1 (9.1)	0.1 (0.0)	3.4 (4.3)	1.2 (2.2)
Joints with limited motion, n	2.0 (6.0)	1.7 (2.5)	0.154	1.8 (4.5)	1.7 (2.5)	4.6 (11.6)	2.3 (4.2)	1.0 (3.1)	1.4 (1.7)
WBC count, 10 <sup>-3</sup> /mm <sup>3</sup>	15.4 (7.3)	7.9 (4.9)	< 0.001	15.5 (10.3)	6.7 (2.3)	14.6 (6.2)	7.5 (3.3)	15.7 (6.0)	8.7 (6.3)
CRP, mg/dl	5.7 (6.2)	0 (0.1)	< 0.001	4.5 (4.1)	0.0 (0.1)	3.7 (4.2)	0.0 (0.0)	7.1 (7.5)	0.0 (0.0)
ESR, mm/h	42 (22)	3 (2)	< 0.001	41 (14)	4 (4)	30 (10)	3 (2)	42 (27)	2 (1)
MMP-3, ng/ml	338 (205)	180 (300)	< 0.001	321 (205)	49 (37)	335 (163)	86 (91)	348 (229)	278 (382)
FDP-E, ng/ml	222 (216)	81 (47)	< 0.001	220 (152)	70 (20)	205 (121)	75 (17)	229 (278)	89 (61)
Glucocorticoid dosage, mg/day	18.1 (10.1)	3.3 (3.1)	< 0.001	13.8 (9.0)	1.3 (2.7)	14.9 (6.0)	3.1 (3.8)	25.2 (10.9)	4.4 (3.6)
Patients who discontinued glucocorticoids, n		14			7		3		4

p = significance of data before and after tocilizumab treatment in all patients. CRP: C-reactive protein; ESR: erythrocyte sedimentation rate; FDP-E: fibrin degradation product-E; MMP-3: matrix metalloproteinase-3; TCZ: tocilizumab; WBC: white blood cell.

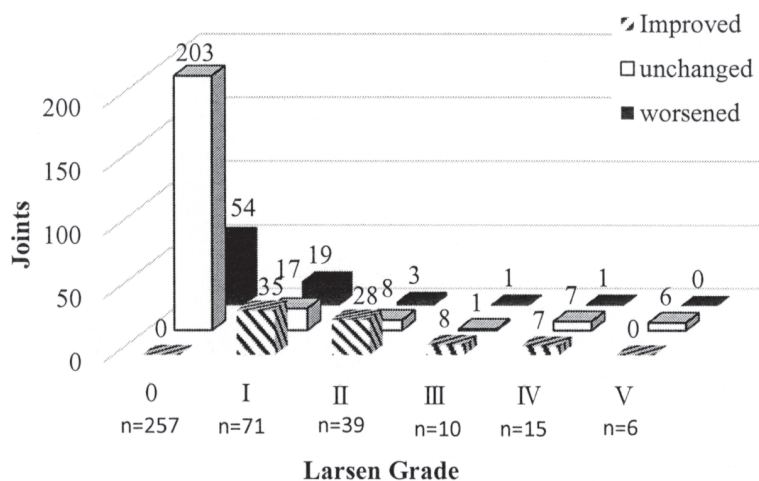


Figure 2. Changes in the Larsen score of joints grouped by the initial Larsen score before tocilizumab (TCZ) treatment. Of the 398 joints evaluated, 257 (65%) were categorized as grade 0 before TCZ treatment. Of the 71 joints categorized as grade I, 52 (73%) improved or remained unchanged. Of the 70 joints categorized as grades II to V, 65 (94%) improved or remained unchanged.

The CARSH increased (worsened) significantly from 3.9 ± 6.7 before TCZ treatment to 6.2 ± 6.7 after treatment (p < 0.01). Following treatment, the joint space narrowing increased from 0.9 ± 1.7 to 1.4 ± 1.7, erosion increased from 1.1 ± 2.1 to 1.7 ± 2.0, growth abnormality increased from 0.6 ± 1.2 to 0.9 ± 1.4, subchondral cysts increased from 0.6 ± 1.3 to 1.2 ± 1.5, malalignment remained unchanged at 0.5 ± 0.8, sclerosis of the acetabulum increased from 0.2 ± 0.5 to 0.4 ± 0.7, and avascular necrosis of the femoral head increased from 0.1 ± 0.6 to 0.3 ± 0.8. Avascular necrosis was observed in both hips of 1 patient before TCZ treatment and

in 5 hips (6%) of 4 patients after treatment. Radiological abnormalities in the hip joints after treatment were observed in 26 cases (65%). The correlation between modified Larsen score of the hip and CARSH was observed (p < 0.001, rs = 0.73412).

We found that the Poznanski score improved in 22 cases (58%), was unchanged in 3 cases (8%), and worsened in 13 cases (34%), whereas the modified Larsen score of the hands improved in 4 cases (11%), was unchanged in 23 cases (61%), and worsened in 13 cases (34%).

The modified Larsen score of the large joints improved in



11 cases (27.5%, Group A), was unchanged in 8 cases (20%, Group B), and worsened in 21 cases (52.5%, Group C). Group A showed significant improvements in the score of each joint after TCZ treatment (shoulder, 1.14 to 0.27; elbow, 0.59 to 0.25; hip, 1.36 to 0.66; knee, 1.45 to 0.23; ankle, 0.98 to 0.34), even in damaged joints categorized as grade III or IV<sup>11</sup>. Group B scores remained unchanged for each joint after TCZ treatment (shoulder, 0.96 to 0.90; elbow, 1.04 to 0.75; hip, 0.81 to 0.91; knee, 0.68 to 0.69; and ankle, 0.81 to 0.81). Group C showed significant deterioration in the score of each joint after TCZ treatment (shoulder, 0.27 to 0.88; elbow, 0.10 to 0.30; hip, 0.55 to 1.89; knee, 0.19 to 0.76; and ankle, 0.05 to 0.31). The representative case in Group C showed marked progression of joint destruction in both hips (Figure 3<sup>11</sup>).

Tables 1 and 2 show the patient demographics and clinical data among the 3 groups at baseline and final followup. At baseline, the mean age at onset was significantly higher in Group C (5.7 yrs) than in Groups A and B (3.4 yrs;  $p = 0.047$ ). The mean disease duration before the start of TCZ treatment in Group C (3.2 yrs) was significantly shorter than that in Groups A and B (5.8 yrs;  $p = 0.006$ ). The mean glucocorticoid dose before the start of TCZ treatment in Group C (25.2 mg/day) was significantly higher than that in Groups A and B (14.3 mg/day;  $p = 0.009$ ). There were no significant differences among the groups in the mean active joint count or number of joints with limited motion before TCZ treatment. At the latest followup, the mean active joint count in Group C (1.19) was significantly higher than that in Groups A and B (0.05;  $p = 0.038$ ). The groups showed no significant differences in laboratory data after TCZ treatment, except for MMP-3 levels, which were significantly higher in Group C (278 mg/dl) than in Groups A and B (65 mg/dl;  $p = 0.045$ ) during treatment.

Table 3 shows the univariate analysis results of the patient characteristics and laboratory data. There was a significant difference in the mean age at onset, mean disease duration, and mean glucocorticoid dose before TCZ treatment. The active joint count and MMP-3 levels after

treatment were not significant. In multivariate analysis, after adjusting for other risk factors, the mean age at onset presented a 1.312 higher risk of progression (95% CI 1.011–1.703;  $p = 0.41$ ) in the large joints.

Interobserver and intraobserver agreements of the modified Larsen method for the large joints were 0.769 and 0.765, respectively, whereas the weighted  $\kappa$  coefficients were good to fair ( $> 0.7$ ) at 0.711 and 0.746, respectively. Interobserver and intraobserver reliability values of the Poznanski score were 0.996 and 0.993, respectively.

## DISCUSSION

We previously reported the clinical efficacy of TCZ in patients with sJIA. In a phase III trial<sup>3</sup>, ACR Pedi 30, 50, and 70 responses were achieved in 98%, 94%, and 90% of patients with sJIA, respectively, by Week 48 under open-label treatment, and most patients treated with TCZ achieved clinical remission. In our current study, ACR Pedi 30, 50, and 70 responses were achieved in 91%, 88%, and 81% of patients, respectively, by 48 weeks, which is comparable to the results of the previous trial.

Several studies<sup>12,13,14,15</sup> have reported the efficacy of anakinra (an IL-1 receptor antagonist) and canakinumab (a selective, fully human, anti-IL-1 $\beta$  monoclonal antibody) in patients with sJIA. Nigrovic, *et al*<sup>12</sup> reported that about 60% of patients attained a complete response to anakinra without escalation of therapy. Gattorno, *et al*<sup>14</sup> described 2 patterns of response to anakinra: 50% of patients had a dramatic response and 50% had an incomplete or no response. Ruperto, *et al*<sup>15</sup> reported that the response rate of canakinumab was similar to that of TCZ. However, no study has investigated the radiological changes after anakinra or canakinumab treatment. Considering the current study results, which show a discrepancy between clinical and radiological responses, radiological evaluations should be performed to determine the efficacy of anakinra or canakinumab treatment.

Several studies have reported retardation in the radiological progression of joint damage in patients with JIA after treatment with MTX or biologics<sup>16,17,18</sup>. Nielsen, *et al*<sup>18</sup>

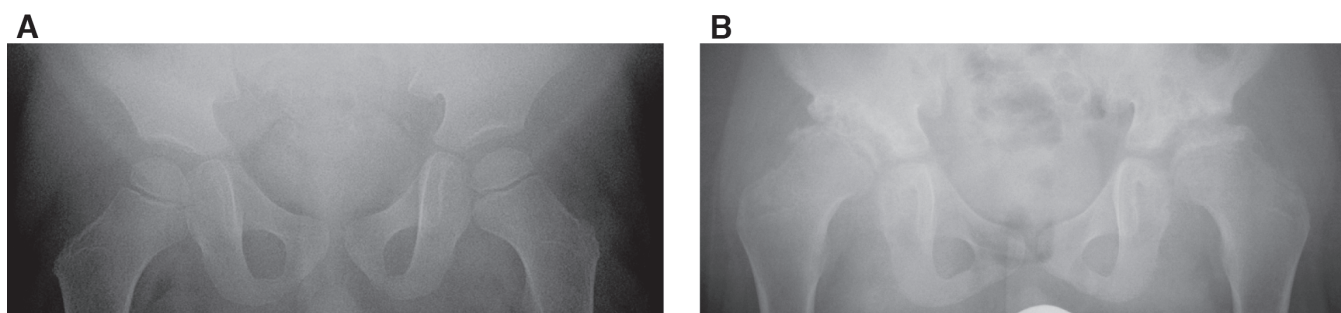


Figure 3. Progression of joint destruction in the hip joint (representative case in Group C). A. Before tocilizumab (TCZ) treatment (4.3-yr-old boy), osteoporosis was observed, but the joint spaces were preserved, and no erosion occurred in either hip. B. Three years after TCZ treatment of the same patient (7.4-yr-old). Severe erosion and cysts were observed and no joint space remained in either hip. From Inaba, *et al*. *Ann Rheum Dis* 2011;70:1693-5<sup>11</sup>; with permission.

Table 3. Univariate analysis of factors affecting disease progression in the large joints.

	OR	95% CI	p
Mean age at onset	1.02	1.307–1.674	0.034*
Female	0.675	0.194–2.352	0.573
Mean disease duration	0.791	0.635–0.986	0.037*
Mean age at the start of TCZ therapy	0.966	0.822–1.135	0.674
Mean duration of TCZ therapy	0.778	0.564–1.073	0.126
Active joint count before TCZ therapy	0.948	0.844–1.064	0.363
Limited ROM before TCZ therapy	0.934	0.811–1.074	0.337
WBC count before TCZ therapy	1	1	0.807
CRP level before TCZ therapy	1.095	0.962–1.248	0.170
ESR before TCZ therapy	1.012	0.981–1.043	0.450
MMP-3 level before TCZ therapy	1.002	0.997–1.004	0.772
FDP-E level before TCZ therapy	1	0.997–1.003	0.835
Glucocorticoid dose before TCZ therapy	1.091	1.008–1.181	0.030*

\*Statistically significant. CRP: C-reactive protein; ESR: erythrocyte sedimentation rate; FDP-E: fibrin degradation product-E; MMP-3: matrix metalloproteinase-3; ROM: range of motion; TCZ: tocilizumab; WBC: white blood cell.

reported that the Poznanski score improved after etanercept therapy in children with polyarticular JIA. In most studies, radiological assessment of patients with JIA has mainly focused on the small joints in the hands using the Poznanski score, original or modified Sharp score, or Larsen score<sup>17,19</sup>. However, because sJIA affects all joints, including the weight-bearing joints involved in walking, it is very important to assess the large joints to provide a prognosis for the quality of life. Therefore, we assessed the large joints, as well as the hands, of patients with sJIA using the Poznanski and modified Larsen scores. Because the modified Larsen score is more appropriate for assessing erosions and cysts as well as joint space narrowing, we found a discrepancy between these 2 scores for the hands.

Because ossification varies in children according to age, developmental status, and disease, and because there is no standard value for joint space width, it can be difficult to radiologically evaluate the large joints in JIA. However, the statistical reliability of the modified Larsen score in the current study using standard standing radiographs of children of different ages for each joint was fair to good, with a  $\kappa$  coefficient of  $> 0.7$ . Therefore, the use of the modified Larsen method for evaluating the large joints in patients with sJIA is considered reasonable.

In our previous study, we reported a radiological improvement in 52% of the large joints following TCZ therapy in 9 patients with sJIA after 82 months of followup<sup>6</sup>. The results of our current study, which included more cases, showed on average no significant differences in the Poznanski or modified Larsen scores of the large joints before and after TCZ treatment. However, all patients showed significant improvements in clinical data, and their glucocorticoid dose decreased. The Poznanski score

improved by +0.4 units after a mean 4.5 years of TCZ therapy in this series of patients; this finding is consistent with that of Nielsen, *et al*<sup>18</sup>, who showed an improvement in the Poznanski score of +0.3 units after 1 year of etanercept treatment. In terms of the modified Larsen score of the large joints, we observed improvement in 27.5% of patients. In those patients, marked radiological improvement with remodeling of damaged joints, widening of joint spaces, and healing of erosion was observed, even in large joints categorized as Larsen grade III or IV. Moreover, patients with improved modified Larsen scores had longer disease duration than patients with worsened scores, indicating the radiological efficacy of TCZ treatment, even in patients with long duration of disease and damaged joints. However, the improvement in the modified Larsen score observed in our current study appears to be less than that observed in our previous study. This might be because more patients were without joint damage before TCZ treatment in our current study. In fact, 64% of the large joints were categorized as grade 0 (normal) before TCZ treatment. Therefore, none of them could be scored as improved after treatment. Moreover, there was a discrepancy between the clinical and radiological results. It should be noted that half the patients in our present study showed progression in the modified Larsen score of the large joints after TCZ treatment, even though their clinical and laboratory data significantly improved.

We also evaluated the CARSH because a high frequency of radiological abnormalities in the hip joint has been reported in patients with sJIA<sup>10,20,21</sup>. The frequency of radiological abnormality in the hip joint was 65% even after TCZ treatment in our present study. The CARSH worsened by +2.3 units, and this result correlated well with the modified Larsen score of the hips. The scores for joint space narrowing, erosion, and subchondral cysts increased after treatment. Avascular necrosis of the femoral head was observed at a low frequency, consistent with a previous study<sup>10</sup>.

MMP-3 levels were also significantly higher among patients with radiological worsening compared to those with radiological improvement or no radiological change following TCZ treatment. We conclude that high MMP-3 levels, which have been reported to correlate with high levels of IL-6<sup>22,23,24</sup> and disease activity, are an important sign of joint progression. For patients with high MMP-3 levels during TCZ treatment, radiological evaluation of the large joints, especially the hip joints, is recommended, even if clinical findings and laboratory data other than MMP-3 levels are improved. Moreover, logistic regression analysis showed that an older age at onset (mean age: 5.7 yrs) is a risk factor for progression in the large joints. Close observation might be warranted for patients with an older age at onset.

Our study has several limitations. The clinical and

radiographic data were collected retrospectively, and therefore the timepoints varied. Although we used the modified Larsen score, there is no established radiological method to accurately evaluate the progression of large joints in children.

Our study confirms the benefits of TCZ treatment for patients with sJIA and suggests the importance of radiographic assessment in such cases. A prospective radiological study in the future may more accurately reveal the efficacy of this treatment.

## ACKNOWLEDGMENT

We are grateful to Satoshi Morita, PhD, Professor, Department of Biostatistics and Epidemiology, Yokohama City University, for statistical analysis and advice.

## REFERENCES

1. Petty RE, Southwood TR, Manners P, Baum J, Glass DN, Goldenberg J, et al. International League of Associations for Rheumatology classification of juvenile idiopathic arthritis: second revision, Edmonton, 2001. *J Rheumatol* 2004;31:390-2.
2. Yokota S, Miyamae T, Imagawa T, Iwata N, Katakura S, Mori M, et al. Therapeutic efficacy of humanized recombinant anti-interleukin-6 receptor antibody in children with systemic-onset juvenile idiopathic arthritis. *Arthritis Rheum* 2005;52:818-25.
3. Yokota S, Imagawa T, Mori M, Miyamae T, Aihara Y, Takei S, et al. Efficacy and safety of tocilizumab in patients with systemic-onset juvenile idiopathic arthritis: a randomised, double-blind, placebo-controlled, withdrawal phase III trial. *Lancet* 2008;371:998-1006.
4. De Benedetti F, Brunner HI, Ruperto N, Kenwright A, Wright S, Calvo I, et al. Randomized trial of tocilizumab in systemic juvenile idiopathic arthritis. *N Engl J Med* 2012;367:2396-406.
5. Inaba Y, Ozawa R, Aoki C, Imagawa T, Mori M, Hara R, et al. Radiologic analysis of the effect of tocilizumab on hands and large joints in children with systemic juvenile idiopathic arthritis. *Mod Rheumatol* 2013;23:667-73.
6. Yokota S, Imagawa T, Takei S, Murata T, Tomiita M, Itoh Y, et al. Guidance on using tocilizumab for juvenile idiopathic arthritis. *Mod Rheumatol* 2011;21:563-71.
7. Giannini EH, Ruperto N, Ravelli A, Lovell DJ, Felson DT, Martini A. Preliminary definition of improvement in juvenile arthritis. *Arthritis Rheum* 1997;40:1202-9.
8. Poznanski AK, Hernandez RJ, Guire KE, Bereza UL, Garn SM. Carpal length in children—a useful measurement in the diagnosis of rheumatoid arthritis and some congenital malformation syndromes. *Radiology* 1978;129:661-8.
9. Larsen A. How to apply Larsen score in evaluating radiographs of rheumatoid arthritis in long-term studies. *J Rheumatol* 1995;22:1974-5.
10. Bertamino M, Rossi F, Pistorio A, Lucigrai G, Valle M, Viola S, et al. Development and initial validation of a radiographic scoring system for the hip in juvenile idiopathic arthritis. *J Rheumatol* 2010;37:432-9.
11. Inaba Y, Ozawa R, Imagawa T, Mori M, Hara Y, Miyamae T, et al. Radiographic improvement of damaged large joints in children with systemic juvenile idiopathic arthritis following tocilizumab treatment. *Ann Rheum Dis* 2011;70:1693-5.
12. Nigrovic PA, Mannion M, Prince FH, Zeff A, Rabinovich CE, van Rossum MA, et al. Anakinra as first-line disease-modifying therapy in systemic juvenile idiopathic arthritis. *Arthritis Rheum* 2011;63:545-55.
13. Quartier P, Allantaz F, Cimaz R, Pillet P, Messiaen C, Bardin C, et al. A multicentre, randomized, double-blind, placebo-controlled trial with the interleukin-1 receptor antagonist anakinra in patients with systemic-onset juvenile idiopathic arthritis (ANAJIS trial). *Ann Rheum Dis* 2011;70:747-54.
14. Gattorno M, Piccini A, Lasigliè D, Tassi S, Brisca G, Carta S, et al. The pattern of response to anti-interleukin-1 treatment distinguishes two subsets of patients with systemic-onset juvenile idiopathic arthritis. *Arthritis Rheum* 2008;58:1505-15.
15. Ruperto N, Brunner HI, Quartier P, Constantin T, Wulfraat N. Two randomized trials of Canakinumab in systemic juvenile idiopathic arthritis. *N Engl J Med* 2012;36:2396-406.
16. Harel L, Wagner-Weiner L, Poznanski AK, Spencer CH, Ekwo E, Magilavay DB. Effects of methotrexate on radiologic progression in juvenile rheumatoid arthritis. *Arthritis Rheum* 1993;36:1370-4.
17. Ravelli A, Ioseliani M, Norambuena X, Sato J, Pistorio A, Rossi F, et al. Adapted versions of the Sharp/van der Heijde score are reliable and valid for assessment of radiographic progression in juvenile idiopathic arthritis. *Arthritis Rheum* 2007;56:3087-95.
18. Nielsen S, Ruperto N, Gerloni V, Simonini G, Cortis E, Lepore L, et al. Preliminary evidence that etanercept may reduce radiographic progression in juvenile idiopathic arthritis. *Clin Exp Rheumatol* 2008;26:688-92.
19. Rossi F, Di Dia F, Galipo O, Pistorio A, Valle M, Magni-Manzoni S, et al. Use of the Sharp and Larsen scoring methods in the assessment of radiographic progression in juvenile idiopathic arthritis. *Arthritis Rheum* 2006;55:717-23.
20. Ozawa R, Inaba Y, Mori M, Hara R, Kikuchi M, Higuchi R, et al. Definitive differences in laboratory and radiological characteristics between two subtypes of juvenile idiopathic arthritis: systemic arthritis and polyarthritis. *Mod Rheumatol* 2012;22:558-64.
21. Spencer CH, Bernstein BH. Hip disease in juvenile rheumatoid arthritis. *Curr Opin Rheumatol* 2002;14:536-41.
22. Nakajima S, Naruto T, Miyamae T, Imagawa T, Mori M, Nishimaki S, et al. Improvement of reduced serum cartilage oligomeric matrix protein levels in systemic juvenile idiopathic arthritis patients treated with the anti-interleukin-6 receptor monoclonal antibody tocilizumab. *Mod Rheumatol* 2009;19:42-6.
23. Sugiyama E. Role of matrix metalloproteinase-3 in joint destruction in rheumatoid arthritis. *Clin Calcium* 2007;17:528-34.
24. Ally MM, Hodkinson B, Meyer PW, Musenge E, Tikly M, Anderson R. Serum matrix metalloproteinase-3 in comparison with acute phase proteins as a marker of disease activity and radiographic damage in early rheumatoid arthritis. *Mediators Inflamm* 2013;2013:183653.

## Correction

### **Discrepancy Between Clinical and Radiological Responses to Tocilizumab Treatment in Patients with Systemic-onset Juvenile Idiopathic Arthritis**

Aoki C, Inaba Y, Choe H, Kaneko U, Hara R, Miyamae T, Imagawa T, Mori M, Oba MS, Yokota S, Saito T. Discrepancy between clinical and radiological responses to tocilizumab treatment in patients with systemic-onset juvenile idiopathic arthritis. *J Rheumatol* 2014;41:1171-7. In Materials and Methods, paragraph 1, sentence 5, the definition of high-dose should read: (0.2 mg/kg/day or more of prednisolone). We regret the error.

doi:10.3899/jrheum.130924.C1