

A False-positive Antineutrophil Cytoplasmic Antibody Proteinase 3 Test in a Patient with Pulmonary-renal Syndrome

To the Editor:

Rapid tests for clinical decision making involving the pulmonary-renal syndrome are useful but still require careful consideration of the overall clinical picture. Proving the diagnosis of systemic vasculitis usually requires histological confirmation.

A previously healthy 47-year-old man presented with progressive illness (fever, dry cough, headache, and muscle ache) and nosebleeds for 4 days. In the past weeks he had spent several nights fishing by a waterside in the presence of rats. On physical examination he appeared ill; heart rate 114 bpm, blood pressure 112/61 mmHg, temperature 38.8°C, respiratory rate 25/min, and normal oxygen saturation. Initial laboratory results included a mild normocytic anemia, high inflammatory markers, severe thrombopenia, mildly elevated liver enzymes, increased conjugated bilirubin, and acute kidney injury (Table 1). Because of anuria, no urine was available for analysis. A chest radiograph showed subtle bilateral opacifications (Figure 1). He was admitted and treated with intravenous amoxicillin/clavulanic acid because of a suspected leptospirosis infection. A qualitative STAT test for antineutrophil cytoplasmic antibodies (ANCA) and antiglomerular basement membrane (anti-GBM; dot-blot from Biomedical Diagnostics) was performed to identify systemic vasculitis as the primary cause of the acute renal insufficiency.

A day later the patient was in progressive respiratory distress with now extensive bilateral alveolar consolidations (Figure 2). Meanwhile, the STAT dot-blot was positive for anti-proteinase 3 (PR3; Table 2). Because of the reported high specificity for ANCA-associated vasculitis, particularly in a patient presenting with a pulmonary-renal syndrome, the original diagnosis of leptospirosis was rejected and immunosuppressive treatment

was started for suspected granulomatosis with polyangiitis (GPA). The treatment consisted of cyclophosphamide, prednisolone, plasmapheresis, and intermittent hemodialysis. A renal biopsy was postponed because of thrombopenia, and to avoid intubation and mechanical ventilation. Three days later the microscopic agglutination test for leptospirosis proved positive for leptospirosis serovar icterohaemorrhagiae (1:20; and 2 months later, 1:640). Meanwhile the general condition and kidney function were already improving rapidly. The diagnosis of GPA was no longer considered valid, therefore immunosuppressive treatment was discontinued and doxycycline was started according to national guidelines for leptospirosis (<http://swabid.nl>). Kidney and liver functions normalized within the next 5 days and the patient's clinical condition improved quickly. Reassessment in the outpatient clinic 2 months later showed complete recovery.

Patients presenting with a pulmonary-renal syndrome (diffuse alveolar hemorrhage and glomerulonephritis) pose a medical emergency. Urgent serological support or refutation for ANCA directed against PR3 and myeloperoxidase or anti-GBM is of utmost importance in differentiating between systemic vasculitis and other underlying diseases and may lead to the appropriate administration of aggressive immunosuppressive therapy¹. This case illustrates that false-positive serological results can, however, sporadically occur, and can lead to incorrect diagnosis and treatment.

Icteric leptospirosis (or Weil disease) is characterized by fever, jaundice, acute renal insufficiency, pulmonary infiltrates, and hyperbilirubinemia. Lung involvement occurs in 20-70% of leptospirosis infections². Although all other symptoms in our patient could be consistent with GPA, the hyperbilirubinemia and thrombopenia were more suggestive for leptospirosis. Nevertheless, the medical team was misdirected by the positive dot-blot test for PR3 ANCA, because this result is very specific for the diagnosis of ANCA-associated vasculitis in a patient with pulmonary-renal syndrome¹.

In suspected systemic vasculitis, the general approach is to confirm the diagnosis with histological findings³. In this case, a kidney biopsy was not performed because of the patient's respiratory condition. Because the patient was anuric, a urine sediment was not available. Thus, immunosuppressive treatment was started based solely on clinical findings and positive ANCA test.

The rapid ANCA test used in our laboratory is a dot-blot. Routinely all STAT samples are repeated in the indirect immunofluorescence (IIF) test, and when positive the myeloperoxidase and PR3 tests (ELiA Thermo Fisher) are done. In this case, the IIF test was positive for cytoplasmic ANCA and the PR3 test was positive (although low) for anti-PR3. All 3 are strongly associated with GPA⁴.

The usefulness of likelihood ratio (LR) in ANCA testing for the diagnosis of small vessel vasculitis has been demonstrated^{5,6}. The LR+ of the dot blot is not known, but is supposed to be high. Rutgers, *et al*⁷ demonstrated a specificity of the blot system of 100%, but only a limited series of negative controls were tested (n = 34). In our laboratory, over 240 dot-blot tests have been performed in the past 8 years and only 2 known false-positives have occurred. This supports the supposedly high LR+ of the dot-blot system.

ANCA have also been described in diseases other than vasculitis, such as connective tissue diseases and infections⁸. However, in most of these cases no anti-PR3 antibodies are detected. A false-positive anti-PR3 in a dot-blot in a patient with leptospirosis is unique to date. In a series of 10 patients with Weil disease, none showed a positive cytoplasmic ANCA with IIF⁹. Only once has a positive anti-PR3 been described in leptospirosis, but that was tested by IIF and the DIASAT anti-PR3 kit¹⁰.

Rapid ANCA/anti-GBM tests for decision making in the acute clinical setting of the pulmonary-renal syndrome, although important, still require careful consideration of the overall clinical picture. Also, often, if not always, histological confirmation to prove the diagnosis of systemic vasculitis is required.

DINETTE E. AGTERHUIS, MD, Department of Internal Medicine, Hospitalgroup Twente, Almelo; A.H. LEONTINE MULDER, MSc, PhD,

Table 1. Laboratory results at admission.

Variables	Unit	Result
Hemoglobin	g/dl	11.4
C-reactive protein	mg/l	359
Leukocytes	× 10 ³ /μl	18.3
Thrombocytes	× 10 ³ /μl	39
Direct Coombs test		Negative
Total bilirubin	mg/dl	3.62
Direct bilirubin	mg/dl	3.04
Alkaline phosphatase	U/l	97
Gamma GT	U/l	86
AST	U/l	131
ALT	U/l	83
LDH	U/l	250
CK	U/l	2527
Creatinine	mg/dl	4.42
Sodium	mEq/l	136
Potassium	mEq/l	3.8
Calcium	mg/dl	6.92
Phosphate	mg/dl	3.16
Albumin	g/dl	2
pH		7.35
pCO ₂	Hg	31.6
Bicarbonate	mEq/l	17
pO ₂ (arterial)	Hg	75.9

Gamma GT: gamma-glutamyltransferase; AST: aspartate aminotransferase; ALT: alanine aminotransferase; LDH: lactate dehydrogenase; CK: creatine kinase; pCO₂: partial pressure of carbon dioxide; pO₂ (arterial): partial pressure of oxygen.

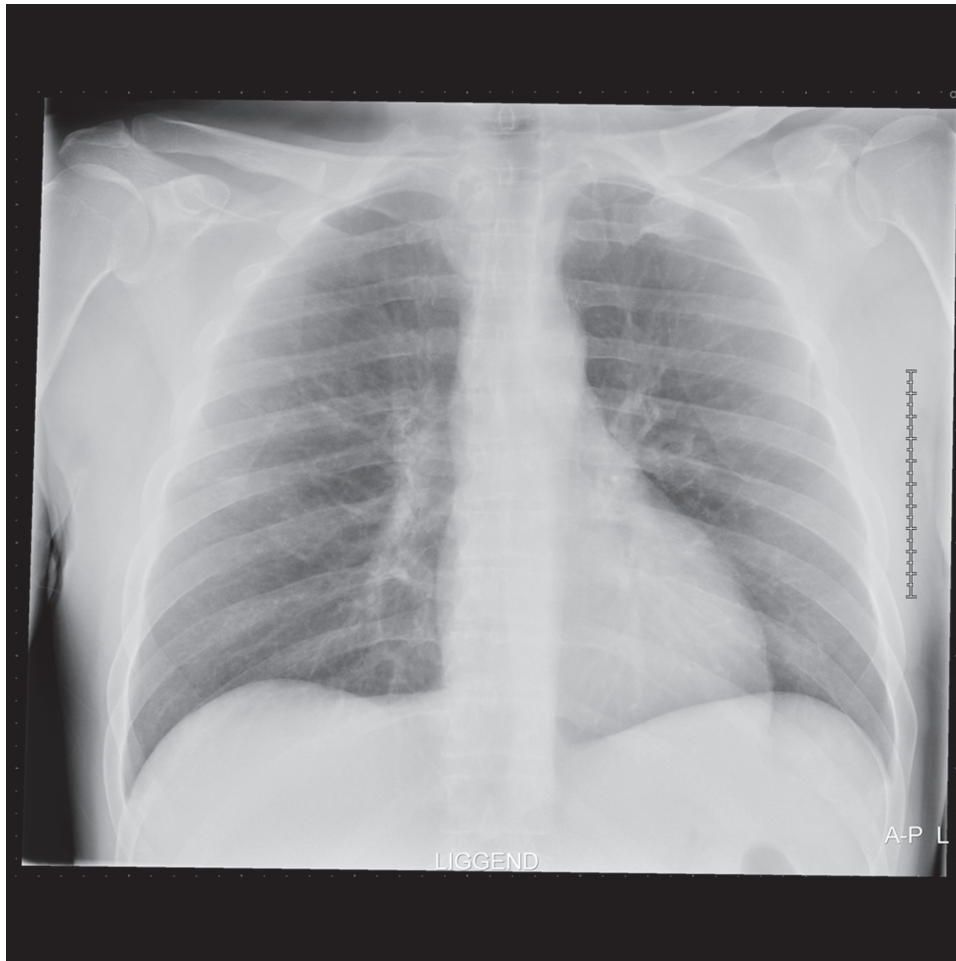


Figure 1. Radiograph on admission, showing subtle bilateral opacifications.

Hospitalgroup Twente, Almelo, Medlon BV; CAROLINE ROOZENDAAL, MD, Department of Clinical Immunology, University Medical Center, Groningen; COEN A. STEGEMAN, MD, PhD, Department of Internal Medicine, Division of Nephrology, University Medical Center Groningen; GOZEWIJN D. LAVERMAN, MD, PhD, Department of Internal Medicine, Hospitalgroup Twente, Almelo, The Netherlands. Address correspondence to Dr. D.E. Agterhuis, Zilvermeeuw 1, 7609 PP, Almelo, The Netherlands. E-mail: D.agterhuis@zgt.nl

REFERENCES

- Sanders JS, Rutgers A, Stegeman CA, Kallenberg CG. Pulmonary: renal syndrome with a focus on anti-GBM disease. *Semin Respir Crit Care Med* 2011;32:328-34.
- Helmerhorst HJ, van Tol EN, Tuinman PR, de Vries PJ, Hartskeerl RA, Grobusch MP, et al. Severe pulmonary manifestation of leptospirosis. *Neth J Med* 2012;70:215-21.
- Rao JK, Allen NB, Feussner JR, Weinberger M. A prospective study of antineutrophil cytoplasmic antibody (c-ANCA) and clinical criteria in diagnosing Wegener's granulomatosis. *Lancet* 1995;346:926-31.
- Berden A, Göçeroglu A, Jayne D, Lugmani R, Rasmussen N, Bruijn JA, et al. Diagnosis and management of ANCA associated vasculitis. *BMJ* 2012;344:326.
- Stone JH, Talor M, Stebbing J, Uhlfelder ML, Rose NR, Carson KA, et al. Test characteristics of immunofluorescence and ELISA tests in 856 consecutive patients with possible ANCA-associated conditions. *Arthritis Care Res* 2000;13:424-34.
- Vermeersch P, Blockmans D, Bossuyt X. Use of likelihood ratios can improve the clinical usefulness of enzyme immunoassays for the diagnosis of small-vessel vasculitis. *Clin Chem* 2009; 55:1886-8.
- Rutgers A, Damoiseaux J, Roozendaal C, Limburg PC, Stegeman CA, Tervaert JW. ANCA-GBM dot-blot: evaluation of an assay in the differential diagnosis of patients presenting with rapidly progressive glomerulonephritis. *J Clin Immunol* 2004;24:435-40.
- Bosch X, Guilabert A, Font J. Antineutrophil cytoplasmic antibodies. *Lancet* 2006;368:404-18.
- Abdulkader R, Sabbaga E, Meireles L, Radu A. Vascular injury in acute renal failure due to leptospirosis is not associated with ANCA. *Nephron* 1993;65:156.
- Constantin A, Marin F, Oksman F, Bouteiller G. Antineutrophil cytoplasmic antibodies in leptospirosis. *J Rheumatol* 1996;23:411. *J Rheumatol* 2014;41:5; doi:10.3899/jrheum.131205

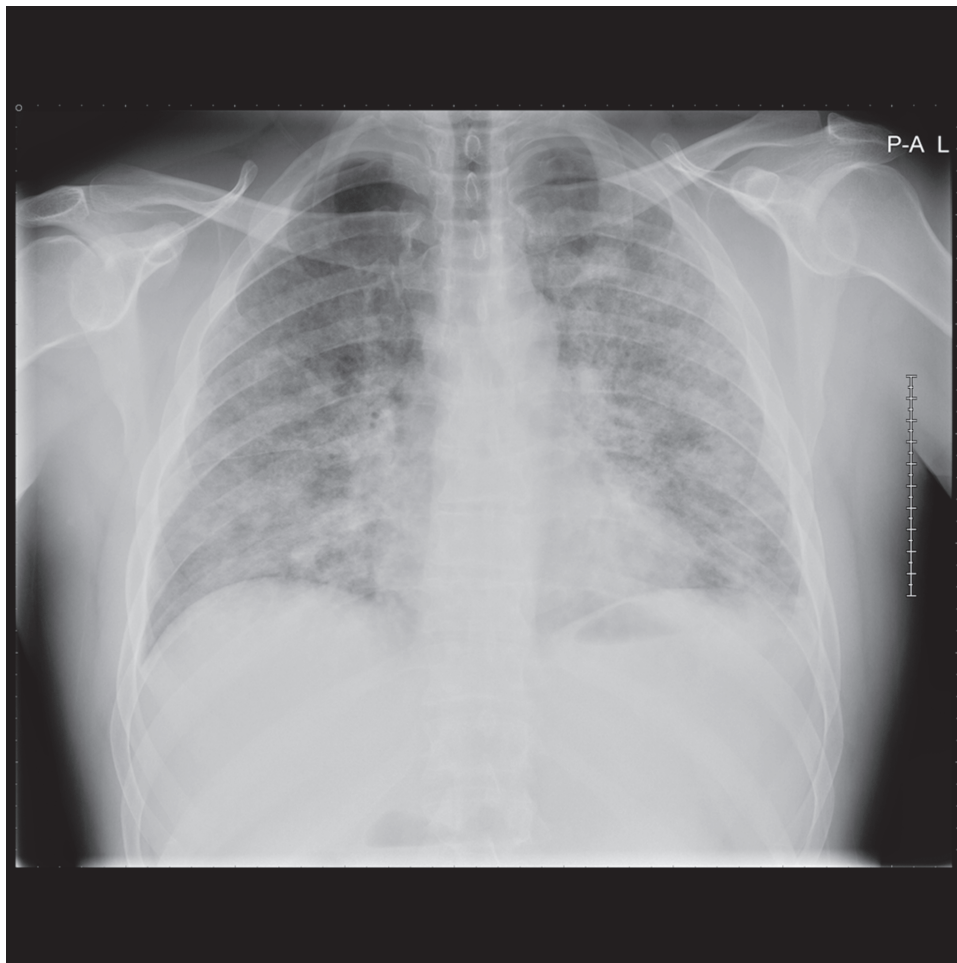

Figure 2. Radiograph the day after admission, showing extensive bilateral alveolar consolidations.

Table 2. Results of ANCA screen on Day 1.

Test	Result	Value
Dot-blot		
Anti-GBM	Negative	—
Anti-MPO	Negative	—
Anti-PR3	Positive	—
Indirect immunofluorescence		
cANCA	Positive	1:80
pANCA	Negative	—
ELiA		
Anti-MPO	Negative	—
Anti-PR3	Positive	3.8

ANCA: antineutrophil cytoplasmic antibodies; anti-GBM: anti-glomerular basement membrane; anti-MPO: anti-myeloperoxidase; anti-PR3: anti-proteinase 3; cANCA: cytoplasmic ANCA; pANCA: perinuclear ANCA; ELiA: ELiA Thermo Fisher tests.