

The OMERACT-RAMRIS Rheumatoid Arthritis Magnetic Resonance Imaging Joint Space Narrowing Score: Intrareader and Interreader Reliability and Agreement with Computed Tomography and Conventional Radiography

Uffe Møller Døhn, Philip G. Conaghan, Iris Eshed, Annelies Boonen, Pernille Boyesen, Charles G. Peterfy, Siri Lillegraven, Bo Ejbjerg, Frederique Gandjbakhch, Paul Bird, Violaine Foltz, Harry K. Genant, Espen Haavardsholm, Fiona M. McQueen, and Mikkel Østergaard

ABSTRACT. Objective. To test the intrareader and interreader reliability of assessment of joint space narrowing (JSN) in rheumatoid arthritis (RA) wrist and metacarpophalangeal (MCP) joints on magnetic resonance imaging (MRI) and computed tomography (CT) using the newly proposed OMERACT-RAMRIS JSN scoring method, and to compare JSN assessment on MRI, CT, and radiography.

Methods. After calibration of readers, MRI and CT images of the wrist and second to fifth MCP joints from 14 patients with RA and 1 healthy control were assessed twice for JSN by 3 readers, blinded to clinical and imaging data. Radiographs were scored by the Sharp/van der Heijde method. Intraclass correlation coefficients (ICC) and smallest detectable differences (SDD) were calculated, and the performance of various simplified scores was investigated.

Results. Both MRI and CT showed high intrareader (ICC ≥ 0.95) and interreader (ICC ≥ 0.94) reliability for total (wrist + MCP) assessment of JSN. Agreement was generally lower for MCP joints than for wrist joints, particularly for CT. Intrareader SDD for MCP/wrist/MCP + wrist were 1.2/6.1/6.4 JSN units for MRI, while 2.7/8.3/9.9 JSN units for CT. JSN on MRI and CT correlated moderately well with corresponding radiographic JSN scores (MCP 2–5: 0.49 and 0.56; wrist areas assessed by Sharp/van der Heijde: 0.80 and 0.95), and high ICC between scores on MRI and CT were demonstrated (MCP: 0.94; wrist: 0.92; MCP + wrist: 0.92).

Conclusion. The OMERACT-RAMRIS MRI JSN scoring system showed high intrareader and interreader reliability, and high correlation with CT scores of JSN. The suggested JSN score may, after further validation in longitudinal studies, become a useful tool in RA clinical trials. (First Release Dec 1 2013; J Rheumatol 2014;doi:10.3899/jrheum.131087)

Key Indexing Terms:

MAGNETIC RESONANCE IMAGING COMPUTED TOMOGRAPHY RADIOGRAPHY
RHEUMATOID ARTHRITIS JOINT SPACE NARROWING RELIABILITY

The Outcome Measures in Rheumatology (OMERACT) Rheumatoid Arthritis (RA) Magnetic Resonance Imaging

(MRI) Scoring System (RAMRIS) evaluates bone erosions, synovitis, and bone edema^{1,2}, and is increasingly being used

From the Center for Rheumatology and Spine Diseases, Copenhagen University Hospital Glostrup, Denmark; University of Leeds and the UK National Institute for Health Research (NIHR) Leeds Musculoskeletal Biomedical Research Unit, Leeds, UK; Sheba Medical Center, Tel Aviv University, Tel Aviv, Israel; Maastricht University Medical Center, Maastricht, Netherlands; Diakonhjemmet Hospital, Oslo, Norway; University of California, San Francisco, CA, USA; Slagelse University Hospital, Copenhagen, Denmark; Pitié Salpêtrière Hospital, Paris, France; University of New South Wales (NSW), Sydney, Australia; and University of Auckland, Auckland, New Zealand.

U.M. Døhn, MD, PhD, Center for Rheumatology and Spine Diseases, Copenhagen University Hospital Glostrup; P.G. Conaghan, MBBS, PhD, FRACP, FRCP, Leeds Institute of Rheumatic and Musculoskeletal Medicine, University of Leeds and NIHR Leeds Musculoskeletal Biomedical Research Unit; I. Eshed, MD, Sheba Medical Center, Tel Aviv

University; A. Boonen, MD, Maastricht University Medical Center; P. Bøyesen, MD, Diakonhjemmet Hospital; C.G. Peterfy, MD, PhD, FRCP, Spire Sciences Inc., Boca Raton, FL, USA; S. Lillegraven, MD, Diakonhjemmet Hospital; B. Ejbjerg, MD, PhD, Slagelse University Hospital; F. Gandjbakhch, MD, Pitié Salpêtrière Hospital; P. Bird, MD, University of NSW; V. Foltz, MD, Pitié Salpêtrière Hospital; H.K. Genant, MD, University of California; E.A. Haavardsholm, MD, Diakonhjemmet Hospital; F.M. McQueen, MBChB, MD, FRACP, University of NSW; M. Østergaard, MD, PhD, DMSc, Professor of Rheumatology, Center for Rheumatology and Spine Diseases, Copenhagen University Hospital Glostrup.

Address correspondence to Dr. M. Østergaard, Center for Rheumatology and Spine Diseases, Glostrup Hospital, Nordre Ringvej 57, DK-2600 Glostrup, Denmark. E-mail: mo@dadlnet.dk

as an outcome measure in RA clinical trials^{3,4,5}. As evaluation of cartilage thickness on MRI was impaired by lower quality images because of lower signal and resolution, the evaluation of joint space narrowing (JSN) was omitted in the early phase of developing the OMERACT RAMRIS. However, because of more recent technical advances of MRI, images with higher signal and resolution are now available, allowing a more detailed visualization of cartilage^{6,7}. Because cartilage damage is an essential aspect of structural joint damage in RA, a reliable MRI assessment system of JSN would be an important improvement in the RAMRIS, for potential use as an outcome measure in RA clinical trials. Because future clinical trials will very often involve an active comparator rather than placebo, highly sensitive methods for differentiating treatment arms with respect to structural joint damage, including cartilage loss, are needed. One such method could be assessment of cartilage loss by MRI. Recently, an MRI JSN scoring system was developed by the OMERACT MRI in Inflammatory Arthritis Task Force⁸. Computed tomography (CT) has been used in several RA studies as a reference method for bone erosions^{9,10,11,12}, and owing to its precise tomographic visualization of bone surfaces, CT is also well suited as a reference method for assessment of JSN.

The aim of the present initiative was to further validate the newly proposed assessment method of JSN in RA, by investigating the intrareader and interreader reliability and by comparison with CT and conventional radiography using an established and validated scoring method for joint space narrowing¹².

MATERIALS AND METHODS

In a multireader exercise, undertaken by the OMERACT MRI in Inflammatory Arthritis Task Force, MRI, CT, and conventional radiographs of 14 patients with RA and 1 healthy control subject (see Table 1 for patient characteristics) were assessed for JSN in the wrist and second to fifth metacarpophalangeal (MCP) joints by 3 readers.

Image Acquisition

MRI of the wrist and second to fifth MCP joints was performed on a Philips

Table 1. Patient characteristics. All data are median (range) unless otherwise indicated.

Age, yrs	60 (31–78)
Female	71%
Disease duration, yrs	4.5 (1–20)
IgM rheumatoid factor-positive	71%
Swollen joint count, 0–28	6 (1–20)
Tender joint count, 0–28	5 (1–26)
CRP, mg/l	9 (3–117)
DAS28-CRP3	4.2 (3.5–7.1)
HAQ score	1.13 (0–1.88)
No. previous DMARD	2.5 (1–5)
Methotrexate dose, mg/week	18.8 (7.5–25)

The healthy control was a 37-year-old male. CRP: Serum C-reactive protein; DAS: Disease Activity Score; HAQ: Health Assessment Questionnaire; DMARD: disease-modifying antirheumatic drugs.

Panorama 0.6T unit (Philips Medical Systems). High-resolution T1-weighted 3-dimensional fast-field-echo sequences were obtained separately of wrist and second to fifth MCP joints [repetition time 20 ms, echo-time 8 ms, acquired slice thickness 0.8 mm (reconstructed at 0.4 mm), field of view 100 mm, matrix 216*216, averages 1]. Multidetector CT images of the wrist and second to fifth MCP joints were obtained on a Philips Mx8000IDT unit (Philips Medical Systems). Images were obtained with an in-plane resolution of 0.4 mm*0.4 mm, slice thickness 0.4 mm, pitch 0.4 mm, slice spacing 0.4 mm, overlap 50%, 90 kV, and 100 mAs.

Radiography was performed on a Philips Digital Diagnost unit (Philips Medical Systems; resolution 0.143 mm). Posterior-anterior of both hands and feet were obtained. All imaging procedures were done at the Department of Radiology, Copenhagen University Hospital at Herlev, Denmark, as part of a cohort study¹³.

Scoring of Joint Space Narrowing

As proposed by Østergaard, *et al*⁸, JSN on MRI is defined as a reduced joint space width compared to normal, as assessed in a slice perpendicular to the joint surface. JSN is scored at 17 sites in the wrist and at the second to fifth MCP joints on a 0–4 scale [0: No narrowing; 1: Focal or mild (< 33%); 2: Moderate (34%–66%); 3: Moderate to severe (67%–99%); 4: Ankylosis] leading to a total score ranging from 0–84⁸. The same definition of JSN was applied on CT for the purpose of the study.

The performance of various simplified scores was investigated. As in the previous exercise, we tested intrareader and interreader ICC of separate MCP and wrist scorings and scorings of the joint space locations assessed by the Sharp/van der Heijde (SvdH) and the Sharp/Genant radiographic methods and by 2 further suggestions for simplified scores, assessing 14 and 7 joint spaces in the wrist, respectively. Detailed description of the joint spaces assessed by the different approaches has been reported⁸.

Radiographs of hands and feet were scored for joint space narrowing according to the SvdH method¹².

For comparison between MRI, CT, and radiography we chose to use the scores from the radiologist (IE), in accordance with the procedure in the previous OMERACT MRI JSN exercise⁸.

Multireader Exercise

An exercise was held in September 2011 in Copenhagen and included 3 readers of MRI and CT images [1 musculoskeletal radiologist (IE) and 2 rheumatologists (PC and MØ), experienced in MRI assessment of RA joints]. Radiographs were assessed by a single reader, a rheumatologist (AB) experienced in assessment on radiographs according to the SvdH method.

Phase A (calibration). To calibrate readers, MR and CT images of unilateral wrist and MCP joints from 4 patients with RA and 1 healthy control were assessed in common, the day before the exercise.

Phase B (multireader exercise). In this exercise, 14 persons with RA and 1 healthy control without radiographic evidence of structural joint damage was included. MR and CT images of unilateral wrist and second to fifth MCP joints were assessed separately by all readers, blinded to person identity and clinical and other imaging data. Images were read twice with different patient identification numbers and with a 1-day interval.

Statistics

Descriptive statistics, intraclass correlation coefficients (ICC; mixed effects, absolute agreement definition; average measure for interreader agreement, single measure for intrareader and comparisons between MRI and radiography and CT) and intrareader smallest detectable differences (SDD) were calculated, using SPSS Statistics, version 16.0.

RESULTS

Patient characteristics are presented in Table 1.

All patients had evidence of structural joint damage on

Table 2. Magnetic resonance imaging and computed tomography joint space narrowing scores in patients with rheumatoid arthritis and healthy controls. Intrareader and interreader agreement.

Assessed Areas	Score Characteristics	MRI Observed Scores, median (range)	MRI Intrateader Agreement (single measure ICC)				MRI Agreement with Radiograph SvDH JSN Score (single measure ICC)*				CT Intrateader Agreement (single measure ICC)				CT Agreement with Radiograph SvDH JSN score (single measure ICC)*				MRI Agreement with CT	Radiograph Observed Scores, Median (range)			
			Rheumatologist 1	Rheumatologist 2	ICC (average measure)	Agreement	Unilateral MCP2-5	Unilateral Wrist	Bilateral MCP2-5 and Wrist	Hands and Feet	Radiologist	Rheumatologist 1	Rheumatologist 2	ICC (average measure)	Unilateral MCP2-5	Unilateral Wrist	Unilateral MCP2-5 and Wrist	Bilateral MCP2-5 and Wrist					
JSN score**	No. Assessed Areas	Possible Range																					
Wrist + MCP2-5	21	0-84	13 (0-57)	0.98	0.97	0.98	0.94	-0.01	0.53	0.57	0.46	23 (0-58)	0.98	0.96	0.95	0.96	0.03	0.40	0.50	0.67	0.92	-	
	4	0-16	0 (0-5)	0.91	0.99	0.93	0.82	0.49	0.02	0.09	0.03	1 (0-6)	0.90	0.81	0.75	0.66	0.56	-0.01	0.09	0.03	0.94	2 (0-16)	
	17	0-68	12 (0-57)	0.98	0.97	0.98	0.95	-0.04	0.55	0.55	0.40	17 (0-58)	0.98	0.97	0.96	0.97	0.01	0.43	0.50	0.61	0.92	-	
	SvDH-Wrist + MCP2-5	11	0-40	5 (0-19)	0.96	0.96	0.95	0.91	0.10	0.85	0.63	0.14	11 (0-20)	0.97	0.92	0.90	0.92	0.23	0.89	0.89	0.24	0.81	14 (0-24)
		7	0-24	3 (0-19)	0.97	0.96	0.96	0.95	-0.16	0.80	0.47	0.10	7 (0-20)	0.98	0.95	0.95	0.97	0.07	0.95	0.75	0.19	0.81	8 (0-22)
Genant-wrist + MCP2-5	11	0-28	4 (0-11)	0.93	0.94	0.97	0.90	0.32	0.54	0.39	0.09	6 (0-11)	0.95	0.91	0.88	0.89	0.46	0.62	0.51	0.12	0.89	-	
	7	0-12	1 (0-9)	0.96	0.93	0.99	0.97	-0.14	0.47	0.24	0.05	5 (0-15)	0.99	0.96	0.96	0.96	0.06	0.83	0.56	0.13	0.69	-	
Genant-wrist	14	0-56	9 (0-49)	0.98	0.97	0.98	0.95	-0.05	0.64	0.62	0.35	16 (0-50)	0.99	0.97	0.96	0.97	0.01	0.52	0.60	0.54	0.92	-	
	7	0-28	4 (0-24)	0.96	0.97	0.97	0.94	-0.08	0.91	0.66	0.16	8 (0-24)	0.99	0.98	0.95	0.97	0.06	0.90	0.84	0.25	0.91	-	

* For comparison with radiography, JSN scores of unilateral second to fifth MCP joints, unilateral wrist by the SvdH and the total SvdH JSN score (bilateral PIP2-5, MCP1-5, wrist, MTP1-5 and IPI) are used. ** Simplified MRI and CT JSN scores in which only some joint spaces are evaluated: SvdH-wrist, SvdH-wrist + MCP2-5, Genant-wrist and Genant-wrist + MCP2-5 include all joint spaces included in the SvdH and Genant radiograph methods, respectively (for wrist and wrist + MCP2-5). OM7 includes the CMC2-3, trapezoid-scaphoid, capitate-lunate, hamate-triquetrum, radius-scaphoid, and the radius-lunate joint spaces and OM14 the same plus CMC4-5, trapezoid-hamate, capitate-hamate, trapezium-scaphoid, capitate-scaphoid, and the lunate-triquetrum joint spaces. For a detailed description of which joint areas are included in the different scoring approaches, see Table 1 in Østergaard, et al⁸. Observed MRI and CT scores, correlations with radiographic scores, and agreement between MRI and CT are given for the experienced musculoskeletal radiologist. Interreader ICC (average measure ICC provided) are for all 3 readers. MRI: magnetic resonance imaging; CT: computed tomography; JSN: joint space narrowing; MCP: metacarpophalangeal; OM7: OMERACT JSN assessment of 7 joint spaces; OM14: OMERACT JSN assessment of 14 joint spaces; SvdH: Sharp/van der Bijle; ICC: intraclass correlation coefficient.

radiographs, with a median (range) total SvH score of 75 (3–106), joint space narrowing score of 40 (1–70), and erosion score of 27 (2–44).

Intraobserver and interobserver ICC of MRI and CT readings with various scoring approaches, with respect to number of joints and joint areas, as well as ICC between JSN scores on MRI, CT, and radiography, are presented in Table 2.

Intraobserver SDD and the intraobserver SDD as a fraction of the observed maximum score are presented in Table 3.

In Figures 1 and 2, examples of joint space assessments on MRI, CT, and radiography are presented.

DISCUSSION

The results presented here build on experiences from a former OMERACT exercise, where initial results on the OMERACT-RAMRIS scoring method of JSN on MRI were presented⁸, and is a further step for developing and validating a MRI scoring system for JSN in RA wrist and MCP joints. This is the first study comparing JSN assessment on MRI, CT, and radiography.

CT is generally accepted as a reference method for assessment of bone, and is an ideal imaging modality to visualize

bone surfaces, and therefore the cortical margins of joints. Further, in contrast to conventional radiography, CT is a tomographic imaging technique allowing assessment of joint space without projectional superimposition and distortion. Consequently, CT is the best possible imaging external reference for the MRI JSN score.

Close correlation between JSN assessment on MRI and CT was found, and a statistically significant, albeit lower, correlation with radiographic scores was detected. Further, high to very high intrareader and interreader reliability of JSN assessment on both MRI and CT was found, especially at the wrist joints and irrespective of the number of bone surfaces assessed. Scoring of MRI JSN at a reduced number of sites has also showed high reproducibility, and good correlation with corresponding radiographic scores of JSN in other studies^{6,7}. As in the previous exercise, substantial reader variation in absolute scores was observed, highlighting a need for further reader calibration and potentially the development of an atlas, which could serve as a reference image set. Also in agreement with the previous exercise, lower ICC for assessment of MCP joints were found. However, it should be noted that the scores of JSN were significantly higher in the wrist compared to MCP (median scores 5 and 0, respectively), which may have

Table 3. Intraobserver smallest detectable difference of MRI and CT JSN scoring.

Reader	MRI				CT			
	Intraobserver SDD† (SDD/maximum observed value)				Intraobserver SDD† (SDD/maximum observed value)			
	Radiologist	Rheumatologist 1	Rheumatologist 2	Mean SDD	Radiologist	Rheumatologist 1	Rheumatologist 2	Mean SDD
MCP2–5	1.7 (0.28)	1.0 (0.12)	1.0 (0.20)	1.2	1.8 (0.29)	3.3 (0.37)	3.1 (0.34)	2.7
Wrist	6.4 (0.11)	7.1 (0.12)	4.9 (0.08)	6.1	7.1 (0.12)	9.4 (0.16)	8.3 (0.14)	8.3
Total	6.6 (0.12)	7.3 (0.13)	5.2 (0.09)	6.4	8.1 (0.14)	11.2 (0.17)	10.4 (0.16)	9.9

† SDD = ± 1.96•SD[Read_A–Read_B]. SDD: smallest detectable difference; MCP2-5: second to fifth metacarpophalangeal joints; MRI: magnetic resonance imaging; CT: computed tomography; JSN: joint space narrowing.

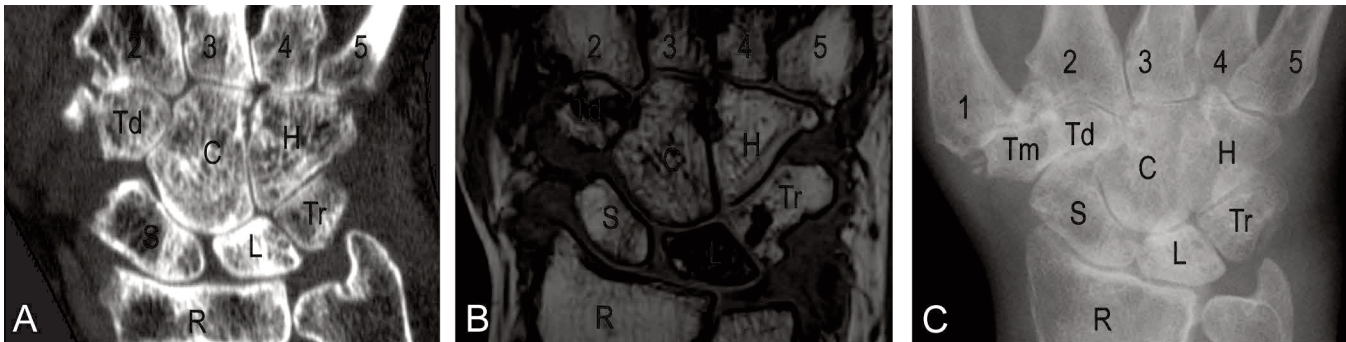


Figure 1. Computed tomography (CT; A), magnetic resonance imaging (MRI; B), and radiography (C) of the wrist of a patient with rheumatoid arthritis. A coronal CT slice, the corresponding coronal T1-weighted slice, and the conventional radiograph in posterior–anterior projection are shown (note that not all joint spaces are visible in this slice). CMC: carpometacarpal; Tm: trapezium; Td: trapezoid; C: capitate; H: hamate; S: scaphoid; L: lunate; Tr: triquetrum; R: radius. Joint space narrowing scores on CT/MRI were CMC1 = 3/3; CMC2 = 3/1; CMC3 = 2/0; CMC4 = 2/0; CMC5 = 1/0; Tm-Td = 3/1; Td-C = 3/1; C-H = 0/1; Tm-S = 2/3; Td-S = 0/1; C-S = 1/1; C-L = 2/0; H-T = 0/0; S-L = 0/0; L-T = 1/1; R-S = 1/1; R-L = 1/1. Sharp/van der Heijde joint space narrowing scores were CMC3 = 2; CMC4 = 2; CMC5 = 0; Tm/Td-S = 2; C-S = 3; R-S = 2.

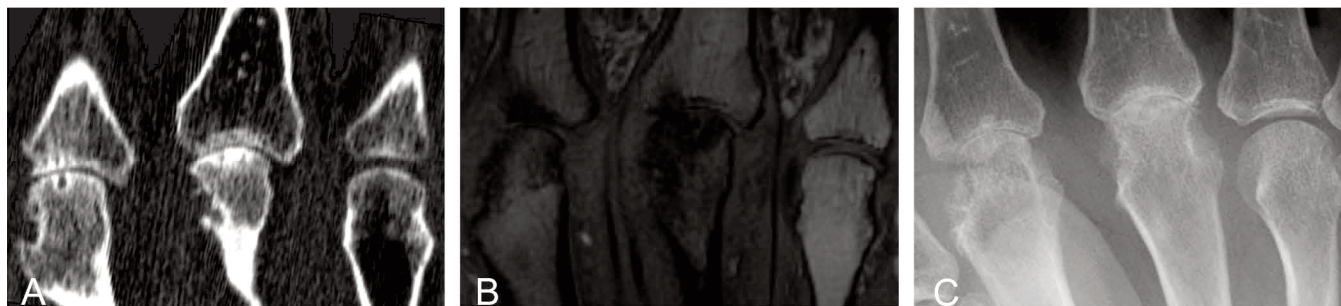


Figure 2. Computed tomography (CT; A), magnetic resonance imaging (MRI; B), and radiography (C) of the metacarpophalangeal (MCP 2–4) joints (left to right) of a patient with rheumatoid arthritis. A coronal CT slice, the corresponding coronal T1-weighted slice and the conventional radiograph in posterior-anterior projection are shown. Joint space narrowing scores on CT/MRI/radiography were MCP2 = 1/2/3, MCP3 = 2/3/3, MCP4 = 0/0/0.

influenced our results in the direction toward the lower agreements in the MCP joints. The higher mobility between the metacarpal and phalangeal bone compared to the tightly bound wrist bones may also contribute to the lower reliability of scoring the MCP joints. In recent studies by Peterfy, *et al* a specially designed acrylic hand frame was used to ensure reproducible positioning of the hand. This possibly contributed to the high correlation to radiography^{7,14}. Also in future MRI studies of JSN, fixed positioning of the joints must be the goal.

A major advantage of the current study compared to our previous study, and to other studies investigating JSN in RA^{6,7}, was that an additional comparison with CT was added. A strength of using CT is its tomographic visualization of bone with a high resolution and great contrast to the surrounding soft tissues. Both MRI and CT allow visualization of joint surfaces that are inaccessible to radiographic assessment because of projectional superimposition, and consequently omitted from accepted radiographic scoring methods. In this exercise, MRI JSN assessment showed reproducibility similar to what was observed with CT. Further, although CT does not directly visualize cartilage, very high correlation with CT JSN scores supports the construct validity, if not the criterion validity (if CT can be accepted as a gold standard for joint space width), of MRI JSN. The total RAMRIS JSN score (incorporating unilateral wrist and second to fifth MCP joints) appears to have the highest correlation to the overall total SvdH, and based on these results a reduced JSN assessment score is not supported.

Radiography is a projectional 2-dimensional representation of 3-D anatomy, and some areas in the SvdH score are not assessed because they have been found not to contribute to the responsiveness of the score. This in turn is probably mainly due to projectional superimposition on radiographs that hinders appropriate assessment of all joint areas. This hindrance at least partly explains the moderate correlation between the radiographic and MRI JSN scores. In contrast, radiography is favored for its ability to visualize many different joint regions during the same examination.

However, the moderate correlation of radiographs of both hands, wrists, and forefeet with MRI scores of unilateral wrist and second to fifth MCP joints demonstrates the construct validity of the MRI measure, and also that the information provided by MRI is adding to the information provided by radiography. Although direct assessment of cartilage loss with MRI in randomized controlled clinical trials of RA have been reported^{14,15,16}, the sensitivity to change and the possible added clinical value of MRI assessment of JSN remain to be elucidated.

A limitation to our study is the cross-sectional design, because testing the MRI JSN score in a longitudinal setting would be beneficial to describe the responsiveness and discriminatory validity of the score. A future step in the validation of the scoring system will be to determine discriminant validity by testing sensitivity to change in longitudinal studies. Another limitation is that only 1 healthy control individual was included. JSN on MRI has been observed in healthy controls^{6,8}, and in the current study JSN in the wrist was also scored at a few locations in the control person, by 2 of 3 assessors. It is expected that JSN narrowing can be seen frequently in nonrheumatoid controls, particularly with increasing age and in certain joint areas (e.g., CMC1) more commonly affected by degenerative joint disease. We did not test the feasibility of the score by measuring the time spent for assessment of JSN. However, it should be noted that when assessing MRI for JSN, important information on erosions, synovitis, and bone marrow edema are obtained in parallel, because the images used are T1-weighted images, which are also used for erosion assessment. Thus, the sequences needed for assessment of JSN did not require additional scanning time.

A theoretical limitation of JSN measurement, regardless of whether it is measured with MRI, radiography, or CT, is that it is only an indirect measure of cartilage loss. While radiography and CT cannot visualize cartilage directly, MRI is capable of delineating cartilage, and may thus offer additional accuracy¹⁴.

The OMERACT-RAMRIS MRI JSN scoring system showed high intrareader and interreader reliability, and the

construct validity of the score was supported by high correlation with CT scores of JSN. Further studies on the discriminatory validity are needed, but the suggested MRI JSN score seems to be a potentially important outcome measure of cartilage damage in RA and may, after further validation in longitudinal studies, become a useful tool in RA clinical trials.

REFERENCES

1. Østergaard M, Peterfy C, Conaghan P, McQueen F, Bird P, Ejbjerg B, et al. OMERACT rheumatoid arthritis magnetic resonance imaging studies. Core set of MRI acquisitions, joint pathology definitions, and the OMERACT RA-MRI scoring system. *J Rheumatol* 2003;30:1385-6.
2. Østergaard M, Edmonds J, McQueen F, Peterfy C, Lassere M, Ejbjerg B, et al. The EULAR-OMERACT rheumatoid arthritis MRI reference image atlas. *Ann Rheum Dis* 2005;64 Suppl 1:i2-i55.
3. Østergaard M, Emery P, Conaghan PG, Fleischmann R, Hsia EC, Xu W et al. Significant improvement in synovitis, osteitis, and bone erosion following golimumab and methotrexate combination therapy as compared with methotrexate alone: a magnetic resonance imaging study of 318 methotrexate-naïve rheumatoid arthritis patients. *Arthritis Rheum* 2011;63:3712-22.
4. Conaghan PG, Emery P, Østergaard M, Keystone EC, Genovese MC, Hsia EC, et al. Assessment by MRI of inflammation and damage in rheumatoid arthritis patients with methotrexate inadequate response receiving golimumab: results of the GO-FORWARD trial. *Ann Rheum Dis* 2011;70:1968-74.
5. Cohen SB, Dore RK, Lane NE, Ory PA, Peterfy CG, Sharp JT, et al. Denosumab treatment effects on structural damage, bone mineral density, and bone turnover in rheumatoid arthritis: a twelve-month, multicenter, randomized, double-blind, placebo-controlled, phase II clinical trial. *Arthritis Rheum* 2008;58:1299-309.
6. McQueen F, Clarke A, McHaffie A, Reeves Q, Williams M, Robinson E et al. Assessment of cartilage loss at the wrist in rheumatoid arthritis using a new MRI scoring system. *Ann Rheum Dis* 2010;69:1971-5.
7. Peterfy CG, Dicarolo JC, Olech E, Bagnard MA, Gabriele A, Gaylis N. Evaluating joint-space narrowing and cartilage loss in rheumatoid arthritis using MRI. *Arthritis Res Ther* 2012;14:R131.
8. Østergaard M, Boyesen P, Eshed I, Gandjbakhch F, Lillegraven S, Bird P, et al. Development and preliminary validation of a magnetic resonance imaging joint space narrowing score for use in rheumatoid arthritis: potential adjunct to the OMERACT RA MRI scoring system. *J Rheumatol* 2011;38:2045-50.
9. Møller Døhn U, Ejbjerg B, Court-Payen M, Hasselquist M, Narvestad E, Szkudlarek M, et al. Are bone erosions detected by magnetic resonance imaging and ultrasonography true erosions? A comparison with computed tomography in rheumatoid arthritis metacarpophalangeal joints. *Arthritis Res Ther* 2006;8:R110.
10. Albrecht A, Finzel S, Englbrecht M, Rech J, Hueber A, Schlechtweg P, et al. The structural basis of MRI bone erosions: an assessment by microCT. *Ann Rheum Dis* 2013;72:1351-7.
11. Møller Døhn U, Terslev L, Szkudlarek M, Hansen MS, Hetland ML, Hansen A, et al. Detection, scoring and volume assessment of bone erosions by ultrasonography in rheumatoid arthritis: comparison with CT. *Ann Rheum Dis* 2013;72:530-4.
12. van der Heijde D. How to read radiographs according to the Sharp/van der Heijde method. *J Rheumatol* 1999;26:743-5.
13. Møller Døhn U, Boonen A, Hetland ML, Hansen MS, Knudsen LS, Hansen A, et al. Erosive progression is minimal, but erosion healing rare, in patients with rheumatoid arthritis treated with adalimumab. A 1 year investigator-initiated follow-up study using high-resolution computed tomography as the primary outcome measure. *Ann Rheum Dis* 2009;68:1585-90.
14. Peterfy CG, Olech E, Dicarolo JC, Merrill JT, Countryman PJ, Gaylis NB. Monitoring cartilage loss in the hands and wrists in rheumatoid arthritis with magnetic resonance imaging in a multi-center clinical trial: IMPRESS (NCT00425932). *Arthritis Res Ther* 2013;15:R44.
15. Peterfy CG, Emery P, Tak PP, Østergaard M, Dicarolo J, Otsa K, et al. Rituximab (RTX) plus methotrexate (MTX) prevents bone erosion and joint-space narrowing (JSN) and reduces synovitis, osteitis as shown on MRI: results from a randomized placebo controlled trial in patient (Pts) with rheumatoid arthritis (RA-SCORE) [abstract]. *Ann Rheum Dis* 2011;70 Suppl 3:152.
16. Peterfy CG, Emery P, Genovese MC, Keystone E, Taylor P, Berclaz P-Y, et al. Magnetic resonance imaging substudy in a phase 2b dose-ranging study of baricitinib, an oral janus kinase 1/janus kinase 2 inhibitor, in combination with traditional disease-modifying antirheumatic drugs in patients with rheumatoid arthritis [abstract]. *Arthritis Rheum* 2012;64 Suppl: 1050.