Patients with Rheumatoid Arthritis in Clinical Remission Manifest Persistent Joint Inflammation on Histology and Imaging Studies

Allen Anandarajah, Ralf Thiele, Ellen Giampoli, Johnny Monu, Gwy-Suk Seo, Changyong Feng, and Christopher T. Ritchlin

ABSTRACT. ***Objective.*** The purpose of our study was to test the hypothesis that synovitis on magnetic resonance imaging (MRI) and ultrasound (US) observed in patients with rheumatoid arthritis (RA) who meet remission criteria reflects active inflammation on histopathology.

Methods. We analyzed 15 synovial specimens obtained during surgical procedures from 14 patients with RA in clinical remission as defined by the American College of Rheumatology criteria. Histological specimens were scored for hyperplasia of synovial lining and synovial stroma, inflammation, lymphoid follicles, and vascularity. The histology scores were classified as minimal, mild, moderate, or severe disease activity. US and MRI performed within a 4-month period of surgery were scored for disease activity. The correlation between histology and imaging scores was examined.

Results. Four of 14 patients were receiving anti-tumor necrosis factor (TNF) therapy, 4 were receiving methotrexate (MTX) alone, 4 were taking MTX and hydroxychloroquine (HCQ), and 1 was taking HCQ and sulfasalazine. Four specimens had severe, 6 moderate, 3 mild, and 2 minimal disease activity on histology. Three of 4 specimens with minimal and mild histology were observed in subjects receiving anti-TNF therapy. Synovitis was noted on greyscale in 80% of joints and Doppler signal in 60%. MRI demonstrated synovitis and bone marrow edema in 86% of images. Positive but not significant correlations were noted between histology and synovitis scores on US.

Conclusion. Despite clinical remission, histology and imaging studies documented a persistently active disease state that may explain the mechanism for radiographic progression. (First Release Oct 1 2014; J Rheumatol 2014;41:2153–60; doi:10.3899/jrheum.140411)

Key Indexing Terms:
RHEUMATOID ARTHRITIS REMISSION HISTOLOGY
MAGNETIC RESONANCE IMAGING ULTRASOUND

Traditionally, the primary treatment goals in rheumatoid arthritis (RA) have been the control of signs and symptoms, and the prevention of joint damage and functional disability[1]. Realization of these goals is now possible for many patients with the emergence of biologic therapies and improved treatment strategies that profoundly suppress joint inflammation and induce minimal or undetectable disease activity[1,2]. Based on these new developments, RA treatment goals have been modified to target "remission."[3]

From the Allergy, Immunology and Rheumatology Division, University of Rochester Medical Center; Medicine, University of Rochester School of Medicine and Dentistry, Rochester, New York, USA.

A. Anandarajah, MD, MSc, Allergy, Immunology and Rheumatology Division, University of Rochester Medical Center; R. Thiele, MD; E. Giampoli, MD, Department of Pathology and Laboratory Medicine; J. Monu, MD, MSc; G-S. Seo, MD, Department of Musculoskeletal Radiology; C. Feng, Department of Biostatistics, University of Rochester School of Medicine and Dentistry; C.T. Ritchlin, MD, MPH, Allergy, Immunology and Rheumatology Division, University of Rochester.

Address correspondence to Dr. A. Anandarajah, Allergy, Immunology and Rheumatology Division, University of Rochester Medical Center, 601 Elmwood Ave., PO Box 695, Rochester, New York 14642, USA. E-mail: allen_anandarajah@urmc.rochester.edu

Accepted for publication July 15, 2014.

Remission is defined as the complete absence of any measurable disease activity. Until recently, most studies have relied on the American College of Rheumatology (ACR) or the European League Against Rheumatism definitions for remission despite the fact that these measures were not designed to serve as a target goal for the clinician and have several shortcomings[4,5,6,7,8,9]. Remission, as defined by the above criteria, is not consistently associated with good patient-reported outcomes[10]. Indeed, several articles reported progression of joint damage despite apparent clinical remission and therefore suggest a disparity between clinical status and ongoing synovitis, and in some cases, joint damage[11,12,13,14,15,16]. Most importantly, current measures of disease activity do not directly measure inflammation at the primary site of tissue pathology[14,15]. Potential explanations for progression of disease in the presence of clinical remission include dissociation between synovitis and subsequent erosive joint damage, and underestimation of active synovitis because of low sensitivity of current clinical assessments. The limitations associated with remission criteria based solely on clinical assessments outlined above have fostered an interest in imaging modal-

Personal non-commercial use only. The Journal of Rheumatology Copyright © 2014. All rights reserved.

Downloaded on April 24, 2024 from www.jrheum.org

ities as adjunctive instruments to document disease remission[17].

Imaging techniques, such as ultrasonography (US) and magnetic resonance imaging (MRI), can directly visualize and objectively quantify synovial inflammation. Several studies have highlighted the superior sensitivity of these imaging modalities over clinical assessment in the detection of synovial inflammation[18,19,20,21]. In particular, they have the resolution to reveal low levels of synovitis often noted during clinical remission. Several studies have demonstrated active synovitis detected by MRI and US during clinical remission [ACR and/or Disease Activity Score at 28 joints (DAS28) criteria] in patients with RA[22,23,24]. A central question that remains to be addressed, however, is whether these abnormal findings on US and MRI in patients represent active synovial inflammation capable of mediating joint destruction. The finding that subclinical inflammation recorded by US and MRI may predict subsequent radiographic progression in clinically asymptomatic patients provides preliminary support for a direct connection between smoldering synovitis and joint destruction in patients in low disease states or remission[25]. Thus, we hypothesize that abnormal imaging findings on MRI and US noted during clinical remission represent active inflammation. To address this hypothesis, we conducted a retrospective analysis to examine whether patients with RA who meet remission criteria manifest inflammatory synovitis. We performed histological analysis of joint tissue retrieved at the time of orthopedic surgery and correlated histologic findings with US and MRI data.

MATERIALS AND METHODS

Clinical data. We conducted a single-center retrospective, observational study between December 2006 and June 2011. All patients were followed in the Rheumatology Clinic at the University of Rochester Medical Center. Our study protocol was approved by the local institutional review board. Records of patients with RA who had pathology specimens at the time of elective orthopedic surgery were retrieved. The following clinical data were collected from the records: joint assessments, C-reactive protein (CRP; within a month prior to surgery), patient's global assessment, rheumatoid factor (RF) and anticyclic citrullinated peptide antibodies (anti-CCP) status, year of RA diagnosis, and age at time of surgery.

Histology. Tissue was collected from patients in remission based on the revised ACR (1996) criteria from 1 up to 4 months prior to surgery. Further, our study was restricted to patients who underwent joint surgeries or synovial biopsies for indications other than active RA (Table 1). The synovial tissue was graded based on a modification of the scoring system proposed by Krenn, *et al*, and was performed on routine H&E slides[26]. Histological grading was based on the presence and degree of synovial lining hyperplasia and the amount of papillary formation, cellularity of the synovial stroma, extent of inflammatory infiltrate, number of lymphoid follicles, and the degree of vascularity on a scale of 0–4 (absent, minimal, mild, moderate, and severe). Table 2 depicts the details of the scoring system. Scoring was performed by 2 pathologists and a consensus score was calculated. Both pathologists were blinded to the clinical measures, imaging scores, and treatment regimens for the individual patients. A total histology score was calculated by adding the individual scores (0–20). The total histology scores were further classified as representing minimal (0–5), mild (6–10), moderate (11–15), or severe (16–20) inflammation.

Imaging. The most recent plain radiographs of hands and feet, obtained as standard of care in all patients, were assessed for the presence of erosions by a radiologist and a rheumatologist. US and MRI performed within a 4-month period prior to surgery were retrieved and scored. US images were assessed for synovitis on greyscale and Doppler signal based on the Outcome Measures in Rheumatology Clinical Trials definitions[27]. A semiquantitative scoring method was used to score for synovial hypertrophy on greyscale where 0 = no synovial hypertrophy, 1 = mild hypertrophy, 2 = moderate hypertrophy, and 3 = severe hypertrophy[19]. Power Doppler (PD) signals were scored as follows: 0 = no signal, 1 = single vessel dots over synovial tissue, 2 = confluent Doppler signals over less than half of visible synovial tissue, and 3 = Doppler signals over more than half of the visible synovial tissue. The US examinations were performed and interpreted by a rheumatologist experienced in musculoskeletal ultrasound who was not aware of clinical status, treatment regimen, or histology

Table 1. Patient demographics, disease duration, reasons for surgery, treatment, and total synovial scores for the 14 patients.

Patient	Sex	Age at Time of Biopsy, yrs	Disease Duration, yrs	Reason for Surgery	Treatment	Synovial Score	DAS28
1	F	49	8	Carpal tunnel release	ADA, MTX	8	2.4
2	F	67	2	Suspected giant cell tumor of tendon sheath	MTX, HCQ	13	2.1
3	M	63	3	Distal ulna hemi resection	MTX, HCQ	12	2.3
4	F	47	20	Shoulder arthroplasty	ETN	5	2.5
5	F	46	1	TKR	MTX	18	2.6
6	F	53	1	Left TKR	MTX	17	2.6
6	F	53	1	Right TKR	MTX	12	2.4
7	F	73	2	THR	MTX	15	2.4
8	F	62	7	Repair of FPL tendon rupture	MTX, PRED	12	NA
9	F	60	2	TKR	ETN, MTX	9	2.5
10	F	67	2	TKR	SSZ, HCQ, PRED	20	NA
11	F	63	20	Arthroscopy for persistent elbow swelling	ADA	11	2.9
12	M	71	3	THR	MTX	3	2.1
13	F	61	20	Carpal tunnel release	MTX, HCQ	18	2.3
14	F	60	3	Carpal tunnel release	MTX, HCQ	9	2.6

DAS28: Disease Activity Score at 28 joints; ADA: adalimumab; MTX: methotrexate; HCQ: hydroxychloroquine; ETN: etanercept; TKR: total knee replacement; FPL: flexor pollicis longus; PRED: prednisone; SSZ: sulfasalazine; THR: total hip replacement; NA: not available.

Personal non-commercial use only. The Journal of Rheumatology Copyright © 2014. All rights reserved.

Downloaded on April 24, 2024 from www.jrheum.org

Table 2. Morphological features of the scoring system used to grade the synovial specimens.

Hyperplasia of the synovial lining:
0 = no thickening of synovial lining and no papillary formation
1 = lining of 2–3 layers and/or suggestive papillary formation
2 = lining of 3–4 layers and/or some formation of papillae
3 = lining of 4–5 layers and/or definite papillary formation
4 = lining of more than 5 layers and/or extensive papillary formation
Scoring for cellularity of the stroma:
0 = apparent normal cellularity
1 = minimally increased cellularity
2 = mildly increased cellularity
3 = moderately increased cellularity
4 = markedly increased cellularity
Scoring for inflammation:
0 = no apparent inflammatory response
1 = a few lymphocytes and/or plasma cells
2 = some lymphocytes and/or plasma cells
3 = many lymphocytes and/or plasma cells
4 = abundant lymphocytes and/or plasma cells
Scoring for vascularity:
0 = apparent normal vascularity
1 = increase of small vessels, predominantly at the base
2 = increase of predominantly small vessels, some reaching into papillary formations
3 = increase of vessels into papillary formations, larger vessels appearing at the base
4 = larger vessels at base and extending into papillary formation
Scoring for lymphoid follicles:
0 = no lymphoid follicles identified
1= rare lymphoid follicles
2 = scattered lymphoid follicles, predominantly at the base
3 = some lymphoid follicles at base and within papillary formations
4 = many lymphoid follicles at base and within papillary formations

scores. Images were obtained with high frequency US machines [SonoSite M-Turbo unit with a 14 MHz linear transducer (SonoSite) and/or an Ultrasonix unit with a 14 MHz linear transducer (Ultrasonix)]. The MRI were scored for synovial proliferation, bone marrow edema (BME), effusion, and erosion by 2 radiologists who were not aware of the treatment regimen or histology scores. Each variable was scored on a semiquantitative scale (0 = no signal, 1 = mild, 2 = moderate, and 3 = severe)[28]. A consensus score was calculated for each of these features. All MRI studies were performed using a 1.5 T superconductive magnet (GE Signa). The imaging protocol comprised 1 of the 3 orthogonal planes: T1-weighted, fast spin echo; intermediate-weighted with fat saturation and short-tau inversion recovery; and pre- and post-IV contrast sequences with fat saturation.

Statistical analysis. The Spearman correlation coefficient was calculated to assess the relationship between scores for hyperplasia of synovial lining on histology and greyscale score on US, and between vascularity scores on histology and scores for PD signal on US. The same method was used to determine correlation between the scores of hyperplasia of synovial lining on histopathology and synovitis on MRI.

RESULTS

A total of 15 synovial specimens from 14 patients (1 patient had 2 knee replacements at different times) were obtained from patients undergoing elective orthopedic surgery for a variety of indications. Twelve of 14 patients had complaints of joint pain, but all patients met the ACR remission criteria. Eleven of 14 patients also met the DAS28 criteria for remission (1 patient had low disease activity and DAS28 was not available for 2 patients because of missing variables). Synovial specimens were obtained from patients undergoing elective orthopedic surgery for a variety of indications other than active RA (Table 1). Most surgeries (5 knee replacements, 2 hip replacements, and 1 shoulder arthroplasty) were performed for severe degenerative joint disease, 3 for treatment of carpal tunnel syndrome, 1 for suspected giant cell tumor of tendon sheath, 1 for the repair of a ruptured tendon secondary to trauma, and another for persistent pain suspected to be attributable to benign tumor/bone cyst. One patient presented with elbow swelling without pain in the setting of a 20-year history of RA and arthroscopy was performed based on imaging studies suggestive of tenosynovitis. CRP was normal in 13 of 15 cases.

Thirteen of the 14 patients had a positive RF, 12 were positive for anti-CCP. Twelve patients had erosive disease on radiographs. The mean age was 61 years with median disease duration of 3 years (range 1–20 yrs). Four of the 14 patients were receiving anti-tumor necrosis factor (anti-TNF) therapies [2 undergoing monotherapy and 2 combined with methotrexate (MTX)], 4 patients were undergoing MTX monotherapy, 4 were taking MTX and hydroxychloroquine (HCQ), 1 was taking MTX and low-dose prednisone, and 1 was taking HCQ, sulfasalazine (SSZ), and low-dose prednisone. Table 1 provides the details on demographics, treatment regimens, surgical indications, and treatment regimens.

Histology. A total of 15 synovial specimens were obtained from the knee (5), wrist (5), hip (2), elbow (1), shoulder (1), and thumb (1). The median synovitis score for the 15 specimens was 12. Four specimens had synovial scores in the severe range, 6 in the moderate range, 3 in the mild, and 2 in minimal range. Thickening of the synovial lining and inflammatory infiltrate were seen in all specimens. The inflammatory infiltrate consisted mainly of lymphoplasmacytic cells that were present in all specimens while neutrophilic infiltrates were identified in 6 tissue samples. An increase in cellularity of the stroma and vascularity was noted in 14 of the 15 specimens, and lymphoid follicles were detected in 7 specimens. Histology and imaging scores are listed in Table 3.

Interestingly, 3 of 5 subjects with minimal and mild synovitis scores on histology were receiving anti-TNF therapy (Figures 1a and 1b). The other 2 patients with minimal or mild synovitis scores were taking MTX: 1 was taking MTX and HCQ, and the other was taking MTX monotherapy. Five patients had moderate synovitis scores: 1

Personal non-commercial use only. The Journal of Rheumatology Copyright © 2014. All rights reserved.

Downloaded on April 24, 2024 from www.jrheum.org

Table 3. Scores for histology, US, and MRI.

Patient	Histology						US		MRI			
	HSL	SSC	INF	LF	VAS	TOTAL	GS	PD	BME	SYN	EFF	ERO
1	2	2	2	0	2	08	2	2	3	3	0	3
2	2	3	4	0	3	13	3	2	3	3	3	1
3	3	3	4	0	2	12	—	—	—	—	—	—
4	1	1	2	0	1	05	0	0	—	—	—	—
5	4	4	4	3	3	18	—	—	0	0	2	0
6 (L)	3	3	4	3	4	17	1	0	—	—	—	—
6 (R)	2	2	2	2	4	12	1	1	3	3	0	1
7	3	3	3	3	3	15	1	1	3	3	1	0
8	3	3	3	0	3	12	—	—	—	—	—	—
9	2	2	2	0	3	09	2	1	—	—	—	—
10	4	4	4	4	4	20	—	—	—	—	—	—
11	3	2	4	0	2	11	3	0	2	3	3	3
12	1	0	1	0	1	03	0	0	—	—	—	—
13	4	4	4	3	3	18	—	—	1	3	0	1
14	2	2	3	0	2	09	3	2	—	—	—	—

US: ultrasound; MRI: magnetic resonance imaging; HSL: hyperplasia of synovial lining; SSC: cellularity of synovial stroma; INF: inflammatory infiltrate; LF: lymphoid follicles; VAS: vascularity; TOTAL: total histology score; GS: greyscale; PD: power Doppler; BME: bone marrow edema; SYN: synovitis; EFF: effusion; ERO: erosion; L: Left; R: Right.

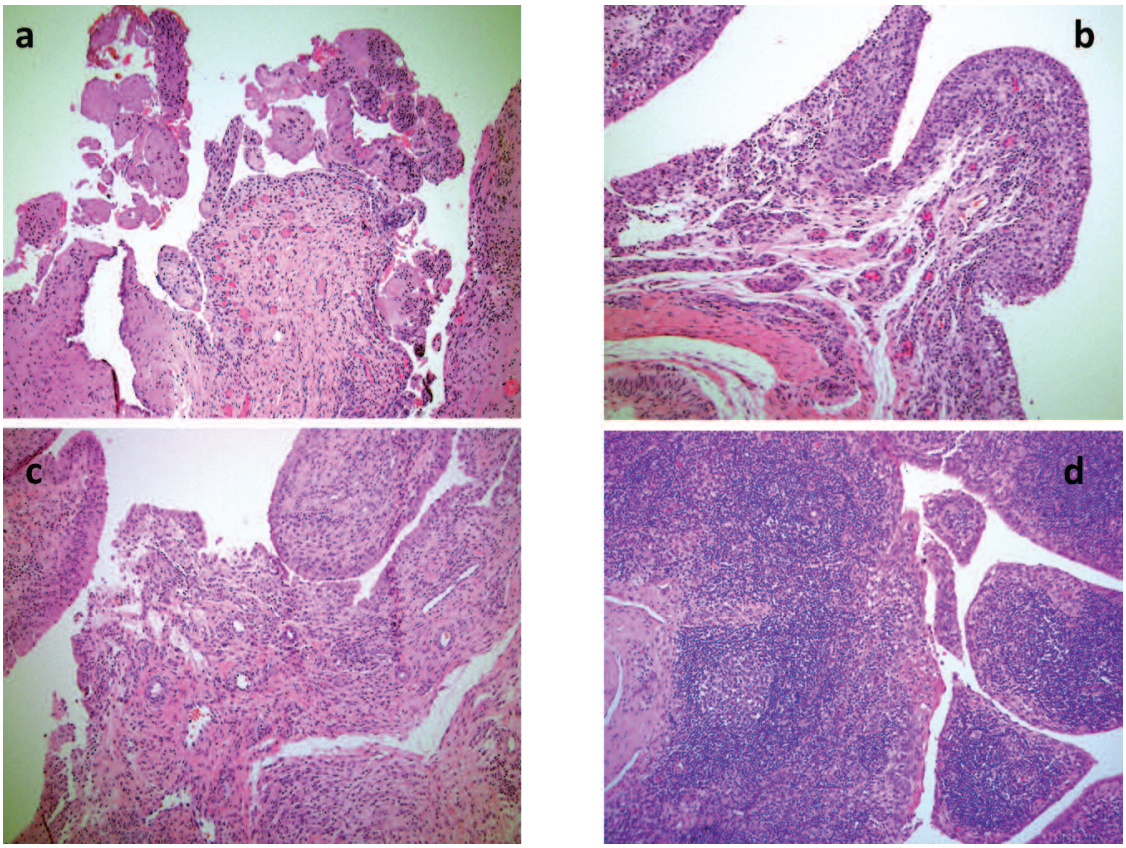

Figure 1. (a) Histology for Patient 4 shows minimal disease activity in a patient receiving anti-TNF therapy. There is early papillary formation with some lymphocytic infiltrate and scattered small vessels. (b) Histology for Patient 1 shows mild disease activity in a patient receiving anti-TNF therapy. There is slight papillary formation with a mild increase in lymphocyte infiltrate with some small vessels. (c) Histology for Patient 2 shows moderate disease activity in a patient receiving methotrexate (MTX) and hydroxychloroquine (HCQ). There is papillary formation with moderate lymphocytic infiltrate and easily identifiable vasculature extending into the papillary formation. (d) Histology for Patient 14 shows high disease activity in a patient receiving MTX and HCQ. There is extensive papillary formation with prominent lymphoplasmacytic infiltrate with germinal center formation. TNF: tumor necrosis factor.

Personal non-commercial use only. The Journal of Rheumatology Copyright © 2014. All rights reserved.

Downloaded on April 24, 2024 from www.jrheum.org

of these was receiving anti-TNF therapy, 2 were taking a combination of MTX and HCQ (Figure 1c), 1 was undergoing MTX therapy, and the other was taking MTX and prednisone. Among the 4 patients with severe synovitis scores: 2 were receiving a combination of MTX and HCQ (Figure 1d), 1 was undergoing MTX monotherapy, and the other was receiving a combination of SSZ, HCQ, and prednisone.

Imaging. US images were available for 10 joints (9 patients). Synovitis on greyscale was noted in 8 of 10 joints and Doppler signal was noted in 6 of 10 joints (Figure 2). The median score for all images on greyscale was 1.5 and the median Doppler score was 1.0. Five patients with moderate or severe scores for hyperplasia of synovial lining, had moderate or severe disease activity scores on US, and 2 patients with minimal hyperplasia of synovial lining had no evidence for synovial hypertrophy on greyscale. However, no significant correlation was noted between synovial hypertrophy on US and hyperplasia of synovial lining on histology ($r = 0.4$, $p = 0.3$). Three patients with moderate to severe scores on vascularity also had high scores for Doppler, and 2 patients with minimal to mild vascularity scores had low or no signals on PD. A positive but not significant correlation was noted between PD signal and degree of vascularity ($r = 0.2$, $p = 0.5$).

In the 7 patients who had MRI studies, 6 images showed synovitis and BME. The median scores for synovitis and BME were 3 (Figure 3). Erosions and effusions were seen in 5 of the 7 subjects, and the median score for erosions and effusions for all patients was 1. The 2 patients without erosions on MRI had no erosions on the radiographs of hands and feet. Six of 7 patients with moderate to severe scores for synovial hyperplasia also had high scores for synovial proliferation. There was no statistical correlation between synovial scores on MRI and synovial hyperplasia on histology, which may have been related to the small sample size. Other possibilities include the use of a scoring system that has not been validated (scoring MRI in RA has only been validated in the hands), and to date, MRI scoring methods have not been correlated with synovial pathology.

Figure 3. MRI of elbow (sagittal, fat-suppressed post- gadolinium) demonstrates the presence of synovitis (arrow) in Patient 13. MRI: magnetic resonance imaging.

DISCUSSION

A major challenge for rheumatologists is the development of remission criteria that truly reflect both the absence of

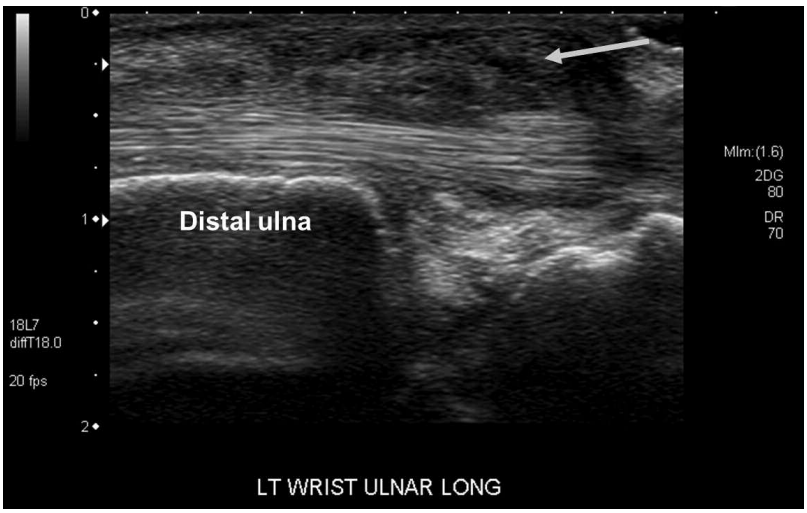

Figure 2. Long axis view of left wrist shows synovitis on greyscale (arrow) in Patient 15.

Personal non-commercial use only. The Journal of Rheumatology Copyright © 2014. All rights reserved.

Downloaded on April 24, 2024 from www.jrheum.org

clinical signs and symptoms and histologic features associated with progressive damage in the individual patient. The current outcome measures fall short of this goal and a major gap to be addressed is accurate and reliable methods to detect active synovitis in patients deemed to be in clinical remission. As a first step to address the validity of these remission assessments as true measures of disease quiescence, we performed an observational study and found that patients with RA in remission by the ACR criteria demonstrated active synovitis on histology, US, and MRI. We were unable to find significant correlations between findings on US (synovial hypertrophy, power Doppler signals) and histologic features (synovial thickening and vascularity), or between MRI findings and histology. This may reflect the small sample size, sampling error, potential differences in the pathology sampling versus imaging area or insensitivity of the imaging instruments, and scoring system. Nevertheless, the results of our study show that inflammatory changes, detected on US and MRI in patients in clinical remission, do represent areas with ongoing disease activity and provide potential insight into the mechanisms that underlie progression of joint damage despite clinical remission.

The control of signs and symptoms and prevention of joint damage are essential elements in the comprehensive management of RA. It is generally accepted that these goals may be achieved by targeting remission through the use of defined outcome measures[3,29]. Several studies, however, have demonstrated that patients in clinical remission frequently manifest abnormal signals on US and MRI, and these findings underscore the poor sensitivity of the traditional methods to assess synovitis and may explain the lack of association between clinical status and outcome[22,23,24,25]. Therefore, to establish the relationship between findings on imaging studies with histopathology, we performed a retrospective, observational study of patients with RA in remission who underwent elective orthopedic surgery to treat joint problems not considered related to active arthritis. In our study, we found synovitis on US greyscale in 8 of 10 subjects (80%) and PD signal in 6 of 10 (60%) subjects. These findings are similar to those of Brown, *et al*, who reported synovial hypertrophy on greyscale (84.9%) and presence of PD signal (60.4%) in the majority of US examinations of patients with RA receiving disease-modifying antirheumatic drug therapy and who were determined to be in clinical remission[22]. We also noted synovitis and BME in 6 of the 7 (85.7%) MRI scans. Brown, *et al* detected synovitis (92.6%) and BME (55.2%) on the MRI in their cohort of patients. Wakefield, *et al* also detected synovitis on greyscale in 35.1% and by PD in 6.6% of clinically normal joints in 10 patients with early RA treated with a combination of anti-TNF agents and MTX therapy, and who were determined to be in clinical remission[23]. These findings suggest that synovitis on US and MRI corresponds to the presence of subclinical inflammation despite clinical remission, and underscores a disconcerting disparity between clinical and imaging definitions of remission.

Disease activity in RA is characterized by hyperplasia of the synovial lining and marked infiltration of the sublining layer by inflammatory cells that produce cytokines, which in turn can result in joint damage[30,31,32,33,34,35,36]. Additionally, several studies have demonstrated an association between synovial enhancement on US and MRI, and synovitis on histology in patients with RA[20,37]. However, to our knowledge, ours is the first study to compare histopathology and imaging findings in patients with RA during remission. We found hyperplasia of the synovial lining with inflammatory infiltrates in all pathology specimens. Cellularity of the synovial stroma and increased vascularity were identified in 14 of 15 tissue samples. We also noted a relationship between the presence of synovial inflammation on imaging and on histology. Thus, a reasonable interpretation of our data is that abnormal signals on MRI and US identify regions of persistent synovitis which, in turn, may explain the underlying pathophysiology for progression of joint damage during states of clinical remission. In addition, the finding of BME in most patients may signify ongoing osteitis with a strong probability for continued joint damage[38,39,40].

Several studies have highlighted the significant decrease in radiographic progression in patients treated with anti-TNF-α agents[2,41,42]. On the other hand, recent publications demonstrated that some patients in clinical remission receiving MTX therapy continue to experience progression of joint damage[43]. Interestingly, in our study, 3 of the 4 patients receiving anti-TNF-α therapy had minimal or mild synovitis scores (Figures 1a and 1b). These results contrast with the 3 of the 4 patients (4 of 5 specimens) taking MTX monotherapy who had moderate to severe synovitis scores. The finding of minimal or mild synovial disease on histology in the patients receiving anti-TNF therapy may explain the greater inhibition of structural damage observed with the use of anti-TNF agents and, conversely, explain the mechanism for radiographic progression in patients judged to be in clinical remission while taking MTX. These results must be interpreted with caution, however, based on the small sample size.

Our study has several limitations. Ours was an observational study and remission was diagnosed by a single investigator based on a review of the medical records[1,2]. It is possible that the histologic changes in some of the synovial tissues reflect synovitis secondary to osteoarthritis (OA). We anticipated this potential problem and modified the scoring method to include the extent of vascularity and the number of lymphoid follicles — features that are important in the pathophysiology of RA[19,44,45,46]. The high scores for disease activity in the histology samples coupled with the presence of increased vascularity and number of lymphoid

Personal non-commercial use only. The Journal of Rheumatology Copyright © 2014. All rights reserved.

Downloaded on April 24, 2024 from www.jrheum.org

follicles in the majority of tissues suggest that the synovial specimens in our studies were from RA and not OA synovium. Another potential limitation is that US and MRI evaluations were scored retrospectively, and had been obtained for reasons other than future scoring of synovitis (e.g., assessment of effusion).

We found that patients in clinical remission based on the 1996 ACR criteria had evidence of disease activity on histology, as well as on US and MRI. Taken together with previous findings that showed radiographic progression during remission in RA, our data suggest that traditional clinical approaches such as the ACR remission criteria and the DAS28 criteria lack the sensitivity to accurately detect synovitis and assess true remission states. We conclude that despite clinical remission, histology and imaging studies documented a persistently active disease state that may benefit from more aggressive therapy. Thus, additional prospective studies should be performed to examine whether imaging data should be incorporated into remission assessments.

REFERENCES

1. Mader R, Keystone E. Optimizing treatment with biologics. J Rheumatol Suppl 2007;80:16-24.
2. Goekoop-Ruiterman YP, de Vries-Bouwstra JK, Allaart CE, van Zeben D, Kerstens PJ, Hazes JM, et al. Clinical and radiographic outcomes of four different treatment strategies in patients with early rheumatoid arthritis (the BeSt study): a randomized, controlled trial. Arthritis Rheum 2005;52:3381-90.
3. Smolen JS, Aletaha D, Bijlsma JW, Breedveld FC, Boumpas D, Burmester G, et al. Treating rheumatoid arthritis to target: recommendations of an international task force. Ann Rheum Dis 2010;69:631-7.
4. Pinals ES, Masi AT, Larsen RA. Preliminary criteria for clinical remission in rheumatoid arthritis. Arthritis Rheum 1981:24;1308-15.
5. Prevoo ML, van Gestel AM, van T Hof MA, van Rijswijk MH, van de Putte LB, van Riel PL. Remission in a prospective study of patients with rheumatoid arthritis. American Rheumatism Association preliminary remission criteria in relation to the disease activity score. Br J Rheumatol 1996;35:1101-5.
6. ven der Heijde DM, van 't Hof MA, van Riel PL, Theunisse LA, Lubberts EW, van Leeuwen MA, et al. Judging disease activity in clinical practice in rheumatoid arthritis: first step in the development of a disease activity score. Ann Rheum Dis 1990;49:916-20.
7. van der Heijde DM, van 't Hof M, van Riel PL, van de Putte LB. Development of a disease activity score based on judgment in clinical practice by rheumatologists. J Rheumatol 1993;20:579-81.
8. van Gestel AM, Prevoo MI, van 't Hof M, van Rijswijk MH, van de Putte LB, van Riel PL. Development and validation of the European League Against Rheumatism response criteria for rheumatoid arthritis. Comparison with the preliminary American College of Rheumatology and the World Health Organization/International League Against Rheumatism Criteria. Arthritis Rheum 1996;39:34-40.
9. Prevoo ML, van't Hof MA, Kuper HH, van Leeuwen MA, van de Putte, van Riel PL. Modified disease activity scores that include twenty-eight-joint counts: development and validation in a prospective longitudinal study of patients with rheumatoid arthritis. Arthritis Rheum 1995;35:1101-5.
10. Sesin CA, Bingham CO. Remission in rheumatoid arthritis: wishful thinking or clinical reality? Semin Arthritis Rheum 2005;35:185-96.
11. Mulherin D, Fitzgerald O, Bresnihan B. Clinical improvement and radiological deterioration in rheumatoid arthritis: evidence that the pathogenesis of synovial inflammation and articular erosions may differ. Br J Rheumatol 1996;35:1263-8.
12. Molenaar ET, Vaskuyl AE, Dinant HJ, Bezemer PD, Boers M, Dijkmans BA. Progression of radiological damage in patients with rheumatoid arthritis in clinical remission. Arthritis Rheum 2004;50:36-42.
13. Cohen G, Gossec L, Dougados M, Cantagrel A, Goupille P, Daures JP, et al. Radiological damage in patients with rheumatoid arthritis on sustained remission. Ann Rheum Dis 2007;66:358-63.
14. Lee J, Lee SK, Suh JS, Yoon M, Song JH, Lee CH. Magnetic resonance imaging of the wrist in defining remission of rheumatoid arthritis. J Rheumatol 1997;24:1303-8.
15. Paulus HE. Defining remission in rheumatoid arthritis: what is it? Does it matter? J Rheumatol 2004;31:1-4.
16. Smolen JS, Han C, Bala M, Maini RN, Kalden JR, van der Heijde D, et al. Evidence of radiographic benefit of treatment with infliximab plus methotrexate in rheumatoid arthritis patients who had no clinical improvement: a detailed subanalysis of data from the anti-tumor necrosis factor trial in rheumatoid arthritis with concomitant therapy study. Arthritis Rheum 2005;52:1020-30.
17. Wakefield RJ, D'Agostino MA, Naredo E, Buch MH, Iagnocco A, Tersley L, et al. After treat-to-target: can a targeted ultrasound initiative improve RA outcomes? Postgrad Med J 2012;88:482-6.
18. Grassi W. Clinical examination versus ultrasonography: who is the winner? J Rheumatol 2003;30:908-9.
19. Karim Z, Wakefield RJ, Quinn M, Conaghan PG, Brown AK, Veale DJ, et al. Validation and reproducibility of ultrasonography in the detection of synovitis in the knee: a comparison with arthroscopy and clinical examination. Arthritis Rheum 2004;50:387-94.
20. Ostergaard M, Stoltenberg M, Løvgreen-Nielsen P, Volck B, Jensen CH, Lorenzen I. Magnetic resonance imaging-determined synovial membrane and joint effusion volumes in rheumatoid arthritis and osteoarthritis: comparison with the macroscopic and microscopic appearance of the synovium. Arthritis Rheum 1997;40:1856-67.
21. Ostendorf B, Peters R, Dann P, Becker A, Scherer A, Wedekind F, et al. Magnetic resonance imaging and miniarthroscopy of metacarpophalangeal joints: sensitive detection of morphologic changes in rheumatoid arthritis. Arthritis Rheum 2001;44:2492-502.
22. Brown AK, Quinn MA, Karim Z, Conaghan PG, Peterfy CG, Hensor E, et al. Presence of significant synovitis in rheumatoid arthritis patients with disease-modifying antirheumatic drug induced clinical remission. Arthritis Rheum 2006;54:3761-73.
23. Wakefield RJ, Freeston JE, Hensor EM, Bryer D, Quinn MA, Emery P. Delay in imaging versus clinical response: a rationale for prolonged treatment with anti-tumor necrosis factor medication in early rheumatoid arthritis. Arthritis Rheum 2007;57:1564-7.
24. McQueen FM, Stewart N, Crabbe J, Robinson E, Yeoman S, Tan PL, et al. Magnetic resonance imaging of the wrist in early rheumatoid arthritis reveals progression of erosions despite clinical improvement. Ann Rheum Dis 1999;58:156-63.
25. Brown AK, Conaghan PG, Karim Z, Quinn MA, Ikeda K, Peterfy CG, et al. An explanation for the apparent disassociation between clinical remission and continued structural deterioration in rheumatoid arthritis. Arthritis Rheum 2008;58:2958-67.
26. Krenn V, Moraqietz L, Burmester GR, Kinne RW, Mueller-Ladner U, Muller B, et al. Synovitis score; discrimination between chronic low-grade and high grade synovitis. Histopathology 2006;49:358-64.
27. Wakefield RJ, Balint PV, Szkudlarek M, Filippucci E, Backhaus M, D'Agostino MA, et al. Musculoskeletal ultrasound including definitions for ultrasonographic pathology. J Rheumatol

Personal non-commercial use only. The Journal of Rheumatology Copyright © 2014. All rights reserved.

Downloaded on April 24, 2024 from www.jrheum.org

2005;32:2485-7.
28. Anandarajah AP, Ory P, Salonen D, Feng C, Wong RL, Ritchlin CT. Effect of adalimumab on joint disease: features of patients with psoriatic arthritis detected by magnetic resonance imaging. Ann Rheum Dis 2010;69:206-9.
29. Felson DT, Smolen JS, Wells G, Zhang B, van Tuyl LH, Funovits J, et al. American College of Rheumatology/European League Against Rheumatism provisional definition of remission in rheumatoid arthritis for clinical trials. Arthritis Rheum 2011;63:573-86.
30. Walsh NC, Crotti TN, Goldring SR, Gravallese EM. Rheumatic diseases: the effects of inflammation on bone. Immunol Rev 205;208:228-51.
31. Gerlag DM, Tak PP. Novel approaches for the treatment of rheumatoid arthritis: lessons from the evaluation of synovial biomarkers in clinical trials. Best Pract Res Clin Rheumatol 2008;22:311-23.
32. Bresnihan B, Tak PP, Emery P, Klareskog L, Breedveld F. Synovial biopsies in arthritis research: five years of concerted European Collaboration. Ann Rheum Dis 2000;59:506-11.
33. Tak PP, Smeets TJ, Daha MR, Kluin PM, Meijers KA, Brand R, et al. Analysis of the synovial infiltrate in early rheumatoid synovial tissue in relation to local disease activity. Arthritis Rheum 1997;40:217-25.
34. Kraan MC, Versendaal H, Jonker M, Bresnihan B, Post WJ, Hart BA, et al. Asymptomatic synovitis precedes clinically manifest arthritis. Arthritis Rheum 1998;41:1481-8.
35. Smith MD, Kraan MC, Slavotinek J, Au V, Weedon H, Parker A, et al. Treatment induced remission in rheumatoid arthritis patients is characterized by a reduction in macrophage content of synovial biopsies. Rheumatology 2001;40:367-74.
36. Cunnane G, Fitzgerald O, Hummel KM, Youssef PP, Gay RE, Gay S, et al. Synovial tissue protease gene expression and joint erosions in early rheumatoid arthritis. Arthritis Rheum 2001;44:1744-53.
37. Walther M, Harms H, Krenn V, Radke S, Faehndrich TP, Gohlke F, et al. Correlation of power Doppler sonography with vascularity of the synovial tissue of the knee joint in patients with osteoarthritis and rheumatoid arthritis. Arthritis Rheum 2001;44:331-8.
38. McQueen FM, Gao A, Ostergaard M, King A, Shalley G, Robinson E, et al. High-grade MRI bone marrow oedema is common within the surgical field in rheumatoid arthritis patients undergoing joint replacement and is associated with osteitis in subchondral bone. Ann Rheum Dis 2007;66:1581-7.
39. Schwarz EM, Proulx ST, Ritchlin CT, Boyce BF, Xing L. The role of bone marrow edema and lymphangiogenesis in inflammatory-erosive arthritis. Adv Exp Med Biol 2010;658:1-10.
40. Jimenez-Boj E, Nobauer-Huhmann I, Hanslik-Schnabel B, Dorotka R, Wanivenhaus AH, Kainberger F, et al. Bone erosions and bone marrow edema as defined by magnetic resonance imaging reflect true bone marrow inflammation in rheumatoid arthritis. Arthritis Rheum 2007;56:1118-24.
41. Klareskog L, van der Heijde D, de Jager JP, Gough A, Kalden J, Malaise M, et al. Therapeutic effect of the combination of etanercept and methotrexate compared with each treatment alone in patients with rheumatoid arthritis: double-blind randomised controlled trial. Lancet 2004;363:675-81.
42. Breedveld FC, Weisman MH, Kavanaugh AF, Cohen SB, Pavelka K, van Vollenhoven R, et al. The PREMIER study: A multicenter, randomized, double-blind clinical trial of combination therapy with adalimumab plus methotrexate versus methotrexate alone or adalimumab alone in patients with early, aggressive rheumatoid arthritis who had not had previous methotrexate therapy. Arthritis Rheum 2006;54:26-37.
43. Rezaei H, Saevarsdottir S, Forslind K, Albertsson K, Wallin H, Bratt J, et al. In early rheumatoid arthritis, patients with a good initial response to methotrexate have excellent 2-year clinical outcomes, but radiographic progression is not fully prevented; data from the methotrexate responder's population in the SWEFOT trail. Ann Rheum Dis 2012;71:186-91.
44. Hitchon CA, El-Gabalawy HS. The histopathology of early synovitis. Clin Exp Rheumatol 2003;Suppl 31:S28-36.
45. Timmer TC, Baltus B, Vondenhoff M, Huizinga TW, Tak PP, Verweij CL, et al. Inflammation and ectopic lymphoid structures in rheumatoid arthritis synovial tissues detected by genomics technology: identification of the interleukin-7 signaling pathway in tissues with lymphoid neogenesis. Arthritis Rheum 2007; 56:2492-502.
46. Rooney M, Whelan A, Feighery C, Bresnihan B. Changes in lymphocyte infiltration of the synovial membrane and the clinical course of rheumatoid arthritis. Arthritis Rheum 1989;32:361-9.

Personal non-commercial use only. The Journal of Rheumatology Copyright © 2014. All rights reserved.

Downloaded on April 24, 2024 from www.jrheum.org