

Experiences with Rituximab for the Treatment of Autoimmune Diseases with Ocular Involvement

Laura Pelegrin, Eva Jakob, Annette Schmidt-Bacher, Vedat Schwenger, Matthias Becker, Regina Max, Hans Martin Lorenz, and Friederike Mackensen

ABSTRACT. Objective. To report the efficacy of rituximab (RTX) in the treatment of ocular or orbital inflammation accompanying autoimmune diseases refractory to previous standard immunosuppressive therapy.

Methods. We reviewed medical records of 9 consecutive patients with noninfectious ocular or orbital inflammation treated with RTX.

Results. Over a mean followup of 42 months, 7 patients were in clinical remission, 1 had partial response to treatment, and 1 did not respond. Best corrected visual acuity improved ≥ 1 line in 4 patients, was stable in another 4 patients, and worsened in 1. Concomitant immunosuppressive therapy was tapered in 6 cases. Systemic corticosteroids were tapered or kept below 7.5 mg a day in 5 patients 1 year after the first RTX cycle.

Conclusion. RTX therapy, in patients who are refractory to standard immunosuppressive therapy, was effective and showed a beneficial response to treatment including induction of clinical remission of inflammation in most patients. (First Release Nov 15 2013; J Rheumatol 2014;41:84–90; doi:10.3899/jrheum.130206)

Key Indexing Terms:

CLINICAL REMISSION
ORBITAL INFLAMMATION

OCULAR INFLAMMATION

RITUXIMAB
GRANULOMATOUS POLYANGIITIS

Rituximab (RTX) is a chimeric human-mice monoclonal antibody directed against CD20 surface marker, localized on pre-B lymphocytes, normal, and neoplastically transformed mature B lymphocytes. RTX was registered for the first time in the United States in 1997 for the therapy of malignant non-Hodgkin lymphomas, and in Europe in 1998¹. RTX has been shown to be an effective treatment for rheumatoid arthritis (RA) in 3 randomized controlled trials and is now licensed for use in refractory rheumatic disease². In the United States, it has been approved by the Food and Drug Administration for use in combination with methotrexate (MTX) for reducing signs and symptoms in adult patients with moderate to severe RA who have had an inadequate response to 1 or more anti-tumor necrosis factor (TNF)- α

therapies. The medication is also successfully used in patients with idiopathic thrombocytopenic purpura, hemolytic anemia, and systemic lupus erythematosus^{3,4,5}. Efficacy of B cell depletion therapy with RTX has also been reported in patients with juvenile idiopathic arthritis (JIA)-associated uveitis⁶ granulomatous polyangiitis (GPA) and other antineutrophil cytoplasmic antibodies-associated systemic vasculitis^{7,8,9,10}. There is limited data available regarding the use of rituximab in diseases affecting the eye^{11,12}.

We describe 9 patients diagnosed with different types of ocular and orbital inflammation accompanying autoimmune diseases refractory to conventional therapy and other immunosuppressive drugs who were treated with RTX and who showed clinical improvement without any adverse effects.

From the Hospital Clinic de Barcelona, Universidad de Barcelona, Spain; Department of Ophthalmology, Department of Nephrology, Interdisciplinary Uveitis Center, Rheumatology Department for Internal Medicine V, University of Heidelberg, Heidelberg, Germany; and the Department of Ophthalmology, Triemli Spital, Zürich, Switzerland.

L. Pelegrin, MD, PhD, Hospital Clinic of Barcelona, University of Barcelona; E. Jakob, MD, Interdisciplinary Uveitis Center, Department of Ophthalmology, University of Heidelberg; A. Schmidt-Bacher, MD, Department of Ophthalmology, University of Heidelberg; V. Schwenger, MD, Department of Nephrology, University of Heidelberg; M. Becker, MD, PhD, Department of Ophthalmology, Triemli Spital Zürich; R. Max, MD; H.M. Lorenz, MD, Interdisciplinary Uveitis Center, Rheumatology Department for Internal Medicine V, University of Heidelberg; F. Mackensen, MD, Interdisciplinary Uveitis Center, Department of Ophthalmology, University of Heidelberg.

Address correspondence to Dr. L. Pelegrin Colás, Hospital Casa Maternidad, Instituto Clínico de Oftalmología, Calle Sabino de Arana n°1 2ª planta, 08028 Barcelona, Spain. E-mail: laurapelegrin79@hotmail.com
Accepted for publication September 3, 2013.

MATERIAL AND METHODS

Approval of the local ethics committee was obtained. We retrospectively reviewed medical records of all patients in our center treated with RTX. Cases were consecutive patients with GPA, Behçet disease, RA, and JIA whose disease was refractory to standard immunosuppressive therapy. Patients with GPA disease were evaluated separately because they were the biggest group. Patients in our center are usually managed with a step-up therapy of immunosuppressive treatment. Initially, systemic corticosteroids are administered at 1 mg/kg/day. Later, a therapy with an isolated anti-metabolite, such as MTX; a signal transduction inhibitor, such as cyclosporine; a purine synthesis inhibitor, such as azathioprine or mycophenolate mofetil acid; or an alkylating agent such as cyclophosphamide is administered depending on the type of ocular inflammation. If patients are refractory or intolerant to this therapy, switching to another immunosuppressive treatment or a combined treatment of 2 or 3 immuno-

suppressive therapies is used. In some cases, if patients still do not respond, an anti-TNF- α therapy (infliximab, etanercept, or adalimumab) would be added to immunosuppressive treatment. Patients were considered refractory to treatment if they presented persistent ocular inflammation after using all these combined therapies.

Initially, 2 doses of RTX (1000 g) were infused over several hours separated by 2 weeks. After 6 months, another cycle of treatment was repeated if ocular inflammation was not controlled. Before and after each cycle, a complete ophthalmological examination was performed. B cell counts were obtained if clinical response was lacking. Therapy failure occurred if subjective symptoms, best corrected visual acuity (BCVA), and/or signs of inflammation, such as anterior chamber or vitreous cells, scleral injection, ocular motility, or proptosis, did not improve. Intraocular inflammation was graded and evaluated per Standardization of Uveitis Nomenclature recommendations¹³. Regarding scleral injection, motility, and proptosis, no standardized grading took place but the overall clinical improvement or worsening was taken from the chart. Intolerance of RTX requiring cessation of treatment was defined as appearance of serious adverse events that can cause death or disability such as cardiac arrest, hepatitis B reactivation, or pulmonary toxicity.

We recorded BCVA as main outcome measure and secondary outcome measures as changes in patient complaints, presence of intraocular or orbital inflammation, concomitant immunosuppressive therapy requirements before and after RTX therapy, and adverse events. Snellen BCVA stabilization or an improvement of 1 line or more in either eye was considered a clinically significant change. Response to treatment was defined as a 50% reduction in ocular disease activity, which had previously required treatment escalation, in the absence of new manifestations. Remission was defined as the absence of active disease with stable maintenance immunosuppressive therapy, including prednisone at a dosage of \leq 7.5 mg/day. Relapse was defined as the recurrence or new onset of disease; major ocular relapses were defined as those involving sight-threatening disease¹¹.

Concomitant immunosuppressive therapy was tapered if the patient achieved control of inflammation. Any decrease in the number or dosage of immunosuppressive medications was recorded and considered improvement data. Patient complaints and complications due to treatment were recorded as adverse events.

RESULTS

The median patient age at disease onset was 36 (13–72) years. At the time of the first RTX cycle, patient age was 48 years with a range of 30 to 74 years. Six patients were affected by GPA (5 had orbital granulomatosis and 1 had scleritis); 1 patient had scleritis, myositis, and intermediate uveitis due to Behçet disease; and 2 patients had anterior uveitis, one associated to RA and the other to JIA. RTX therapy was administered in all cases because of refractory ocular disease to conventional immunosuppressive treatment. Before RTX therapy all patients were treated with 2 or 3 different immunosuppressive medications and with corticosteroids at 1 mg/kg/day. The clinical data, outcomes, and medications prior to and after RTX therapy for each patient are summarized in Table 1.

The mean number of RTX cycles was 3.6, with a range of 1 to 8, and the mean followup time from the first infusion was 42 months, with a range of 6 to 60 months. After achieving suppression of ocular inflammation, we were able to reduce the dosage of corticosteroids in all patients and the number of immunosuppressive therapies in 6 patients

(patients 1, 2, 4, 5, 8, and 9). Systemic corticosteroids were tapered or kept below 7.5 mg a day in 5 patients 1 year after the first RTX cycle. BCVA improved in 4 patients, was stable in 4 patients, and worsened in 1 patient. No patient experienced any adverse effects or complaints associated with the RTX treatment. Treatment was judged to be successful in 8 patients. One patient (number 3) failed.

Patient 1 was diagnosed with seronegative, cyclic citrullinated peptide–negative RA with erosive joint damage in 1985 at the age of 36 and was treated with MTX, azathioprine, hydroxychloroquine, leflunomide, and a combination of cyclosporine and MTX. In 2000, infliximab was given in combination to MTX with improvement, but was stopped because of thrombocytopenia in 2002. Therapy was switched to etanercept. In 2004, she developed anterior uveitis with macular edema in her left eye. This did not respond sufficiently to local treatment (prednisolone drops and triamcinolone orbital floor injections). Therefore, she was switched to adalimumab in 2005. With this her arthritis worsened dramatically, so after only 2 months, the patient changed back to etanercept, with improvement of arthritis. Uveitis was partially controlled with repeated periocular triamcinolone injections and topical therapy. Cataract extraction was necessary in 2006. After this, repeated intravitreal triamcinolone injections were needed every 4 to 5 months. Macular edema improved but never resolved completely. In 2007, moderately elevated intraocular pressure was noted. The first dose of RTX was given in July 2007. B cell depletion was confirmed in November 2007. Repeated infusions were performed regarding joint activity every 8 to 10 months at first. Joints improved, but relapsing macular edema required another intravitreal injection in October 2007 and October 2008, and a periocular in July 2009. Glaucomatous changes of the optic disc were noted in September 2009. Finally, RTX infusions were given in regular 6-month intervals from October 2009 to date (October 2011). With this, uveitis and joints were equally well controlled and no more injections or topical treatments were needed. Oral corticosteroids were tapered to 5 mg prednisone. BCVA improved 1 line to 20/32. Intraocular pressure was normal (17 mmHg), and central retinal thickness measurements by optical coherence tomography were normal.

Patient 2 was diagnosed with JIA in early childhood. In 1993, at 13 years of age, anterior uveitis was detected. She was treated with leflunomide, azathioprine, cyclosporine, and oral and topical steroids. In 2000, etanercept was introduced, which improved joints but was insufficient to control uveitis activity. In 2005, she was switched to infliximab with subsequent improvement. After 1 year, loss of effect was suspected as uveitis activity increased again. A switch to adalimumab led to improvement, but it was short-lived. Only 9 months later, the first RTX infusion was given, as the eyes and joints were active again. This led to improvement

Table 1. Demographic data and treatment before and after rituximab (RTX) therapy.

ID	Sex	Age at Onset of Ocular Inflammation, yrs	Ocular Disease	Systemic Disease	Number of RTX Cycles	Treatment Before RTX (Besides Corticosteroids and MTX)	BCVA Before RTX	BCVA 1 Year After First RTX Cycle	Prednisone Dose Before RTX	Prednisone Dose 1 Year After First RTX Cycle	Followup, Mos	Treatment Combined with RTX*
1	Female	55	Anterior uveitis, ME	RA	8	Azathioprine, hydroxychloroquine, leflunomide, cyclosporine A, infliximab, etanercept, adalimumab	20/32	20/25	5 mg	5 mg	51	Leflunomide
2	Female	13	Anterior uveitis	JIA	1	Etanercept, infliximab, adalimumab, cyclosporine A, leflunomide, azathioprine	20/200	NA	7.5 mg	NA	5	MTX
3	Female	26	Scleritis, myositis, intermediate uveitis	Behcet	1	Cyclophosphamide, cyclosporine A, azathioprine, etanercept, infliximab, interferon α	Light projection	Eye enucleated	40 mg	20 mg	60	MTX
4	Male	67	Scleritis	GPA (cANCA+, kidney, skin, nose, joints and nerves)	2	Cyclophosphamide, azathioprine, mycophenolate, MTX	20/25	20/25	20 mg	5 mg	48	MTX
5	Female	72	Inflammatory orbital disease	GPA (ANCA-, locoregional)	2	Cyclophosphamide, azathioprine	LP	20/400	0	0	26	MTX
6	Female	31	Inflammatory orbital disease	GPA (cANCA+, locoregional)	3	Cyclophosphamide, azathioprine, MTX	20/20	20/20	30 mg	11 mg	60	Mycophenolate
7	Male	36	Inflammatory orbital disease	GPA (cANCA+, lung, nose)	6	Cyclophosphamide, MTX, leflunomide	20/20	20/20	20 mg	5 mg	54	MTX, leflunomide
8	Female	42	Inflammatory orbital disease	GPA (cANCA+, locoregional)	1	Cyclophosphamide, azathioprine	20/20	20/20	60 mg	4 mg	27	MTX
9	Male	30	Inflammatory orbital disease	GPA (cANCA+, lung and later locoregional)	8	Cyclophosphamide, azathioprine, mycophenolate	HM	20/400	100 mg	7.5 mg	48	Mycophenolate

GPA: granulomatous polyangiitis; JIA: juvenile idiopathic arthritis; RA: rheumatoid arthritis; ME: macular edema (*besides corticosteroids); LP: light projection; HM: hand movements; ANCA: antineutrophilic cytoplasmic antibodies; MTX: methotrexate; NA: not applicable; BCVA: best corrected visual acuity.

so that a cataract operation could be performed on the left eye. BCVA improved to 20/63, but postoperative uveitis activity of 1+ cells and 2+ flare on the operated eye required a periocular triamcinolone injection. The patient was lost to followup afterward, so no evaluation at 1 year took place.

Patient 3, with Behçet disease (oral and genital ulcers, arthritis, severe uveitis, scleritis, and myositis flares), was diagnosed in 1993. Treatment consisted of oral corticosteroids as well as MTX, cyclosporine, and azathioprine, which were only partially effective in controlling disease activity. Side effects, including nausea, vomiting, pancytopenia, and infections, limited treatment as well. In 2005, etanercept was added for 3 months without effect. Following this, cyclophosphamide was given, which led to improvement of uveitis after 8 months of therapy. Cyclophosphamide was stopped after 12 months with a cumulative dose of 84 g because of pancytopenia and varicella zoster virus reactivation. The patient was treated with infliximab and later with interferon- α without sufficient response and significant side effects from interferon. RTX was first given in March 2007, but did not lead to sufficient B cell depletion (> 3% CD20+ B cells). The eye was

enucleated owing to intolerable pain and no visual function in June 2007. For systemic symptoms, adalimumab was introduced in December 2007 but had to be stopped after 2 injections because of leukopenia. In 2008, leflunomide was added to MTX to reduce steroid need. In December 2008, the patient presented with sudden vision loss on her previously unaffected right eye. Optic neuritis and scleritis were diagnosed. Periocular triamcinolone injection, high-dose intravenous corticosteroids, and cyclophosphamide were given immediately but vision dropped to no light projection within 3 weeks. Mycophenolate was added to the systemic therapy. Repeated painful scleritis activity required repeated subconjunctival triamcinolone injections. In April 2010 adalimumab was given again, and in June, 200 mg cyclosporine was added to 20 mg subcutaneous MTX and adalimumab. Since then no more scleritis flares have been observed and systemic activity is better controlled as well.

All patients with GPA (patients 4–9) had been treated with cyclophosphamide and baseline immunosuppressive therapy before RTX, but were not controlled. Baseline immunosuppressive therapy was kept stable before RTX was given or was reduced for fear of side effects. Four

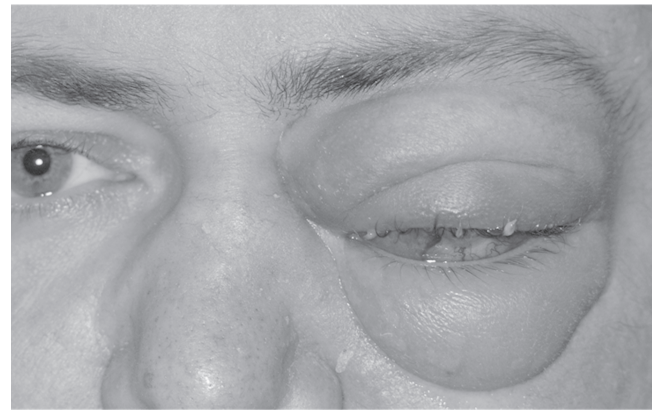patients (4, 5, 6, and 8) achieved total control of orbital and/or scleral inflammation with the addition of RTX treatment at the end of followup period. They did not require continuous RTX cycles, but could be maintained with a baseline immunosuppressive medication. Patient 7 needed another RTX cycle in June 2012 because of activity of systemic GPA after being in remission for 2 years. His orbital disease has been quiet since the second RTX cycle.

Patient 9 with GPA and orbital inflammation with proptosis improved 6 weeks after the first RTX infusions (Figure 1). Orbital inflammation improvement was also seen at magnetic resonance imaging before and after infusions (Figure 2). Unfortunately he presented at another center in the interval and did not receive his 6-month reinfusion, which made increased doses of oral corticosteroids necessary. After the flare during the time RTX was ceased, his vision dropped to no light perception. Currently, he is controlled at 2 mg prednisone and mycophenolate with regular reinfusions of RTX every 6 months. This patient was shown to have uncontrolled hepatitis B reactivation with elevated liver enzymes and very high viral load when laboratory tests were performed before RTX was started. After discussion with infectious disease specialists, therapy with tenofovir was added and viral load declined while he was taking concomitant therapy with RTX, mycophenolic acid, and high-dose steroids.

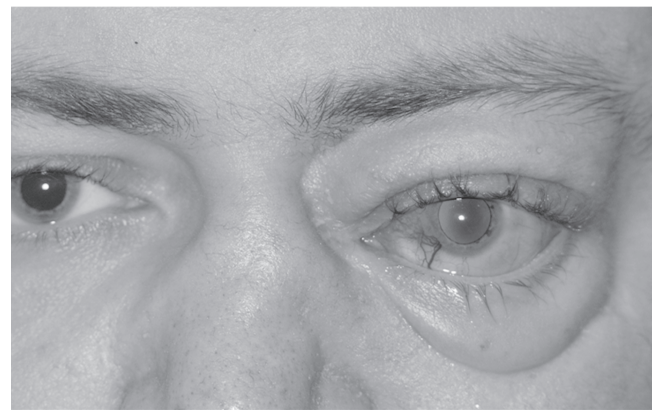DISCUSSION

We describe our clinical experiences with the use of RTX treatment in 9 patients with ocular inflammation resistant to standard immunosuppressive therapy. There were 3 patients with uveitis in our series, and 6 with ophthalmic GPA. RTX treatment was efficacious in controlling inflammation and stabilizing vision for the majority of patients in our study.

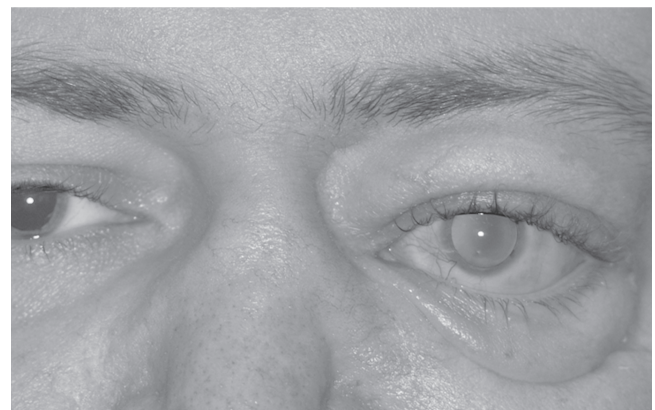We have reviewed reports about ocular GPA and there are no randomized controlled trials to support RTX use in this disease. Until now, the data available were based on case reports or case series. Recently, Joshi, *et al*¹⁴ have reported the largest case series of 20 patients with refractory ophthalmic GPA. Although relapse occurred in one-third of patients, all of them achieved remission without further relapse. Previous reports^{11,14,16,17,18,19,20} mention 15 patients with refractory ophthalmic GPA treated with RTX in whom the ophthalmic disease was driving treatment decisions and disease activity had persisted despite standard immunosuppressive therapy (prednisolone and intravenous pulses of cyclophosphamide). RTX was effective and induced remission in all cases, without concomitant post-infusional treatment in 8 cases, prednisolone with 1 immunosuppressive medication in 6 cases, and only prednisolone in 1 case. No adverse effects were detected. Taylor, *et al*¹⁵ reported a case series of 10 patients with orbital and ocular (scleritis) GPA with a beneficial response to treatment with RTX in all patients, including induction of



A



B



C

Figure 1. Patient with granulomatous polyangiitis and orbital inflammation. A. Orbital inflammation with proptosis was observed before rituximab (RTX) therapy. B. We observed improvement in orbital inflammation 4 weeks after RTX treatment. C. Proptosis and orbital inflammation were improved 6 weeks after RTX infusions.

clinical remission. Other reports^{21,22,23,24,25,26,27}, with a total of 14 patients, have described the use of RTX in patients with ophthalmic manifestations of GPA. In those cases, authors have concluded that, as opposed to vasculitis

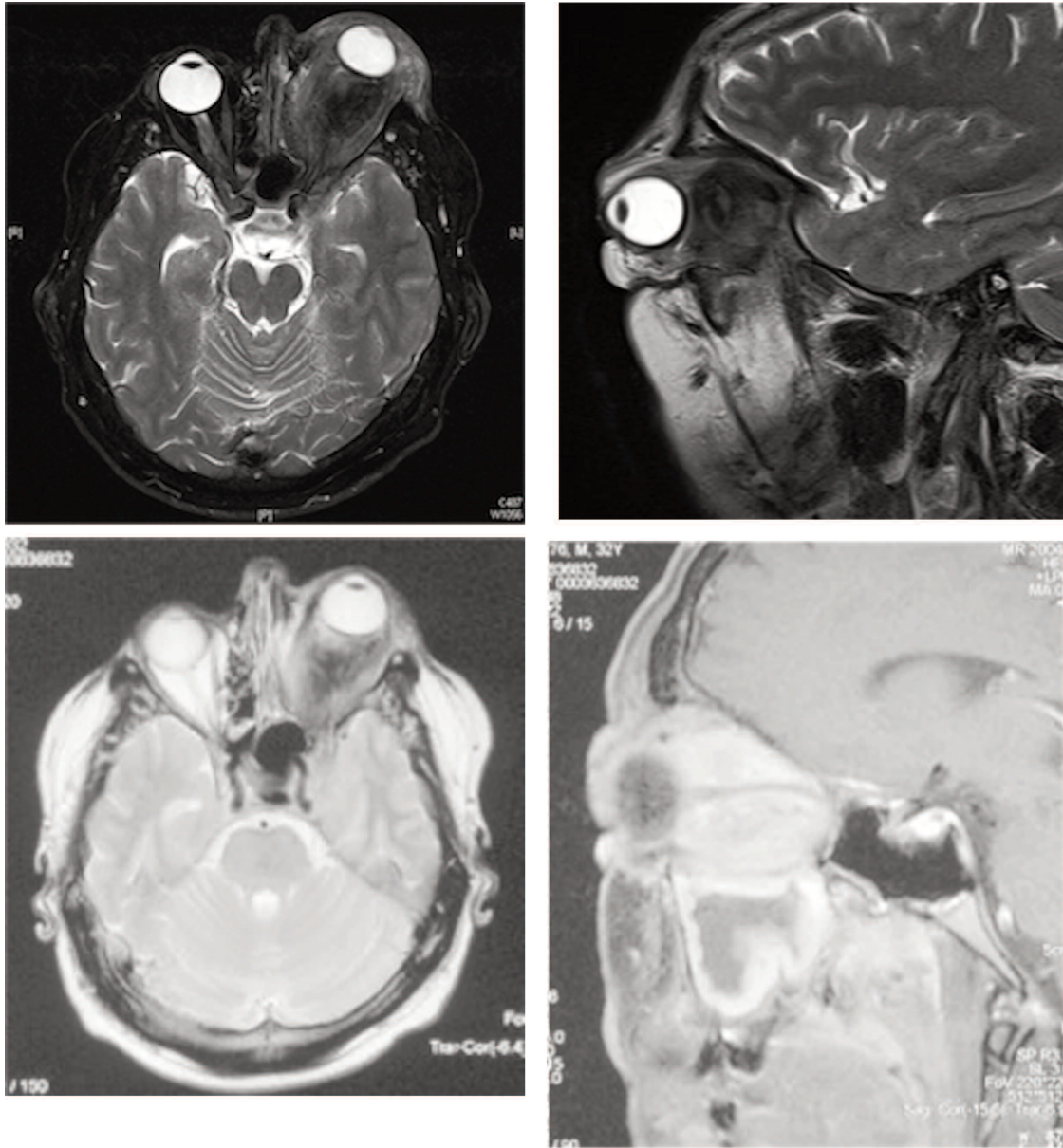


Figure 2. Magnetic resonance images (MRI) before and after rituximab (RTX) infusions. Axial (upper left) and sagittal (upper right) short-tau inversion recovery images before RTX treatment showing left exophthalmos and inflammatory tissue involving extraconal and periorbital fat. MRI 5 weeks after rituximab: Axial (lower left) and sagittal (lower right) T1-weighted images after gadolinium injection. There was persistence but improvement in both fatty infiltration and the left exophthalmos. The persistence of inflammatory reaction is evident inside the maxillary sinus and the cavernous sinus, in the sagittal view postcontrast injection.

symptoms, granulomatous orbital involvement does not respond to RTX because of the fibrotic nature of granulomas in GPA, especially when occurring retro-orbitally. Looking at our case series and the remaining literature, we see a clinical response even when granulomas do not completely disappear. To date, only 1 prospective open-label trial has reported that RTX appears to be effective for the induction and maintenance of stable remission without glucocorticoids in patients with systemic GPA who failed to respond

to cyclophosphamide or had contraindications for cyclophosphamide⁹. RTX was well tolerated in these patients and the short-term safety profile was encouraging.

In the same way, we have reviewed RTX treatment in RA and Behçet disease. Four patients with severe scleritis associated with RA refractive to conventional treatment have been reported to have had a successful response to RTX (mean time in remission 8.25 months) without any side effects^{28,29,30}. Sadreddini, *et al*³¹ reported 1 patient with

visual loss due to retinal vasculitis in Behçet disease that was resistant to prednisolone and azathioprine. This patient was treated successfully with RTX and his remission was sustained for 24 months of followup. Unfortunately, no B cell depletion could be achieved in our patient with Behçet and no response to RTX was seen.

Miserocchi, *et al*¹⁶ retrospectively evaluated the efficacy of RTX on 8 patients with JIA-associated uveitis refractory to conventional immunosuppressants and anti-TNF agents (etanercept, infliximab, adalimumab). All patients revealed improvement of intraocular inflammation around the 4th month after the first infusion of RTX without any adverse events. More recently, Heiligenhaus, *et al*⁶ published a case series of 10 patients with JIA associated uveitis and good response to RTX.

RTX appears to be a very effective medication in refractory forms of ocular and orbital inflammation to immunosuppressive therapy. In patients with JIA associated uveitis, the positive response to RTX is in agreement with previous immunohistochemical observations in these patients who show focal aggregates of CD20+ B cells³². RTX is generally well tolerated and has fewer side effects than corticosteroids. The most common side effects include infusion-related effects such as dizziness, weakness, nausea, itching, fever, or chills, which often occur within the first 24 h after the start of RTX infusion. We did not observe any side effects or complications related to RTX therapy during the mean followup time of 42 months. Still, a case series of 9 patients is not sufficiently powered to rule out side effects. In 2010, the results of the RAVE trial, performing a head to head comparison between RTX and cyclophosphamide in GPA, were published³³. Somewhat unexpected, the rate of adverse events in the RTX group was as high as in the cyclophosphamide group, with 7% developing severe infections. Severity of disease and high doses of corticosteroids probably contributed to the side effects, but the risk of different kinds of infections should always be taken into account when treating patients with RTX. Also, a report on cases of progressive multifocal leukoencephalopathy³⁴ in patients receiving RTX for RA or systemic lupus erythematosus is a concern and, in our regard, limits RTX to salvage therapy for treatment-resistant patients with ocular or orbital inflammation. Another point to be determined is the appropriate length of RTX treatment.

Our study results must be interpreted in the context of the retrospective design, small number and heterogeneity of patients, and lack of a control group. The outcome measures chosen (BCVA and ability to taper prednisone) are of clinical relevance, but have limitations in longstanding disease and only reflect part of the picture. Still, in our case series, RTX treatment was associated with stability or improvement of intraocular inflammation in 8 of 9 patients after a mean followup of 42 months. This suggests that RTX treatment may be efficacious in controlling or inducing

remission in patients with ocular and orbital inflammation. Although we would hope that this experience would be confirmed in randomized clinical trials, we conclude that RTX seems to be a useful treatment for severe ocular inflammation refractory to classical immunosuppressive therapy.

REFERENCES

1. Kowalewska B, Szechiński J, Roszkowska E. Wegener's granulomatosis effectively treated with rituximab: a case study. *Pol Arch Med Wewn* 2008;118:381-5.
2. Edwards JC, Szczepanski L, Szechinski J, Filipowicz-Sosnowska A, Emery P, Close DR, et al. Efficacy of B-cell-targeted therapy with rituximab in patients with rheumatoid arthritis. *N Engl J Med* 2004;350:2572-81.
3. Brulhart L, Ciurea A, Finckh A, Notter A, Waldburger JM, Kyburz D, et al. Efficacy of B-cell depletion in rheumatoid arthritis patients refractory to anti-tumour necrosis factor (TNF): an open label observational study. *Ann Rheum Dis* 2006;65:1255-7.
4. Emery P, Fleischmann R, Filipowicz-Sosnowska A, Schechtman J, Szczepanski L, Kavanaugh A, et al. The efficacy and safety of rituximab in patients with active rheumatoid arthritis despite methotrexate treatment: results of a phase IIB randomized, double-blind, placebo-controlled, dose-ranging trial. *Arthritis Rheum* 2006;54:1390-400.
5. Looney RJ, Anolik JH, Campbell D, Felgar RE, Young F, Arend L, et al. B cell depletion as a novel treatment for systemic lupus erythematosus: a phase I/II dose-escalation trial of rituximab. *Arthritis Rheum* 2004;50:2580-9.
6. Heiligenhaus A, Miserocchi E, Heinz C, Gerloni V, Kotaniemi K. Treatment of severe uveitis associated with juvenile idiopathic arthritis with anti-CD20 monoclonal antibody (rituximab). *Rheumatology* 2011;50:1390-4.
7. Stasi R, Stipa E, Del Poeta G, Amadori S, Newland AC, Provan D. Long-term observation of patients with anti-neutrophil cytoplasmic antibody-associated vasculitis treated with rituximab. *Rheumatology* 2006;45:1432-6.
8. Keogh KA, Ytterberg SR, Fervenza FC, Carlson KA, Schroeder DR, Specks U. Rituximab for refractory Wegener's granulomatosis: report of a prospective, open-label pilot trial. *Am J Respir Crit Care Med* 2006;173:180-7.
9. Keogh KA, Wylam ME, Stone JH, Specks U. Induction of remission by B lymphocyte depletion in eleven patients with refractory antineutrophil cytoplasmic antibody-associated vasculitis. *Arthritis Rheum* 2005;52:262-8.
10. Eriksson P. Nine patients with anti-neutrophil cytoplasmic antibody positive vasculitis successfully treated with rituximab. *J Intern Med* 2005;257:540-7.
11. Tappeiner C, Heinz C, Specker C, Heiligenhaus A. Rituximab as a treatment option for refractory endogenous anterior uveitis. *Ophthalmic Res* 2007;39:184-6.
12. Miserocchi E, Modorati G. Rituximab for noninfectious uveitis. *Dev Ophthalmol* 2012;51:98-109.
13. Jabs DA, Nussenblatt RB, Rosenbaum JT; Standardization of Uveitis Nomenclature (SUN) Working Group. Standardization of uveitis nomenclature for reporting clinical data. Results of the First International Workshop. *Am J Ophthalmol* 2005;140:509-16.
14. Joshi L, Lightman SL, Salama AD, Shirodkar AL, Pusey CD, Taylor SR. Rituximab in refractory ophthalmic Wegener's granulomatosis PR3 titers may predict relapse, but repeat treatment can be effective. *Ophthalmology* 2011;118:2498-503.
15. Taylor SR, Salama AD, Joshi L, Pusey CD, Lightman SL. Rituximab is effective in the treatment of refractory ophthalmic

- Wegener's granulomatosis. *Arthritis Rheum* 2009;60:1540-7.
16. Miserochi E, Pontikaki I, Modorati G, Bandello F, Meroni PL, Gerloni V. Rituximab for uveitis. *Ophthalmology* 2001;118:223-4.
 17. Matsudaira R, Tamura N, Nawata M, Kaneda K, Takasaki Y. Successful treatment with rituximab in a refractory Wegener's granulomatosis with hypertrophic pachymeningitis and the right orbital granuloma. *Nippon Naika Gakkai Zasshi* 2007;96:1464-6.
 18. Onal S, Kazakoglu H, Koc A, Yavuz S. Rituximab for remission induction in a patient with relapsing necrotizing scleritis associated with limited Wegener's granulomatosis. *Ocul Immunol Inflamm* 2008;16:230-2.
 19. Avshovich N, Rozenbaum M. Refractory Wegener's granulomatosis: effect of rituximab on granulomatous bilateral orbital involvement. *Isr Med Assoc J* 2009;11:566-8.
 20. Huerva V, Sanchez MC, Traveset A, Jurjo C, Ruiz A. Rituximab for peripheral ulcerative keratitis with Wegener granulomatosis. *Cornea* 2010;29:708-10.
 21. Ooka S, Maeda A, Ito H, Omata M, Yamada H, Ozaki S. Treatment of refractory retrobulbar granuloma with rituximab in a patient with ANCA-negative Wegener's granulomatosis: a case report. *Mod Rheumatol* 2009;19:80-3.
 22. Aries PM, Hellmich B, Voswinkel J, Both M, Nölle B, Holl-Ulrich K, et al. Lack of efficacy of rituximab in Wegener's granulomatosis with refractory granulomatous manifestations. *Ann Rheum Dis* 2006;65:853-8.
 23. Tamura N, Matsudaira R, Hirashima M, Ikeda M, Tajima M, Nawata M, et al. Two cases of refractory Wegener's granulomatosis successfully treated with rituximab. *Intern Med* 2007;46:409-14.
 24. Brihaye B, Aouba A, Pagnoux C, Cohen P, Lacassin F, Guillemin L. Adjunction of rituximab to steroids and immunosuppressants for refractory/relapsing Wegener's granulomatosis: a study on 8 patients. *Clin Exp Rheumatol* 2007;25:S23-7.
 25. Cheung CM, Murray PI, Savage CO. Successful treatment of Wegener's granulomatosis associated scleritis with rituximab. *Br J Ophthalmol* 2005;89:1542.
 26. Omdal R, Wildhagen K, Hansen T, Gunnarsson R, Kristoffersen G. Anti-CD20 therapy of treatment-resistant Wegener's granulomatosis: favourable but temporary response. *Scand J Rheumatol* 2005;34:229-32.
 27. Freidlin J, Wong IG, Acharya N. Rituximab treatment for peripheral ulcerative keratitis associated with Wegener's granulomatosis. *Br J Ophthalmol* 2007;91:1414.
 28. Minami R, Miyamura T, Watanabe H, Takahama S, Yamamoto M, Suematsu E. Successful treatment of a patient with refractory Wegener's granulomatosis by rituximab. *Nihon Rinsho Meneki Gakkai Kaishi* 2007;30:133-8.
 29. Chauhan S, Kamal A, Thompson RN, Estrach C, Moots RJ. Rituximab for treatment of scleritis associated with rheumatoid arthritis. *Br J Ophthalmol* 2009;93:984-5.
 30. Iaccheri B, Androudi S, Bocci EB, Gerli R, Cagini C, Fiore T. Rituximab treatment for persistent scleritis associated with rheumatoid arthritis. *Ocul Immunol Inflamm* 2010;18:223-5.
 31. Sadreddini S, Noshad H, Molaeefard M, Noshad R. Treatment of retinal vasculitis in Behçet's disease with rituximab. *Mod Rheumatol* 2009;18:306-8.
 32. Parikh JG, Tawansy KA, Rao NA. Immunohistochemical study of chronic nongranulomatous anterior uveitis in juvenile idiopathic arthritis. *Ophthalmology* 2008;115:1933-6.
 33. Stone JH, Merkel PA, Spiera R, Seo P, Langford CA, Hoffman GS, et al. Rituximab versus cyclophosphamide for ANCA-associated vasculitis. *N Engl J Med* 2010;363:221-32.
 34. Cohen SB. Targeting the B cell in rheumatoid arthritis. *Best Pract Res Clin Rheumatol* 2010;24:553-63.