

## Cutaneous Manifestations and Comorbidities in 60 Cases of Takayasu Arteritis

To the Editor:

Takayasu arteritis (TA) is a rare chronic vascular inflammatory disease that affects predominantly the aorta and its main branches, in addition to coronary arteries and pulmonary arteries. TA mainly affects young women, especially in the second and third decades of life; it has a high prevalence in Asian countries. The true incidence and prevalence of TA is probably underestimated and many patients remain undiagnosed or wait a long time before the correct diagnosis is made<sup>1</sup>.

TA is typically presented in 2 stages: a “prepulseless” stage and a “pulseless” stage. In the former there are malaise, fever, myalgias, arthralgias, and weight loss. In this stage it may be difficult to differentiate TA from other rheumatic and collagen diseases. In the second stage, complications related to large arterial stenosis and aneurysm formation predominate. The 2 stages may overlap or occur out of sequence. In both stages, cutaneous manifestations may be present, such as inflammatory nodules, erythema nodosum, and pyoderma gangrenosum-like ulcers, and more rarely, purpura<sup>2</sup>. Eventually, cutaneous manifestations may be present as an initial signal of TA<sup>3</sup>.

We systematically reviewed 60 patients with TA as proposed by the 1990 American College of Rheumatology (ACR) classification<sup>4</sup>, further delineating the prevalence and cutaneous manifestations observed in these cases. Three patients with specific TA cutaneous manifestations are described in detail.

Our study was a single-center transversal study. From March 2010 to April 2012, 87 consecutive patients with TA were followed at our service. All patients fulfilled at least 3 of the 6 ACR criteria for the classification of TA, as proposed by Arend, *et al*<sup>4</sup>. All these patients were invited for our evaluation, and 60 showed up.

A dermatologist in the dermatology department of our hospital examined these 60 patients. Medical data and clinical manifestations were recorded.

The median age of patients was 39 years (range 20 to 80 yrs), with 52 female (86%). Mean age at symptom onset was 28 years and the average delay of diagnosis was 21 months. In 68.3% of the cases, symptom onset was in the same year as TA diagnosis. The duration of disease progression, from the TA diagnosis to the date of our evaluation, ranged from 1 to 34 years and the median was 11 years.

Fifty-five patients (91.67%) were diagnosed with TA before the age of 40 years and 28 patients (46.67%) had claudication of extremities as the initial symptom. Thirty patients (50%) had decreased brachial artery pulse, 27 (61%) had a difference of 10 mm Hg or more in systolic blood pressure between arms, 23 (39%) had bruit over subclavian arteries or abdominal aorta, and 51 patients (85%) had arteriogram abnormalities.

Twenty-four patients (40%) had a diagnosis of hypertension, 15 (25%) dyslipidemia, and 6 patients (10%) had diabetes. There was a history of glucocorticoid use in 48 patients (80%) and immunosuppressive treatment in 36 (60%). At medical evaluation, 16 patients (26.6%) were in an active phase of the TA<sup>1,5</sup>, and all of them were using glucocorticoid regularly.

Nineteen patients (31.6%) presented with dermatologic lesions at the medical examination. The dermatologic criteria for the cutaneous lesions were those proposed by Freedberg, *et al*<sup>6</sup>. Raynaud phenomenon was present in 3 patients (5%).

A 30-year-old female patient, who had a TA diagnosis since age of 26 years, had clinical findings of tumid lesions on the face and thoracic region. A skin biopsy demonstrated alterations compatible with cutaneous lupus erythematosus. Antinuclear antibodies were negative and there was no alteration in laboratory results. At the time of examination, she was receiving prednisone 30 mg/day and methotrexate (MTX) 10 mg/day. Hydroxychloroquine (HCQ) therapy 400 mg/day was introduced, with a partial response of the cutaneous lesions in 2 months.

A 42-year-old female patient, with chronic alopecia on the front of the head, had a recent diagnosis of lichen planopilaris. She was 38 years old at

onset of TA symptoms and the arteritis diagnosis was confirmed 3 years later. She was receiving no treatment for TA because she presented a controlled state of the disease. HCQ therapy 400 mg/day was introduced for treatment of alopecia.

Two patients (3.3%) presented chronic plaque psoriasis disease. One was receiving topical treatment with calcipotriol and corticosteroid, and the other had no active psoriasis lesion. Both patients presented a controlled state of TA disease. Table 1 summarizes the findings for cutaneous lesions of the patients.

Three cases with specific cutaneous lesions of TA, specifically erythema nodosum-like lesions, are described in detail, as follows.

*Case 1.* A 41-year-old woman presented claudication of extremities, fever, arthralgias, and subcutaneous nodules of the legs for over 13 years. The diagnosis of TA was suggested by the difference of 30 mm Hg in systolic blood pressure between arms and diminished left brachial and radial pulses. Diagnosis of TA was confirmed by angiography, in accord with the angiographic classification of the International TA Conference in Tokyo, 1994<sup>1,7</sup>. She had type V angiographic classification because she presented stenosis of left subclavian and vertebral arteries and stenosis of thoracic and abdominal aorta. After diagnosis, systemic glucocorticoid therapy was introduced, with moderate response. Six months later, as the symptoms persisted, immunosuppressive treatment with azathioprine was introduced, with a poor response, and mycophenolate mofetil was initiated. Both drugs were associated with glucocorticoid therapy, but clinical response was poor. MTX was introduced when the patient was 30 years old and dramatically improved the clinical findings.

Ten years after diagnosis, she presented an active disease phase, with fever, persistent elevated erythrocyte sedimentation rate (ESR) and C-reactive protein (CRP) levels, and erythematous nodules on her legs. The initial histopathological features were nonspecific, showing superficial perivascular dermatitis. All the following laboratory investigations were negative or normal: chest radiography, tuberculin test, antistreptococcal antibodies, white and red blood cell counts, hepatic and renal tests, rheumatoid factor, antiphospholipid antibodies, antineutrophil cytoplasmic antibodies, antinuclear antibodies, and serological tests for hepatitis A, B and C viruses. Azathioprine treatment was associated with prednisone and MTX therapy, with regression of cutaneous lesions and clinical symptoms.

At the age of 40 years, she presented a new active phase, with fever, painful erythematous nodules on her left leg (Figures 1a and 1b), ESR increased to 18 mm/h, and CRP 13.1 mg/dl. Complementary laboratory investigations were within normal limits or negative. Serological tests for human immunodeficiency virus and hepatitis A, B, and C viruses remained negative. Skin biopsy of a nodule of the left leg showed vasculitis of dermohypodermic arterial vessels, with lymphocytic inflammation (Figures 1c, 1d). An increase in corticosteroid therapy (0.5 mg/kg/day) led to resolution of both the systemic complaints and cutaneous lesions.

Since symptom onset, all the active phases had recurred when the corticosteroid dose was tapered and control was regained with increased doses of prednisone associated with immunosuppressive agents (MTX 20 mg/week and azathioprine 150 mg/day).

Table 1. Summary data on cutaneous manifestations.

Cutaneous Manifestation	Total (n)
Erythema nodosum-like	3
Raynaud's syndrome	3
Psoriasis	2
Eczema	2
Lupus erythematosus	1
Lichen planopilaris	1
Pityriasis versicolor	2
Viral warts	2
Seborrheic dermatitis	3

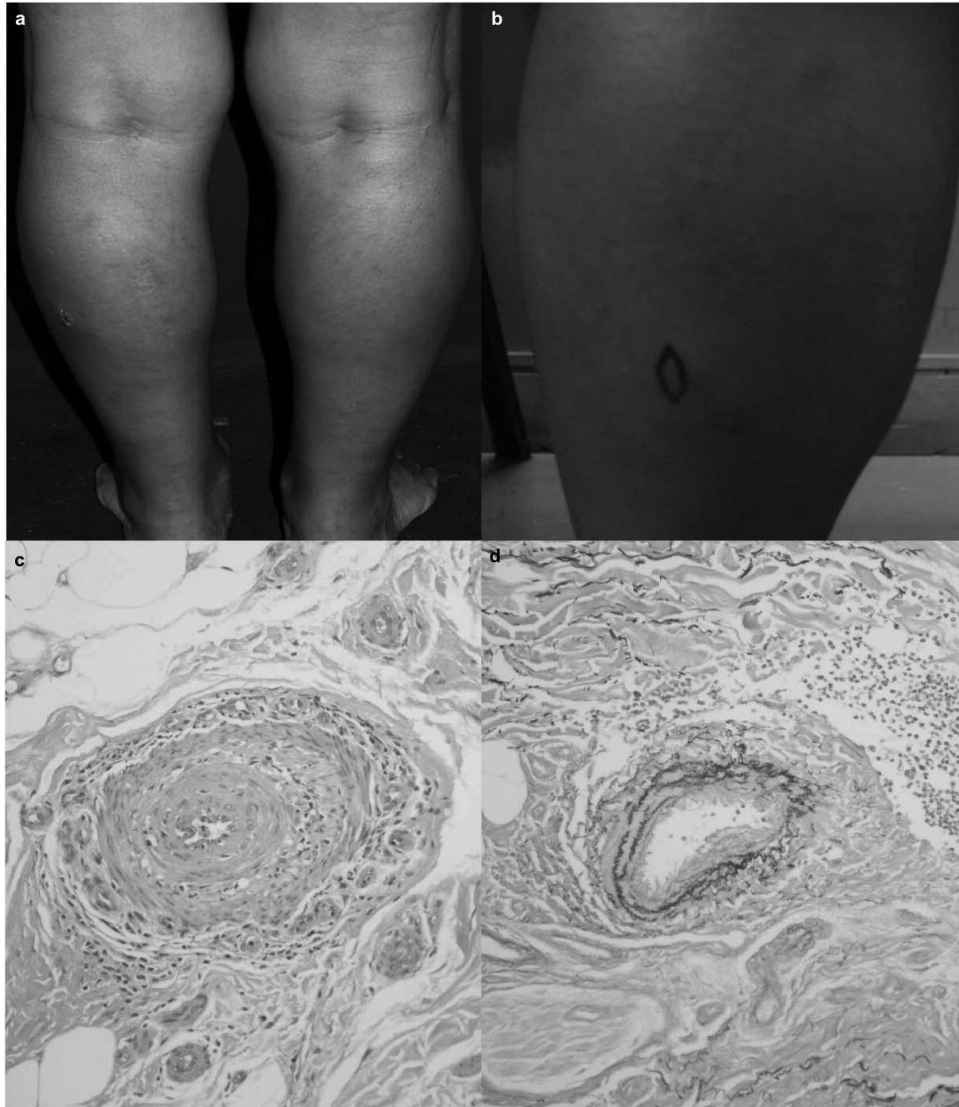


Figure 1. a. Cutaneous nodule of the left leg (Case 1). b. Detail of skin lesion in Case 1. c. Vasculitis of dermo-hypodermic arterial vessels. d. Arterial vessel involvement; fucsina resorcina coloration.

**Case 2.** A 34-year-old female patient had a 1-year history of subcutaneous nodules on her legs (Figures 2a, 2b), with fever, right arm pain, and dyspnea on moderate effort.

She was evaluated at our dermatologic department and the clinical hypothesis was erythema nodosum. The biopsy showed granulomatous vasculitis and septal panniculitis, with lymphocytic inflammation (Figures 2c, 2d, 2e, 2f). Laboratory investigations were negative or normal except the ESR (48 mm/h) and CRP levels (36 mg/dl), which were high. Among the clinical findings were inaudible arterial pressure and absence of pulses at the right arm. Angiographic examination demonstrated concentric thickening of the ascending aorta and stenosis of innominate and left common carotid arteries (type IIA angiographic classification)<sup>7</sup>. A diagnosis of TA was established and treatment with corticosteroids (prednisone 20 mg/day) and MTX 25 mg/week led to partial disease control.

**Case 3.** A 53-year-old female patient had severe arterial hypertension since 1994. At age 50 years she developed painful cutaneous nodules of the legs and arthralgias. A clinical finding was bruit over abdominal aorta, and arteriogram abnormality was classified as type IV<sup>7</sup>, with stenosis of the

descending thoracic aorta, stenosis of the superior mesenteric artery, and occlusion of the left renal artery. She showed high levels of CRP (55 mg/dl) and ESR (58 mm/h). Other laboratory investigations were negative or normal. Histopathology results of the nodular lesion were a necrotizing and granulomatous vasculitis in the upper subcutaneous tissue arteries (Figure 3), with a negative acid-alcohol-resistant bacillus.

The patient underwent corticotherapy (prednisone 0.5 mg/kg/day) with good response. A new episode of subcutaneous lesions of the legs occurred when the corticosteroid dose was tapered, almost 2 years after the beginning of treatment. Immunosuppressive therapy with MTX 25 mg/week was added, which improved the dermatologic features. One year later, another episode of cutaneous nodules, with the same characteristics, occurred with a reduction of prednisone dose. Mycophenolate mofetil 1 g/day was introduced, with a satisfactory control of clinical signs, ESR, and CRP.

The proportions of diabetes mellitus, pressure hypertension, and dyslipidemia in our patients with TA were similar to those of the general Brazilian adult population<sup>8,9,10</sup>.

The most common diagnosis criterion, as proposed by the 1990 ACR

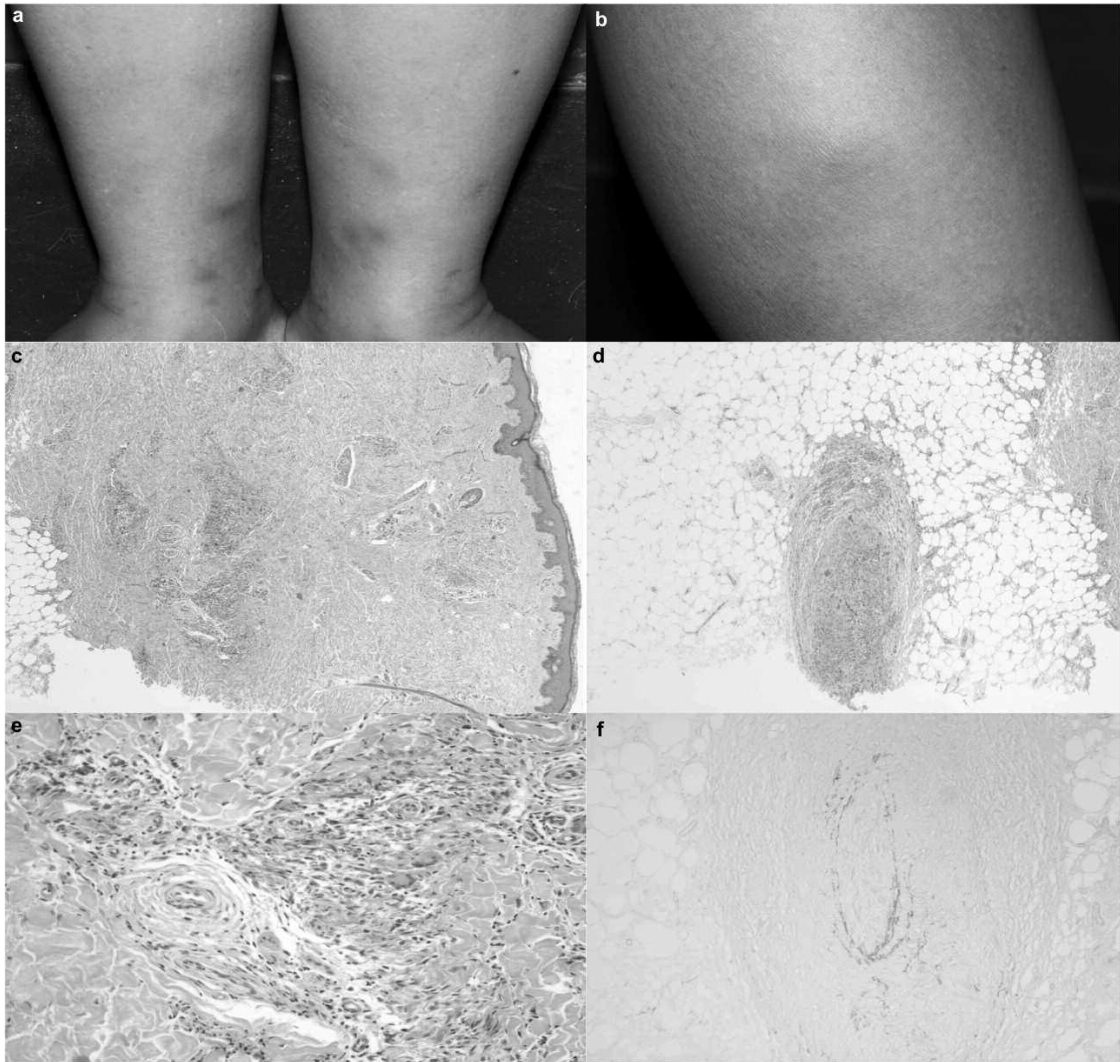


Figure 2. a. Cutaneous nodule of the legs (Case 2). b. Detail of skin lesions (Case 2). c, d, e. Granulomatous vasculitis and septal panniculitis, with lymphocytic inflammation (Case 2). f. Arterial vessel involvement.

classification<sup>4</sup>, was the age of disease onset, followed by arteriogram abnormalities. In the 3 reported cases, all patients were < 40 years old when the initial symptoms presented and had arteriogram abnormalities. Two cases presented 4 diagnosis criteria and 1 case just 3 criteria.

Cutaneous manifestations in patients with TA vary greatly from country to country. The frequency of skin lesions in TA is estimated to be between 2.8% and 28% of cases<sup>11</sup>. In Europe and North America, acute inflammatory nodules or erythema nodosum-like lesions are the most commonly observed skin lesions<sup>2,3,11</sup>. There are no such data for South America. Specific skin manifestations in TA include Raynaud phenomenon, pyoderma gangrenosum, erythema nodosum-like lesions, necrotic or ulcerated nodules, livedo reticularis, and purpura<sup>2,3,12</sup>. In our literature review, we found 21 reported TA patients with erythematous nodules, and 12 of them presented histological findings of vasculitis. Adding our 3 cases to those findings, a total of 24 patients are now reported with erythematous nodules associated with TA disease<sup>2</sup>.

In Cases 1 and 2, the cutaneous vasculitis lesions represented the first manifestation. In Case 2 specifically, the dermatologic symptoms triggered the TA investigation. Because the constitutional symptoms of TA frequently precede obvious arterial manifestations, the diagnosis of TA is

often delayed for several years. The presence of skin manifestations, such as vasculitic and panniculitic lesions, in the context of systemic symptoms and arterial bruits should be considered TA. Acute and subacute cutaneous nodules were more frequently reported early in the course of TA. In contrast, pyoderma gangrenosum and papulonecrotic lesions occurred more frequently at the occlusive stage of the disease process<sup>4</sup>. There were no patients in our study with pyoderma gangrenosum and papulonecrotic lesions. Regardless of the disease stage, the occurrence of the TA cutaneous skin lesions was strongly related to persistent activity, and as we see in our 3 cases, related to the tapering of glucocorticoid treatment. Indeed, optimization of the immunosuppressive treatment was necessary in our cases because the cutaneous manifestation was related to an active phase. According to the US National Institutes of Health criteria, an active phase occurs when 2 or more of the following elements appear or become worse: systemic features, ESR or CRP levels, features of vascular ischemia, or inflammation and angiographic changes<sup>1,5</sup>.

Granulomatous involvement of vessel walls and/or perivascular granulomas may also be seen in a wide range of conditions including lymphoma, angioimmunoblastic, lymphadenopathy, sarcoidosis, systemic vasculitis, Crohn disease, drug reactions, the site of previous herpes zoster or herpes

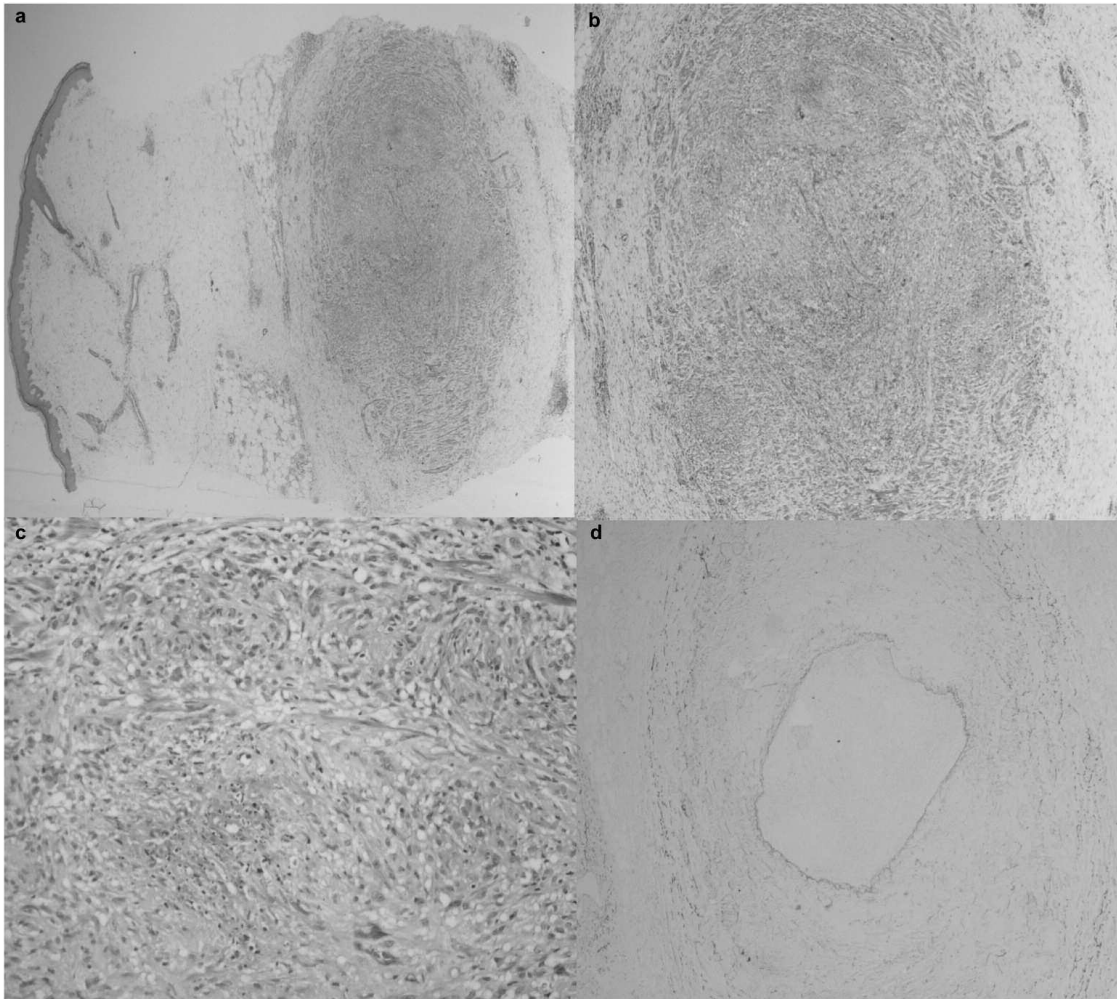


Figure 3. a, b, c. Granulomatous vasculitis and septal panniculitis (Case 3). d. Arterial vessel involvement.

simplex, rheumatoid arthritis, and infectious granulomatous diseases such as tuberculosis and tertiary syphilis. With the clinical and laboratory findings and the arterial vessel involvement, we considered the cutaneous lesions found in the 3 cases to be presentations of the TA.

Skaria, *et al*<sup>11</sup> observed that TA does not uniquely involve large arterial vessels. Two cases were reported with cutaneous manifestations and necrotizing vasculitis on histological findings. It was argued that the vascular inflammatory processes observed in the skin and in the large vessel walls are closely related because involvement of the vasa vasorum system in TA may have an important role in the development of the clinicopathological features of this condition.

The 3 reported cases showed arterial vascular involvement in the skin, further supporting the concept that the small-vessel inflammatory process may be an early etiological event. But more studies are needed to prove that the primary involvement of the vasa vasorum system is the early pathogenic event leading to development of the inflammatory process affecting the wall of large arterial vessels in TA.

No correlation could be found between the localization of the skin lesions and the alteration of large vessels revealed by angiography. Hidano and Watanabe<sup>13</sup> and Frances, *et al*<sup>3</sup> have reported the lack of correlation between the sites of cutaneous manifestations and arteritis.

Specific skin lesions in TA can appear in all stages of the disease. These

lesions are not associated with a more severe disease course, location, or severity of large-artery lesions. However, patients with cutaneous lesions can have a major presence of systemic symptoms and thus more difficult control of TA at the active phase<sup>3</sup>. Finally, all apparently idiopathic recurrent acute skin nodules may evoke a diagnosis of TA and should lead to clinical examination of systolic blood pressure, brachial artery pulse, and bruit over main arteries, beyond skin biopsies and arterial Doppler echography studies of the neck, heart, and limbs.

Our study emphasizes relevant cutaneous manifestations of TA, supporting early diagnosis of this life-threatening disorder.

LILIAN KELLY ROCHA, MD, Hospital das Clínicas da Faculdades de Medicina da Universidade de São Paulo (USP), Dermatology; RICARDO ROMITTI, MD, PhD, Hospital das Clínicas de USP, Dermatology; SAMUEL SHINJO, MD, PhD; MAURICIO LEVY NETO, MD, PhD, Hospital das Clínicas de USP, Rheumatology; JOZELIO CARVALHO, MD, PhD, Universidade de São Paulo, Medicina; Hospital das Clínicas de USP, Rheumatology; PAULO CRIADO, MD, PhD, Hospital das Clínicas de USP, Dermatology. Address correspondence to Dr. L. Rocha, Hospital das Clínicas da Faculdade de Medicina da USP – Dermatology, Av. Dr. Enéas de Carvalho, 500 São Paulo, São Paulo 05409-000, Brazil. E-mail: lilianrocha@me.com

## REFERENCES

1. Ohigashi H, Haraguchi G, Konishi M, Tezuka D, Kamiishi T, Ishihara T, et al. Improved prognosis of Takayasu arteritis over the past decade. *Circ J* 2012;76:1004-11.
2. Pascual-López M, Hernández-Núñez A, Aragiés-Montañés M, Daudén E, Fraga J, García-Díez A. Takayasu's disease with cutaneous involvement. *Dermatology* 2004;208:10-5.
3. Francès C, Boissic S, Blétry O, Dallot A, Thomas D, Kieffer E, et al. Cutaneous manifestations of Takayasu arteritis: A retrospective study of 80 cases. *Dermatologica* 1990;181:266-72.
4. Arend WP, Michel BA, Bloch DA, Hunder GG, Calabrese LH, Edworthy SM, et al. The American College of Rheumatology 1990 criteria for the classification of Takayasu arteritis. *Arthritis Rheum* 1990;33:1129-34.
5. Kerr GS, Hallahan CW, Giordano J, Leavitt RY, Fauci AS, Rottem M, et al. Takayasu arteritis. *Ann Intern Med* 1994;120:919-29.
6. Freedberg IM, Eisen AZ, Wolff K. *Fitzpatrick's dermatology in general medicine*. 6th ed. New York: McGraw-Hill Professional; 2003.
7. Moriwaki R, Noda M, Yajima M, Sharma BK, Numano F. Clinical manifestations of Takayasu arteritis in India and Japan — New classification of angiographic findings. *Angiology* 1997;48:369-79.
8. Dalpino FB, Sodr  FL, de Faria EC. The use of a hospital laboratory cohort to estimate the prevalence of dyslipidemia in an adult Brazilian population. *Clin Chim Acta* 2006;367:189-91.
9. American Diabetes Association. 2011 National Diabetes Fact Sheet. [Internet. Accessed Feb 12, 2013.] Available from: <http://www.diabetes.org/diabetes-basics/diabetes-statistics>
10. Guimar es AC. Hypertension in Brazil. *J Hum Hypertens* 2002;16 Suppl:S7-10.
11. Skaria AM, Ruffieux P, Piletta P, Chavaz P, Saurat JH, Borradori L. Takayasu arteritis and cutaneous necrotizing vasculitis. *Dermatology* 2000;200:139-43.
12. Perniciaro CV, Winkelmann RK, Hunder GG. Cutaneous manifestations of Takayasu's arteritis: A clinicopathologic correlation. *J Am Acad Dermatol* 1987;17:998-1005.
13. Hidano A, Watanabe K. Pyoderma gangraenosum et cardiovasculopathies, en particulier art rite de Takayasu [French]. Pyoderma gangraenosum and cardio-vasculopathies, particularly Takayasu arteritis. Review of the Japanese literature. *Ann Dermatol V nierol* 1981;108:13-21.

*J Rheumatol* 2013;40:5; doi:10.3899/jrheum.121276

**Cutaneous Manifestations and Comorbidities in 60 Cases of Takayasu Arteritis**

Rocha KL, Romitti R, Shinjo S, Neto ML, Carvalho J, Criado P. Cutaneous manifestations and comorbidities in 60 cases of Takayasu arteritis [letter]. *J Rheumatol* 2013;40:734-8. The author's full name should be given: Paulo Ricardo Criado. We regret the error.  
doi:10.3899/jrheum.121276.C1