

# Fascin-expressing Dendritic Cells Dominate in Polymyositis and Dermatomyositis

HANNA GENDEK-KUBIAK and EWA G. GENDEK

**ABSTRACT. Objective.** Dendritic cells (DC) have been reported among inflammatory infiltrating cells in muscle tissue in idiopathic inflammatory myopathies (IIM), but to our knowledge no studies concerning the expression of langerin (CD207) or fascin (markers of immature and mature DC, respectively) in IIM have been published.

**Methods.** Immunohistochemical analyses of langerin and fascin expression were performed on specimens from normal muscles, as well as those affected by polymyositis (PM) and dermatomyositis (DM). The results were analyzed by Mann-Whitney U test.

**Results.** In PM and DM, fascin-positive cells were numerous in the majority of the studied samples in perimysial, endomysial, and perivascular cellular infiltrates. Sporadic langerin-positive cells were detected.

**Conclusion.** Fascin-positive DC predominance in inflammatory infiltrates in myositic muscles confirms the prevalence of mature forms and indicates that there are conditions stimulating DC maturation in both PM and DM. The induction of immunological tolerance by inhibiting DC maturation may be a promising direction for studies of myositis treatment. (First Release Nov 1 2012; J Rheumatol 2013;40:186–91; doi:10.3899/jrheum.120590)

*Key Indexing Terms:*

MYOSITIS  
FASCIN

IMMUNOHISTOCHEMISTRY

DENDRITIC CELL  
LANGERIN

Polymyositis (PM), dermatomyositis (DM), and inclusion body myositis (IBM) are the main conditions classified as idiopathic inflammatory myopathies (IIM). Early studies of the histological and immunohistochemical aspects of IIM focused mainly on diagnosing and finding differences between the disease entities, to allow predictions of clinical outcome<sup>1,2,3</sup>. Until recently, mononuclear cell infiltrates observed in the course of IIM had been reported as composed mainly of lymphocytes (especially of T cells, CD4+, and CD8+) and macrophages<sup>1,4</sup>. Emphasis was placed on cytotoxic T cell-mediated myofiber injury in IBM and PM, as opposed to the important role played by Th cells and B cells in DM<sup>1,3</sup>.

The infiltration of T cells into affected muscles indicates an ongoing immune response, requiring the presence of antigen-presenting cells. Dendritic cells (DC) are considered crucial for the induction of immunization; thus several analyses have been performed to find out whether DC parti-

cipate in the immune response in the course of IIM<sup>5</sup>. DC have been reported in muscle tissue, among the inflammatory infiltrating cells in these diseases<sup>6,7</sup>. High interferon- $\alpha$  and  $\beta$  production by DC in myositis has been implicated in causing characteristic changes in muscles in IIM<sup>5,6,7,8</sup>. In addition to the DC markers, molecules assumed to be lymphocyte or macrophage markers can be detected on the DC cell surface: CD4 of Th cells, CD8 of T suppressor/cytotoxic cells, and CD68 — earlier considered only a macrophage marker<sup>5,6,7,8</sup>. DC closely related to B cells might coexpress some antigens of this lineage<sup>9</sup>.

Because DC demonstrate a substantial range of phenotypes, depending on their differentiation stage and environmental factors, a single monoclonal antibody cannot identify all possible DC<sup>10,11,12,13,14,15</sup>. During DC differentiation, sequential and sometimes overlapping expression of their numerous markers can be observed<sup>10,11,12,13,14</sup>. For example, not only can at least 5 populations of DC related to different stages of differentiation be identified in the mouse, but multistage maturation of DC can also be observed in humans<sup>12,16</sup>.

The CD1a and BDCA2 antigens are markers of immature DC, while DC-LAMP and CD83 are markers of mature DC, but CD83 is considered a marker of DC that are too immature to express DC-LAMP<sup>6,17</sup>. The high expression of fascin in human DC generated from monocytes, as well as in those from CD34+ blood precursors, correlates with the presence of the CD83 maturation marker. Moreover, the blockage of fascin production was found to retard the struc-

*From the Department of Cytophysiology, Histology, and Embryology, and the Department of Chemistry and Clinical Biochemistry, Medical University of Lodz, Lodz, Poland.*

*Supported by the Medical University of Lodz (grant numbers 502-18-558 and 502-17-555).*

*H. Gendek-Kubiak, MD, PhD, Department of Cytophysiology, Histology and Embryology; E.G. Gendek, PhD, Department of Chemistry and Clinical Biochemistry, Medical University of Lodz.*

*Address correspondence to Dr. H. Gendek-Kubiak, Department of Cytophysiology, Histology and Embryology, Medical University of Lodz, G. Narutowicza 60, 90-136 Lodz, Poland. E-mail: h\_kubiak@hotmail.com Accepted for publication September 12, 2012.*

Personal non-commercial use only. The Journal of Rheumatology Copyright © 2013. All rights reserved.

tural maturation of the cells<sup>18</sup>. Hence, most fascin-positive DC should be CD83-positive.

According to Tsoumakidou, *et al*<sup>19</sup>, most of the CD1a+ Langerhans cells isolated from lungs of some patients can coexpress langerin, CD83, plasmacytoid, and myeloid DC markers. Other studies have revealed that bone marrow plasmacytoid DC can differentiate into myeloid DC upon virus infection<sup>20</sup>. Hence, the results of studies on DC subsets may be influenced by the stage of the disease, accompanying diseases, and their treatment, as well as environmental and genetic factors. Interestingly, Abdullah, *et al*<sup>21</sup> indicate that human T cell lymphotropic virus-1 infection is responsible for modifying the clinical course and the histopathological features of PM in humans.

No reports concerning langerin or fascin (markers of immature/mature DC, respectively) expression in IIM have been published to date, to our knowledge. Langerin (CD207) is expressed by the Langerhans cells of the epidermis and some other types of DC<sup>22,23</sup>. Chemically, langerin is a type II  $\text{Ca}^{2+}$ -dependent lectin, displaying mannose-binding specificity<sup>24,25</sup>. The langerin staining pattern is nearly always strictly associated with CD1a expression in the same cells<sup>10,23</sup>; hence, the presence of the anti-CD207 antibody reveals immature DC<sup>23</sup>. Fascin, an actin-bundling protein, is characteristic of mature DC and endothelial cells<sup>26</sup>.

In our study, immunohistochemical stainings of langerin and fascin were performed in specimens from normal muscles, as well as from muscles affected by PM and DM. The results were preliminarily reported during 2 scientific meetings<sup>27,28</sup>.

## MATERIALS AND METHODS

Muscle samples were taken from 5 patients with PM and 5 patients with DM before treatment, with the patients' written agreement. PM and DM, defined according to the Bohan and Peter criteria<sup>29</sup>, were diagnosed before any treatment. Muscle specimens taken from 2 patients in whom muscle disease had been excluded (muscle specimens were histologically "normal"), served as controls. All muscle specimens were used when the diagnosis was completed. Specimen dimensions ranged from about 3 mm × 5 mm to 12 mm × 18 mm.

Additionally, as a positive control of langerin and fascin expression, specimens of human skin from 2 volunteers were used.

Material was fixed with 10% formalin solution and embedded in paraffin. Sections measuring 7  $\mu\text{m}$  were used throughout our study. From each biopsy specimen, 1 slide was stained with H&E for histological assessment, and 2 slides were immunohistochemically stained for langerin and 2 for fascin.

**Immunohistochemical procedures.** Antigen unmasking was performed using microwave treatment of the specimens submerged in citrate buffer, pH 6.0. Immunohistochemical reactions were performed using anti-CD207 (antilangerin) mouse monoclonal primary antibody, clone 12D6 (Novocastra Laboratories) at a 1:50 dilution or antifascin mouse monoclonal primary antibody, clone IM20 (Novocastra) at 1:40 dilution. Primary antibodies were incubated for 1 h with tissue sections, after blocking endogenous peroxidase with 2% hydrogen peroxide.

Next, a biotinylated goat antimouse antibody and streptavidin-peroxidase included in the LSAB2 kit (DakoCytomation) were

applied. All the necessary washings were performed with phosphate buffered saline, pH 7.6. The negative control was obtained by omitting the primary antibody. Staining with mouse antibodies against langerin or fascin, used as primary antibodies, served as controls for each other, allowing exclusion of unspecific mouse antibody binding.

Either 3,3'-diaminobenzidine substrate solution (Sigma) or Vector SG (Vector) was used as a chromogen. Next, some slides were slightly counterstained with hematoxylin, or nuclear fast red for nuclei. Some slides from the skin were counterstained with Alcian blue for mast cell visualization.

**Cellular infiltrate assessment.** Every slide was browsed for "hot spots," muscle areas containing the highest density of infiltrating cells. At least 3 hot spots per slide were evaluated. Additionally, in the slides stained immunohistochemically for langerin or fascin, all cells expressing the antigen were found and counted. The percentage of fascin-positive cells in hot spots was then calculated.

Thus, the intensity of the infiltrates was evaluated, as was their localization, in 5 slides for every biopsy. The maximal infiltrate intensity was classified as follows: 0, no infiltrate (up to 5 cells); +, 6 to 10 cells; ++, 11 to 25 cells; +++, 26 to 50 cells; and +++++, over 50 cells. The results were analyzed by the Mann-Whitney U test<sup>30</sup>.

## RESULTS

The intensities and localization of cellular infiltrates in the muscle samples studied have been listed in Table 1.

In positive controls, langerin-positive cells (Langerhans cells) were seen in the spinous layer of the normal human epidermis (Figure 1), and fascin-positive DC were seen in the dermis (Figure 2). However, no langerin-positive cells were found in control muscle specimens. Single fascin-positive cells were present, albeit sparsely, in the control muscle (below 1 cell in the field of vision at magnification 100 $\times$ ), but numerous endothelial cells also were fascin-positive.

In the negative controls of immunohistochemical reactions, i.e., without any primary antibody, no staining occurred. Immunoreaction for langerin and for fascin can be treated as reciprocal isotypic controls, because both of the primary antibodies used were of the same type (mouse monoclonal) and were used in similar concentrations and showed no unspecific staining.

The immunohistochemical reaction for langerin was positive in only 1 infiltrating cell in 1 slide from PM-affected muscle, and in just 2 cells in the slides from DM-affected muscles (Figure 3, Table 1). In infiltrates, fascin-positive cells were found in all DM specimens (5/5) and in 4 of the 5 PM specimens (Table 1). These fascin-positive cells were localized in the perimysium, as well as in the endomysium (Figure 4) and in the perivascular region (Figure 5, Table 1). Other cells present in cellular infiltrates were mononuclear cells, mainly lymphocytes. In hot spots of specimens from 9 patients, fascin-positive cells represented about 10% to 70% of all the infiltrating cells; endothelial cells were also fascin-positive (Figure 5). No differences were noted between PM and DM in the presence and localization of fascin-positive DC.

**Statistical analysis.** Control muscles, in contrast to PM/DM

Table 1. Characteristics of patients and muscle specimens.

Case Number/ Diagnosis	Age/Sex	Maximal Infiltrate Intensity	Main Location of Infiltrates	Percentage Range of Fascin-expressing Infiltrating Cells in Hot Spots (range midpoint)	Number of Langerin- expressing Cells/ 2 Slides
1/control	65 F	0	—	—	0
2/control	Unknown, M	0	—	—	0
3/DM	65 M	++	Endomysium	20–40 (30)	0
4/DM	59 F	+++	Perivascular	20–60 (40)	0
5/DM	52 F	++	Perivascular, endomysium	10–45 (27.5)	0
6/DM	45 M	++++	Perimysium, endomysium, perivascular	40–70 (55)	2
7/DM	48 F	+	Perivascular, endomysium	10–15 (12.5)	0
8/PM	67 F	+++	Perimysium, endomysium	20–55 (37.5)	1
9/PM	38 M	+++	Perimysium, endomysium	30–60 (45)	0
10/PM	Unknown, M	++	Perivascular	10–20 (15)	0
11/PM	66 M	++	Endomysium, perimysium	0 (0)	0
12/PM	53 F	+++	Perivascular, endomysium	30–60 (45)	0

Infiltrate intensity: 0, no infiltrates; +, 6 to 10 cells; ++, 11 to 25 cells; +++, 26 to 50 cells; +++, over 50 cells. DM: dermatomyositis; PM: polymyositis.

muscles, did not contain inflammatory infiltrates, and the difference was statistically significant ( $p < 0.05$ ). These observed differences between PM and DM were statistically insignificant: infiltration intensities, percentages of fascin-expressing DC in infiltrates, numbers of langerin-expressing DC, age of patients, and sex. In the muscle specimens from all patients with PM or DM, fascin-expressing DC outnumbered langerin-expressing DC ( $p < 0.001$ ). Patient age ( $< 55$  vs  $> 55$  yrs) and sex did not affect relative fascin-expressing DC values (range midpoints;  $p > 0.1$ ). Higher percentages of fascin-expressing DC among infiltrating cells (range midpoints  $> 30\%$ ) were present in the specimens of larger hot spots ( $p < 0.01$ ).

## DISCUSSION

The prevalence of fascin-expressing (mature) DC over immature (langerin-expressing) DC that we observed indicates that there are conditions stimulating DC maturation in both PM and DM. The question is where the DC maturation takes place: in the muscle or extramuscularly. Page, *et al*<sup>6</sup> suggested that accumulation of mature DC results from a local maturation process. The practical absence of langerin-positive DC (immature DC), both in control and PM/DM muscles, that we observed seems to suggest but does not prove extramuscular DC maturation. Another possible explanation suggested by Page, *et al*<sup>6</sup> is that immature DC appear in early stages of PM or DM and mature DC characterize more advanced stages of myositis.

The literature on the presence of DC in IIM is limited<sup>5,6,7,8,17,31,32,33</sup>. Some of the results were obtained using cryostat sections, but the pioneering study on DC maturation stage by Page, *et al*<sup>6</sup> used paraffin sections, as we did. These authors detected CD1a-positive cells (immature) in infiltrates in muscle specimens from most patients with DM (4/6) and in material from 3/6 patients

with PM. The exact ratio of mature to immature DC expressing DC-LAMP (M/I) has been calculated as M/I = 1.7 in DM and M/I = 2.3 in PM, the difference being statistically insignificant. Neither in our studies nor in those described by other authors<sup>6,31</sup> has a predominance of immature DC been found in any muscle specimens affected by PM or DM. Hence, the ratio of immature to mature DC would always fall in the range of 0 to 1. For example, the results of Page, *et al*<sup>6</sup> would be I/M = 0.59 for DM and I/M = 0.43 for PM. But after taking into account the specimens in which immature DC were not detected, the results would be I/M = 0.393 and I/M = 0.215, respectively. In our study, I/M in most cases equaled 0. Our results show that neither detecting the presence of DC nor their maturation stage in IIM muscle specimens seemed to be helpful in the differential diagnosis of PM versus DM, and in this regard confirm observations of Page, *et al*<sup>6</sup>.

In juvenile DM, DC-LAMP, a marker of mature DC, and BDCA2, a marker produced by immature plasmacytoid DC, were studied in muscles affected for  $> 2$  months<sup>17</sup>. The cells expressing DC-LAMP predominated, but BDCA2 was found in numerous DC-LAMP-positive cells<sup>17</sup>. According to Tournadre, *et al*<sup>31</sup>, in muscle specimens from 11 PM and 2 DM patients with refractory disease (treated with steroids and/or intravenous immunoglobulins), DC-LAMP expression was found in all but 1 PM sample. Very few DC expressing CD1a were detected: in 1 of 2 DM specimens and in 6 of 11 PM specimens. It is noteworthy that in Duchenne muscular dystrophy and in Becker muscular dystrophy, prednisone treatment resulted in reduced DC among the infiltrating cells in the dystrophic muscles<sup>34,35</sup>.

A comparison of langerin/fascin-expressing DC ratios in other muscle disease entities, which are histologically cross-differentiated with PM and DM (muscle dystrophies and some rare inflammations), has never been performed, to



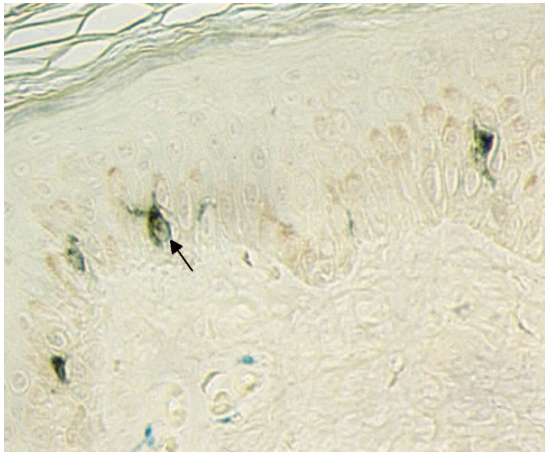


Figure 1. Positive control for langerin immunostaining in human skin. Langerhans (dendritic) cells (DC) are visible in spinous layer of epidermis (arrow). Diaminobenzidine was used as a chromogen. In dermis are mast cells stained with Alcian blue. Original magnification 400 $\times$ .

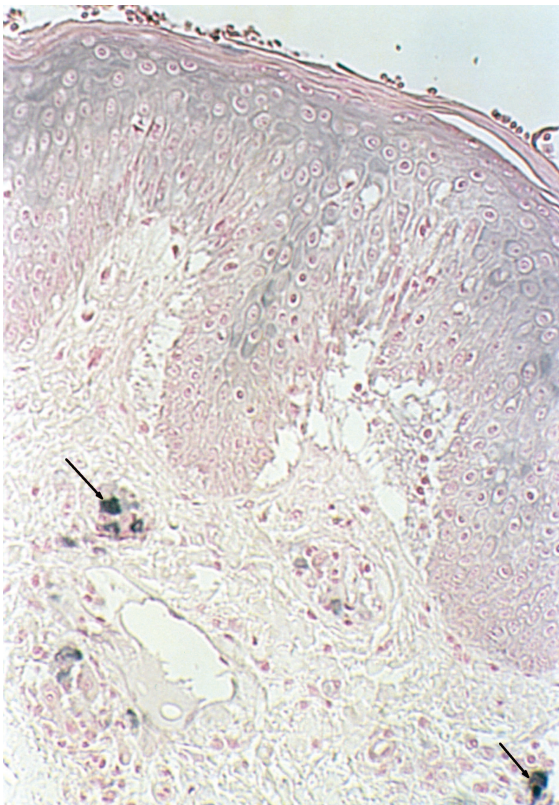


Figure 2. Positive control for fascin in human skin. Blue-black dendritic cells are visible in dermis only (arrows). Vector SG was used as a chromogen. Nuclear fast red counterstain. Original magnification 160 $\times$ .

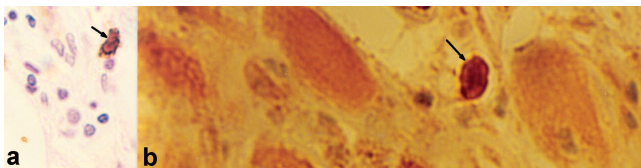


Figure 3. Immunohistochemical staining for langerin in (a) DM and (b) PM muscles. Arrows show langerin-positive cells. Diaminobenzidine was used as a chromogen. Hematoxylin counterstain. Original magnification 400 $\times$ .

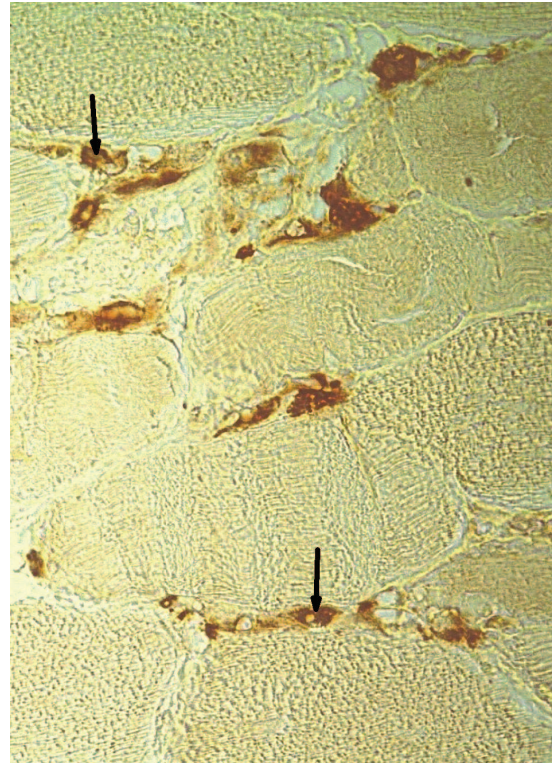


Figure 4. Immunohistochemical staining for fascin in PM muscle. Fascin-positive cells in endomysium are present (representative DC, arrows). Diaminobenzidine was used as a chromogen. Hematoxylin counterstain. Original magnification 400 $\times$ .

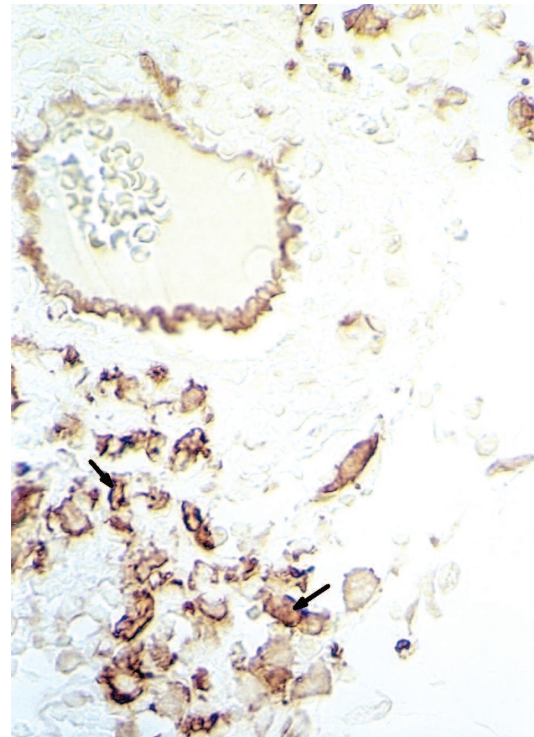


Figure 5. Immunohistochemical staining for fascin in DM muscle. In perivascular infiltration, numerous fascin-positive cells are visible (representative DC, arrows). Endothelial cells also express fascin. Diaminobenzidine was used as a chromogen. Original magnification 400 $\times$ .

our knowledge. Until now, few papers have reported on the expression of DC markers in different muscle diseases. One example is the 2000 report of DC-expressing factor XIIIa and HLA-DR in Duchenne muscular dystrophy and limb-girdle muscular dystrophy<sup>36</sup>. The identification of DC in Duchenne muscular dystrophy and in Becker muscular dystrophy, by means of electron microscopy with euchromatic nuclei and multiple long dendrites, was described in 2010<sup>34</sup>.

Immunohistochemical staining for fascin in paraffin slides used in our study seems to be a promising tool for visualizing DC in different tissue samples collected through several years. This allows mature DC detection in material from many patients at the same time — of special value in studies on rare diseases.

The role played by DC in IIM is far from clear. According to Novak, *et al*<sup>12</sup>, at least 5 phenotypically different populations of DC, related to various stages of their differentiation, were identified by Shortman and Liu in a mouse model<sup>16</sup>. Multistage maturation of DC can also be observed in humans, not only because of the interplay between immunological factors but because of factors related to the physicochemical background, such as the presence of reactive oxygen species. It has been found that DC maturation can be inhibited by different factors such as oxidative stress, leading to tolerogenicity<sup>12,13</sup>.

Based on our results, the maturation of DC in PM and DM does not appear to be hampered. The induction of immunological tolerance by inhibiting DC maturation may be a promising direction in studies on myositis treatment.

## ACKNOWLEDGMENT

We are deeply indebted to Prof. Anna Sysa-Jędrzejowska, Head of the Dermatology and Venerology Clinic, Medical University of Lodz, who provided us with DM muscle specimens that were histopathologically diagnosed by Prof. Wojciech Biernat. The PM specimens were provided by Prof. Wielisław Papierz, Head of the Department of Pathomorphology, Medical University of Lodz. PM diagnosis was made by Dr. Aleksandra Omulecka and Prof. Wielisław Papierz. Both DM and PM muscle specimens had been collected in the 1990s.

## REFERENCES

- De Bleecker JL, Engel AG. Immunocytochemical study of CD45 T-cell isoforms in inflammatory myopathies. *Am J Pathol* 1995;14:1178-87.
- Arahata K, Engel AG. Monoclonal-antibody analysis of mononuclear-cells in myopathies. 1. Quantitation of subsets according to diagnosis and sites of accumulation and demonstration and counts of muscle-fibers invaded by T-cells. *Ann Neurol* 1984;16:193-208.
- Emslie-Smith AM, Engel AG. Microvascular changes in early and advanced dermatomyositis — A quantitative study. *Ann Neurol* 1990;27:343-56.
- Gendek-Kubiak H, Gendek EG. Immunolocalization of protectin (CD59) and macrophages in polymyositis and dermatomyositis. *J Neuroimmunol* 2004;149:187-94.
- Greenberg SA, Pinkus JL, Pinkus GS, Bursleson T, Sanoudou D, Tawil R, et al. Interferon-alpha/beta-mediated innate immune mechanisms in dermatomyositis. *Ann Neurol* 2005;57:664-78.
- Page G, Chevrel G, Miossec P. Anatomic localization of immature and mature dendritic cell subsets in dermatomyositis and polymyositis — Interaction with chemokines and Th1 cytokine-producing cells. *Arthritis Rheum* 2004;50:199-208.
- Chevrel G, Page G, Miossec P. Novel aspects on the contribution of T cells and dendritic cells in the pathogenesis of myositis. *Autoimmunity* 2006;39:171-6.
- Greenberg SA. Proposed immunologic models of the inflammatory myopathies and potential therapeutic implications. *Neurology* 2007;69:2008-19.
- Shortman K, Naik SH. Steady-state and inflammatory dendritic-cell development. *Nat Rev Immunol* 2007;7:19-30.
- Chikwava K, Jaffe R. Langerin (CD207) staining in normal pediatric tissues, reactive lymph nodes, and childhood histiocytic disorders. *Pediatr Dev Pathol* 2004;7:607-14.
- Lutz MB, Schuler G. Immature, semi-mature and fully mature dendritic cells: Which signals induce tolerance or immunity? *Trends Immunol* 2002;23:445-9.
- Novak N, Koch S, Allam JP, Bieber T. Dendritic cells: Bridging innate and adaptive immunity in atopic dermatitis. *J Allergy Clin Immunol* 2010;125:50-9.
- Kazama H, Ricci JE, Herndon JM, Hoppe G, Green DR, Ferguson TA. Induction of immunological tolerance by apoptotic cells requires caspase-dependent oxidation of high-mobility group box-1 protein. *Immunity* 2008;29:21-32.
- Peter ME. ROS eliminate danger. *Immunity* 2008;29:1-2.
- Berger TG, Schulze-Koops H, Schafer M, Muller E, Lutz MB. Immature and maturation-resistant human dendritic cells generated from bone marrow require two stimulations to induce T cell anergy in vitro. *PLoS One* 2009;4:e6645.
- Shortman K, Liu YJ. Mouse and human dendritic cell subtypes. *Nat Rev Immunol* 2002;2:151-61.
- Chen YW, Shi R, Geraci N, Shrestha S, Gordish-Dressman H, Pachman LM. Duration of chronic inflammation alters gene expression in muscle from untreated girls with juvenile dermatomyositis. *BMC Immunol* 2008;9:43.
- Ross R, Jonuleit H, Bros M, Ross XL, Yamashiro S, Matsumura F, et al. Expression of the actin-bundling protein fascin in cultured human dendritic cells correlates with dendritic morphology and cell differentiation. *J Invest Dermatol* 2000;115:658-63.
- Tsoumakidou M, Kemp SJ, Thorley AJ, Zhu J, Dewar A, Jeffery PK, et al. Expression of blood dendritic cell antigens (BDCAs) by CD1a+ human pulmonary cells. *Respir Med* 2009;103:935-8.
- Zuniga EI, McGavern DB, Pruneda-Paz JL, Teng C, Oldstone MB. Bone marrow plasmacytoid dendritic cells can differentiate into myeloid dendritic cells upon virus infection. *Nat Immunol* 2004;5:1227-34.
- Abdullah HM, Higuchi I, Kubota R, Matsuura E, Hashiguchi A, Abdelbary NH, et al. Histopathological differences between human T-lymphotropic virus type 1-positive and human T-lymphotropic virus type 1-negative polymyositis. *Clin Exp Neuroimmunol* 2011;2:12-24.
- Valladeau J, Ravel O, Dezutter-Dambuyant C, Moore K, Kleijmeer M, Liu Y, et al. Langerin, a novel C-type lectin specific to Langerhans cells, is an endocytic receptor that induces the formation of Birbeck granules. *Immunity* 2000;12:71-81.
- Dziegiel P, Dolinska-Krajewska B, Dumanska M, Weclawek J, Jelen M, Podhorska-Okolow M, et al. Coexpression of CD1a, langerin and Birbeck's granules in Langerhans cell histiocytoses (LCH) in children: Ultrastructural and immunocytochemical studies. *Folia Histochem Cytobiol* 2007;45:21-5.
- Hunger RE, Sieling PA, Ochoa MT, Sugaya M, Burdick AE, Rea TH, et al. Langerhans cells utilize CD1a and langerin to efficiently present nonpeptide antigens to T cells. *J Clin Invest* 2004;113:701-8.



25. Valladeau J, Clair-Moninot V, Dezutter-Dambuyant C, Pin JJ, Kissenpfennig A, Mattei MG, et al. Identification of mouse langerin/CD207 in Langerhans cells and some dendritic cells of lymphoid tissues. *J Immunol* 2002;168:782-92.
26. Al-Alwan MM, Rowden G, Lee TDG, West KA. Fascin is involved in the antigen presentation activity of mature dendritic cells. *J Immunol* 2001;166:338-45.
27. Gendek-Kubiak H, Gendek EG. Dendritic cells' markers in idiopathic inflammatory myopathies [abstract]. 8th EFIS-EJI Tatra Immunology Conference, Strbske Pleso, Slovak Republic, 2008; p17.
28. Gendek-Kubiak H, Gendek EG. Some equivocality of "markers" used for identification of infiltration cells in myositic muscles [abstract]. *Folia Histochem Cytobiol* 2008;46 Suppl:S60.
29. Bohan A, Peter JB. Polymyositis and dermatomyositis (first of two parts). *N Engl J Med* 1975;292:344-7.
30. Zar JH. Two sample hypotheses. In: McElroy WD, Swanson CP, editors. *Biostatistical analysis*. Englewood Cliffs, NJ: Prentice-Hall Inc.; 1974:101-20.
31. Tournadre A, Porcherot M, Cherin P, Marie I, Hachulla E, Miossec P. Th1 and Th17 balance in inflammatory myopathies: Interaction with dendritic cells and possible link with response to high-dose immunoglobulins. *Cytokine* 2009;46:297-301.
32. Greenberg SA, Pinkus GS, Amato AA, Pinkus JL. Myeloid dendritic cells in inclusion-body myositis and polymyositis. *Muscle Nerve* 2007;35:17-23.
33. Reed AM, Ernste F. The inflammatory milieu in idiopathic inflammatory myositis. *Curr Rheumatol Rep* 2009;11:295-301.
34. Hussein MRA, Abu-Dief EE, Kamel NF, Mostafa MG. Steroid therapy is associated with decreased numbers of dendritic cells and fibroblasts, and increased numbers of satellite cells, in the dystrophic skeletal muscle. *J Clin Pathol* 2010;63:805-13.
35. Hussein MR, Hamed SA, Mostafa MG, Abu-Dief EE, Kamel NF, Kandil MR. The effects of glucocorticoid therapy on the inflammatory and dendritic cells in muscular dystrophies. *Int J Exp Pathol* 2006;87:451-61.
36. Chen YW, Zhao P, Borup R, Hoffman EP. Expression profiling in the muscular dystrophies. *J Cell Biol* 2000;151:1321-36.