

# Subacute Liver Failure Following Anakinra Treatment for Adult-onset Still Disease

To the Editor:

Anakinra is approved for the treatment of rheumatoid arthritis and it is used off-label for various other rheumatic diseases<sup>1</sup>. Although beneficial effects of anakinra on liver inflammation and regeneration have been shown<sup>2</sup>, we describe a case of subacute liver failure in a patient with adult-onset Still disease (AOSD) who had been treated with anakinra monotherapy.

Three months before admission to our hospital, the 20-year-old man had been diagnosed with AOSD. Initial treatment consisted of anakinra 100 mg and prednisolone 100 mg daily. The latter had been tapered to 10 mg after achieving remission 1 week before the first symptoms of liver failure appeared. The patient developed fever and jaundice. C-reactive protein was increased to 42 mg/dl, immunoglobulin E (IgE) was elevated to 709 kU/l, and transaminases were substantially increased, with alanine transaminase levels of 1128 U/l (Figure 1a). With an INR of 2.7, coagulation was massively disturbed.

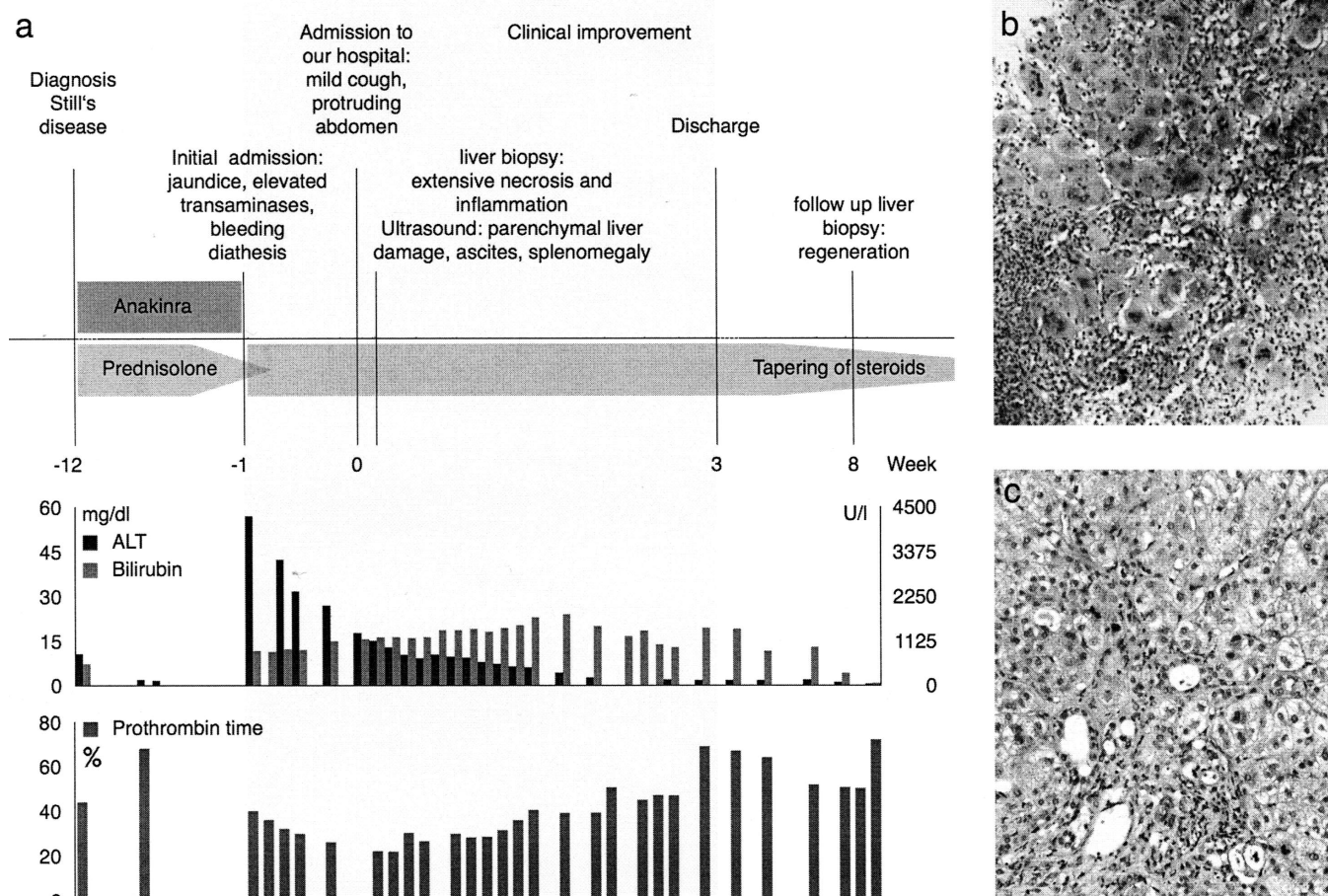
Abdominal ultrasound revealed parenchymal hepatic damage accompanied by ascites and splenomegaly. Liver perfusion was normal. Minilaparoscopy displayed a smooth liver surface and histology revealed extensive hepatocyte necrosis with inflammatory neutrophil infiltration (Figure 1b).

The patient had not been traveling, and the consumption of medications including over-the-counter or illicit drugs was reliably denied. Apart from

the patient's clinical presentation, which was not suggestive of an ongoing infection, extensive laboratory and microbiological tests excluded viral hepatitis and other viral, bacterial, and parasitic infections. Stable improvement was achieved by the increase in steroids, again strongly arguing against an infectious genesis of the presented liver failure. Autoimmune hepatitis, metabolic liver disease such as Wilson disease, hemochromatosis, and  $\alpha$ -1 antitrypsin deficiency have been ruled out. Hemophagocytic syndrome appeared implausible because clinical and laboratory criteria were not met, and massively elevated ferritin levels (i.e., 25,370  $\mu$ g/l) could be explained by his hepatic failure, as it is frequently seen in this condition<sup>3</sup>. Glutamate dehydrogenase levels were only mildly increased, again indicating unimpaired liver perfusion, and parasitic infection was unlikely owing to the absence of clinical features or eosinophilia.

After anakinra had been stopped and prednisolone had been re-increased to 100 mg per day, transaminases and liver synthesis ameliorated gradually (Figure 1a). Because bilirubin levels remained highly elevated, a second liver biopsy was performed, showing only the remains of necrotic liver injury and hepatic regeneration (Figure 1c). Prednisolone treatment was eventually tapered and bilirubin levels as well as transaminases further improved. Within 5 months, liver function tests normalized, notably without any sign of active Still disease.

Usually, AOSD-associated hepatitis can be successfully treated with anakinra<sup>4</sup>. The drug has demonstrated protective effects on acute liver injury by the blockage of interleukin 1 (IL-1), a proinflammatory cytokine.



**Figure 1.** Development of the clinical course and hematoxylin and eosin stainings of the liver biopsy. (a) Development of alanine transaminase (ALT, U/l), bilirubin (mg/dl), and prothrombin time (percent), with a summary of the clinical progress. (b) Present on admission were massive necrosis of hepatocytes with vast neoductal proliferation, lymphocytic and neutrophil-granulocytic infiltration, and swollen hepatocytes in regeneration, including polynuclear giant cells. (c) Eight weeks later, nearly normal morphology appeared, with signs of ongoing regeneration and cholestasis.

IL-1 $\beta$  inhibits hepatocyte proliferation in mice<sup>5</sup>, and it has been reported that the use of anakinra leads to improved regeneration after hepatectomy in mice<sup>2</sup>. Anakinra has been applied with 60,000 patient-years and side effects are usually mild<sup>6</sup>. Steatosis and focal hepatocytic necrosis have been observed in 1 woman<sup>7</sup>, and 3 children with systemic juvenile arthritis developed acute liver failure during anakinra treatment<sup>8</sup>. Here, hepatotoxicity did not inevitably result from anakinra alone and treatment with nonsteroidal antiinflammatory drugs (NSAID), might have significantly contributed to (if not mainly caused) liver damage.

Typical symptoms of AOSD include high spiking fevers, evanescent salmon-colored rash, arthralgias, and arthritis. Myalgias, sore throat, lymphadenopathy, splenomegaly, and neutrophilic leukocytosis are also frequently seen. In terms of liver involvement, hepatomegaly with coeval increase of transaminases are present in 50-75% of patients, but changes are usually mild<sup>9</sup>. Liver failure is untypical and appeared with other symptoms of active Still disease; all 9 reported cases were cotreated with NSAID<sup>10,11</sup>.

The German institution for pharmacovigilance ruled that an association between anakinra therapy and liver failure was possible in this case. Reactivation of AOSD appears highly unlikely because there was no other clinical manifestation of Still disease, not even after steroids had been tapered. Histologic findings in the initial biopsy and increased levels of IgE also argue in favor of immune-mediated drug-induced liver injury. The late beginning of liver failure 3 months after initiation of anakinra can be explained by the cotreatment with steroids, suppressing overwhelming immune responses; symptoms appeared promptly after these had been tapered. Other causes of liver damage had been ruled out.

This is the first case, to our knowledge, of anakinra-associated liver failure. It is of high importance to unravel the pathophysiology leading to anakinra-mediated hepatotoxicity, e.g., analysis of proinflammatory cytokines and proliferation after peripheral blood mononuclear cells have been treated with anakinra. The presentation of unexpected side effects can be misleading, and in case of anakinra use in AOSD, the clinician should not only think of liver involvement from the underlying disease but also of potential drug-induced hepatotoxicity.

LILIAN ALY, MD, Department of Gastroenterology and Hepatology;  
CHRISTOF IKING-KONERT, MD, Departments of Nephrology and Rheumatology; ALEXANDER QUAAS, MD, Department of Pathology;  
DANIEL BENTEN, MD, Department of Gastroenterology and Hepatology, University Medical Center Hamburg-Eppendorf, Martinistr. 52, 20246 Hamburg, Germany. Address correspondence to Dr. Bente; E-mail: d.benten@uke.de

## REFERENCES

1. Woo P. Anakinra treatment for systemic juvenile idiopathic arthritis and adult onset Still disease. *Ann Rheum Dis* 2008;67:281–2.
2. Sgroi A, Gonelle-Gispert C, Morel P, Baertschiger RM, Niclauss N, Mentha G, et al. Interleukin-1 receptor antagonist modulates the early phase of liver regeneration after partial hepatectomy in mice. *PLoS ONE* 2011;6:e25442.
3. Ozawa E, Abiru S, Nagaoka S, Yano K, Komori A, Migita K, et al. Ferritin/alanine aminotransferase ratio as a possible marker for predicting the prognosis of acute liver injury. *J Gastroenterol Hepatol* 2011;26:1326–32.
4. Mylona E, Golfinopoulou S, Samarkos M, Fanourgiakis P, Papadakos V, Skoutelis A. Acute hepatitis in adult Still's disease during corticosteroid treatment successfully treated with anakinra. *Clin Rheumatol* 2008;27:659–61.
5. Ogiso T, Nagaki M, Takai S, Tsukada Y, Mukai T, Kimura K, et al. Granulocyte colony-stimulating factor impairs liver regeneration in mice through the up-regulation of interleukin-1beta. *J Hepatol* 2007;47:816–25.
6. Mertens M, Singh JA. Anakinra for rheumatoid arthritis. *Cochrane Database Syst Rev* 2009;(1):CD005121.
7. Mahamid M, Paz K, Reuven M, Safadi R. Hepatotoxicity due to tocilizumab and anakinra in rheumatoid arthritis: two case reports. *Int J Gen Med* 2011;4:657–60.
8. Canna S, Frankovich J, Higgins G, Narkewicz MR, Nash SR, Hollister JR, et al. Acute hepatitis in three patients with systemic juvenile idiopathic arthritis taking interleukin-1 receptor antagonist. *Pediatr Rheumatol* 2009;7:21.
9. Wouters JM, van de Putte LB. Adult-onset Still's disease; clinical and laboratory features, treatment and progress of 45 cases. *Q J Med* 1986;61:1055–65.
10. Pouchot J, Sampalis JS, Beaudet F, Carrette S, Décaré F, Salusinsky-Sternbach M, et al. Adult Still's disease: manifestations, disease course, and outcome in 62 patients. *Medicine* 1991;70:118–36.
11. Linde B, Oelzner P, Katenkamp K, Hein G, Wolf G. Fulminate liver failure in a 39-year-old female patient with leukocytosis, unclear fever, and arthralgic pain [German]. *Med Klin* 2007;102:846–51.

*J Rheumatol* 2013;40:10; doi:10.3899/jrheum.121309