

RANK-RANKL-OPG in Hemophilic Arthropathy: From Clinical and Imaging Diagnosis to Histopathology

DANIELA MELCHIORRE, ANNA FRANCA MILIA, SILVIA LINARI, ELOISA ROMANO, GEMMA BENELLI, MIRKO MANETTI, SERENA GUIDUCCI, CLAUDIA CECCARELLI, MASSIMO INNOCENTI, CHRISTIAN CARULLI, ROBERTO CIVININI, MASSIMO MORFINI, MARCO MATUCCI-CERINIC, and LIDIA IBBA-MANNESCHI

ABSTRACT. *Objective.* Hemarthrosis triggers hemophilic arthropathy, involving the target joints. The histopathogenesis of blood-induced joint damage remains unclear. The triad of receptor activator of nuclear factor- κ B (RANK), RANK ligand (RANKL), and osteoprotegerin (OPG; RANK-RANKL-OPG) controls bone turnover. Our aim was to evaluate RANK-RANKL-OPG expression in the synovium of hemophilic patients with severe arthropathy.

Methods. Synovial biopsies were obtained from 18 patients with hemophilic arthropathy and 16 with osteoarthritis (OA) who were undergoing total knee replacement and synovectomy. The severity of hemophilic arthropathy was evaluated according to ultrasonography score, the World Federation of Hemophilia (WFH) orthopedic joint scale, and the radiographic Pettersson score. RANK-RANKL-OPG expression was examined by immunohistochemistry and Western blotting. Serum levels of soluble RANKL (sRANKL) and OPG from an extended group of 67 patients with hemophilic arthropathy and 30 healthy controls were measured by ELISA.

Results. The mean ultrasonography, WFH orthopedic joint scale, and Pettersson scores in patients with hemophilic arthropathy indicated severe arthropathy. A decreased expression of OPG was found in hemophilic arthropathy synovium compared with patients with OA. RANK and RANKL immunopositivity was strong in the lining and sublining layers in hemophilic arthropathy synovial tissue. Western blotting confirmed the immunohistological findings. Serum levels of sRANKL and OPG in patients with hemophilia were lower than in healthy controls.

Conclusion. In hemophilic arthropathy, the synovium highly expressed RANK and RANKL, whereas OPG immunopositivity decreased, suggesting an osteoclastic activation. Low tissue expression of OPG paralleled the serum levels of this protein and the severity of hemophilic arthropathy assessed by ultrasonography, Pettersson, and WFH orthopedic joint scale scores. (First Release July 1 2012; J Rheumatol 2012;39:1678–86; doi:10.3899/jrheum.120370)

Key Indexing Terms:

HEMOPHILIC ARTHROPATHY
SYNOVIUM

RANK-RANKL-OPG SYSTEM
ULTRASONOGRAPHY

From the Department of Biomedicine, Division of Rheumatology, Azienda Ospedaliero Universitaria Careggi (AOUC); the Excellence Centre for Research, Transfer and High Education DENOthe; the Department of Anatomy, Histology and Forensic Medicine; the Regional Reference Center for Inherited Coagulopathies, AOUC; and the Department of Traumatology and Orthopedics, University of Florence, Florence, Italy.

Supported by a grant from the Regional Government of Tuscany (Regione Toscana).

D. Melchiorre, MD, PhD, Department of Biomedicine, Division of Rheumatology, AOUC, and Excellence Centre for Research, Transfer and High Education DENOthe; A.F. Milia, PhD, Department of Biomedicine, Division of Rheumatology, AOUC, and Excellence Centre for Research, Transfer and High Education DENOthe, and Department of Anatomy, Histology and Forensic Medicine; S. Linari, MD, Regional Reference Center for Inherited Coagulopathies, AOUC; E. Romano, PhD, Department of Biomedicine, Division of Rheumatology, AOUC, and Excellence Centre for Research, Transfer and High Education DENOthe; G. Benelli, PhD; M. Manetti, PhD, Department of Anatomy, Histology and Forensic Medicine; S. Guiducci, MD, PhD, Department of

Biomedicine, Division of Rheumatology, AOUC, Excellence Centre for Research, Transfer and High Education DENOthe; C. Ceccarelli, Laboratory Technician, Department of Biomedicine, Division of Rheumatology, AOUC, Excellence Centre for Research, Transfer and High Education DENOthe; M. Innocenti, MD; C. Carulli, MD; R. Civinini, MD, Department of Traumatology and Orthopedics; M. Morfini, MD, Regional Reference Center for Inherited Coagulopathies, AOUC; M. Matucci-Cerinic, MD, PhD, Department of Biomedicine, Division of Rheumatology, AOUC, Excellence Centre for Research, Transfer and High Education DENOthe; L. Ibba-Manneschi, MD, Department of Anatomy, Histology and Forensic Medicine, University of Florence.

Dr. Melchiorre and Dr. Milia contributed equally to this work. Dr. Matucci-Cerinic and Dr. Ibba-Manneschi share the senior authorship of this report.

Address correspondence to Prof. L. Ibba-Manneschi, Department of Anatomy, Histology and Forensic Medicine, University of Florence, Largo Brambilla 3, 50134 Florence, Italy. E-mail: ibba@unifi.it

Accepted for publication May 8, 2012.

Hemophilia is characterized by a deficiency or functional defect of either coagulation factor VIII or IX, for hemophilia A or B, respectively¹. The disease affects mainly the joints, when even a few occurrences of bleeding lead to synovial hypertrophy and modifications of cartilage and subchondral bone. In this microenvironment, the synovium has an invasive and destructive interaction with bone and cartilage^{1,2}. Ankles, knees, and elbows are the joints most commonly affected by hemophilic arthropathy (HAt)³.

HAt was originally described as a degenerative rather than an inflammatory joint disease⁴. Recent studies indicate that HAt not only has similarities with degenerative joint modification such as osteoarthritis (OA), but also develops an inflammatory process similar to that found in rheumatoid arthritis (RA). Increased vascularity and neoangiogenesis, with involvement of key angiogenic factors, have been implicated in the development of hemophilic synovitis⁵. There is also evidence that these vascular changes may be sustained by the inflammatory stimuli due to iron deposits consequent to hemarthrosis⁶. The pathogenesis of HAt has not yet been fully elucidated.

Hemophilia can be treated either on demand to stop bleeding or with prophylaxis to prevent joint damage. Primary prophylaxis, defined as the start or regular continuous treatment before the age of 2 years or after the recurrence of the first joint bleeding³, is the "gold standard" regimen to prevent joint bleeding and HAt. Secondary prophylaxis, defined as all longterm regular treatments not fulfilling the criteria of primary prophylaxis, helps to prevent joint bleeding and to keep damage from worsening⁷. The administration of clotting factor stops bleeding, but arthropathy remains the most common and severe complication of hemophilia^{1,8}.

A crucial pathway regulating bone biology is the molecular triad consisting of receptor activator of nuclear factor- κ B (RANK), RANK ligand (RANKL), and osteoprotegerin (OPG)⁹, which tightly controls bone turnover. RANKL, a member of the tumor necrosis factor (TNF) receptor superfamily, is a transmembrane ligand mainly expressed on osteoblasts/stromal cells in the bone microenvironment. RANKL exists either as a cell-bound form or a truncated ectodomain variant released by enzymatic cleavage of the cellular form [soluble RANKL (sRANKL)]. RANKL binds to its receptor RANK expressed on the cell surface of osteoclast precursors, and induces osteoclast differentiation and maturation, leading to bone resorption. In the synovium, RANKL is expressed by fibroblast-like synoviocytes (type B synoviocytes) and by activated T cells, and may induce osteoclastogenesis through a mechanism enhanced by several cytokines, including TNF- α , interleukin 1 (IL-1), and IL-17, that promote both inflammation and bone resorption^{10,11}. OPG, another member of the TNF receptor superfamily, acts as a decoy receptor for RANKL and competes for binding of RANKL to RANK^{12,13,14}. By this mechanism, OPG inhibits osteoclast differentiation, activity, and survival both *in vivo*

and *in vitro*^{9,11,14,15,16}. RANKL inhibits whereas OPG promotes osteoclast apoptosis¹⁷. OPG is predominantly expressed in macrophages of the intimal synovial lining layer and in endothelial cells, where it is complexed with von Willebrand factor (vWF) within the Weibel-Palade bodies¹⁶.

Any change in the balance between OPG and RANKL leads to pathological bone conditions. In RA, characterized by both inflammation and bone erosions, the interaction between the RANK-RANKL-OPG system and T cells has been demonstrated^{10,11}. Few studies have addressed the pathological features of HAt^{18,19}. A high prevalence of osteoporosis among hemophilic patients has been reported; the condition is related to the severity of arthropathy and is enhanced by human immunodeficiency virus (HIV) infection. Therefore, high bone resorption seems not to be balanced by comparable bone formation^{18,19}.

Our aim was to analyze the expression of the RANK-RANKL-OPG triad in synovial tissue from patients with HAt, treated on demand (HAtOD) or with secondary prophylaxis (HAtSP), who underwent knee joint surgery. We also evaluated the circulating levels of OPG and sRANKL in patients with HAt.

MATERIALS AND METHODS

Patients. Sixty-seven patients (median age 38.6 yrs, range 10–85) affected by severe (82%) and moderate (18%) hemophilia A (Factor VIII: C < 1 or 1%–5%, respectively) were recruited and followed up at the Agency for Hemophilia, University Hospital, Florence, Italy. Forty-five/67 patients were treated on demand and 22/67 with secondary prophylaxis, defined as longterm continuous factor replacement therapy 3 times per week at a dosage of 25 U/kg²⁰. Secondary prophylaxis was started at an age between 16 and 68 years (median 29 yrs), when the median of total joint bleeding occurrences per year was 9 (range 6–14), with a median of target joints of 2 per patient (range 1–6). In patients with HAtOD, the median of total joint bleeding occurrences per year was 6 (range 3–12), with a median of target joints of 2 per patient (range 1–5). All 22 patients who switched to secondary prophylaxis are still undergoing this treatment. Fifty-one of 67 patients (76%) were positive for the hepatitis C virus (HCV). HCV viremia was present in 22/51 subjects (43%) and HCV-RNA was undetectable (< 15 IU/mol) in the other 29 patients (57%); 25/29 had received anti-HCV therapy. Fourteen/67 patients (21%) were also HIV-positive with undetectable viremia (HIV-RNA < 20 cp/ml), and were receiving antiretroviral therapy. Blood samples were collected for serum measurements of circulating sRANKL and OPG from the patients with hemophilia and 30 age-matched and sex-matched healthy subjects (median age 36.5 yrs, range 18–73) used as controls.

Synovial biopsy samples. Eighteen/67 patients (median age 40 yrs, range 22–66) with severe knee HAt underwent synovectomy or arthroplasty. Ten/18 patients (56%) were treated on demand and 8/18 (44%) with secondary prophylaxis. Sixteen/18 patients (89%) were HCV-positive, and 4 of them (22%) were also HIV-positive and were treated with antiretroviral therapy. Samples of synovial tissue from 18 patients with HAt were obtained during surgery at the Department of Orthopedics and Traumatology, Plastic Surgery and Rehabilitation, University of Florence. Synovial biopsies from 16 age-matched and sex-matched patients with OA (median age 67.9 yrs, range 35–78) were used as a control group for the histopathological analysis.

All subjects gave written informed consent, and the study protocol was carried out under the terms of the Declaration of Helsinki and approved by the institutional medical ethics committee of the local government.

Instrumental analyses. The severity of HAt of the 18 patients who underwent

synovial biopsy was evaluated according to the World Federation of Hemophilia orthopedic joint scale (WFH), which consists of a physical examination and a pain scale²¹. Knee radiographs and ultrasonography (US) were also scored in each joint. The radiograph score (Petterson score) evaluates osteoporosis, enlarged epiphysis, irregular subchondral surface, narrowing of the joint space, subchondral cyst formation, erosions of the joint margins, gross incongruity of articulating bone ends, and joint deformity (angulation and/or displacement between articulating bones)²². The joint score for a single joint ranges from zero (normal) to 13 (destroyed). US is an imaging method for detecting joint structures, muscles, tendons, sheaths, and entheses. Further, it is well known that power Doppler US (PDUS) may identify synovial blood flow. Sonographic score is based on a semiquantitative method, ranging from 0–21 with a cutoff < 5²³.

Histochemistry and immunohistochemistry. All synovial specimens were cut into small pieces. One part was fixed in 10% buffered formalin and, after standard processing, embedded in paraffin and used for light microscopy analysis. The other part was immediately frozen in liquid nitrogen for protein extraction and Western blotting analysis.

Paraffin sections were stained with H&E and 3 randomly chosen sections of the stained samples of 2 representative pieces per patient were scored by 2 blinded observers. For immunohistochemistry analysis, serial sections were stained with the following primary mouse monoclonal antibodies: anti-human RANK (Abcam, Cambridge, UK), anti-human RANKL (Abcam), and anti-human OPG (Santa Cruz Biotechnology, Santa Cruz, CA, USA). After blocking endogenous peroxidase activity, immunohistochemistry analysis was performed using the Ultravision Detection System (LabVision Corporation, Fremont, CA, USA) according to the manufacturer's protocol. The immunopositive products were detected using 3,3'-diaminobenzidine tetrahydrochloride substrate (DAB kit; Vector Laboratories, Burlingame, CA, USA). The sections were counterstained with hematoxylin and observed under a light microscope (Eclipse E400; Nikon, Tokyo, Japan) and then photographed with a digital camera (Coolpix 2500; Nikon, Tokyo, Japan). Negative controls were obtained by omitting the primary antibodies.

Western blotting. Proteins were extracted from synovial specimens by homogenization for 5 min in ice-cold lysis buffer [50 mM Tris HCl (pH 7.4), 150 mM NaCl, 1 mM EDTA, 1% Triton X-100, 0.25% sodium dodecyl sulfate (SDS)] supplemented with the protease inhibitor cocktail (Complete; Roche, Mannheim, Germany), followed by sonication. The solution was cleared by centrifugation for 30 min at 4°C at 15,000 rpm and assayed for protein content using Bradford's method. Fifty micrograms of proteins were electrophoresed in SDS 12%–13.5% polyacrylamide gel under reducing conditions and then blotted to a nitrocellulose transfer membrane (Amersham Biosciences, Piscataway, NJ, USA). The membranes were blocked in 5% nonfat dry milk with 0.05% Tween-20 in phosphate buffered saline for 1 h at room temperature, and then incubated overnight at 4°C with the following mouse monoclonal anti-human antibodies: anti-RANK and anti-RANKL (both 1.5 µg/ml; Abcam), and anti-OPG (1:1000; Santa Cruz Biotechnology). After incubation with horseradish peroxidase-conjugated anti-mouse IgG (Cell Signaling Technology, Beverly, MA, USA) for 1 h at room temperature, immune complexes were detected with the enhanced chemiluminescence detection system (Amersham Biosciences). The membranes were exposed to autoradiographic films (Amersham Biosciences). Blots were stripped and reprobed with rabbit monoclonal antihuman α -tubulin antibodies (1:1000; Cell Signaling Technology) to confirm similar loading of the gels and efficiency in electrophoretic transfer. Densitometric analysis of the bands was performed using Image J software (US National Institutes of Health, Bethesda, MD, USA).

ELISA. Serum levels of sRANKL and OPG were measured with quantitative sandwich ELISA kits (Ampli sRANKL, Biomedica Medizinprodukte GmbH & Co., Vienna, Austria; Human OPG Instant ELISA, Bender Medsystems, Vienna), following the manufacturer's instructions. For both sRANKL and OPG assays, the interassay and intraassay variances were < 10%.

Statistical analysis. These analyses were performed using SPSS software for Windows (Version 12.0). Data are shown as mean \pm SD or median and range.

The nonparametric Mann-Whitney U test was used to analyze significant differences between 2 independent groups. Spearman's rank correlation coefficient (r) was used to analyze the relationship between 2 continuous variables. All p values were 2-tailed and $p < 0.05$ was considered statistically significant.

RESULTS

Clinical and imaging findings. WFH clinical score, Petterson score, and sonographic score were evaluated in 18 patients with HAt who underwent surgery. The mean WFH clinical score was 39.5 ± 15.8 points for HAtOD (range 12–57) and 35 ± 17.5 for HAtSP (range 19–71), with no significant difference. The mean Petterson score was 10.4 ± 2.5 points (range 6–12) for HAtOD and 8.25 ± 2.6 for HAtSP (range 4–12), with no significant difference.

The cutoff of the sonographic score in all patients was > 5 and the mean value was 10.4 ± 1.52 points for HAtOD and 11.5 ± 2.3 points for HAtSP. In 11/18 patients (61.1%), US detected effusion hydrarthrosis; in 4/18 (22.2%), effusion hemarthrosis; in 8/18 (44%), hemosiderin deposition (Figure 1A); in 5/18 (27.7%), synovial hypertrophy with flags on PDUS (Figure 1B); in 12/18 (67%), synovial hypertrophy without flags on PDUS (Figure 1C); in 2/18 (11%), fibrotic septa; in 4/18 (22.2%), erosion; and in 18/18 patients (100%), osteophytes, bone remodeling, and cartilage modifications.

Histological analysis. HAt synovial tissue showed hypertrophy and hyperplasia of the lining cells resulting in villi and folds, as observed also in OA. In HAt, intracellular deposits of hemosiderin, a breakdown product of hemoglobin, were observed in the lining cells as discrete brown granules. Aggregates of ferritin and iron as extracellular dense oval bodies were present in the sublining tissue, near areas of normal appearance. The sublining was characterized by hypervascularization, with inflammatory infiltrates around the vessels. Some areas of the sublining layer showed vessels with a hyperplasia of intima and media and narrowing lumen. A diffuse mild infiltration of inflammatory cells was observed in HAt synovium, different from the distinct follicular structures observed in OA (Figure 1 E-H).

Expression of osteoclastogenesis-modulating factors in synovial tissue. RANK was strongly expressed in the lining, sublining, and vascular endothelium in HAt synovium, with no relevant differences between HAtOD and HAtSP, as shown in Figure 2A. In OA, RANK was expressed less in the lining, but was strongly expressed by the inflammatory infiltrates in the sublining layer (Figure 2A).

RANKL was expressed in the intimal lining layer and in the sublining in HAt, as well as in OA (Figure 2A).

Reduced expression of OPG in HAt synovial tissue. In HAtOD tissue, only a few cells of the sublining were positive for OPG, the decoy receptor for RANKL. In tissue from HAtSP, the positivity for OPG was increased in both the lining and sublining, as well as in the vascular endothelium of some vessels (Figure 2A). By contrast, in OA tissue, OPG was found

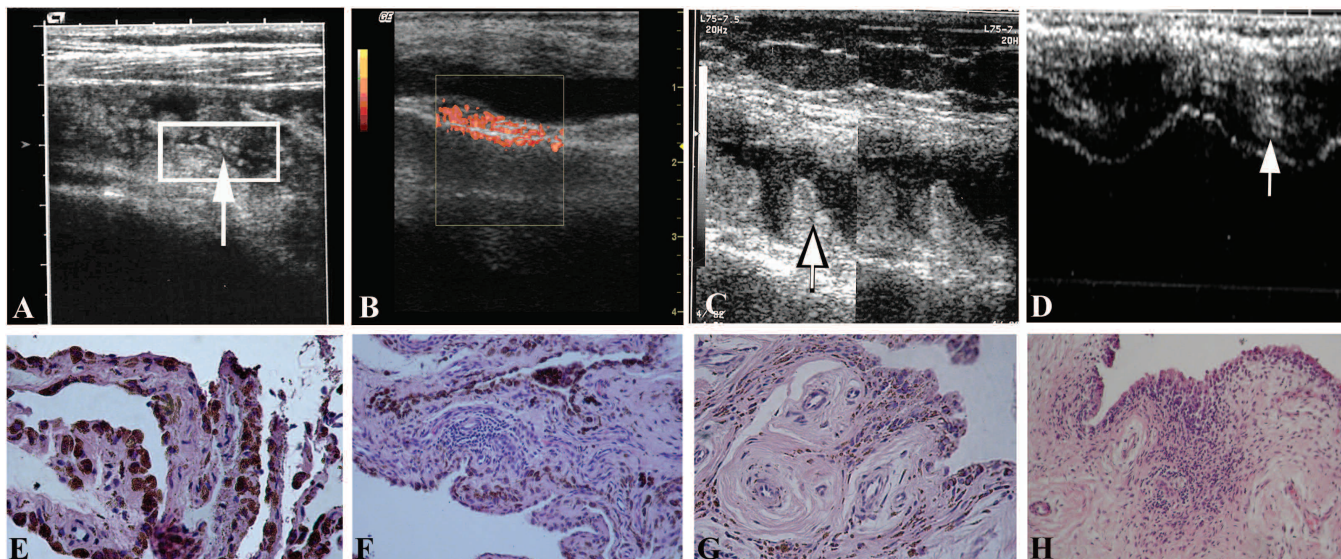


Figure 1. Ultrasonographic (US) and histological images of hemophilic arthropathy (HAT) synovial tissue. A-D are representative images of the knee by US. A. Deposit of hemosiderin is visible as a little oval shape with hyperechoic surface (arrow) on the synovial tissue. B. Power Doppler US (PDUS) signal and marked increase of the synovial tissue are visible in the box. C. Marked increase of the synovial tissue (arrow) without PDUS signal. D. Osteoarthritis (OA) of the knee showing reduction of joint space with marked irregularity of bone profile. The cartilage structure is hyperechoic (arrow). E-H: representative images of histopathological features in synovial tissue of patients with HAT. E. Synovial villi show intracellular brown granules of hemosiderin. F. Diffuse infiltrate of inflammatory cells in the synovial sublining layer. G. Vessels showing hypertrophy of intima and media with narrowing lumen. H. Inflammatory cells arranged in follicular structures are observed in OA synovium. H&E staining. Original magnification: E, G $\times 20$; F, H $\times 10$.

strongly expressed in synovial lining cells, as well as in endothelial cells, as shown in Figure 2A. Instrumental and immunohistochemical data are summarized in Table 1.

Western blot analysis. RANK, RANKL, and OPG protein expression levels were evaluated in protein extracts from synovial tissue using Western blotting (Figure 2B). The antibodies detected single protein bands with approximate molecular weights of 97 kDa for RANK, 35 kDa for RANKL, and 60 kDa for monomeric OPG (Figure 2B). The protein expression profiles indicated that there was a significant decrease in OPG levels in HAtOD compared with HAtSP and OA, as well as in HAtSP compared with OA (Figure 2B). Western blotting confirmed the immunohistochemical findings.

Circulating levels of sRANKL and OPG. Circulating sRANKL was detected in 60 of 67 patients with hemophilia (89.5%) and in all controls (100%). Serum levels of sRANKL were significantly lower in patients with hemophilia (median 0.15 pmol/l, range 0–4.91) compared to controls (median 0.225 pmol/l, range 0.05–3.8; $p < 0.05$; Figure 3A). In patients with hemophilia, serum levels of sRANKL correlated inversely with US score ($r = -0.75$, $p = 0.012$). The same direction was observed for correlation with Pettersson and WFH scores, although these analyses did not reach statistical significance ($r = -0.58$, $p = 0.079$, and $r = -0.49$, $p = 0.15$, respectively).

Circulating OPG was detected in 63 out of 67 patients with hemophilia (94%) and in all controls (100%), with a median 19.59 pg/ml (range 0–363.42) and 44.36 pg/ml (range 11.16–747.18), respectively. OPG levels were significantly

lower in patients with hemophilia compared to controls ($p < 0.001$; Figure 3B). In patients with hemophilia, circulating levels of OPG showed a significant inverse correlation with US score ($r = -0.77$, $p = 0.009$) and Pettersson score ($r = -0.73$, $p = 0.017$). A trend toward significant association was found with WFH score ($r = -0.57$, $p = 0.08$).

Serum levels of sRANKL and OPG were not different between patients with HAtOD and those with HAtSP (data not shown).

DISCUSSION

The molecular RANK-RANKL-OPG triad is involved in the pathogenesis of bone loss and arthropathy. To date, few studies have addressed the role of these molecules in HAt^{19,21}.

This is the first report, to our knowledge, on osteoclastogenesis-modulating factors in human HAt synovial tissue. Our results showed decreased levels of OPG in all patients with HAt, and strong expression of RANK and RANKL. We also observed a correlation between instrumental findings and severity of HAt, according to WFH, Pettersson, and sonographic scores.

Joint bleeding, or hemarthrosis, occurs in the larger joints of patients with hemophilia, resulting in severe arthropathy. A single hemorrhage may lead to irreversible joint damage, as demonstrated in previous studies^{24,25}. Further, microhemorrhages are sufficient to induce severe joint damage in later years³. Blood-induced arthropathy has characteristics of both degenerative joint disease such as OA, and inflammation-induced joint damage such as RA²⁴.

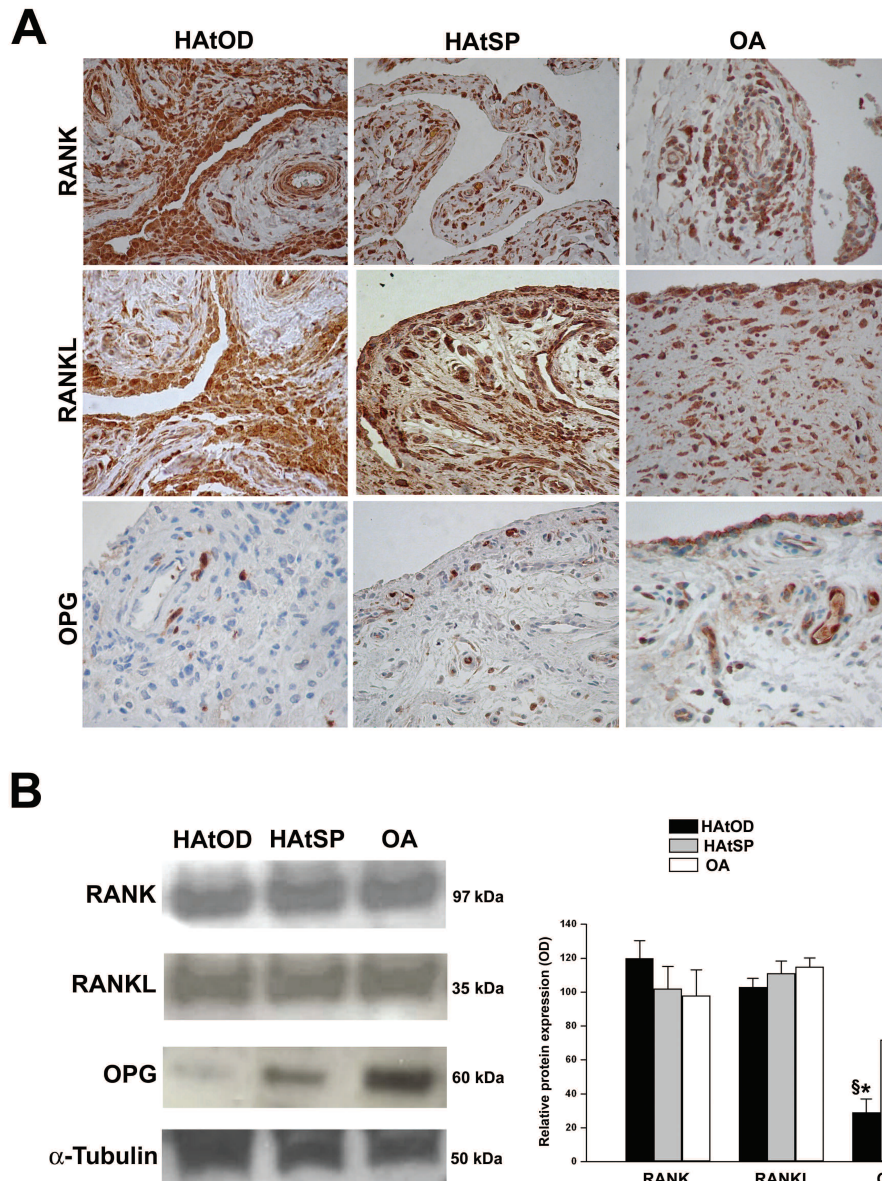


Figure 2. Immunohistochemistry and Western blotting analysis for RANK-RANKL-OPG. **A.** Representative microphotographs of immunohistochemical staining for RANK, RANKL, and OPG in synovial tissue from patients with hemophilic arthropathy with on-demand therapy (HAtOD; left panels), hemophilic arthropathy with secondary prophylaxis (HAtSP; middle panels), and patients with osteoarthritis (OA; right panels). Original magnification: Left panels: RANK, RANKL $\times 20$; OPG $\times 40$. Middle panels: RANK $\times 20$; RANKL, OPG $\times 40$. Right panels: RANK $\times 20$; RANKL, OPG $\times 40$. **B.** Western blotting analysis of RANK, RANKL, and OPG protein in synovial tissue samples. Blots were stripped and reprobed with anti- α -tubulin antibodies as a loading control for normalization. Numbers on the right indicate molecular weight. Lanes are shown in the left panel. Right panel: Bars represent intensity of bands, quantified by densitometry (mean \pm SD). Levels of RANK and RANKL in synovial tissue are elevated while OPG is significantly decreased in HAtOD compared to OA and HAtSP and in HAtSP compared to OA. (* $p < 0.05$ vs OA, $\$p < 0.05$ vs HAtSP, by ANOVA and Tukey's w-test). OD: optical density in arbitrary units.

An important characteristic of HAt synovial changes is the deposition of iron (hemosiderin) in the synovium. Iron has a double effect on synovial tissue. Hemosiderin, a breakdown product of hemoglobin, accumulates in the synovial tissue, causing oxidant damage that induces inflammation. The hemosiderin cannot be fully cleared from the synovium and this leads to an increased production of the proinflammatory

cytokines IL-1, IL-6, and TNF- α ²⁶, which are known for their tissue-destructive properties²⁴. Further, there is evidence for an iron proliferative effect on synoviocytes among synovial changes occurring during hemarthrosis¹.

In our samples, synovial lining cells of both HAtOD and HAtSP showed deposits of hemosiderin as discrete granules in the cytoplasm, whereas dense intracellular and extracellular

Table 1. Clinical, instrumental, and histological findings in 18 patients with hemophilic arthropathy (HAt) who underwent surgery. Comparison is between patients with secondary prophylaxis (HAtSP) and patients with on-demand therapy (HAtOD).

	HAtSP	HAtOD
WFH score	35	39.5
Pettersson score	8.25	10.4
Sonographic score	> 5 (11.4)	> 5 (10.4)
RANK	+++	+++
RANKL	++	++
OPG	+	±

Score values are calculated as mean. WFH score ranges from 0 to 86. Pettersson score varies between zero (normal joint) and 13 (destroyed joint). Sonographic score ranges from 0–21, with a cutoff < 5 (normal range 0–4) and > 5 (pathological range 5–21). For immunohistochemistry semiquantitative scoring was performed independently by 2 blinded observers, based on immunostained synovial sections for receptor activator of nuclear factor κ B (RANK)-RANK ligand (RANKL)-osteoprotegerin (OPG). Score definitions: +++ intense staining; ++ moderate staining; + weak staining; ± not homogeneous positive staining. WFH: World Federation of Hemophilia orthopedic joint scale.

aggregates were visible in the sublining layer. The histopathological features observed in our biopsies are in agreement with previous studies^{4,26,27}. Further, it has also been demonstrated that magnetic resonance imaging (MRI) and PDUS may be important diagnostic tools in the evaluation of synovial changes^{23,28}. In 17/18 patients, the sonographic synovial study showed a thickened synovium (> 2.5 mm) and in 5/18 patients, power Doppler activity was also present, with flags scored according to validated method²³. These findings are in agreement with the evidence of hypervascularization and vascular changes in the sublining, such as thickened wall and narrowed lumen, suggesting vessel involvement (Figure 1). Neovascularization and pathological vascular changes may be induced by the continuous inflammatory stimuli due to iron deposits. This has also been demonstrated in an animal model of hemophilia⁶. In patients with HAt, a recent study demonstrated an increase in proangiogenic factors, such as vascular endothelial growth factor-A, stromal cell-derived factor-1, and matrix metalloproteinase-9, together with proangiogenic monocytes/macrophages in the synovium and peripheral blood supporting the hypothesis of a pathogenetic role of angiogenesis in HAt^{5,29}.

As the iron accumulates, the metabolic properties of the synovium are modified, thus inducing pathological events also involving articular cartilage and subchondral bone. In fact, inhibition of the proteoglycan synthesis rate and their loss from the cartilage matrix occur at the articular level¹. The subchondral bone changes frequently observed in HAt joints are osteoporosis, subchondral cyst formations, and bone erosions and osteophytes leading to ankylosis^{1,22}. In all our patients with HAt, the US and Pettersson score values confirmed the presence of bone and cartilage modifications, showing the severity of arthropathy (Figure 4). Whether such

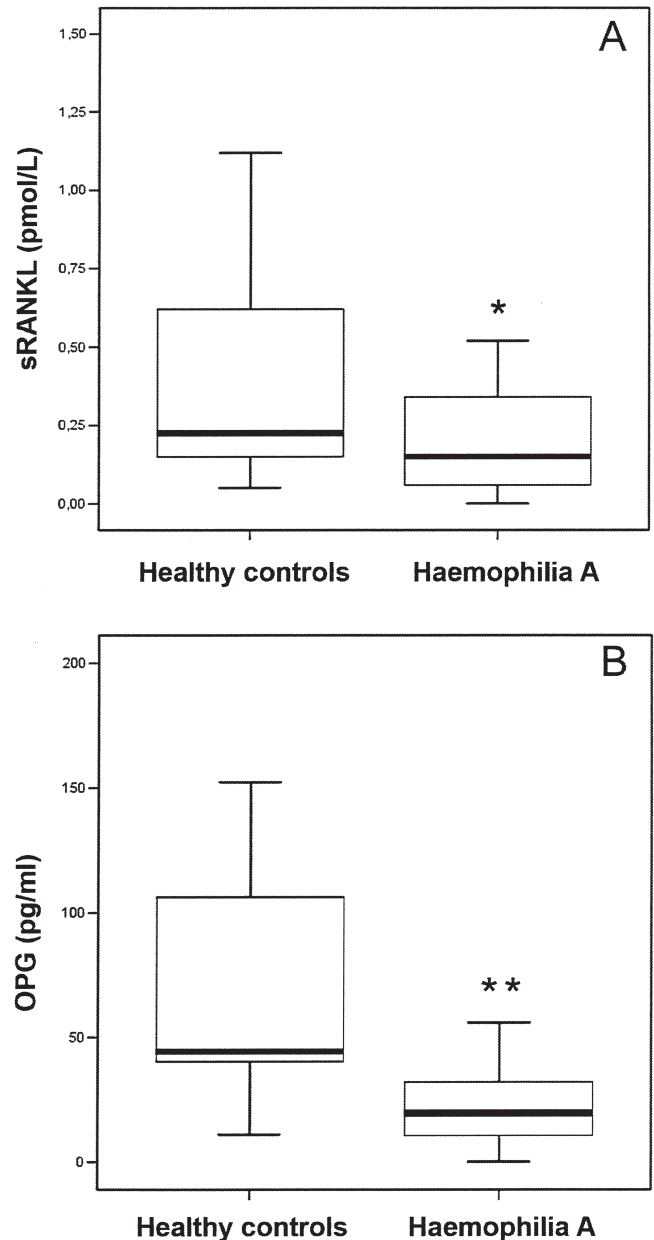


Figure 3. ELISA for soluble receptor activator of nuclear factor- κ B ligand (sRANKL) and osteoprotegerin (OPG). Serum concentration of sRANKL (A) and OPG (B) in 67 patients with hemophilia A and 30 healthy controls. Boxes show 25th and 75th percentiles. Lines within boxes show medians. Vertical lines below and above boxes show 10th and 90th percentiles. Significant differences between patients with hemophilia and healthy controls are indicated: * $p < 0.05$, ** $p < 0.01$.

changes are a consequence of inflammatory and degenerative processes that may coincide with or even precede cartilage damage is still unknown¹. The mechanisms and pathways of blood-induced damages in cartilage and bone are yet to be completely understood.

Members of the TNF receptor superfamily such as RANK, RANKL, and its decoy receptor OPG are involved in cartilage

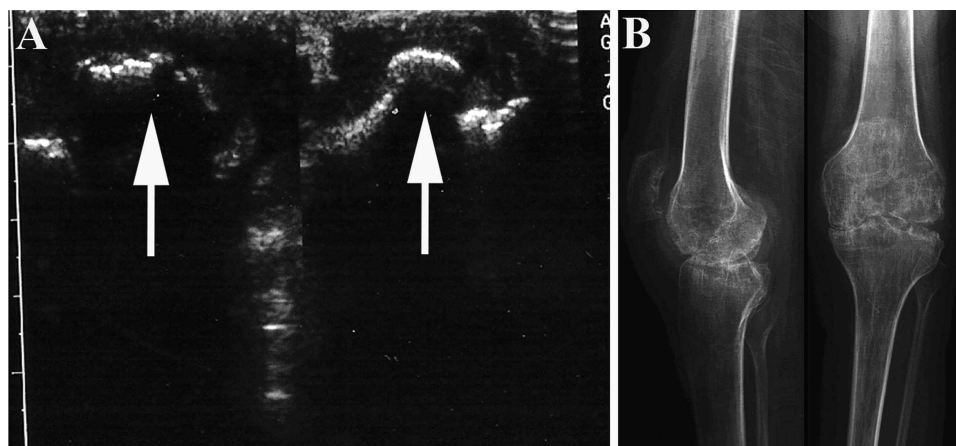


Figure 4. Representative images of ultrasonographic (US) and radiological findings of the knee in patients with hemophilic arthropathy. A. Bone remodeling with osteophytes and calcifications (arrows) of medial femoral condyle by US. B. Cartilage alterations, bone remodeling, calcifications, and osteophytes are shown by radiograph.

and bone remodeling in most adult skeletal diseases, such as osteoporosis, periodontal disease, and RA. Indeed, the balance of these proteins tightly regulates osteoclast formation and activity, as they are the final effector proteins of osteoclastic bone resorption⁶. Several studies reported reduced bone density among patients with hemophilia, and this is likely explained by their blood-induced arthropathy, which has a severe effect on bone mineralization³⁰.

In our study, the expression of molecular markers of bone turnover in the synovial tissue of patients with HAt indicates an osteoclastic activation not counteracted by OPG. RANK and RANKL were strongly expressed in the synovium of patients with HAtOD and those with HAtSP. The expression of OPG was dramatically reduced in synovial tissue of patients with HAtOD, whereas the synovium from HAtSP showed a higher positivity compared to the HAtOD group, also at the endothelial level. Similarly to our findings, the expression of OPG was found by others to be strongly reduced in vessels of the inflamed pannus of active RA and interestingly, OPG expression normalized with remission of arthritis^{16,31}.

Serum levels of both sRANKL and OPG were decreased in our cohort of patients with HAt compared to controls. Unexpectedly, the serum levels of sRANKL in our patients were not increased and did not reflect the expression at the tissue level. This may be due to methodological aspects or to pathophysiological factors related to this complex disease. sRANKL levels may be influenced by several factors³¹. Moreover, physiological factors such as cyclic variation, age, and sex, and the relative instability of serum sRANKL, must also be considered in interpretation of sRANKL assay results. However, although serum levels may be relevant, the data on synovial tissue are the most significant aspects of what occurs at the joint level. RANKL was strongly expressed in our syn-

ovial HAt samples, suggesting a proactivated osteoclastic mechanism likely induced by the inflammatory process, as proposed by Valentino in a murine model of hemophilia and as demonstrated in RA synovitis⁶.

The lower expression of OPG in HAt, in both synovial tissue and serum, represents an important finding. The absence of OPG in synovial tissue implies that the RANK-RANKL-OPG balance is shifted toward osteoclastic activation. The serum levels of OPG in our study reflect the tissue finding, even though it is known that circulating OPG levels may originate from various tissues besides bone³².

The few studies that have addressed the measurement of serum levels of sRANKL and OPG in patients with HAt have shown varying results^{18,19}. Several researchers have demonstrated that serum OPG concentrations increase with age in both women and men^{33,34}, but in our samples there were no differences of OPG serum levels related to age (data not shown).

The activity of OPG is increased by the FVIII-vWF complex. This complex inhibits RANKL-induced osteoclastogenesis by a physical interaction between FVIII-vWF complex and RANKL and by a synergic effect with OPG¹⁶. The increased osteoclastogenesis in HAt may be supported by the increased expression of RANKL and by a deficiency of FVIII-vWF complex.

Our histological and serological results showed a correlation with instrumental and clinical data. The US findings revealed bone and cartilage involvement in addition to synovial hypertrophy and PDUS activity. Sonographic, Pettersson, and WFH scores demonstrated severe HAt in our patients. Ours is the first study, to our knowledge, to indicate that osteoclastogenesis is activated in the synovial tissue of patients with HAt and may be mediated by the inflammatory milieu. The activated osteoclastogenesis may be responsible

for the severity of HAt, independently from the regimen therapy with FVIII. Our data showed that even though OPG expression was increased in synovial tissue in HAtSP compared with HAtOD, patients with HAtSP developed arthropathy as severe as patients with HAtOD. Assuming that low OPG levels are indeed of pathophysiologic relevance, OPG levels in HAtSP, although significantly higher than in HAtOD, are still low enough to cause severe joint damage. Therapy did not influence RANK and RANKL expression. Our results did not show a significant difference in the synovial changes between HAtSP and HAtOD. According to the literature^{3,27}, the secondary prophylaxis did not slow down the progression of the arthropathy. However, we should consider that secondary prophylaxis usually starts when blood-induced joint damage has already occurred. We cannot exclude the possibility that earlier prophylaxis might influence the balance among bone remodeling regulators. Further studies are needed to obtain a wide view of the pathological mechanisms of HAt, including patients with hemophilia B, although the importance of the RANK-RANKL-OPG triad in the development of severe HAt in hemophilia A seems to be corroborated by our data.

REFERENCES

- Jansen NW, Roosendaal G, Lafeber FP. Understanding haemophilic arthropathy: An exploration of current open issues. *Br J Haematol* 2008;143:632-40.
- Hoots WK. Pathogenesis of haemophilic arthropathy. *Semin Hematol* 2006;43 Suppl 1:S18-22.
- Manco-Johnson MJ, Abshire TC, Shapiro AD, Riske B, Hacker MR, Kilcoyne R, et al. Prophylaxis versus episodic treatment to prevent joint disease in boys with severe hemophilia. *N Engl J Med* 2007;357:535-44.
- Roosendaal G, van Rinsum AC, Vianen ME, van den Berg HM, Lafeber FP, Bijlsma JW. Haemophilic arthropathy resembles degenerative rather than inflammatory joint disease. *Histopathology* 1999;34:144-53.
- Achayra SS, Kaplan RN, Macdonald D, Fabiyi OT, DiMichele D, Lyden D. Neo-angiogenesis contributes to the development of haemophilic synovitis. *Blood* 2011;117:2484-94.
- Valentino LA. Blood induced joint disease: The pathophysiology of haemophilic arthropathy. *J Thromb Haemost* 2010;8:1895-902.
- Berntorp E, Astermark J, Bjorkman S, Blanchette VS, Fischer K, Giangrande PL, et al. Consensus perspectives on prophylactic therapy for haemophilia: Summary statement. *Haemophilia* 2003;9 Suppl 1:1-4.
- Hoots WK, Rodriguez N, Boggio L, Valentino LA. Pathogenesis of haemophilic synovitis: Clinical aspects. *Haemophilia* 2007;13 Suppl 3:4-9.
- Baud'huin M, Duplomb L, Téletchéa S, Charrier C, Maillason M, Fouassier M, et al. Factor VIII-von Willebrand factor complex inhibits osteoclastogenesis and controls cell survival. *J Biol Chem* 2009;284:31704-13.
- Vandooren B, Cantaert T, Noordenbos T, Tak PP, Baeten D. The abundant synovial expression of the RANK/RANKL/osteoprotegerin system in peripheral spondylarthritis is partially disconnected from inflammation. *Arthritis Rheum* 2008;58:718-29.
- Saidenberg-Kermanac'h N, Cohen-Solal M, Bessis N, De Vernejoul MC, Boissier MC. Role of osteoprotegerin in rheumatoid inflammation. *Joint Bone Spine* 2004;71:9-13.
- Lacey DL, Timms E, Tan H-L, Kelley MJ, Dunstan CR, Burgess T, et al. Osteoprotegerin ligand is a cytokine that regulates osteoclast differentiation and activation. *Cell* 1998;93:165-76.
- Holstead Jones D, Kong Y-Y, Penninger JM. Role of RANKL and RANK in bone loss and arthritis. *Ann Rheum Dis* 2002;61 Suppl II:ii32-9.
- Hofbauer LC, Heufelder AE. Role of receptor activator of nuclear factor-kappa B ligand and osteoprotegerin in bone cell biology. *J Mol Med* 2001;79:243-53.
- Simonet WS, Lacey DL, Dunstan CR, Kelley M, Chang MS, Lüthy R, et al. Osteoprotegerin: A novel secreted protein involved in the regulation of bone density. *Cell* 1997;89:309-19.
- Zannettino AC, Holding CA, Diamond P, Atkins GJ, Kostakis P, Farrugia A, et al. Osteoprotegerin (OPG) is localized to the Weibel-Palade bodies of human vascular endothelial cells and is physically associated with von Willebrand factor. *J Cell Physiol* 2005;204:714-23.
- Skoumal M, Kolarz G, Haberhauer G, Woloszczuk W, Hawa G, Klingler A. Osteoprotegerin and the receptor activator of NF-kappa B ligand in the serum and synovial fluid. A comparison of patients with longstanding rheumatoid arthritis and osteoarthritis. *Rheumatol Int* 2005;26:63-9.
- Katsarou O, Terpos E, Chatzismalis P, Provelengios S, Adraktas T, Hadjidakis D, et al. Increased bone resorption is implicated in the pathogenesis of bone loss in hemophiliacs: Correlations with haemophilic arthropathy and HIV infection. *Ann Hematol* 2010;89:67-74.
- Christoforidis A, Economou M, Papadopoulou E, Kazantzidou E, Farmaki E, Tzimouli V, et al. Comparative study of dual energy X-ray absorptiometry and quantitative ultrasonography with the use of biochemical markers of bone turnover in boys with haemophilia. *Haemophilia* 2011;17:e217-22.
- Blanchette VS, Manco-Johnson M, Santagostino E, Ljung R. Optimizing factor prophylaxis for the haemophilia population. Where do we stand? *Haemophilia* 2004;10:97-104.
- Gilbert MS. Prophylaxis: Musculoskeletal evaluation. *Semin Hematol* 1993;3 Suppl 2:3-6.
- Petersson H, Ahlberg A, Nilsson IM. A radiologic classification of the haemophilic arthropathy. *Clin Orthop Relat Res* 1980;149:153-9.
- Melchiorre D, Linari S, Innocenti M, Biscoglio I, Toigo M, Cerinic MM, et al. Ultrasound detects joint damage and bleeding in haemophilic arthropathy: A proposal of a score. *Haemophilia* 2011;17:112-7.
- Jansen NW, Roosendaal G, Bijlsma JW, Degroot J, Lafeber FP. Exposure of human cartilage tissue to low concentrations of blood for a short period of time leads to prolonged cartilage damage. An in vitro study. *Arthritis Rheum* 2007;56:199-207.
- Roosendaal G, Vianen ME, Marx JJ, van den Berg HM, Lafeber FP, Bijlsma JW. Blood-induced joint damage: A human in vitro study. *Arthritis Rheum* 1999;42:1025-32.
- Roosendaal G, Vianen ME, Wenting MJ, van Rinsum AC, van den Berg HM, Lafeber FP, et al. Iron deposit and catabolic properties of synovial tissue from patients with haemophilia. *J Bone Joint Surg Br* 1998;80:540-5.
- Roosendaal G, Jansen NW, Schutgens R, Lafeber FP. Haemophilic arthropathy: The importance of the earliest haemarthroses and consequences for treatment. *Haemophilia* 2008;14 Suppl 6:4-10.
- Acharya S, Schloss R, Dyke JP, Mintz DN, Christos P, DiMichele DM, et al. Power Doppler sonography in the diagnosis of haemophilic synovitis — A promising tool. *J Thromb Haemost* 2008;6:2055-61.
- Abshire T. Unraveling haemophilic arthropathy. *Blood* 2011;117:2302-3.
- Khawaji M, Akesson K, Berntorp E. Long-term prophylaxis in

- severe haemophilia seems to preserve bone mineral density. *Haemophilia* 2009;15:261-6.
31. Haynes DR, Barg E, Crotti TN, Holding C, Weedon H, Atkins GJ, et al. Osteoprotegerin expression in synovial tissue from patients with rheumatoid arthritis, spondyloarthropathies and osteoarthritis and normal controls. *Rheumatology* 2003;42:123-34.
 32. Vega D, Maalouf NM, Sakhaee K. The role of receptor activator of nuclear factor-kB (RANK)/RANK ligand/osteoprotegerin: Clinical implications. *J Clin Endocrinol Metab* 2007;92:4514-21.
 33. Pulsatelli L, Dolzani P, Silvestri T, Caraceni P, Facchini A, Ravaglia G, et al. Soluble receptor activator of nuclear factor-kB ligand (sRANKL)/osteoprotegerin balance in ageing and age-associated diseases. *Biogerontology* 2004;5:119-27.
 34. Ziolkowska M, Kurowska M, Radzikowska A, Luszczkiewicz G, Wiland P, Dziewczopolski W, et al. High levels of osteoprotegerin and soluble receptor activator of nuclear factor-kB ligand in serum of rheumatoid arthritis patients and their normalization after anti-tumor necrosis factor treatment. *Arthritis Rheum* 2002;46:1744-53.