

Synovitis and Osteitis Are Very Frequent in Rheumatoid Arthritis Clinical Remission: Results from an MRI Study of 294 Patients in Clinical Remission or Low Disease Activity State

FRÉDÉRIQUE GANDJBAKHCH, PHILIP G. CONAGHAN, BO EBJERG, ESPEN A. HAAVARDSHOLM, VIOLAINE FOLTZ, ANDREW K. BROWN, UFFE MØLLER DØHN, MARISSA LASSERE, JANE FREESTON, PERNILLE BØYESEN, PAUL BIRD, BRUNO FAUTREL, MERETE LUND HETLAND, PAUL EMERY, PIERRE BOURGEOIS, KIM HØRSLEV-PETERSEN, TORE K. KVIEN, FIONA McQUEEN and MIKKEL ØSTERGAARD

J Rheumatol 2011;38;2039-2044
<http://www.jrheum.org/content/38/9/2039>

1. Sign up for TOCs and other alerts
<http://www.jrheum.org/alerts>
2. Information on Subscriptions
<http://jrheum.com/faq>
3. Information on permissions/orders of reprints
http://jrheum.com/reprints_permissions

The Journal of Rheumatology is a monthly international serial edited by Earl D. Silverman featuring research articles on clinical subjects from scientists working in rheumatology and related fields.

Synovitis and Osteitis Are Very Frequent in Rheumatoid Arthritis Clinical Remission: Results from an MRI Study of 294 Patients in Clinical Remission or Low Disease Activity State

FRÉDÉRIQUE GANDJBAKHCH, PHILIP G. CONAGHAN, BO EJBBERG, ESPEN A. HAAVARDSHOLM, VIOLAINE FOLTZ, ANDREW K. BROWN, UFFE MØLLER DØHN, MARISSA LASSERE, JANE FREESTON, PERNILLE BØYESEN, PAUL BIRD, BRUNO FAUTREL, MERETE LUND HETLAND, PAUL EMERY, PIERRE BOURGEOIS, KIM HØRSLEV-PETERSEN, TORE K. KVIEN, FIONA McQUEEN, and MIKKEL ØSTERGAARD

ABSTRACT Objective. In rheumatoid arthritis (RA), radiographic progression may occur despite clinical remission. This may be explained by subclinical inflammation. Magnetic resonance imaging (MRI) provides a greater sensitivity than clinical examination and radiography for assessing disease activity. Our objective was to determine the MRI characteristics of RA patients in clinical remission or low disease activity (LDA) state.

Methods. Databases from 6 cohorts were collected from 5 international centers. RA patients in clinical remission according to Disease Activity Score₂₈-C-reactive protein (DAS₂₈-CRP < 2.6; n = 213) or LDA-state (2.6 ≤ DAS₂₈-CRP < 3.2; n = 81) with available MRI data were included. MRI were assessed according to the OMERACT RA MRI scoring system (RAMRIS).

Results. Patient characteristics: 70% women, median age 55 (interquartile range, IQR 43–63) years, disease duration 2.3 (IQR 0.7–5.1) years, DAS₂₈-CRP 2.2 (IQR 1.8–2.6), Simplified Disease Activity Index, SDAI, 3.9 (IQR 1.9–6.5), Clinical Disease Activity Index, CDAI, 3.1 (IQR 1.5– 5.8), rheumatoid factor/anti-cyclic citrullinated peptide positivity 57%/54%, presence of radiographic erosions: 66%. Wrist and metacarpophalangeal MRI (MCP-MRI) data were available for 287 and 241 patients, respectively. MRI inflammatory activity in wrist and/or MCP joints was observed in the majority [synovitis: 95%, bone edema (osteitis): 35%] of patients. The median (IQR) RAMRIS score was 6 (3–9) for synovitis and 0 (0–2) for osteitis. Synovitis and osteitis were not less frequent in DAS₂₈ clinical remission (synovitis/osteitis 96%/35%) than LDA (91/36). A trend towards lower frequencies of osteitis in patients in SDAI and CDAI remission was observed.

Conclusion. Subclinical inflammation was identified by MRI in the majority of RA patients in clinical remission or LDA state. This may explain structural progression in such patients. Further work is required to understand the place of modern imaging in future remission criteria. (J Rheumatol 2011;38:2039–44; doi:10.3899/jrheum.110421)

Key Indexing Terms:

RHEUMATOID ARTHRITIS
REMISSION

MAGNETIC RESONANCE IMAGING
LOW DISEASE ACTIVITY STATE

From the Department of Rheumatology, Pitié Salpêtrière Hospital, APHP, Université Paris 6-UPMC, Paris, France; Section of Musculoskeletal Disease, University of Leeds and NIHR Leeds Musculoskeletal Biomedical Research Unit, Leeds, UK; Department of Rheumatology, Slagelse Hospital, Slagelse, Denmark; Department of Rheumatology, Diakonhjemmet Hospital, Oslo, Norway; Hull York Medical School, University of York, York, UK; Department of Rheumatology, Copenhagen University Hospitals at Hvidovre and Glostrup, Copenhagen, Denmark; St. George Hospital, University of NSW, Sydney, Australia; King Christian X's Hospital for Rheumatic Diseases, University of Southern Denmark, Graasten, Denmark; and Department of Molecular Medicine and Pathology, Faculty of Medicine and Health Sciences, University of Auckland, Auckland, New Zealand.

F. Gandjbakhch, MD, Practising Rheumatologist, Department of Rheumatology, Pitié Salpêtrière Hospital, APHP, Université Paris 6-UPMC; P.G. Conaghan, MB, BS, PhD, FRACP, FRCP, Professor of Musculoskeletal Medicine, Section of Musculoskeletal Disease, University of Leeds and NIHR Leeds Musculoskeletal Biomedical Research Unit; B. Ejbjerg, MD, PhD, Consultant Rheumatologist, Department of

Rheumatology, Slagelse Hospital; E.A. Haavardsholm, MD, PhD, Senior Registrar, Department of Rheumatology, Diakonhjemmet Hospital; V. Foltz, MD, Practising Rheumatologist, Department of Rheumatology, Pitié Salpêtrière Hospital, APHP, Université Paris 6-UPMC; A.K. Brown, MB, ChB, MRCP, PhD, Hull York Medical School, University of York; U. Møller Døhn, MD, PhD, Senior Registrar, Department of Rheumatology, Copenhagen University Hospitals at Hvidovre and Glostrup; M. Lassere, MBBS (Hons), PhD, Grad Dip Epi, FRACP, FAFPHM, Professor of Medicine, St. George Hospital, University of NSW; J. Freeston, MA, MD, MRCP, Clinical Lecturer, Section of Musculoskeletal Disease, University of Leeds and NIHR Leeds Musculoskeletal Biomedical Research Unit; P. Bøyesen, MD, PhD, Senior Registrar, Department of Rheumatology, Diakonhjemmet Hospital; P. Bird, BMed (Hons), FRACP, PhD, Grad Dip MRI, Senior Lecturer, University of NSW; B. Fautrel, MD, PhD, Associate Professor in Medicine, Department of Rheumatology, Pitié Salpêtrière Hospital, APHP, Université Paris 6-UPMC; M.L. Hetland, MD, PhD, Consultant, Senior Lecturer in Rheumatology, Department of Rheumatology, Copenhagen University Hospitals at Hvidovre and Glostrup; P. Emery,

Personal non-commercial use only. The Journal of Rheumatology Copyright © 2011. All rights reserved.

MA, MD, FRCP, ARC Professor in Rheumatology, Section of Musculoskeletal Disease, University of Leeds and NIHR Leeds Musculoskeletal Biomedical Research Unit; P. Bourgeois, MD, Professor in Rheumatology, Department of Rheumatology, Pitié Salpêtrière Hospital, APHP, Université Paris 6-UPMC; K. Hørslev-Petersen, MD, DMSc, Professor in Rheumatology, King Christian X's Hospital for Rheumatic Diseases, University of Southern Denmark; T.K. Kvien, MD, PhD, Professor of Rheumatology, Department of Rheumatology, Diakonhjemmet Hospital; F.M. McQueen, MChB, MD, FRACP, Professor of Rheumatology, Department of Molecular Medicine and Pathology, Faculty of Medicine and Health Sciences, University of Auckland; M. Østergaard, MD, PhD, DMSc, Professor of Rheumatology, Department of Rheumatology, Copenhagen University Hospitals at Hvidovre and Glostrup.

Address correspondence to Dr. Gandjbakhch;
E-mail: frederique.gandjbakhch@psl.aphp.fr

In the last few years, remission in rheumatoid arthritis (RA) has become an achievable therapeutic goal¹. It is generally defined as the absence of inflammatory activity based upon clinical criteria. Recent studies have shown that radiographic structural progression may occur despite clinical remission or low disease activity (LDA) state^{2,3,4}. Modern imaging methods such as magnetic resonance imaging (MRI) provide the potential to improve the evaluation of disease activity beyond clinical examination⁵. A recent study has demonstrated that MRI-detected “subclinical inflammation” may be present in LDA patients and is related to subsequent radiographic progression^{2,6}.

The objective of this study was to determine the MRI characteristics of patients with RA in clinical remission or LDA state.

MATERIALS AND METHODS

Patients. Anonymized databases from 6 different cohorts were collected from 5 centers (Table 1). For the purposes of this combined cohort [Outcome Measures in Rheumatology Clinical Trials (OMERACT) Rheumatoid Arthritis Acceptable Disease Activity State (ORAS) cohort], RA patients (American College of Rheumatology 1987 criteria) in clinical remission [defined as Disease Activity Score_{28-C}-reactive protein (DAS₂₈-CRP) < 2.6] or LDA state (defined as $2.6 \leq \text{DAS}_{28}\text{-CRP} < 3.2$) with available MRI data were included. Patients could be treated by disease-modifying antirheumatic drugs and/or biologics. Clinical data [age, sex, disease duration in years, treatment, tender joint count, swollen joint count, patient visual analog scale (VAS) global assessment, physician VAS global assessment] and laboratory tests (erythrocyte sedimentation rate, CRP, rheumatoid factor, anti-cyclic citrullinated peptide antibody status) at baseline were collected. DAS₂₈-CRP, the Clinical Disease Activity Index (CDAI), the Simplified Disease Activity Index (SDAI), proportions of patients in clinical remission ($\text{DAS}_{28} < 2.6$, $\text{CDAI} \leq 2.8$, $\text{SDAI} \leq 3.3$), and LDA state ($2.6 \leq \text{DAS}_{28} < 3.2$, $2.8 < \text{CDAI} \leq 10$, $3.3 < \text{SDAI} \leq 11$) for the different composite indices were calculated.

MRI acquisition and scoring. An overview of MRI acquisition data in the different cohorts is provided in Table 1. MRI of unilateral wrist and/or metacarpophalangeal (MCP) joints 2–5 was acquired. Synovitis, erosion, and osteitis were defined and scored semiquantitatively according to the OMERACT RAMRIS^{7,8,9,10,11}. By adding scores from the individual joint regions, MRI sum scores for synovitis (wrist: 0–9/MCP: 0–12/wrist+MCP: 0–21), osteitis (0–45/0–24/0–69), and bone erosion (0–150/0–80/0–230) were calculated.

Statistical analyses. A single database was compiled from the individual cohort data. Data were then analyzed using SAS software, version 9.1. Descriptive statistics and nonparametric tests were used.

RESULTS

Patient characteristics. Included in the study were 294 RA patients, of which 213 were in clinical remission and 81 in LDA state. Patient characteristics are summarized in Table 2. Thirty-nine percent of patients had a disease duration less than 1 year. Clinical disease activity was low, with median (IQR) DAS₂₈-CRP 2.2 (1.8–2.6) (n = 294), SDAI 3.9 (1.9–6.5) (n = 188), and CDAI 3.1 (1.5–5.8) (n = 188). According to DAS₂₈-CRP, 72% and 28% of these patients were in remission and LDA state, respectively. SDAI and CDAI definitions of remission appeared more stringent: Of the 188 patients with data available for calculating both DAS₂₈-CRP, CDAI, and SDAI indices, 75%, 47%, and 45% of the patients were in remission and 25%, 49%, and 52% were in LDA but not remission according to DAS₂₈-CRP, CDAI, and SDAI, respectively. Four percent and 3% of the patients were in neither LDA nor remission according to CDAI and SDAI, respectively.

MRI findings. Wrist and MCP-joint MRI data were available for 287 patients and 241 patients, respectively. MRI inflammatory activity was observed in the majority of patients, as synovitis and osteitis were observed in wrist and/or MCP joints in 95% and 35% of the patients, respectively (Table 3). Figure 1 illustrates the frequency of synovitis and osteitis in wrist and MCP joints in patients in clinical remission. The median (IQR) RAMRIS score (total wrist and MCP) for synovitis was 6 (3–9) and for osteitis was 0 (0–2). Synovitis and osteitis were more commonly observed in the wrist (90% and 31%) than MCP (81% and 16%) joints. The second MCP joint was the most frequently involved MCP joint for both synovitis and osteitis (Table 3). Bone erosion was present in 90% of the patients and more frequently observed in wrist (89%) than in MCP (60%) (Table 3).

No difference was observed between MRI characteristics of patients in clinical remission or LDA, regardless of DAS₂₈-CRP (Table 3), CDAI, or SDAI definitions. While no difference was observed for MRI synovitis with regard to the different remission criteria, a tendency for lower frequencies of osteitis was observed when SDAI/CDAI criteria, as compared to DAS₂₈ criteria, were used (Table 4).

Patients with early RA had significantly lower RAMRIS osteitis and erosion scores than those with established RA: the median (IQR) RAMRIS osteitis score was 0 (0–0) for early RA versus 0 (0–2) for established RA (p < 0.001; Figure 2) and the RAMRIS erosion score 2 (0–5) for early RA versus 11 (7–19) for established RA (p < 0.0001). No differences in synovitis scores were observed.

DISCUSSION

Clinical remission and LDA are considered realistic therapeutic targets in RA, and treatment should be adjusted if these targets are not achieved in individual patients¹. Assessments from imaging modalities are currently not part of the criteria for remission and LDA, which are currently defined solely according to clinical criteria. The present data from multiple

Table 1. Characteristics of the individual studies.

Center	Cohort	No. Patients, n = 294	MRI Equipment	Field Strength (Tesla)	Joints	Side	MRI Sequences	Scoring System
Copenhagen	HURRAH	21	Philips Panorama	0.6	Wrist, MCP	Hand with erosion	T1 pre gad without FS (cor, axial), T1 FS post gad (axial), STIR (cor)	RAMRIS
Copenhagen	CIMESTRA	84	Esaote C-scan, Siemens Impact, Siemens Vision	0.2–1.5	Wrist, MCP	Nondominant	T1 pre gad without FS (cor, axial), T1 post gad without FS (cor, axial), STIR (cor)	RAMRIS
Leeds	REMISSION	81	Philips, Gyroscan	1.5	Wrist, MCP	Dominant	T1 and T1 spectral presaturation with inversion recovery post gad (cor, axial)	RAMRIS
Oslo	ERA	23	General Electric Signa	1.5	Wrist	Dominant	T1 pre gad without FS (cor, axial) T1 post gad without and with FS (cor, axial), STIR (cor), 3D-SPGR	RAMRIS
Paris	LAFRAME	78	Esaote C-scan	0.2	Wrist, MCP	Dominant	3D T1 without FS pre gad (cor, axial), 3D T1 without FS post gad (cor, axial), STIR (cor, axial)	RAMRIS
Sydney	TASRA	7	Siemens	1.5	MCP	Dominant	T1 SE pre gad (cor), T1 SE post gad (cor, axial), T2 TSE (axial), STIR (cor)	RAMRIS

Cor: coronal, Gad: gadolinium, FS: fat saturation, MCP: metacarpophalangeal, SE: spin echo, STIR: short-tau inversion recovery, T1: T1-weighted, 3D-SPGR: 3-dimensional spoiled gradient echo.

Table 2. Characteristics of the patients.

Patient Variable Assessed	No. Patients with Available Data	
Age, median yrs (IQR)	55 (43–63)	294
Disease duration, median yrs (IQR)	2.3 (0.7–5.1)	294
Early RA (< 1 year), %	(39)	294
Female, %	(70)	282
Rheumatoid factor-positive, %	(57)	294
Anti-CCP-positive, %	(54)	185
Erosive on radiography, %	(66)	290
DMARD, %	(99)	282
Biologics, %	(15)	287
Oral corticosteroids, %	(25)	203
DAS28-CRP, median (IQR)	2.2 (1.8–2.6)	294
SDAI, median (IQR)	3.9 (1.9–6.5)	188
CDAI, median (IQR)	3.1 (1.5–5.8)	188

Anti-CCP: anti-cyclic citullinated peptide antibodies; IQR: interquartile range; SDAI: Simplified Disease Activity Index; CDAI: Clinical Disease Activity Index.

cohorts demonstrate clearly that MRI inflammation is frequent both in patients in clinical remission and in patients in LDA state. Inflammatory activity was observed in the majority of patients, with synovitis and osteitis in wrist and/or MCP joints in 95% and 35% of the patients, respectively. These results confirm, in a much larger cohort, the results previously reported from one of the included studies⁶.

MRI showed no significant difference in signs of inflammation when patients in clinical remission were compared with patients with LDA without remission, whatever the criteria used (DAS28, CDAI, SDAI). A tendency towards lower frequencies of MRI osteitis in patients in remission according to SDAI or CDAI compared to DAS28 was observed in both wrist and MCP joints, whereas no difference in frequencies of synovitis was observed whatever the remission criteria employed. SDAI and CDAI remission criteria are often considered more stringent than DAS28 remission criteria, and the observed tendency towards less osteitis in patients in SDAI/CDAI remission supports this notion. The available data also suggest that MRI could be a useful external reference method for different clinical remission criteria.

Osteitis and bone erosion, but not synovitis, were observed less frequently in patients with early RA compared to those with established RA. As osteitis is known to be an independent predictor of subsequent bone erosion^{12,13,14}, one could speculate that clinical remission in established RA is associated with a higher risk of subsequent erosive progression than clinical remission in early RA. However, longitudinal studies of clinical, MRI, and radiographic data are needed to clarify the relative importance of the observed findings.

Recent studies have demonstrated that progression of joint damage may occur in patients in clinical remission^{2,3,4}. Subclinical MRI inflammation may contribute to structural

Table 3. MRI characteristics of patients in clinical remission or low disease activity state according to Disease Activity Score 28-C-reactive protein (DAS28-CRP). No statistically significant differences were observed for presence (Fisher's exact test) or score (Mann-Whitney U test) of any MRI feature.

MRI Feature	Location	All Patients, n = 294		Remission (DAS28-CRP < 2.6), n = 213		LDA (2.6 ≤ DAS28-CRP < 3.2), n = 81	
		Presence*, n (%)	Score Median (IQR)	Presence*, n (%)	Score Median (IQR)	Presence*, n (%)	Score Median (IQR)
Synovitis							
Wrist/MCP	Total	208 (95)	6 (3–9)	156 (96)	5 (3–9)	52 (91)	7 (2–9)
Wrist	Total	240 (90)	3 (2–4)	174 (90)	3 (2–4)	66 (90)	3 (2–5)
	Distal radioulnar	155 (58)	1 (0–2)	110 (56)	1 (0–1)	45 (62)	1 (0–2)
	Radiocarpal	220 (82)	1 (1–2)	158 (81)	1 (1–2)	62 (83)	1 (1–2)
	ICCM	199 (73)	1 (0–2)	143 (73)	1 (0–2)	56 (75)	1 (0–2)
MCP	Total	192 (81)	3 (1–5)	141 (82)	2 (1–5)	51 (78)	3 (1–5)
	MCP2	156 (66)	1 (0–2)	116 (67)	1 (0–2)	40 (61)	1 (0–2)
	MCP 3	137 (57)	1 (0–1)	98 (57)	1 (0–1)	39 (58)	1 (0–2)
	MCP 4	110 (46)	0 (0–1)	77 (44)	0 (0–1)	33 (52)	1 (0–1)
	MCP 5	97 (41)	0 (0–1)	72 (41)	0 (0–1)	25 (41)	0 (0–1)
Osteitis							
Wrist/MCP	Total	78 (35)	0 (0–2)	57 (35)	0 (0–2)	21 (36)	0 (0–2)
Wrist	Total	84 (31)	0 (0–1)	59 (30)	0 (0–1)	25 (33)	0 (0–2)
MCP	Total	44 (16)	0 (0–0)	29 (16)	0 (0–0)	15 (19)	0 (0–0)
	MCP 2	29 (10)	0 (0–0)	19 (10)	0 (0–0)	10 (11)	0 (0–0)
	MCP 3	15 (5)	0 (0–0)	10 (5)	0 (0–0)	5 (5)	0 (0–0)
	MCP 4	6 (1.3)	0 (0–0)	5 (1.2)	0 (0–0)	1 (1.6)	0 (0–0)
	MCP 5	14 (5)	0 (0–0)	9 (5)	0 (0–0)	5 (6)	0 (0–0)
Erosion							
Wrist/MCP	Total	203 (90)	7 (3–15)	155 (92)	8 (3.5–16)	48 (84)	7 (2–13)
Wrist	Total	244 (89)	5 (2–10)	182 (91)	6 (2–10)	62 (83)	4 (1–10)
MCP	Total	142 (60)	1 (0–4)	108 (63)	1 (0–4)	34 (54)	1 (0–3)
	MCP 2	99 (42)	0 (0–1)	77 (45)	0 (0–1)	22 (35)	0 (0–1)
	MCP 3	94 (40)	0 (0–1)	74 (43)	0 (0–1)	20 (32)	0 (0–1)
	MCP 4	54 (23)	0 (0–0)	38 (22)	0 (0–0)	16 (25)	0 (0–0)
	MCP 5	73 (31)	0 (0–1)	56 (33)	0 (0–1)	17 (27)	0 (0–0)

* Presence: number (n) and proportion (%) of patients with the specified pathology in at least one of the indicated joints. MCP: metacarpophalangeal joint; ICCM: intercarpal-carpometacarpal.

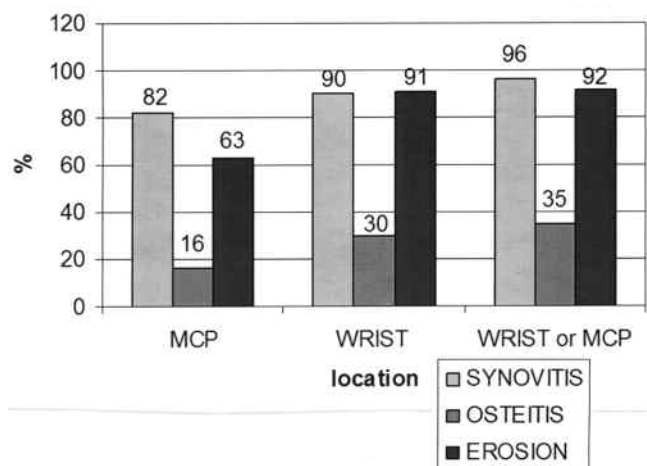


Figure 1. Frequencies of synovitis, osteitis, and bone erosion in patients with clinical remission (Disease Activity Score 28 < 2.6).

progression, and further multivariate analyses of longitudinal data are required to determine the strongest predictive factors in these patients fulfilling criteria for remission. The aim would be to determine an MRI-acceptable inflammatory disease activity state, where structural progression will not occur.

Our study presents some limitations. Patients from different cohorts having different study designs and using different MRI units were included. To homogenize the data analyzed in the study, DAS28-CRP, CDAI, and SDAI were recalculated based on the raw clinical data from the original cohorts. The original MRI assessments from the individual cohorts were used in the analyses, as re-reading of all MRI data was not feasible due to the high number of examinations. Nevertheless, most of the readers had previously participated in RAMRIS multireader exercises, which showed satisfactory interreader reliability.

In summary, MRI identified inflammatory activity in the

Table 4. MRI synovitis and osteitis in RA patients fulfilling different clinical remission criteria (n = 188).

	Wrist, n = 188			MCP, n = 188			Wrist and/or MCP, n = 188		
	DAS28 < 2.6, n = 141	SDAI ≤ 3.3, n = 84	CDAI ≤ 2.8 n = 88	DAS28 < 2.6, n = 141	SDAI ≤ 3.3, n = 84	CDAI ≤ 2.8, n = 88	DAS28 < 2.6, n = 141	SDAI ≤ 3.3, n = 84	CDAI ≤ 2.8 n = 88
Synovitis									
Presence*, %	90	88	90	80	69	72	97	95	97
RAMRIS score, median (IQR)	2 (2–4)	2 (2–4)	2 (2–4)	2 (1–4)	1 (0–3)	1 (0–3)	4 (3–7)	3 (2–6)	4 (2–7)
Osteitis									
Presence*, %	32	24	23	13	8	8	36	25	27
RAMRIS score, median (IQR)	0 (0–1)	0 (0–0)	0 (0–0)	0 (0–0)	0 (0–0)	0 (0–0)	0 (0–1)	0 (0–1)	0 (0–1)

* Presence: proportion of patients presenting the specified pathology in at least one of the indicated joints.

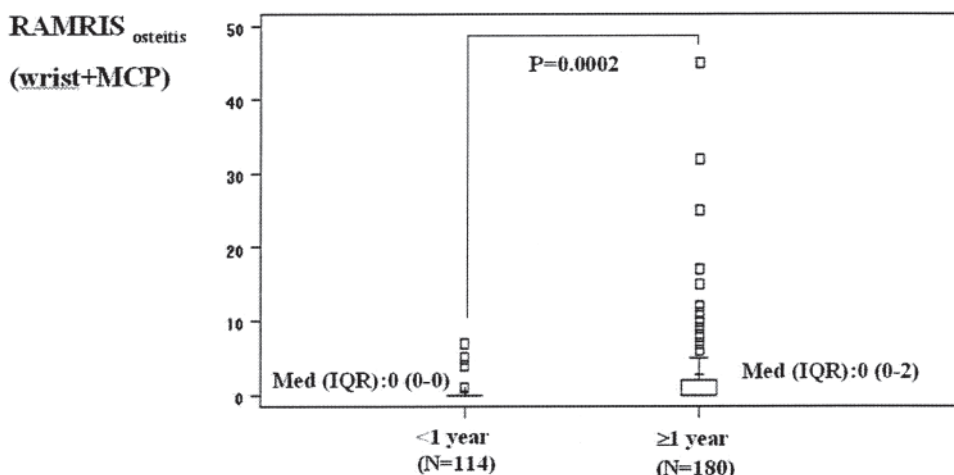


Figure 2. Magnetic resonance imaging (MRI) osteitis in patients with early RA and late RA in clinical remission or low disease activity state. MCP: metacarpophalangeal joint; RAMRIS: Rheumatoid Arthritis MRI scoring system.

majority of patients in clinical remission or LDA state. MRI showed no differences between patients in clinical remission and LDA, despite a tendency to lower osteitis scores in patients in CDAI and SDAI remission. Further work is required to understand the place of modern imaging in future remission criteria.

ACKNOWLEDGMENT

Physicians, study nurses, and patients who have contributed to the described RA cohorts are acknowledged for their contributions.

REFERENCES

- Smolen JS, Landewe R, Breedveld FC, Dougados M, Emery P, Gaujoux-Viala C, et al. EULAR recommendations for the management of rheumatoid arthritis with synthetic and biological disease-modifying antirheumatic drugs. *Ann Rheum Dis* 2008;69:964-75.
- Brown AK, Conaghan PG, Karim Z, Quinn MA, Ikeda K, Peterfy CG, et al. An explanation for the apparent dissociation between clinical remission and continued structural deterioration in rheumatoid arthritis. *Arthritis Rheum* 2008;58:2958-67.
- Molenaar ET, Voskuyl AE, Dinant HJ, Bezemer PD, Boers M, Dijkmans BA. Progression of radiologic damage in patients with

- rheumatoid arthritis in clinical remission. *Arthritis Rheum* 2004;50:36-42.
- Rau R. Is remission in rheumatoid arthritis associated with radiographic healing? *Clin Exp Rheumatol* 2006;24 Suppl 43:S-41-4.
- Backhaus M, Burmester GR, Sandrock D, Loreck D, Hess D, Scholz A, et al. Prospective two year follow up study comparing novel and conventional imaging procedures in patients with arthritic finger joints. *Ann Rheum Dis* 2002;61:895-904.
- Brown AK, Quinn MA, Karim Z, Conaghan PG, Peterfy CG, Hensor E, et al. Presence of significant synovitis in rheumatoid arthritis patients with disease-modifying antirheumatic drug-induced clinical remission: evidence from an imaging study may explain structural progression. *Arthritis Rheum* 2006;54:3761-73.
- Østergaard M, Peterfy C, Conaghan P, McQueen F, Bird P, Ejbjerg B, et al. OMERACT rheumatoid arthritis magnetic resonance imaging studies. Core set of MRI acquisitions, joint pathology definitions, and the OMERACT RA-MRI scoring system. *J Rheumatol* 2003;30:1385-6.
- Ejbjerg B, McQueen F, Lassere M, Haavardsholm E, Conaghan P, O'Connor P, et al. The EULAR-OMERACT rheumatoid arthritis MRI reference image atlas: the wrist joint. *Ann Rheum Dis* 2005;64 Suppl 1:i23-47.

9. Conaghan P, Bird P, Ejbjerg B, O'Connor P, Peterfy C, McQueen F, et al. The EULAR-OMERACT rheumatoid arthritis MRI reference image atlas: the metacarpophalangeal joints. *Ann Rheum Dis* 2005;64 Suppl 1:i11-21.
10. Bird P, Conaghan P, Ejbjerg B, McQueen F, Lassere M, Peterfy C, et al. The development of the EULAR-OMERACT rheumatoid arthritis MRI reference image atlas. *Ann Rheum Dis* 2005;64 Suppl 1:i8-10.
11. Østergaard M, Edmonds J, McQueen F, Peterfy C, Lassere M, Ejbjerg B, et al. An introduction to the EULAR-OMERACT rheumatoid arthritis MRI reference image atlas. *Ann Rheum Dis* 2005;64 Suppl 1:i3-7.
12. Hetland ML, Ejbjerg BJ, Hørslev-Petersen K, Jacobsen S, Vestergaard A, Jurik AG, et al. MRI bone oedema is the strongest predictor of subsequent radiographic progression in early rheumatoid arthritis. Results from a 2 year randomized controlled trial (CIMESTRA). *Ann Rheum Dis* 2009;68:384-90.
13. McQueen FM, Stewart N, Crabbe J, Robinson E, Yeoman S, Tan PL, et al. Magnetic resonance imaging of the wrist in early rheumatoid arthritis reveals progression of erosions despite clinical improvement. *Ann Rheum Dis* 1999;58:156-63.
14. Haavardsholm EA, Bøyesen P, Østergaard M, Schildvold A, Kvien TK. Magnetic resonance imaging findings in 84 patients with early rheumatoid arthritis: bone marrow oedema predicts erosive progression. *Ann Rheum Dis* 2008;67:794-800.