

Patterns of Magnetic Resonance Imaging Bone Erosion in Rheumatoid Arthritis — Which Bones Are Most Frequently Involved and Show the Most Change?

MIKKEL ØSTERGAARD, UFFE MØLLER DØHN, ANNE DUER-JENSEN, MERETE LUND HETLAND, KIM HØRSLEV-PETERSEN, KRISTIAN STENGAARD-PEDERSEN, PETER JUNKER, JAN PØDENPHANT and BO EBJJERG

J Rheumatol 2011;38;2014-2017  
<http://www.jrheum.org/content/38/9/2014>

1. Sign up for TOCs and other alerts  
<http://www.jrheum.org/alerts>
2. Information on Subscriptions  
<http://jrheum.com/faq>
3. Information on permissions/orders of reprints  
[http://jrheum.com/reprints\\_permissions](http://jrheum.com/reprints_permissions)

*The Journal of Rheumatology* is a monthly international serial edited by Earl D. Silverman featuring research articles on clinical subjects from scientists working in rheumatology and related fields.

# Patterns of Magnetic Resonance Imaging Bone Erosion in Rheumatoid Arthritis — Which Bones Are Most Frequently Involved and Show the Most Change?

MIKKEL ØSTERGAARD, UFFE MØLLER DØHN, ANNE DUER-JENSEN, MERETE LUND HETLAND, KIM HØRSLEV-PETERSEN, KRISTIAN STENGAARD-PEDERSEN, PETER JUNKER, JAN PØDENPHANT, and BO EBJJERG

**ABSTRACT. Objective.** To investigate by magnetic resonance imaging (MRI) which bones in wrists and metacarpophalangeal (MCP) joints most frequently show bone erosions, and which most frequently demonstrate erosive progression, in early and established rheumatoid arthritis (RA).

**Methods.** MRI datasets from 258 RA patients [126 with early RA (disease duration < 6 months)] were analyzed, of whom 223, including 126 with early RA, had 1-year followup MRI. All patients had MRI of one wrist, whereas 86 patients had additional images of 2nd–5th MCP joints, and 46 patients additional images of the contralateral wrist. MRI were evaluated blinded by one reader, according to the OMERACT RA MRI scoring system (RAMRIS) for erosions, and presence/absence of erosions was noted in each bone, as was presence/absence of erosive progression.

**Results.** The capitate, ulna, lunate, triquetrum, and scaphoid were the 5 bones with both most frequent baseline erosions and most frequently demonstrated erosive progression. No bones were without erosions. Patterns of erosions and progression were similar in early and established RA. No major difference between dominant and nondominant wrists was detected. In the fingers, the 2nd–3rd MCP joint most frequently displayed erosions and erosive progression.

**Conclusion.** The distribution and frequency of bone erosion and erosive progression as detected by MRI in RA wrists and MCP joints were identified. No pattern differences between early versus established disease and dominant versus nondominant sides were detected. No bones showed erosive progression. Thus, no self-evident simplification of the RAMRIS erosion score was identified. Bone involvement patterns may be considered, when joints are selected for MRI protocols for clinical trials and practice. (J Rheumatol 2011;38:2014–17; doi:10.3899/jrheum.110416)

## Key Indexing Terms:

RHEUMATOID ARTHRITIS  
WRIST

MAGNETIC RESONANCE IMAGING

BONE EROSION

METACARPOPHALANGEAL JOINT

From the Department of Rheumatology and Department of Radiology, Copenhagen University Hospital at Glostrup, Copenhagen; King Christian X's Hospital for Rheumatic Diseases, University of Southern Denmark, Graasten; Department of Rheumatology, Århus University Hospital, Århus; Department of Rheumatology, Odense Hospital, University of Southern Denmark, Odense; Department of Rheumatology, Copenhagen University Hospital at Gentofte, Copenhagen; Department of Internal Medicine, Copenhagen University Hospital at Herlev, Copenhagen; and Department of Rheumatology, Slagelse Hospital, Slagelse, Denmark.

M. Østergaard, MD, PhD, DMSc, Professor of Rheumatology, Department of Rheumatology, Copenhagen University Hospital; U. Møller Døhn, MD, PhD, Senior Registrar, Department of Rheumatology; A. Duer-Jensen, MD, PhD, Registrar, Department of Radiology; M.L. Hetland, MD, PhD, DMSc, Consultant and Senior Lecturer in Rheumatology, Department of Rheumatology, Copenhagen University Hospitals at Glostrup; K. Hørslev-Petersen, MD, DMSc, Professor in Rheumatology, King Christian X's Hospital for Rheumatic Diseases, University of Southern Denmark; K. Stengaard-Pedersen, MD, DMSc, Professor of Rheumatology, Department of Rheumatology, Århus University Hospital; P. Junker, MD, DMSc, Professor of Rheumatology, Department of Rheumatology, Odense Hospital, University of Southern Denmark; J. Pødenphant, Consultant and Senior Lecturer in Rheumatology, Department of Rheumatology, Copenhagen University Hospital at Gentofte; B. Ejjbjerg, MD, PhD, Consultant Rheumatologist, Department of Rheumatology, Slagelse Hospital.

Address correspondence to Dr. Østergaard; E-mail: mo@dadlnet.dk

Magnetic resonance imaging (MRI) has been shown to be more sensitive for identifying early bone damage than conventional radiography<sup>1,2,3,4</sup>, and is increasingly used as an outcome measure of structural joint damage in rheumatoid arthritis (RA) clinical trials<sup>5,6,7,8</sup>. MRI of unilateral wrist and 2nd–5th metacarpophalangeal (MCP) joints is more sensitive to change for erosive progression than radiography of both hands, wrists and forefeet<sup>9</sup>. However, data on the exact distribution of bone erosions, i.e., the pattern of bone involvement, are minimal.

The aim of this study was to investigate which bones in wrists and MCP joints most frequently show bone erosions and which most frequently demonstrate erosive progression in early and established RA.

## MATERIALS AND METHODS

MRI datasets from 258 RA patients [126 with early RA (disease duration < 6 months)] were analyzed. One-year followup MRI were available in 223 patients (126 with early RA). All patients had MRI of one wrist, whereas 86 had additional MCP joint MR images and 46 additional images of the contralateral wrist. The MRI data originated from 5 investigator-initiated clinical

studies<sup>9,10,11,12,13,14</sup>, in which details on population characteristics and MRI techniques are described.

MRI (including T1-weighted images in coronal and axial planes) were evaluated for bone erosions according to the OMERACT RA MRI scoring system (RAMRIS), i.e., an erosion was defined as a sharply margined bone lesion, with correct juxtaarticular localization and typical signal characteristics, visible in 2 planes, with a cortical break seen in at least one plane<sup>5</sup>.

Presence/absence of erosions at baseline was noted in each bone, as was presence/absence of erosive progression. All images were read blinded by the same reader (BE), who has extensive experience in reading MRI of RA

patients and has demonstrated high levels of intra- and interobserver reproducibility<sup>6,9</sup>.

## RESULTS

The distribution of baseline erosions per wrist bone is shown in Figure 1A, whereas the distribution of bones with progression at Year 1 is seen in Figure 1B. The capitate, ulna, lunate, triquetrum, and scaphoid were the 5 bones most frequently demonstrating both baseline erosions and erosive progression.

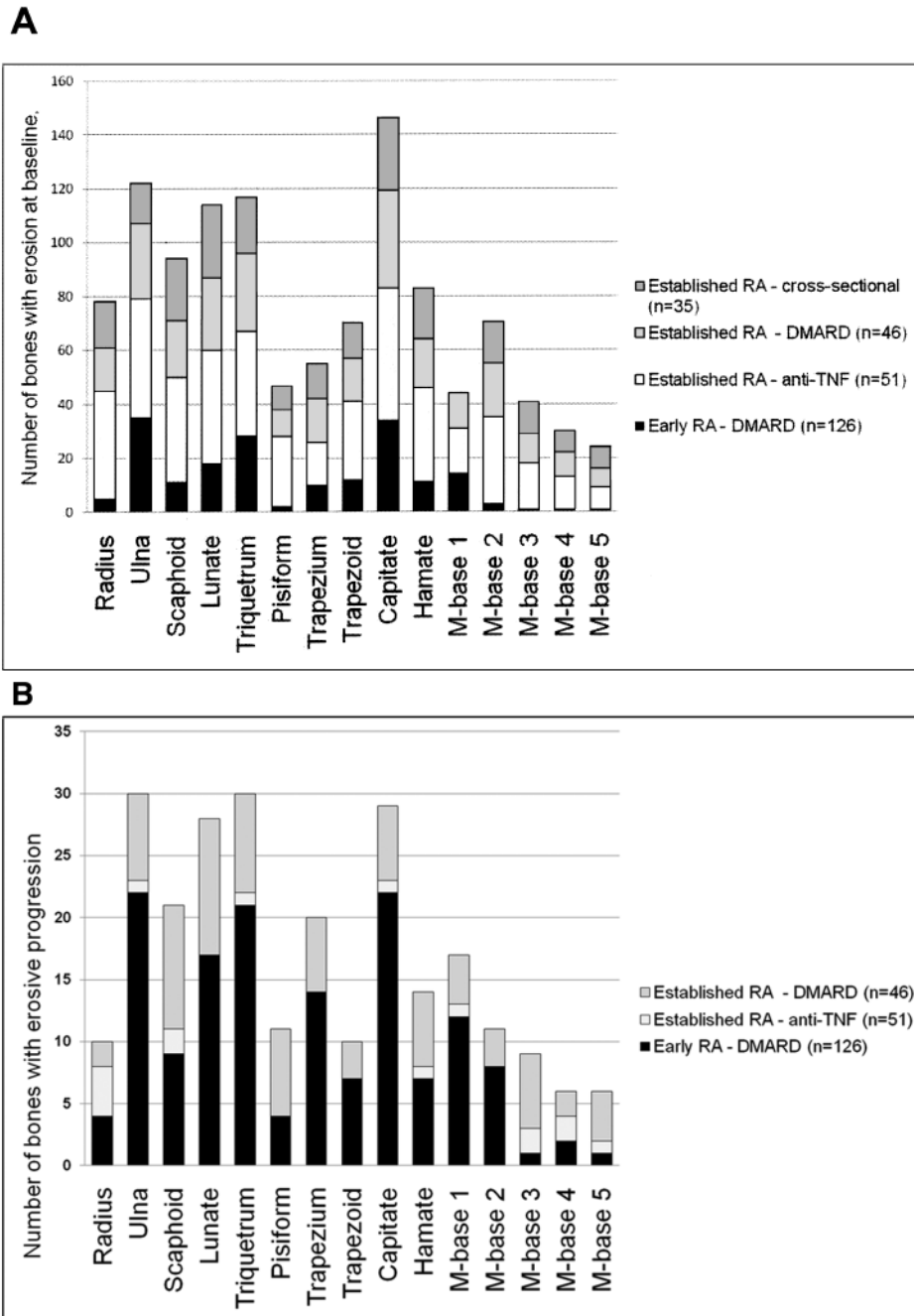


Figure 1. A. Number of bones with bone erosion, per bone (n = 258). B. Number of bones with erosive progression, per bone (n = 233).

Patterns were similar in early and in established RA. No bones were without erosions. In patients with available bilateral wrist MRI, no major differences between dominant and non-dominant hands were found (269 vs 277 bones with baseline erosions; 73 vs 85 bones with erosive progression).

In the patients in whom both wrist and MCP joint images were available, baseline erosions were still most frequently found in the 5 previously mentioned wrist bones, whereas the head of the 2nd metacarpal bone was the most frequently involved MCP joint bone. Second and 3rd MCP joints most frequently showed erosive progression.

## DISCUSSION

Our study documents the frequency and distribution of the presence and progression of MRI bone erosions in a large number of RA patients from different populations. Based on data from 258 RA patients, patterns of MRI bone erosion in wrists and MCP joints could be identified. The capitate, ulna, lunate, triquetrum, and scaphoid were most frequently involved and showed, together with the 2nd and 3rd MCP joints, the most change over time. No obvious differences in erosive patterns between early and established RA, or between dominant and nondominant wrists, were identified.

The images were obtained and scored in agreement with the OMERACT RAMRIS. This method has been extensively validated and is now the standard MRI method in RA clinical trials<sup>5,6,7,8</sup>. Comparisons with computed tomography as a “gold standard” reference for bony destruction have demonstrated a very high level of agreement and, consequently, confirmed that MRI bone erosions are true erosions<sup>15,16,17</sup>. MRI has been documented to be more sensitive to change in erosive joint damage than radiography of both hands, wrists, and forefeet, as evaluated by the Sharp-van der Heijde method<sup>8,9</sup>. The present study did not include assessment of interobserver reliability, but all images were read by the same experienced reader (BE).

This MRI study of 258 RA patients demonstrated the distribution of erosions and erosive progression in wrist and MCP joints. No pattern differences between early versus established disease and dominant versus nondominant sides were detected. No bones ever showed erosive progression. Thus, no evident reductions in the number of bones to be assessed for erosions could be identified. Future studies should test whether the RAMRIS erosion score can be simplified to include only the most frequently involved areas (capitate, ulna, lunate, triquetrum, and scaphoid and the 2nd–3rd MCP joint) without losing sensitivity to change. Bone involvement patterns may be considered when joints are selected for MRI protocols for clinical trials and practice.

## ACKNOWLEDGMENT

Physicians, study nurses, and patients who took part in the RA cohorts are acknowledged for their contributions.

## REFERENCES

1. McQueen FM, Stewart N, Crabbe J, Robinson E, Yeoman S, Tan PLJ, et al. Magnetic resonance imaging of the wrist in early rheumatoid arthritis reveals progression of erosions despite clinical improvement. *Ann Rheum Dis* 1999;58:156-63.
2. Klarlund M, Østergaard M, Jensen KE, Madsen JL, Skjødt H, the TIRA group. Magnetic resonance imaging, radiography, and scintigraphy of the finger joints: one year follow up of patients with early arthritis. *Ann Rheum Dis* 2000;59:521-8.
3. Quinn MA, Conaghan PG, O'Connor PJ, Karim Z, Greenstein A, Brown A, et al. Very early treatment with infliximab in addition to methotrexate in early, poor-prognosis rheumatoid arthritis reduces magnetic resonance imaging evidence of synovitis and damage, with sustained benefit after infliximab withdrawal: results from a twelve-month randomized, double-blind, placebo-controlled trial. *Arthritis Rheum* 2005;52:27-35.
4. Ejbjerg BJ, Vestergaard A, Jacobsen S, Thomsen H, Østergaard M. Conventional radiography requires a MRI-estimated bone volume loss of 20% to 30% to allow certain detection of bone erosions in rheumatoid arthritis metacarpophalangeal joints. *Arthritis Res Ther* 2006;8:R59.
5. Østergaard M, Peterfy C, Conaghan P, McQueen F, Bird P, Ejbjerg B, et al. OMERACT Rheumatoid Arthritis Magnetic Resonance Imaging Studies. Core set of MRI acquisitions, joint pathology definitions, and the OMERACT RA-MRI scoring system. *J Rheumatol* 2003;30:1385-6.
6. Haavardsholm EA, Østergaard M, Ejbjerg BJ, Kvan NP, Uhlig TA, Lilleas FG, et al. Reliability and sensitivity to change of the OMERACT rheumatoid arthritis magnetic resonance imaging score in a multireader, longitudinal setting. *Arthritis Rheum* 2005;52:3860-7.
7. Cohen SB, Dore RK, Lane NE, Ory PA, Peterfy CG, Sharp JT, et al. Denosumab treatment effects on structural damage, bone mineral density, and bone turnover in rheumatoid arthritis: a twelve-month, multicenter, randomized, double-blind, placebo-controlled, phase II clinical trial. *Arthritis Rheum* 2008;58:1299-309.
8. Østergaard M, Emery P, Conaghan PG, Fleischmann R, Xu W, Hsia EC, et al. Golimumab and methotrexate combination therapy significantly improves synovitis, osteitis and bone erosion compared to methotrexate alone — a magnetic resonance imaging study of 318 methotrexate-naïve rheumatoid arthritis patients [abstract]. *Arthritis Rheum* 2011;62 Suppl:S952.
9. Ejbjerg BJ, Vestergaard A, Jacobsen S, Thomsen HS, Østergaard M. The smallest detectable difference and sensitivity to change of magnetic resonance imaging and radiographic scoring of structural joint damage in rheumatoid arthritis finger, wrist, and toe joints: a comparison of the OMERACT rheumatoid arthritis magnetic resonance imaging score applied to different joint combinations and the Sharp/van der Heijde radiographic score. *Arthritis Rheum* 2005;52:2300-6.
10. Hetland ML, Stengaard-Pedersen K, Junker P, Lottenburger T, Ellingsen T, Andersen LS, et al. Combination treatment with methotrexate, cyclosporine, and intraarticular betamethasone compared with methotrexate and intraarticular betamethasone in early active rheumatoid arthritis: an investigator-initiated, multicenter, randomized, double-blind, parallel-group, placebo-controlled study. *Arthritis Rheum* 2006;54:1401-9.
11. Hetland ML, Stengaard-Pedersen K, Junker P, Østergaard M, Ejbjerg BJ, Jacobsen S, et al. Radiographic progression and remission rates in early rheumatoid arthritis — MRI bone oedema and anti-CCP predicted radiographic progression in the 5-year extension of the double-blind randomised CIMESTR trial. *Ann Rheum Dis* 2010;69:1789-95.

12. Duer-Jensen A, Vestergaard A, Døhn UM, Ejbjerg B, Hetland ML, Albrecht-Beste E, et al. Detection of rheumatoid arthritis bone erosions by two different dedicated extremity MRI units and conventional radiography. *Ann Rheum Dis* 2008;67:998-1003.
13. Duer-Jensen A, Ejbjerg B, Albrecht-Beste E, Vestergaard A, Dohn UM, Hetland ML, et al. Does low-field dedicated extremity MRI (E-MRI) reliably detect bone erosions in rheumatoid arthritis? A comparison of two different E-MRI units and conventional radiography with high-resolution CT scanning. *Ann Rheum Dis* 2009;68:1296-302.
14. Dohn UM, Ejbjerg B, Boonen A, Hetland ML, Hansen MS, Knudsen LS, et al. No overall progression and occasional repair of erosions despite persistent inflammation in adalimumab-treated rheumatoid arthritis patients: results from a longitudinal comparative MRI, ultrasonography, CT and radiography study. *Ann Rheum Dis* 2011;70:252-8.
15. Døhn UM, Ejbjerg BJ, Court-Payen M, Hasselquist M, Narvestad E, Szkudlarek M, et al. Are bone erosions detected by magnetic resonance imaging and ultrasonography true erosions? A comparison with computed tomography in rheumatoid arthritis metacarpophalangeal joints. *Arthritis Res Ther* 2006;8:R110.
16. Døhn UM, Ejbjerg BJ, Hasselquist M, Narvestad E, Court-Payen, Szkudlarek M, et al. Rheumatoid arthritis bone erosion volumes on CT and MRI: reliability and correlations with erosion scores on CT, MRI and radiography. *Ann Rheum Dis* 2007;66:1388-92.
17. Døhn UM, Ejbjerg BJ, Hasselquist M, Narvestad E, Møller J, Thomsen HS, et al. Detection of bone erosions in rheumatoid arthritis wrist joints with magnetic resonance imaging, computed tomography and radiography. *Arthritis Res Ther* 2008;10:R25.