

Heterotopic Ossification of the Temporomandibular Joint in Juvenile Idiopathic Arthritis

SARAH RINGOLD, MAHESH THAPA, ELIZABETH A. SHAW, and CAROL A. WALLACE

ABSTRACT. Objective. To describe the clinical, laboratory, pathologic, and radiographic imaging characteristics of a series of children with juvenile idiopathic arthritis (JIA) and radiographic imaging evidence of heterotopic ossification of their temporomandibular joint (TMJ).

Methods. Children were identified through search of an administrative database of imaging results at Seattle Children's Hospital. Retrospective chart review was performed to collect data on each patient's clinical and laboratory characteristics, systemic therapies, timing and number of TMJ intraarticular corticosteroid injections (IAS), TMJ symptoms, and TMJ findings on physician examination. TMJ imaging studies for which heterotopic ossifications were reported were reviewed. Pathology specimens were reviewed for the 2 children who underwent synovial biopsy of their TMJ.

Results. Twelve children were identified. The average duration between onset of JIA and detection of heterotopic ossification of TMJ on an imaging study was 36 months (range 19–94). Half the children had abnormal mouth-opening for age when the calcifications were first detected. In each case, the heterotopic ossification was first detected by computed tomography scan, and in 11 of the cases they were associated with synovial pannus formation as documented on an imaging study. Two children underwent synovial biopsy, which revealed reactive parosteal osteochondromatosis in one case and findings consistent with an intraarticular rheumatoid nodule in the other.

Conclusion. Heterotopic ossifications of the TMJ may be seen in children with JIA and are associated with particularly severe TMJ arthritis, joint destruction, and pannus formation. Pathology from these joints suggests that the heterotopic ossification may result from multiple pathological processes. (First Release April 15 2011; J Rheumatol 2011;38:1423–8; doi:10.3899/jrheum.101198)

Key Indexing Terms:

JUVENILE ARTHRITIS
HETEROTOPIC OSSIFICATION

TEMPOROMANDIBULAR JOINT ARTHRITIS
INTRAARTICULAR CORTICOSTEROID INJECTION

Arthritis of the temporomandibular joint (TMJ) has been reported in association with all of the categories of juvenile idiopathic arthritis (JIA), with a prevalence as high as 75%^{1,2,3}. Because of the superficial location of the mandibular growth plate, the TMJ is particularly susceptible to damage from inflammation, and damage to the joint has been associated with increased morbidity including micrognathia, malocclusion, chronic pain, and poor cosmetic outcomes^{4,5}. Because a large proportion of children are asymptomatic and/or have a normal TMJ examination despite radiographic evidence of TMJ damage, detection of TMJ arthritis requires a high index of suspicion by the examining physician^{5,6}. Despite the high prevalence of TMJ involvement in

JIA, the pathology of TMJ arthritis and how this affects the joint's response to local and systemic therapies is not completely understood. While reports have indicated a benefit of intraarticular corticosteroid injections (IAS) of the TMJ, the development of effective strategies for treatment of TMJ arthritis and for prevention of damage to the joint remains an area of active research^{7,8,9,10,11,12}.

Heterotopic ossifications of peripheral joints are well described as sequelae of IAS for treatment of JIA and have been reported to occur in 0.2%–6% of injected joints^{13,14,15}. Heterotopic ossification has also been reported in association with a range of crystal deposition diseases, secondary to systemic illnesses such as hyperparathyroidism, with tumors, and as a result of trauma^{14,15,16}. In adults, heterotopic ossifications of TMJ have been reported in association with both chondrocalcinosis and synovial chondromatosis^{17,18}. However, heterotopic ossification of TMJ has not been described in children. In this report we describe the characteristics of a series of children with JIA and TMJ arthritis with radiographic imaging evidence of heterotopic ossification, in order to provide additional information regarding the spectrum of TMJ disease in JIA.

From Seattle Children's Hospital and University of Washington, Seattle, Washington, USA.

S. Ringold, MD, MS, Acting Assistant Professor, Seattle Children's Hospital; M. Thapa, MD, Assistant Professor, University of Washington; E.A. Shaw, DO, Acting Assistant Professor; C.A. Wallace, MD, Professor, Seattle Children's Hospital.

Address correspondence to Dr. S. Ringold, Seattle Children's Hospital, 4800 Sandpoint Way NE, Seattle, WA 98105.

E-mail: Sarah.Ringold@seattlechildrens.org

Accepted for publication February 11, 2011.

MATERIALS AND METHODS

Patients. Patients with radiographic evidence of TMJ heterotopic ossification were identified through a search of an administrative database at Seattle Children's Hospital (SCH) maintained by the Division of Radiology. Each of these patient charts was then reviewed to identify patients who also met the 2001 Edmonton International League of Associations for Rheumatology (ILAR) criteria for a diagnosis of JIA¹⁹. Children were identified from the database between January 2002 and December 2008. Cases where there was radiographic evidence of fragmentation of the mandibular condyle leading to the presence of intraarticular calcifications were excluded, as the etiology of the abnormal calcification was evident in those cases.

The TMJ injections were performed by a dental surgeon, without imaging guidance, using 0.5–1 ml triamcinolone acetonide (40 mg/ml) or triamcinolone hexacetonide (20 mg/ml). Injections were performed with a 22-gauge, 1.5-inch spinal needle. The majority of injections were with triamcinolone acetonide.

Data collection. Retrospective chart review was performed to collect data on each patient's clinical and laboratory disease characteristics, age at onset of JIA, serologies, timing and number of IAS procedures for TMJ, patient-reported TMJ symptoms, TMJ findings on physician examination, and results of TMJ imaging studies. Measurements of maximal incisal opening were classified as normal or abnormal for age based on published ranges²⁰. Data regarding systemic medications and IAS were recorded from the patient's first SCH rheumatology clinic visit until their first imaging study on which calcifications were first detected and at their most recent rheumatology or dental clinic visit, or at their last rheumatology clinic visit, if they passed to an adult rheumatologist. IAS were performed by an oral and maxillofacial surgeon with either triamcinolone acetonide or triamcinolone hexacetonide without imaging guidance⁹.

Radiographic imaging studies of the patients' TMJ were obtained at the treating rheumatologist's discretion. Each radiographic imaging study for which heterotopic ossification was reported was re-reviewed with a pediatric radiologist (MT) with specific pediatric musculoskeletal expertise. Pathology specimens were reviewed when available.

Approval for this study was obtained from the Seattle Children's Hospital Institutional Review Board.

RESULTS

Patient characteristics, clinical findings, and medication use. Twelve children with heterotopic ossification of their TMJ were identified. Their JIA categories, serologies, and medication use are summarized in Table 1. The majority of patients had oligoarticular or polyarticular JIA ($n = 5$; 42% each group) and 9 of the 12 patients were positive for anti-nuclear antibody. The average duration between onset of JIA and physician concern for TMJ arthritis, defined as the first clinic visit when patient-reported TMJ symptoms and/or abnormal TMJ examination were documented, was 18 months (range 0–83 mo). The average duration between onset of JIA and detection of heterotopic ossification of TMJ on an imaging study was 36 months (range 19–94 mo).

At the time of the detection of heterotopic ossification, 3 children had documented complaints of TMJ pain, one child reported TMJ stiffness, one child reported decreased mouth opening, and one child reported jaw swelling. No symptoms were documented for 6 children. Measurements of maximal incisal opening were recorded for all children at the time of the detection of heterotopic ossification and 6 out of 12 (50%) were abnormal for age. At their most recent clinic

visit, 4 children reported difficulty eating and 4 children reported pain. Additional patient-reported symptoms included headache, difficulty with mouth opening, sticking, and crepitus. Maximal incisal opening was recorded for 8 children and 7 of these measurements were abnormal for age.

All the children except 2 had received systemic treatment with a disease-modifying antirheumatic drug prior to detection of the calcifications and 3 children had been treated with tumor necrosis factor- α (TNF- α) inhibitors. All children had been treated with at least one TMJ IAS prior to detection of the calcifications (range: 1–4). The average duration between first IAS and detection of TMJ calcification was 15 months (median 16 mo, range 7–23 mo). At the most recent followup visit, or at last visit to SCH Rheumatology prior to transfer to an adult rheumatologist, 7 children were receiving a TNF- α inhibitor and 3 children were not receiving any systemic therapies due to disease remission. All children were still followed by the SCH Dental Clinic at their most recent visit and 2 children had undergone jaw reconstruction surgery.

Radiographic imaging results. One hundred forty-three children had computed tomography (CT) scans of their TMJ for suspected arthritis during this time period. Ten of the 12 children identified for this series had radiographic imaging studies when TMJ arthritis was first suspected by their physician. Two of these 10 children had normal CT scans when TMJ disease was first suspected. Eight of the 10 children had bilateral arthritic changes of the TMJ (joint space narrowing, erosion, or condylar flattening) at the first imaging study where TMJ involvement was suspected. Six of the 12 children also had gadolinium-enhanced magnetic resonance imaging (MRI) of the TMJ at some time after their initial CT on which the ossification was noted. The heterotopic ossifications were noted in 3 of 6 of these MRI scans. No child had heterotopic ossification noted on their initial imaging study.

In each case, the heterotopic ossification was first detected by CT scan and was unilateral (11 right side, 1 left side). For each case the heterotopic ossification was noted to be irregular in appearance, and, although noted to be intraarticular, it could not be determined definitively whether they were also within the synovium. Children 2, 4, 5, 7, and 9 developed heterotopic ossification after 2 or more IAS in the joint that developed calcifications, while children 1, 3, 6, 8, 10, 11, and 12 developed heterotopic ossification following one IAS (Table 1). Three of the 4 children who had unilateral IAS developed heterotopic ossification in the ipsilateral joint.

One child (Case 8) had development of heterotopic ossification without concomitant pannus formation. The remainder of the children had radiographic evidence of pannus formation either by CT or MRI with gadolinium on followup radiographic studies (Figure 1). Three children (Cases 2, 4, and 11) with heterotopic ossification eventually developed unilateral ankylosis of the affected TMJ.

Table 1. Patient characteristics and medication use.

	Sex	Age at Diagnosis, yrs	JIA Category	Serology	Duration Between JIA Onset and TMJ Calcification, mo	Prior IAS of TMJ, no.	Duration Between TMJ IAS and TMJ Calcification, mo	Systemic Medications Prior to Detection of TMJ Calcification on Radiographic Imaging Study
1	F	10.5	Polyarticular	ANA+ RF+	33	2	18	NSAID, MTX
2	F	10	Oligoarticular	ANA-	17	2	17	None
3	F	14.5	Polyarticular	ANA- HLA-B27+	16	2	13	NSAID, MTX
4	F	4.5	Polyarticular	ANA+	19	1	10	NSAID, MTX, infliximab
5	F	13.5	Oligoarticular	ANA+	53	4	23	NSAID, MTX, etanercept
6	M	7	Enthesitis-Related Arthritis	ANA-	94	1	11	NSAID; prednisone; mtx
7	F	9.5	Polyarticular	ANA+	34	2	20	NSAID, prednisone, MTX, etanercept; infliximab
8	M	6	Psoriatic	ANA+	24	1	7	NSAID, MTX
9	F	12.5	Oligoarticular	ANA+ HLA-B27+	16	2	14	NSAID, MTX
10	F	5.5	Oligoarticular	ANA+	22	1	17	NSAID, MTX
11	F	1.5	Oligoarticular	ANA+	57	1	12	NSAID
12	F	7	Polyarticular	ANA+	51	1	18	SSZ, HCQ

TMJ: temporomandibular joint; JIA: juvenile idiopathic arthritis; IAS: intraarticular corticosteroid injection; ANA: antinuclear antibody; RF: rheumatoid factor; NSAID: nonsteroidal antiinflammatory drug; MTX: methotrexate; SSZ: sulfasalazine; HCQ: hydroxychloroquine.

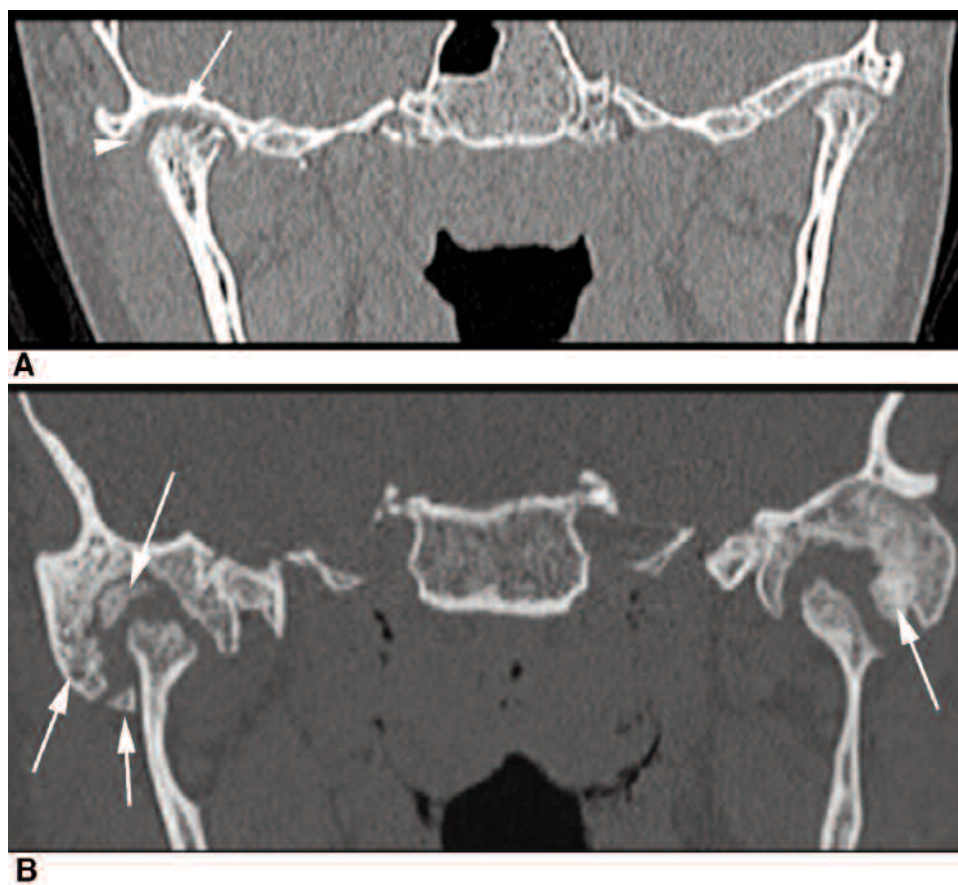
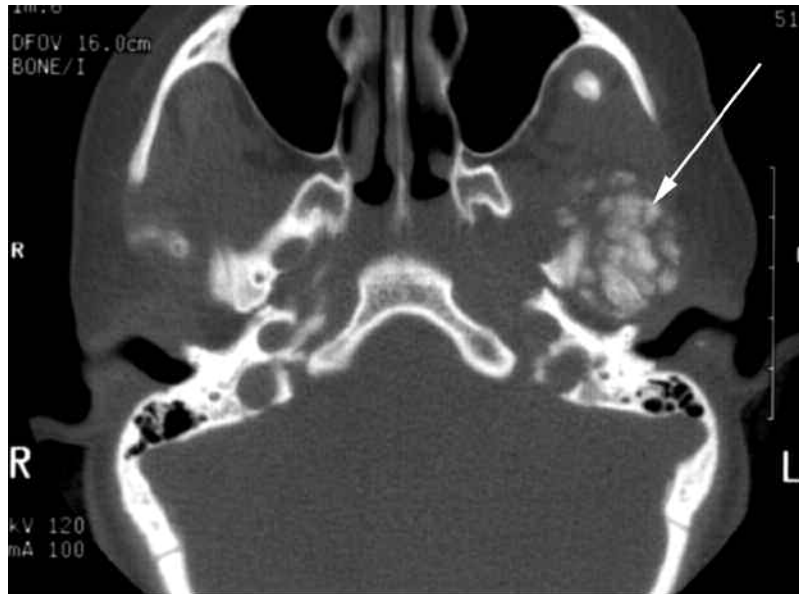

Figure 1. Radiographic imaging of intraarticular calcifications of the temporomandibular joint (TMJ) in 2 patients with juvenile idiopathic arthritis. A. Case 2. Coronal reconstruction of axially acquired noncontrast CT scan through the TMJ. There are bilateral condylar erosions, right worse than left. In the right TMJ, asymmetric widening of the joint space (arrow) is likely from pannus formation. Also note early heterotopic bone formation (arrowhead). B. Case 6. Coronal reconstruction of axially acquired noncontrast CT scan through the TMJ. There is extensive bilateral joint destruction with condylar erosions and significant heterotopic bone formation (arrows).

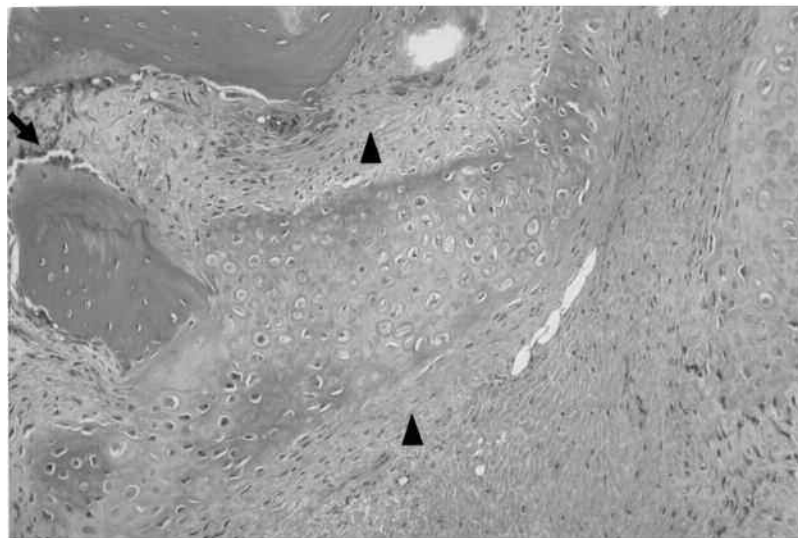
Pathology findings. Two children underwent synovial biopsies of their TMJ. The first (Case 1) underwent synovial biopsy at age 13.5 years for evaluation of an evolving calcific mass involving her left TMJ (Figure 2A). This mass had been first noted about 3 years after her initial diagnosis and after systemic treatment with methotrexate and local treatment with 2 bilateral IAS. Biopsy results revealed reactive parosteal osteochondromatosis and fibrous proliferation (Figure 2B). She subsequently underwent orthognathic sur-

gery for significant jaw deformity and a TNF- α inhibitor was added to her medication regimen.

The second patient (Case 3) underwent synovial biopsy at age 16.5 years for evaluation of a large area of ossification within her right TMJ (Figure 3A). The ossification had been first noted on a CT scan 1 year previously, and after she had undergone IAS of both TMJ on separate occasions and had received systemic therapy with methotrexate. Biopsy results showed irregular regions of necrosis surrounded by a

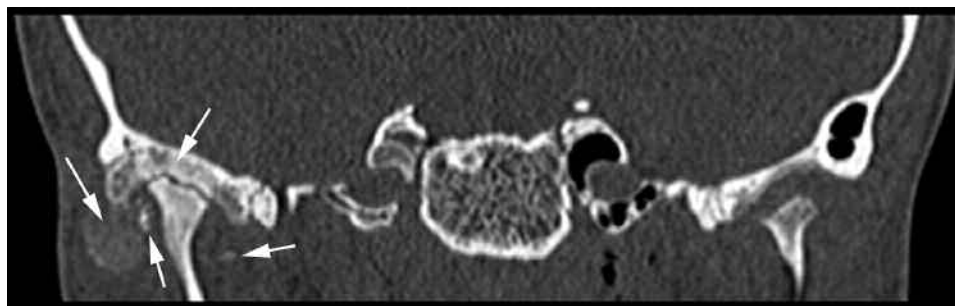


A

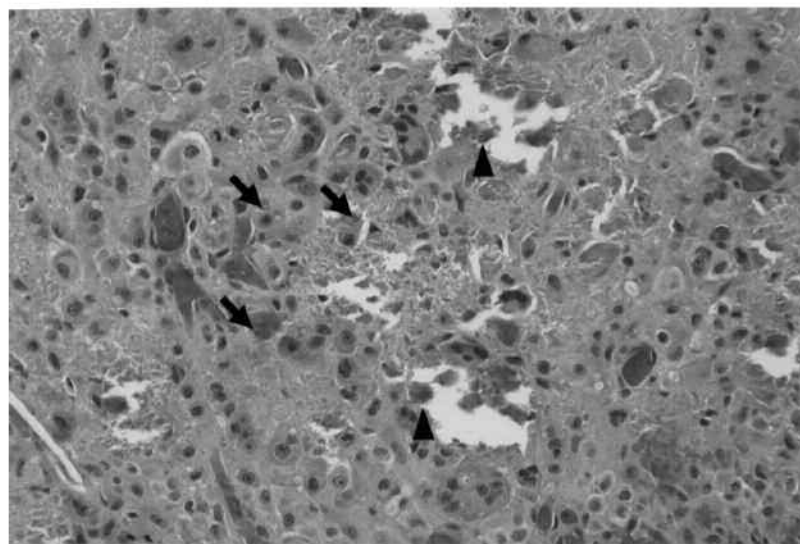


B

Figure 2. Radiographic imaging and pathological specimen findings for Case 1. A. Axial CT image through the temporomandibular joint (TMJ). Arrow indicates a calcified intraarticular mass in the left TMJ. B. Biopsy of the calcific mass showing reactive parosteal osteochondromatous and fibrous proliferation. Arrow indicates an area of osteoid surrounded by a rim of osteocytes, indicative of active bone formation. Arrowheads indicate areas of fibrous proliferation also occurring within this lesion.



A



B

Figure 3. Radiographic imaging and pathological specimen findings for Case 3. A. Coronal reconstruction of axially acquired noncontrast CT scan through the temporomandibular joint (TMJ). There is extensive bilateral joint destruction with condylar erosions and significant heterotopic bone formation (arrows). B. Biopsy of the calcification showing area consistent with intraarticular rheumatoid nodule. Arrows indicate a layer of epithelioid histiocytes and multinucleated giant cells surrounding an area of necrotic debris. Arrowheads indicate areas of osteoid scattered through the specimen.

layer of epithelioid histiocytes mixed with multinucleated giant cells and occasional lymphocytes that were thought to be consistent with intraarticular rheumatoid nodule (Figure 3B). The regions of necrosis appeared to be freshly calcified, with entrapped fragments of collagen and bone. Additional fragments of entrapped osteoid within the surrounding reactive tissue were also noted. She was subsequently treated with a maxillary orthotic device to aid with symptoms of TMJ dysfunction and chronic jaw pain.

DISCUSSION

We describe a series of 12 children with JIA and TMJ arthritis who had evidence of heterotopic ossification of their TMJ on one or more imaging studies. To our knowledge, this series represents the first description of heterotopic ossification of TMJ in JIA, and the first description of what appears on pathology to be an intraarticular rheumatoid nodule of the TMJ.

Although we initially hypothesized that the heterotopic ossification represented the sequelae of corticosteroid injection(s), as reported following IAS of peripheral joints, the pathology results from the 2 children who had synovial biopsies suggested that the heterotopic ossification may have reflected ongoing synovitis. Further, reports based on aspiration of periarticular calcifications resulting from IAS have suggested that the periarticular calcifications associated with steroid injections are hydroxyapatite crystals resulting from tissue necrosis from steroid leakage into soft tissue, and it has been hypothesized that these crystals themselves can induce a localized inflammatory arthritis²¹. In addition, an animal model of TMJ growth and repair indicated that experimentally induced mandibular shift may stimulate new bone formation within the contralateral condyle as a mechanism of repair²². However, the pathology results from our Case 1 (Figure 2) were not consistent with these previous observations, as the specimen indicated active, new bone

formation rather than crystal deposition with reactive inflammation, and the new bone formation was heterotopic, rather than condylar. In addition, in the cases described above, the heterotopic ossification appeared to be intra-articular and/or within the TMJ synovium, rather than in the periarticular soft tissues.

This finding has not been previously reported in the literature. Although it is possible that this finding has been observed in other patients but not published, we also hypothesize that this finding in our clinic cohort may be a result of improved recognition of TMJ arthritis in JIA, the close followup of children with severe TMJ disease, the increased use of TMJ IAS, and the use of CT for followup of condylar changes, which may be more sensitive for visualization of these small areas of ossification than MRI.

Our report has several limitations, as it represents children with very severe TMJ involvement; children in our clinic with known joint damage and/or increased symptoms are more likely to be referred to our dental surgeon, are more likely to undergo TMJ IAS, and are more closely followed with radiographic imaging studies. Given this ascertainment bias and the observational design of the study, and because only 2 children underwent biopsy of the affected joint, we could not determine whether a portion of these calcifications were a sequelae of the IAS or whether there were additional inflammatory processes that led to these findings. Because IAS are being used with increased frequency for treatment of TMJ arthritis, additional followup with standardized clinical and imaging evaluations will be necessary to better describe the outcomes in these children. Our series supports the observation that arthritis in the TMJ tends to be different from arthritis in other synovial joints and remains poorly understood; thus optimal treatment of arthritis in this joint represents a continuing challenge.

REFERENCES

1. Pedersen TK, Jensen JJ, Melsen B, Herlin T. Resorption of the temporomandibular condylar bone according to subtypes of juvenile chronic arthritis. *J Rheumatol* 2001;28:2109-15.
2. Weiss PF, Arabshahi B, Johnson A, Bilaniuk LT, Zarnow D, Cahill AM, et al. High prevalence of temporomandibular joint arthritis at disease onset in children with juvenile idiopathic arthritis, as detected by magnetic resonance imaging but not by ultrasound. *Arthritis Rheum* 2008;58:1189-96.
3. Twilt M, Moberg SM, Arends LR, ten Cate R, van Suijlekom-Smit L. Temporomandibular involvement in juvenile idiopathic arthritis. *J Rheumatol* 2004;31:1418-22.
4. Sarnat BG. The temporomandibular joint. Springfield, IL: Charles C. Thomas; 1951.
5. Larheim TA, Haanaes HR. Micrognathia, temporomandibular joint changes and dental occlusion in juvenile rheumatoid arthritis of adolescents and adults. *Scand J Dent Res* 1981;89:329-38.
6. Larheim TA, Hoyeraal HM, Stabrun AE, Haanaes HR. The temporomandibular joint in juvenile rheumatoid arthritis. Radiographic changes related to clinical and laboratory parameters in 100 children. *Scand J Rheumatol* 1982;11:5-12.
7. Martini G, Bacciliero U, Tregnaighi A, Montesco MC, Zulian F. Isolated temporomandibular synovitis as unique presentation of juvenile idiopathic arthritis. *J Rheumatol* 2001;28:1689-92.
8. Arabshahi B, Dewitt EM, Cahill AM, Kaye RD, Baskin KM, Towbin RB, et al. Utility of corticosteroid injection for temporomandibular arthritis in children with juvenile idiopathic arthritis. *Arthritis Rheum* 2005;52:3563-9.
9. Ringold S, Torgerson TR, Egbert MA, Wallace CA. Intra-articular corticosteroid injections of the temporomandibular joint in juvenile idiopathic arthritis. *J Rheumatol* 2008;35:1157-64.
10. Stoustrup P, Kristensen KD, Kuseler A, Pedersen TK, Gelineck J, Herlin T. Intra-articular vs. systemic administration of etanercept in antigen-induced arthritis in the temporomandibular joint. Part II: mandibular growth. *Pediatr Rheumatol Online J* 2009;7:6.
11. Kristensen KD, Stoustrup P, Kuseler A, Pedersen TK, Nyegaard JR, Hauge E, et al. Intra-articular vs. systemic administration of etanercept in antigen-induced arthritis in the temporomandibular joint. Part I: histological effects. *Pediatr Rheumatol Online J* 2009;7:5.
12. Kristensen KD, Stoustrup P, Kuseler A, Pedersen TK, Nyegaard JR, Hauge EM, et al. Quantitative histological changes of repeated antigen-induced arthritis in the temporomandibular joints of rabbits treated with intra-articular corticosteroid. *J Oral Pathol Med* 2008;37:437-44.
13. Breit W, Frosch M, Meyer U, Heinecke A, Ganser G. A subgroup-specific evaluation of the efficacy of intra-articular triamcinolone hexacetonide in juvenile chronic arthritis. *J Rheumatol* 2000;27:2696-702.
14. Job-Deslandre C, Menkes CJ. Complications of intra-articular injections of triamcinolone hexacetonide in chronic arthritis in children. *Clin Exp Rheumatol* 1990;8:413-6.
15. Sparling M, Malleon P, Wood B, Petty R. Radiographic followup of joints injected with triamcinolone hexacetonide for the management of childhood arthritis. *Arthritis Rheum* 1990;33:821-6.
16. Gilsanz V, Bernstein BH. Joint calcification following intra-articular corticosteroid therapy. *Radiology* 1984;151:647-9.
17. Covani U, Orlando B, Galletti C, Nuterini C, Barone A. Chondrocalcinosis of the temporomandibular joint: clinical considerations and case report. *Cranio* 2009;27:134-9.
18. Guarda-Nardini L, Piccotti F, Ferronato G, Manfredini D. Synovial chondromatosis of the temporomandibular joint: a case description with systematic literature review. *Int J Oral Maxillofac Surg* 2010;39:745-55.
19. Petty RE, Southwood TR, Manners P, Baum J, Glass DN, Goldenberg J, et al. International League of Associations for Rheumatology classification of juvenile idiopathic arthritis: second revision, Edmonton, 2001. *J Rheumatol* 2004;31:390-2.
20. Sheppard IM, Sheppard SM. Maximal incisal opening — a diagnostic index? *J Dent Med* 1965;20:13-5.
21. Dalinka MK, Stewart V, Bomalaski JS, Halpern M, Kricun ME. Periarticular calcifications in association with intra-articular corticosteroid injections. *Radiology* 1984;153:615-8.
22. Liu C, Kaneko S, Soma K. Effects of a mandibular lateral shift on the condyle and mandibular bone in growing rats. *Angle Orthod* 2007;77:787-93.