

## Neuromeningeal Tuberculosis in a Patient with Rheumatoid Arthritis Previously Exposed to Ineffective Etanercept Therapy and Revealed by Infliximab

To the Editor:

We describe the case of a 74-year-old French Caucasian woman, born in Nice, a former storekeeper, with a history of seropositive and erosive rheumatoid arthritis (RA) dating from 1993. She had been treated unsuccessfully (inefficacy or severe side effects) with hydroxychloroquine, methotrexate, and leflunomide. In February 2002, she was given infliximab 3 mg/kg/8 weeks in combination with leflunomide 20 mg per day. Hepatic cytolysis necessitated discontinuation in February 2005. Etanercept alone was tried for 7 months, also unsuccessfully. The hepatic cytolysis was subsequently attributed to the use of nonsteroidal antiinflammatory drugs. In October 2005, infliximab was introduced (5 mg/kg/8 wks) in association with leflunomide (10 mg/day) without glucocorticoids.

In September 2006, she was admitted to our department with headache, tiredness, equilibrium disturbances, and a clinical cerebellar syndrome. Treatment was discontinued but, 24 h later, right flaccid hemiplegia appeared with dysarthria. Brain computed tomography scan showed a pattern of cerebrovascular ischemic accident, and she was treated with low molecular weight heparin plus platelet antiaggregants. The motor deficiency was resolved within a few days, but temporospatial disorientation and confusion were still present 5 days after hospitalization. The confusion syndrome worsened, with fever (39.1°C) and symptoms of meningitis. Cerebrospinal fluid (CSF) was clear, 200 elements/mm<sup>3</sup>, with lymphocyte predominance (99%), high proteinorrachia [2.73 g/l (normal 0.15–0.45)] and low glycorrhachia [2.85 mmol/l (normal 3.20–4.80)]. Serum C-reactive protein and erythrocyte sedimentation rate were normal. A tuberculin skin test (TST) was negative, and chest radiograph was unremarkable.

Three possible diagnoses were considered: listeriosis, herpes simplex virus infection, and tuberculosis (TB). Initial treatment was directed at listeriosis and the herpes simplex virus (amoxicillin and acyclovir), but the patient failed to improve over 4 days. CSF analysis in this immunodepressed individual [anti-tumor necrosis factor (TNF) therapy] supported a possible diagnosis of tuberculous meningitis, and a combination of 4 antibiotics (isoniazid, pyrazinamide, rifampicin, and ethambutol) was begun. Fever disappeared in the next few days and neurological and general manifestations improved. Two weeks later, magnetic resonance imaging detected brain granuloma (Figure 1) and *Mycobacterium tuberculosis* was identified on CSF culture. The initial combination of 4 antibiotics was given for 2 months, followed by isoniazid plus rifampicin to 15 months, with regular clinical, biological, and CSF monitoring. Equilibrium distur-

bance persisted at 15 months, with clinical manifestations of normal pressure hydrocephalus, a well known chronic complication of tuberculous meningitis.

This case of TB associated with anti-TNF treatment with isolated neuromeningeal involvement is the second case described to our knowledge<sup>1</sup>. In our case, the period between initiation of anti-TNF therapy and the development of TB was 4 years, when the average delay in TB development in the literature was 11 months<sup>2</sup>. Another point of interest is the development of TB while under treatment with infliximab and not etanercept in a patient who has been treated with both medications.

TB in patients treated with anti-TNF tends to be severe, with extrapulmonary manifestations, and to develop rapidly after the medication is initiated, particularly when the agent is infliximab. Several theories have been put forward to explain the lower frequency of TB reactivation with etanercept. Factors include differences in mechanism of action, infliximab's longer half-life, and the greater popularity of infliximab. Infliximab binds both soluble and transmembrane TNF, whereas etanercept has a lower binding affinity for the latter<sup>3</sup>. In the context of TB, the implication is that infliximab disrupts granuloma integrity, because 100% neutralization of TNF invariably results in severely diminished inflammatory cell recruitment. Consequently, the high turnover of cells within the dynamic granuloma can no longer be maintained<sup>4</sup>. Etanercept may be thought of as partially preserving granuloma integrity, because it allows redistribution of bioactive TNF from sites of production such as the rheumatoid joint into other tissues, where overall, TNF concentrations are low. TNF bioactivity may therefore not be entirely blocked, thus preserving the residual antimicrobial function of macrophages in granulomatous lesions<sup>4</sup>. Monoclonal antibodies such as infliximab activate complement and cause antibody-dependent cellular toxicity. In the context of TB, lysed granuloma macrophages would release mycobacteria into the bloodstream, potentially explaining the relatively high occurrence of disseminated TB in infliximab-treated patients. Etanercept has no reported apoptosis-inducing effect<sup>4</sup>. TNF neutralization persists for several weeks with infliximab, compared with several days with etanercept, which allows minimal TNF activity between injections<sup>5</sup>. Preservation of 10%–30% of total TNF activity provides sufficient antimicrobial effect to minimize resurgence of TB and help maintain the stability of RA<sup>4</sup>. This can be an explanation for the development of TB in our patient with reintroduction of infliximab and not with etanercept.

Widespread dissemination of recommendations<sup>6</sup> has resulted in a decrease in the number of cases of TB<sup>3,7</sup>. Our patient was given infliximab before the publication of these recommendations, so TST and chest radiography were performed a few months later and were negative.

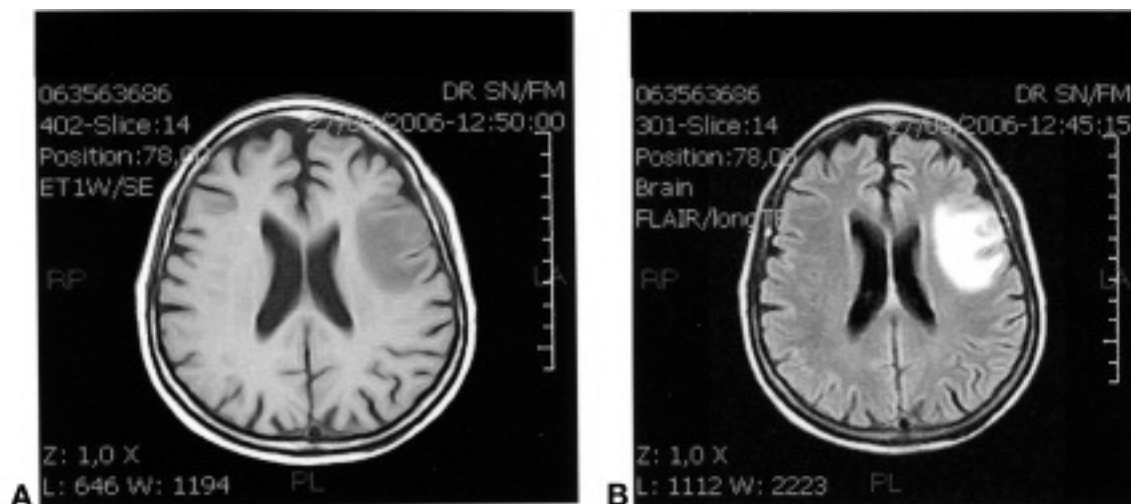


Figure 1. Magnetic resonance imaging showed brain granuloma.

TST remains the only tool available for rapid TB screening. Unfortunately, false-negative results are common (particularly among immunocompromised and severely sick patients). According to one study<sup>8</sup>, anti-TNF treatment can enhance the diagnostic value of the test by improving the anergic status associated with active arthritis. Observation of skin test-negative patients receiving anti-TNF therapy supports repeating the test in order to improve identification of patients requiring isoniazid treatment<sup>9</sup>; for this reason, recommendations include 2-step TST with an interval of 7–10 days between steps. Against that background, TB-specific antigens (CFP10, ESAT6) have been suggested for the past few years. They seem to be more specific for TB screening (overall, ESAT6 and CFP10 have 73% sensitivity and 93% specificity)<sup>10</sup> with a similar sensitivity in active TB with TST. But they do not permit differentiating latent from active forms.

This case of TB induced by anti-TNF therapy has several exceptional features: very rare localizations in the brain of TB granuloma with a clinical pattern of tuberculous meningoencephalitis, the long interval between the introduction of biologic agents and the development of TB, which seems to be more in favor of a primary infection. But it is not possible to know whether TB was a reactivation of latent TB or primary infection, because the TST was not performed previously but during biologic treatment. This emphasizes the risk of development of serious forms of TB with biologic agents and the need to be aware of unusual presentations of TB among patients treated with TNF antagonists.

VIRGINIE DaSILVA, MD, University Hospital, Rheumatology;  
CHRISTIAN H. ROUX, MD, Academic Hospital l'Archet 1, Service de Rhumatologie; EVELYNE BERNARD, MD, University Hospital, Infectious Diseases; OLIVIER BROCCO, MD; CHRISTINE ALBERT, MD; HASNA CHAMI, MD; CHRISTIAN GRISOT, MD; YACINE ALLAM, MD, University Hospital, Rheumatology; PIERRE DELLAMONICA, MD, University Hospital, Infectious Diseases; LIANA EULLER-ZIEGLER, MD, University Hospital, Rheumatology, Nice, France. Address correspondence to Dr. Da Silva. E-mail: dasilva.v@chu-nice.fr

## REFERENCES

1. Keane J, Gershon S, Wise RP, Mirabile-Levens E, Kasznica J, Schwietzman WD, et al. Tuberculosis associated with infliximab, a tumor necrosis factor alpha-neutralizing agent. *N Engl J Med* 2001;345:1098-104.

2. Keane J. Tumor necrosis factor blockers and reactivation of latent tuberculosis. *Clin Infect Dis* 2004;39:300-2.
3. Gomez-Reino JJ, Carmona L, Angel Descalzo M; Biobadaser Group. Risk of tuberculosis in patients treated with tumor necrosis factor antagonists due to incomplete prevention of reactivation of latent infection. *Arthritis Rheum* 2007;57:756-61.
4. Ehlers S. Why does tumor necrosis factor targeted therapy reactivate tuberculosis? *J Rheumatol* 2005;32 Suppl 74:35-9.
5. Gardam MA, Keystone EC, Menzies R, Mannes S, Skamene E, Long R, et al. Anti-tumor necrosis factor agents and tuberculosis risk: mechanisms of action and clinical management. *Lancet Infect Dis* 2003;3:148-55.
6. Agence française de sécurité sanitaire des produits de santé. Recommendations for assessing risk and for managing mycobacterium tuberculosis infection and disease in patients due to start anti-TNF treatment. Available from: [www.afssaps.fr](http://www.afssaps.fr)
7. Carmona L, Gomez-Reino JJ, Rodriguez-Valverde V, Montero D, Pascual-Gomez E, Mola EM, et al; BIOBADASER group. Effectiveness of recommendations to prevent reactivation of latent tuberculosis infection in patients treated with tumor necrosis factor antagonists. *Arthritis Rheum* 2005;52:1766-72.
8. Joven BE, Almodovar R, Galindo M, Mateo I, Pablos JL. Does anti-tumor necrosis factor alpha treatment modify the tuberculin PPD response? *Ann Rheum Dis* 2006;65:699.
9. Ulrichs T, Munk ME, Molenkorpff H, Behr-Perst S, Colangeli R, Gennaro ML, et al. Differential T cell responses to Mycobacterium tuberculosis ESAT 6 in tuberculosis patients and healthy donors. *Eur J Immunol* 1998;28:3949-58. Erratum in: *Eur J Immunol* 1999;29:725.
10. Van Pinxteren LA, Ravn P, Agger EM, Pollock J, Andersen P. Diagnosis of tuberculosis based on the two specific antigens ESAT-6 and CFP 10. *Clin Diagn Lab Immunol* 2000;7:155-60.

*J Rheumatol* 2010;37:2; doi:10.3899/jrheum.090241